

Immediate Surgical Excision Following Embolization of an Extensive Pediatric Facial High Flow AV Malformation

Prajwal M.¹ Sebin V. Thomas¹  Mohammed Rafeeqe P.K.² Raghuram Menon¹

¹ Department of Plastic Surgery, Aster MIMS Hospital, Calicut, Kerala, India

² Division of Neuro Intervention, Department of Clinical Imaging and Interventional Radiology, Aster MIMS Hospital, Calicut, Kerala

Address for correspondence Prajwal M., MBBS, DrNB, Department of Plastic Surgery, 4th floor Aster MIMS Hospital, Calicut 673016, Kerala, India (e-mail: kmpm71@gmail.com).

Indian J Plast Surg 2024;57(Suppl S1):S142–S144.

Arteriovenous (AV) malformations are rare congenital vascular anomalies accounting to approximately 0.1% of the general population.¹ They represent primitive communications between multiple arteries and draining veins without interconnecting capillaries, and are organized into tangled system of vessels called niduses.² Among the recent techniques embolization followed by surgical resection is found to

have best success rates.³ Due to technical difficulties most often excision of the lesion is done after 24 to 48 hours of embolization.

We planned to excise a large (8 × 7 cm) high-flow arterial malformation on a 7-year-old child (► **Fig. 1**) on a single day. By 8 a.m., under general anesthesia, left superficial temporal, internal maxillary, and lingual arteries were embolized using

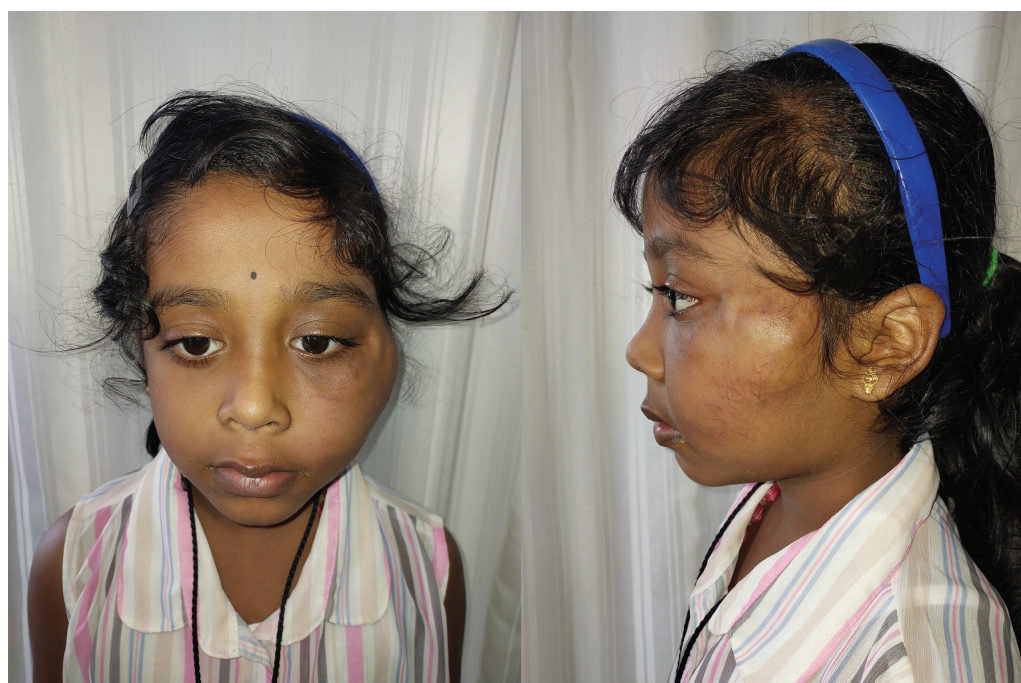

Fig. 1 Preop image front and lateral view.

article published online
June 25, 2024

DOI <https://doi.org/10.1055/s-0044-1787987>.
ISSN 0970-0358.

© 2024. Association of Plastic Surgeons of India. All rights reserved. This is an open access article published by Thieme under the terms of the Creative Commons Attribution-NonDerivative-NonCommercial-License, permitting copying and reproduction so long as the original work is given appropriate credit. Contents may not be used for commercial purposes, or adapted, remixed, transformed or built upon. (<https://creativecommons.org/licenses/by-nc-nd/4.0/>)
Thieme Medical and Scientific Publishers Pvt. Ltd., A-12, 2nd Floor, Sector 2, Noida-201301 UP, India

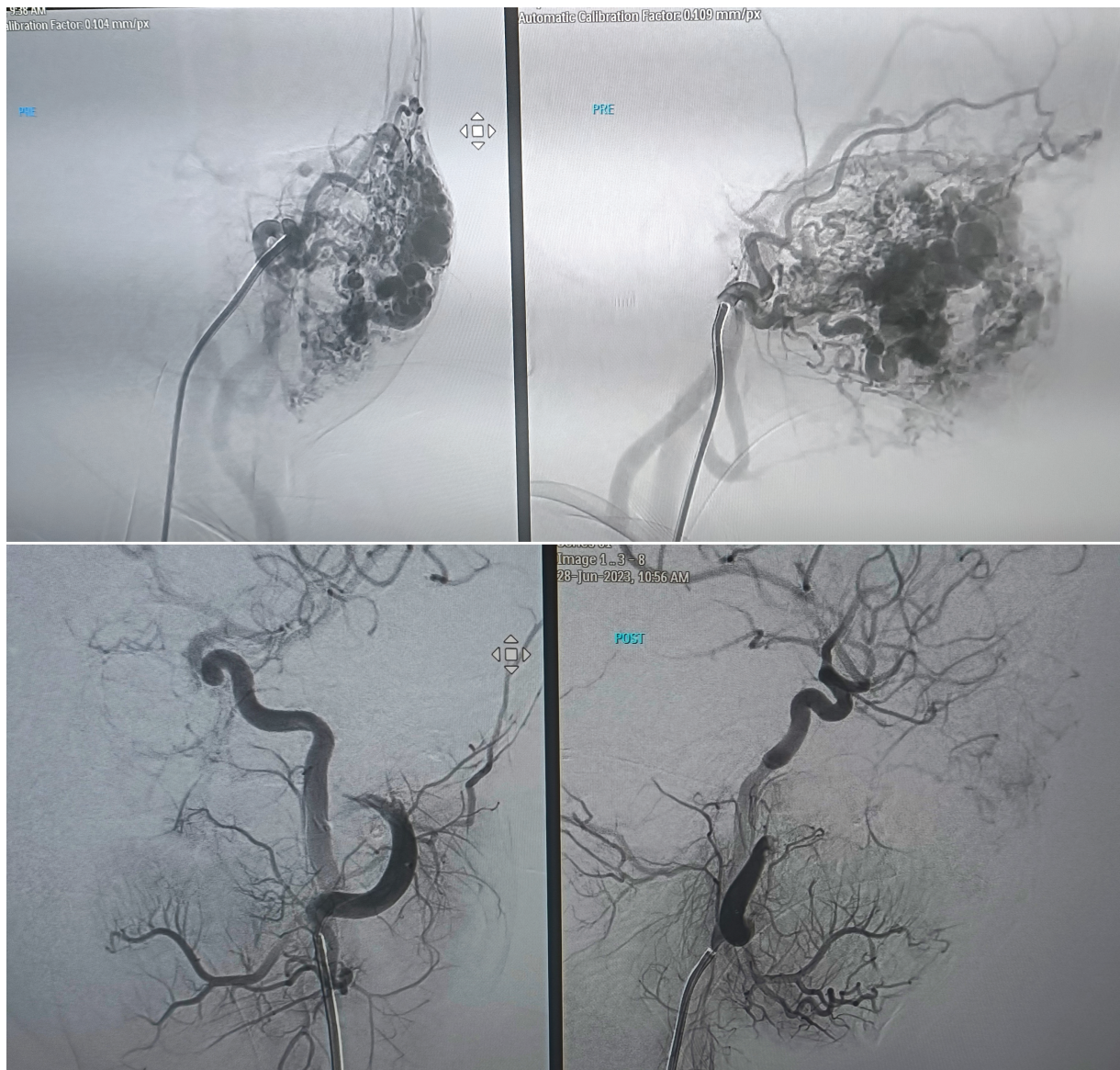


Fig. 2 Pre- and postembolization visuals.

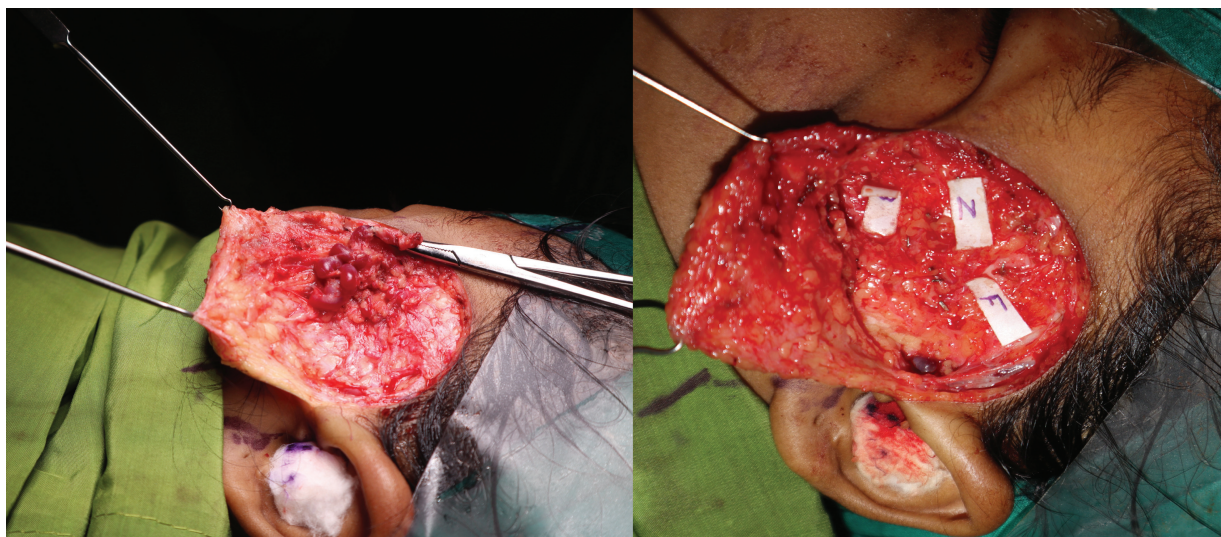


Fig. 3 Intraoperative before and after excision image (with branches of facial nerve marked, T, temporal; Z, zygomatic; B, buccal).

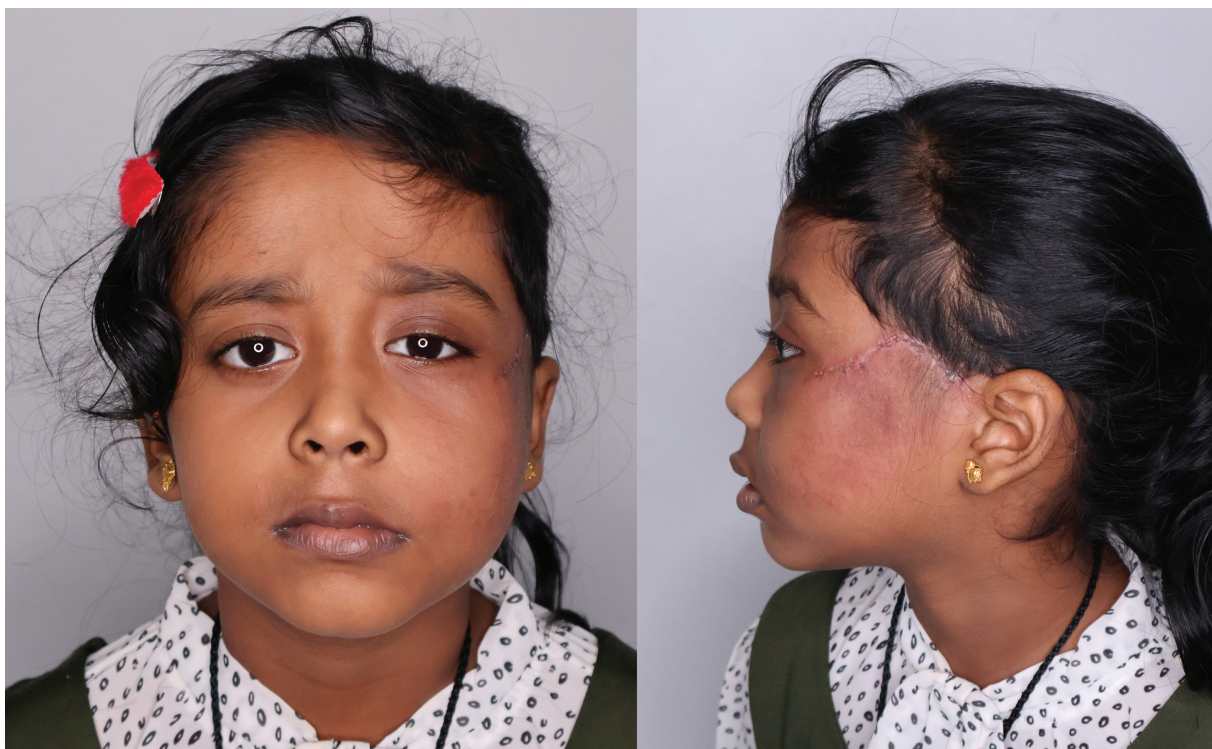

Fig. 4 Three weeks postop image front and lateral view.

N-butyl-cyanoacrylate in combination with lipidol and the facial artery was occluded using gel foam by the interventional radiology team (►Fig. 2). She was then shifted to the operation theater under ventilator support, and without further delay vascular clusters were excised (►Fig. 3). Left zygomatic and buccal branch of the facial nerves were safely dissected out. Total duration of the whole procedure was 5 hours. Facial nerve function was found to be normal postoperatively. She was discharged after 2 days. Suture removal was done after 7 days. Her wound healed well (►Fig. 4). Later, she was started on compression dressing and scar massaging.

Recent literatures idealize the interval between embolization and surgery to be within 1 to 3 days.¹ Few literature do emphasize on advantages of performing both embolization and excision in a single stage,⁴ but there is scarcity of data in Indian scenario and also about lesion involving the head and neck region.

Apart from the economic benefits, early surgical excision had the advantage of very minimal tissue reaction while operating with no bleeders or blood clots, and the surrounding tissues appeared fresh and healthy. There was considerable reduction in local inflammatory exudates as minimal time was given for hypoxic reaction to progress within the area of resection. The benefit of having a virgin display of malformations without any

inflammatory reaction gives a better delineation of structures and also reduces operating time.

By undertaking this quicker protocol, managing high-flow AV malformation by presurgical embolization and immediate excision is more cost effective with better outcomes. Utilizing the idea of hybrid theaters with inbuilt cath laboratory will further reduce anesthesia and operating time.

Conflict of Interest

None declared.

References

- 1 Shoukr T, Abdel Khalek H, Sadaka MS. Extensive facial arteriovenous malformations; combined approach, embolization followed by surgical reconstruction. *The Egyptian Journal of Plastic and Reconstructive Surgery* 2023;47(03):165–171
- 2 Bhandari PS, Sadhotra LP, Bhargava P, Bath AS, Mukherjee MK, Maurya S. Management strategy for facial arteriovenous malformations. *Indian J Plast Surg* 2008;41(02):183–189
- 3 Krt A, Cemazar M, Lovric D, Sersa G, Jamsek C, Groselj A. Combining superselective catheterization and electrochemotherapy: a new technological approach to the treatment of high-flow head and neck vascular malformations. *Front Oncol* 2022; 12:1025270
- 4 Chewing RH, Monroe EJ, Lindberg A, et al. Combined glue embolization and excision for the treatment of venous malformations. *CVIR Endovasc* 2018;1(01):22