Article published online: 2024-08-22

A Rare Cause of Gastric Ulcer in a Treated Case of Diffuse Large B-Cell Lymphoma of Stomach—Cytomegalovirus-Associated Gastric Ulcer

Akhil Mahajan[1] Sridhar Sundaram[1] Kiran Mane[1] Rahul Puri[1] Shravan G.H.[1]

[1] Department of Digestive Diseases and Clinical Nutrition, Tata Memorial Hospital, Mumbai, Maharashtra, India

J Gastrointest Infect 2024;14:28–30.

Address for correspondence Akhil Mahajan, MBBS, MD, Department of Digestive Diseases and Clinical Nutrition, Tata Memorial Hospital, Dr Ernest Borges Road, Mumbai 400012, Maharashtra, India (e-mail: dr.akhilmahajan5@gmail.com).

Abstract

Cytomegalovirus (CMV), a double-stranded deoxyribonucleic acid virus, belongs to the Herpesviridae family. The seroprevalence of CMV varies from 40 to 100% depending on the population studied or detection method used. Infection by CMV is not a rare disease and is frequently observed in immunocompromised hosts with hematological or immunological diseases or under treatment with glucocorticoids or immunosuppressants. CMV infection can manifest as asymptomatic, constitutional symptoms or tissue-invasive diseases. The gastrointestinal (GI) tract is one of the most commonly involved systems and associated with 30% of tissue-invasive diseases among immunocompetent patients. GI involvement in CMV infection most commonly involves the colon. Upper GI tract involvement, especially CMV gastritis, has rarely been recognized or reported.

Keywords
- CMV
- DLBCL
- gastric ulcer

Introduction

Cytomegalovirus (CMV), a double-stranded deoxyribonucleic acid virus, belongs to the Herpesviridae family. The seroprevalence of CMV varies from 40 to 100% depending on the population studied or detection method used. Infection by CMV is not a rare disease and is frequently observed in immunocompromised hosts with hematological or immunological diseases or under treatment with glucocorticoids or immunosuppressants. CMV infection can manifest as asymptomatic, constitutional symptoms or tissue-invasive diseases.[1] The gastrointestinal (GI) tract is one of the most commonly involved systems and associated with 30% of tissue-invasive diseases among immunocompetent patients.[2] GI involvement in CMV infection most commonly involves the colon. Upper GI tract involvement, especially CMV gastritis, has rarely been recognized or reported.

Case History

We present a 70-year-old male patient who presented with loss of appetite and loss of weight, early satiety for 2 months with no hematemesis, melena, or abdominal pain. Patient underwent upper GI endoscopy at a local hospital which showed a circumferential ulcerated lesion seen from body to antrum causing luminal narrowing likely linitis plastica with deformed antrum. Histopathology was inconclusive and hence, patient was referred to our center. Patient underwent endoscopy at our hospital which revealed a large ulcer in the distal body and antrum region of the stomach. Histology revealed atypical lymphoid proliferation. On immunohistochemistry (IHC) testing, the atypical lymphoid cells were diffusely positive for CD20 and CD3 which highlights reactive T cells. On additional IHC, cells were positive for CD10 and

received
January 17, 2024
First Decision
May 11, 2024
accepted
May 26, 2024

DOI https://doi.org/10.1055/s-0044-1787863.
ISSN 2277-5862.

Thieme Medical and Scientific Publishers Pvt. Ltd., A-12, 2nd Floor, Sector 2, Noida-201301 UP, India

Bcl6 and were negative for Bcl2. Mib-1 labeling index was >90%, which was suggestive of diffuse large B-cell lymphoma. Patient received 6 cycles of chemotherapy and radiotherapy in 25 fractionated doses of 45 Gray. Posttreatment, response imaging showed asymmetric wall thickening noted along the greater, lesser curvature and pyloric antrum of lesser curvature, with maximum thickness of 1 cm without any significant fludeoxyglucose tracer uptake. Subsequently, patient was reviewed in multidisciplinary team meeting and was planned for consolidative radiotherapy to stomach at a dose of 25 Gray in 19 fractions.

Now the patient presented with abdominal pain and vomiting for 2 weeks, which did not improve despite conservative management. Repeat endoscopy was done which showed an ulcer in the midbody of the stomach with erythematous, infiltrated, and edematous mucosa throughout the stomach and duodenum (►**Fig. 1**). Histopathology revealed atrophic mucosa with severe chronic gastritis. The glands showed nuclear enlargement and smudging suggestive of a viral infection. Subsequently, IHC was done which revealed CMV infection (►**Fig. 3**). In view of the above clinical picture, patient received antivirals in the form of ganciclovir for 2 weeks followed by valganciclovir as continuation phase for a total duration of 4 weeks. In addition, patient also received supportive care with proton-pump inhibitors and sucralfate. Repeat gastroscopy was done after 6 weeks which revealed a partially healed gastric ulcer (►**Fig. 2**). Patient improved symptomatically thereafter and starting tolerating oral diet.

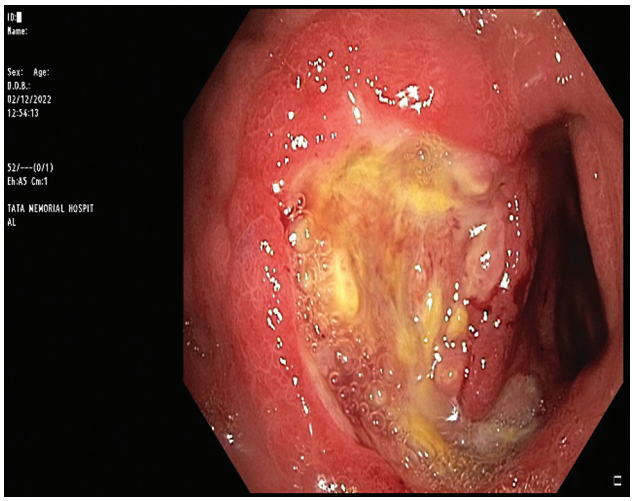

Fig. 1 Endoscopic image of a large excavated ulcer with heaped up margins in distal stomach.

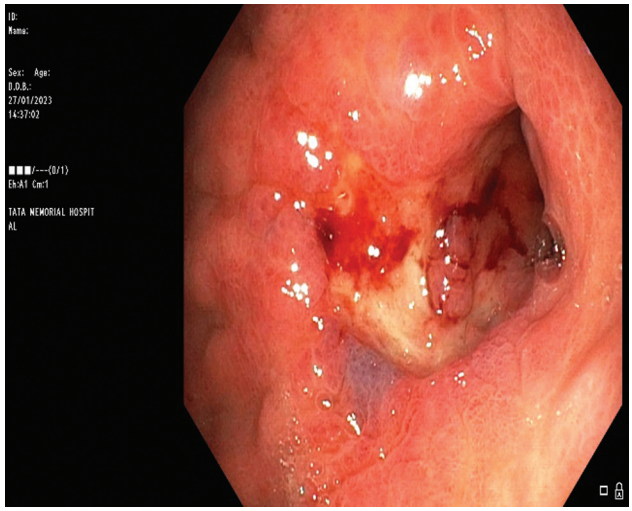

Fig. 2 Endoscopic image of the above healed ulcer after treatment with ganciclovir.

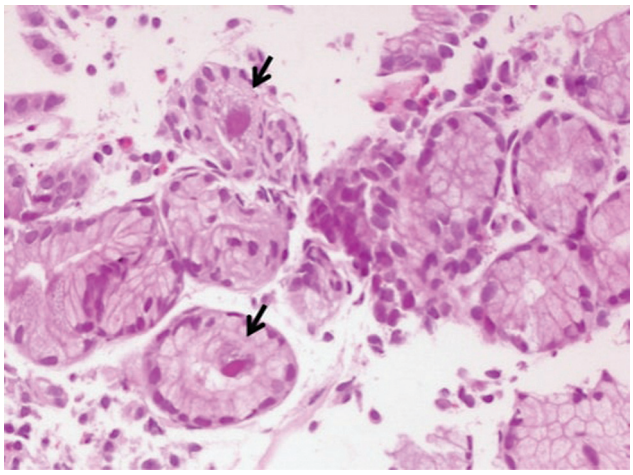

Fig. 3 Microscopic image with hematoxylin and eosin (H&E) staining showing chronic gastritis and scattered large cells with intranuclear and intracytoplasmatic inclusion bodies.

Discussion

Immunosuppressive diseases or exposure to immunosuppressive agents are the most important triggers for the CMV reactivation. In immunosuppressed patients, its severity is directly related to the degree of immunosuppression with manifestations ranging from fever to organ involvement.[3] In patients with upper GI tract CMV infections, gastric ulcers are found in 55% of patients, typically in the gastric antrum. Ischemic mucosal damage resulting from CMV infection of small artery endothelial cells has been hypothesized as a potential mechanism of GI tract ulceration. Inclusion bodies have also been reported to be present in the endothelial cells of small arteries. The name "cytomegalic vasculitis" has been proposed in such circumstances.[4] Due to variety of symptoms, endoscopic findings, biopsy locations, and testing techniques, diagnosing CMV GI disorders can be difficult. There is no way to differentiate the symptoms and test results from other infectious diseases. The most prevalent endoscopic signs of CMV infection are variable ulcers; nevertheless, diagnosis is challenging based only on endoscopic findings. Endoscopic features could be classified into discrete ulcerative type with or without exudate and diffuse erythematous type with/without exudate.[5] On endoscopy, CMV-induced gastric ulcers may resemble to those caused by *Helicobacter pylori* or by nonsteroidal anti-inflammatory drugs. A routine evaluation for CMV ulcer confirmation involves an endoscopic biopsy of the ulcer edge to look for nuclear inclusion bodies. Nonetheless, it has been noted that

identifying nuclear inclusion bodies in routine sections stained with hematoxylin and eosin is challenging and insensitive for detecting CMV infection.[6] The current recommendations are to use IHC or in situ hybridization to detect CMV protein or nucleic acid in addition to histologically identifying nuclear inclusion bodies. The most widely used regimen for treatment is intravenous ganciclovir administered for 3 or 5 weeks, while foscarnet is an effective alternative.[7] In this case report, we describe a case of gastric CMV ulcer mimicking residual gastric lymphoma, which resolved completely with antiviral therapy.

Ethical Statement

Informed consent was obtained from the patient. Institutional ethical approval obtained to publish the report.

Data Availability Statement

There is no data associated with this work.

Funding

None.

Conflict of Interest

None declared.

References

1 Fakhreddine AY, Frenette CT, Konijeti GG. A practical review of cytomegalovirus in gastroenterology and hepatology. Gastroenterol Res Pract 2019;2019:6156581
2 You DM, Johnson MD. Cytomegalovirus infection and the gastrointestinal tract. Curr Gastroenterol Rep 2012;14(04):334–342
3 Sanbonmatsu Gámez S, Ruiz MP, Navarro Marí JM. Infección por citomegalovirus humano. [Infection by human cytomegalovirus] Enferm Infecc Microbiol Clin 2014;32(Suppl 1):15–22
4 Campbell DA, Piercey JR, Shnitka TK, Goldsand G, Devine RD, Weinstein WM. Cytomegalovirus-associated gastric ulcer. Gastroenterology 1977;72(03):533–535
5 Yoon J, Lee J, Kim DS, et al. Endoscopic features and clinical outcomes of cytomegalovirus gastroenterocolitis in immunocompetent patients. Sci Rep 2021;11(01):6284
6 de Castro ML, Tardío A, del Campo V, et al. A comparative study of two histological techniques for the identification of cytomegalovirus infection in colorectal biopsies from patients with chronic inflammatory bowel disease. Rev Esp Enferm Dig 2009;101(10): 697–705
7 Torre-Cisneros J, Aguado JM, Caston JJ, et al; Spanish Society of Transplantation (SET) Group for Study of Infection in Transplantation of the Spanish Society of Infectious Diseases and Clinical Microbiology (GESITRA-SEIMC) Spanish Network for Research in Infectious Diseases (REIPI) Management of cytomegalovirus infection in solid organ transplant recipients: SET/GESITRA-SEIMC/REIPI recommendations. Transplant Rev (Orlando) 2016; 30(03):119–143

