




Volar Plate Draping (VPD) for Severely Comminuted Proximal Phalanx Head Fractures

Ashwini Varadha Rajan¹ Vigneswaran Varadharajan¹ Praveen Bhardwaj¹ S. Raja Sabapathy¹

¹The Department of Plastic, Hand and Reconstructive Microsurgery, Ganga Medical Center and Hospitals, Coimbatore, Tamil Nadu, India

Address for correspondence Praveen Bhardwaj, MS, The Department of Hand and Microsurgery, Ganga Medical Centre and Hospital, 313, Mettupalayam Road, Coimbatore 641043, Tamil Nadu, India (e-mail: drpb23@gmail.com).

Indian J Plast Surg

Abstract

While proximal phalangeal joint injuries with comminution of the base of the middle phalanx are common injuries, proximal interphalangeal (PIP) joint fracture dislocations with an intact base of middle phalanx and a comminuted head of proximal phalanx are rare. Volar plate arthroplasty and other described techniques prevail for the former injury, while the latter does not have any supportive literature on the exact method of management. We herein present a 20-year-old male with a severely comminuted head of proximal phalanx fracture with dislocation of the PIP joint, which was not reconstructable but was managed successfully with a novel technique of volar plate draping that resurfaced the raw phalangeal head. A 3-year follow-up of the patient, whose finger has full, painless, and complete functional range of movement, gives us the belief that this procedure can provide a fully functional finger where other methods fail to do so.

Keywords

- ▶ Volar Plate
- ▶ PIP Joint Fractures
- ▶ Proximal Phalanx Head Fractures
- ▶ Resurfacing
- ▶ Arthroplasty

Introduction

Volar plate arthroplasty (VPA), popularized by Eaton and Malerich,¹ is a well-established technique for providing mobile proximal interphalangeal joints (PIPs) for injuries with severe comminution of the middle phalanx (MPx) base.² However, use of the volar plate in severely comminuted fractures of the head of the proximal phalanx (PPx), especially acute scenarios, is inadequately established in literature. Some texts even mention fractures of the head as a contraindication for VPA.³ We present a rare case of comminuted fracture of the head of PPx which was not amenable to reconstruction. We performed a volar plate draping to resurface the raw phalangeal neck, in anticipation of providing a mobile joint to this young patient who understood the uncertain nature of the operation. He attained an extremely satisfactory, painless, range of movement, and was extremely happy about the outcome, encouraging us to report this technique for wider use in such injuries.

Case Report

A 20-year-old male presented with a closed, severely comminuted fracture of the head of PPx with PIPJ dislocation of the right middle finger. Open reduction of the joint was planned under regional anesthesia. Volar plate was reflected as a proximally based flap. The head of the PPx was extremely comminuted, with small bony fragments that could not be replaced (▶ **Fig. 1**). Since the volar plate was uninjured, it was used to create an even articulating surface. Removal of the bony fragments along with 5-mm shortening of the PPx neck, necessitated by the extensive damage, reduced the height of the PPx enough to allow the volar plate to be flipped over the distal portion of the PPx, from volar to dorsal side. It was then sutured dorsally, to the periosteum and capsule on one side and using Prolene suture taken through a drill hole in the bone, on the other side (▶ **Fig. 2**). This provided a contoured surface that articulated well with the base of the MPx. After

DOI <https://doi.org/10.1055/s-0044-1787849>.
ISSN 0970-0358.

© 2024. Association of Plastic Surgeons of India. All rights reserved. This is an open access article published by Thieme under the terms of the Creative Commons Attribution-NonDerivative-NonCommercial-License, permitting copying and reproduction so long as the original work is given appropriate credit. Contents may not be used for commercial purposes, or adapted, remixed, transformed or built upon. (<https://creativecommons.org/licenses/by-nc-nd/4.0/>)
Thieme Medical and Scientific Publishers Pvt. Ltd., A-12, 2nd Floor, Sector 2, Noida-201301 UP, India

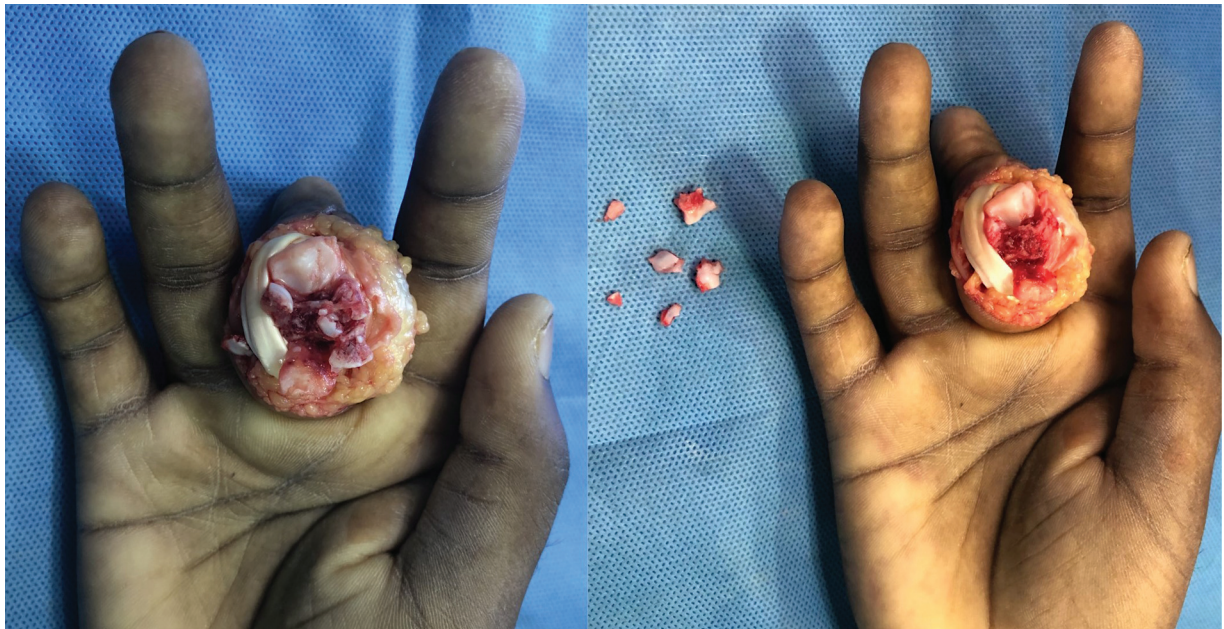


Fig. 1 Comminuted fracture of the proximal phalanx head with multiple loose fragments.

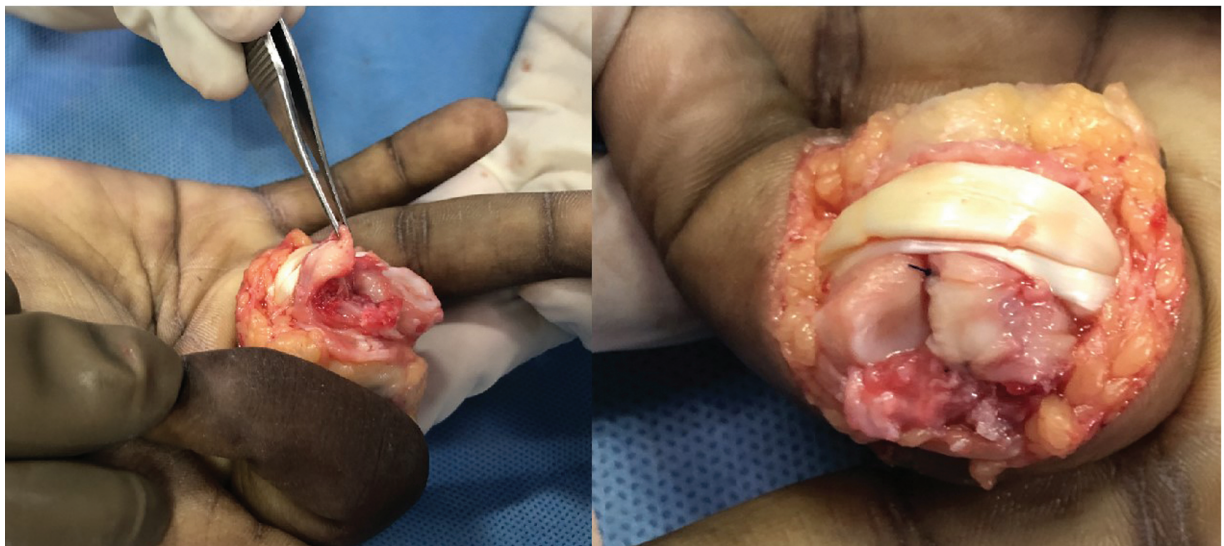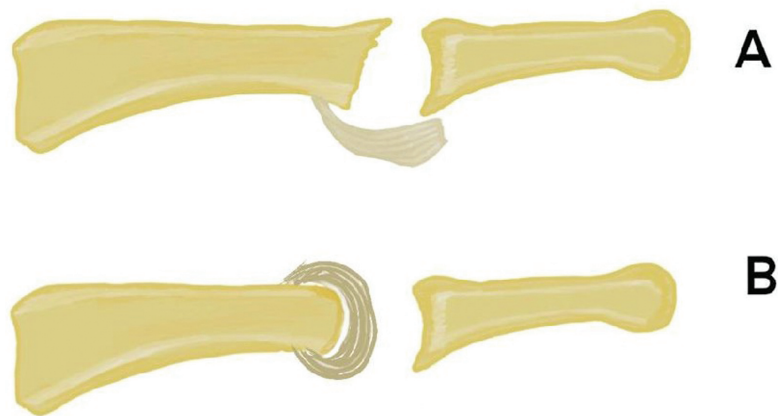


Fig. 2 Schematic representation and clinical photograph demonstrating volar plate draping.

closure, the PIPJ was stable, maintained by the tension of the flexor and extensor tendons. Ten degrees of lateral deviation noted intraoperatively, was managed by buddy strapping the middle finger to the index and ring fingers. Range of motion (ROM) intraoperatively was 110 degrees of flexion at the PIPJ, and complete extension. Active mobilization of the finger was started on day 1.

The patient maintained 100 degrees of active ROM throughout follow-up. Physiotherapy included protected mobilization for 4 weeks, day-to-day activities at 4 weeks, and normal use at 8 weeks. He maintained an excellent ROM throughout, with a total active flexion score of the American Society for Surgery of the Hand of > 220 degrees, and no palm-tip distance. At 3-year follow-up, his ROM at the PIPJ was 110 degrees, painless, and smooth (► **Supplementary Video 1**). He also used his hand for routine and rigorous activities like sports and weightlifting. A slight ulnar deviation of the finger at the PIPJ was noted, which did not cause

instability, malalignment, rotation, or crossing over of the finger (► **Fig. 3**) (► **Figs. 5A–D**).

Supplementary Video 1

Range of movement at three years follow up. Online content including video sequences viewable at: <https://www.thieme-connect.com/products/ejournals/html/10.1055/s-0044-1787849>.

Discussion

PIPJ fracture dislocations are estimated to be 1 to 10 in 100,000 patients⁴ and mismanaged injuries in the PIPJ can result in arthritis of the joint. With a ROM of 10 degrees hyperextension to 110 degrees flexion, PIPJ has 100 to 120 degrees arc of motion, constituting approximately 85% of the finger flexion in grasp.^{2,5} Thus, preserving PIPJ movement should be a priority. For comminuted fractures of the MPx base, time-tested operations include volar plate and hemi-hamate arthroplasties.^{1,3} However, for uncommon, comminuted fractures of the PPx head (London type III)^{5,6} no specific treatment protocols exist. A surgery that provides painless, free movement of a joint, any day surpasses arthrodesis, which functionally reduces pinch aperture, strength, and coordination between all the fingers, required for daily function,⁷ especially significant in younger patients.

Two important factors in achieving good range of movement at the PIPJ are concentricity of the articular surfaces and early ROM.⁵ Joint stability is provided by the shape of the MPx that fits on the head of the PPx, along with soft tissue structures. Concentricity of the surfaces with respect to each other enables them to work in sync, naturally maintaining stability through the range of movement. Since the MPx base was intact, in our patient, the focus was to recreate the impaired contour of the head of PPx by draping the thick volar plate over the remaining neck of PPx, which cannot be achieved by the standard Tupper's arthroplasty. PPx head fractures are contraindicated in VPA,³ which will fail without an intact PPx head to support it.

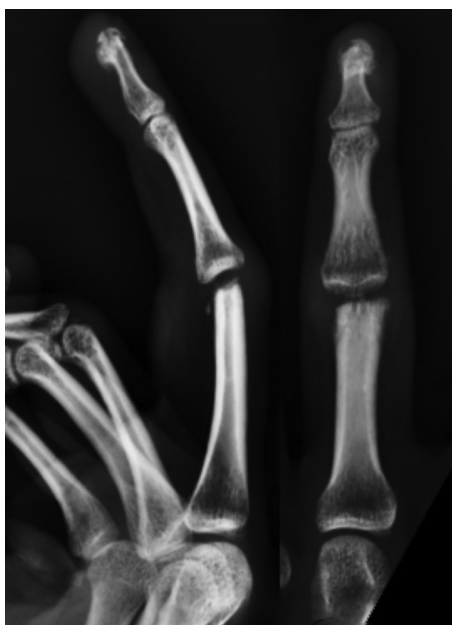

Fig. 3 Check radiographs revealed the neck cut in the proximal phalanx to be sloping ulnar wards.




Fig. 4 Clinical outcomes after 3 years.

The structure of volar plate, described as having a distal fibrocartilaginous portion and a proximal membranous portion,⁸ is ideal to recreate the shape of the head of PPx. The distal portion provides the appropriate tissue for the joint surface because of the tenosynovium lining the volar aspect of the plate, and a fibrocartilaginous core that provides the sturdiness; while the proximal membranous portion allowed mobilization of the volar plate.

The success of this procedure relies on several important factors. First, the volar plate should be uninjured, and precautions should be taken to ensure the distal and proximal ends of the volar plate are intact. Second, the radial and ulnar edges of the distal PPx should be at the same level. Unequal ends may result in deviation of the finger. Third, collateral ligament integrity should be ascertained, just as in Tupper's arthroplasty, which is crucial for stability of the joint. Stability

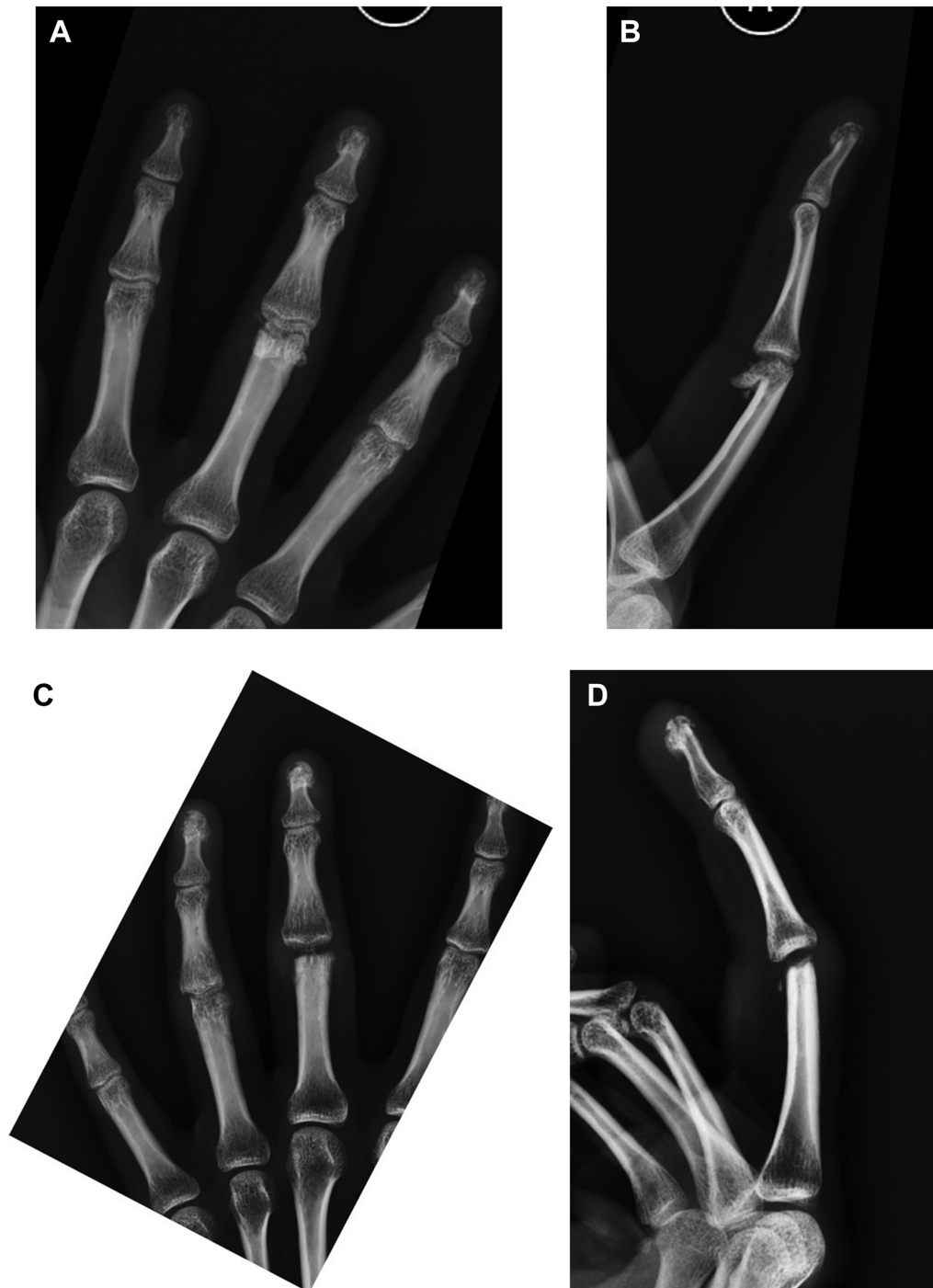


Fig. 5 (A) Preoperative Xray AP view. (B) Preoperative xray lateral view. (C) Post operative follow-up xray AP view. (D) Post operative follow-Up xray lateral view.

and range of movement of the joint can be assessed intra-operatively by doing a squeeze test, as was done in our case.

Conclusion

This procedure converts the joint stability system from that of a combined bony and ligamentous support system to a soft tissue-centered support system. Follow-up of more cases will establish this as a probable standard of treatment for London type III PPx head fractures. Three-year follow-up of this patient (► **Fig. 4**) has given us a strong belief that this procedure can provide an excellent ROM and a functional finger, without pain, when there is severe articular comminution that cannot be managed by the current modes of treatment.

Patients' Consent

Written informed consent was obtained from all subjects before the study.

Funding

None.

Conflict of Interest

None declared.

References

- 1 Eaton RG, Malerich MM. Volar plate arthroplasty of the proximal interphalangeal joint: a review of ten years' experience. *J Hand Surg Am* 1980;5(03):260–268
- 2 Adams JE. PIP Joint Fracture Dislocations: A Clinical Casebook. Springer Nature 2016. Doi: 10.1007/978-3-319-28579-5
- 3 Tan RES, Cheah AEJ. Injuries around the proximal interphalangeal joint. *Clin Plast Surg* 2019;46(03):437–449
- 4 Meena D. Functional evaluation of volar plate advancement arthroplasty in fracture dislocation of proximal interphalangeal joint. *J Orthoped Traumatol Rehabil* 2018;10(01):13
- 5 London PS. Sprains and fractures involving the interphalangeal joints. *Hand* 1971;3(02):155–158
- 6 Ng CY, Oliver CW. Fractures of the proximal interphalangeal joints of the fingers. *J Bone Joint Surg Br* 2009;91(06):705–712
- 7 Domalain M, Evans PJ, Seitz WH Jr, Li Z-M. Influence of index finger proximal interphalangeal joint arthrodesis on precision pinch kinematics. *J Hand Surg Am* 2011;36(12):1944–1949
- 8 Williams EH, McCarthy E, Bickel KD. The histologic anatomy of the volar plate. *J Hand Surg Am* 1998;23(05):805–810