



Spontaneous Chest Wall Hernias: Intercostal Lung Hernia and Inverted Intercostal Hernia

Aybuke Ucgun¹  Esin Kurtulus Ozturk¹  Saffet Ozturk¹ 

¹ Department of Radiology, Ankara Etlik City Hospital, Ankara, Türkiye

Address for correspondence Esin Kurtulus Ozturk, MD, Department of Radiology, Ankara Etlik City Hospital, Ankara 06170, Türkiye (e-mail: e.kurtulus@hotmail.com).

Indian J Radiol Imaging

Abstract

Intercostal lung hernia and inverted intercostal hernia are rare chest wall hernias usually asymptomatic and detected incidentally on chest radiograph. In this case report, we discussed here on the chest radiograph and computed tomography imaging findings of two cases of these rare hernias with an emphasis being in differential diagnosis of chest tumors.

Keywords

- ▶ chest wall
- ▶ intercostal lung hernia
- ▶ inverted intercostal hernia
- ▶ spontaneous

Introduction

Chest wall hernias are characterized by thoracic contents protrusion outside their normal anatomical sites or extension of the soft tissue within the thoracic cavity through a defect of the chest wall. It can be congenital, spontaneous, or more commonly secondary to trauma or thoracic surgery.¹ Spontaneous intercostal lung hernia is defined as the protrusion of the lung parenchyma and pleura through a defect of thoracic wall without any trauma or pathologic condition.^{2,3} However, if the direction of the herniation changes, that is, the subcutaneous tissue protrudes through the intercostal space inwards the thoracic cavity, it is defined as inverted intercostal hernia.⁴ Intercostal hernias are better detected with chest computed tomography (CT) due to its high resolution and multiplanar imaging. Radiologists should be aware of the imaging findings of chest wall hernias to avoid confusion with pathological conditions included in the differential diagnosis, such as tumor.^{1,4,5} Herein, we aimed to present two rare chest wall hernia cases of spontaneous intercostal lung hernia and spontaneous inverted intercostal hernia (▶ **Fig. 1**), describing the radiographic and CT findings.

Case 1: A 64 year-old man who was an ex-smoker (20-pack-year history), with a body mass index of 30, was

admitted to the emergency department with fever, cough, and chest pain that had developed suddenly for the last 1 week. The patient had no history of previous trauma or thoracic surgery. In his physical examination, a soft but fixed mass lesion was palpated from the left sixth intercostal space anterolateral to the subcutaneous tissue during inspiration. Radiolucent, well-delineated area in the middle zone of the left hemithorax and adjacently ground-glass densities were detected in posteroanterior (PA) chest radiograph (▶ **Fig. 2A**). On chest CT, subcutaneous herniation of the pulmonary parenchyma was detected from the fourth intercostal space in the anterolateral side of the left hemithorax. Also, consolidation with ground-glass opacities was in favor of pneumonic infiltration (▶ **Fig. 2B**). It was reported as a spontaneous intercostal lung hernia. The nasopharyngeal aspirate result was compatible with coronavirus disease 2019 pneumonia. Drug treatment for the infection was administered and the patient was discharged after 2 weeks. At the 3-month outpatient follow-up, he clinically recovered well, without any respiratory symptoms. He refused surgery and it was decided to provide conservative treatment with planned chest CT follow-up in case of any respiratory complaints.

DOI <https://doi.org/10.1055/s-0044-1787840>.
ISSN 0971-3026.

© 2024. Indian Radiological Association. All rights reserved.
This is an open access article published by Thieme under the terms of the Creative Commons Attribution-NonDerivative-NonCommercial-License, permitting copying and reproduction so long as the original work is given appropriate credit. Contents may not be used for commercial purposes, or adapted, remixed, transformed or built upon. (<https://creativecommons.org/licenses/by-nc-nd/4.0/>)
Thieme Medical and Scientific Publishers Pvt. Ltd., A-12, 2nd Floor, Sector 2, Noida-201301 UP, India

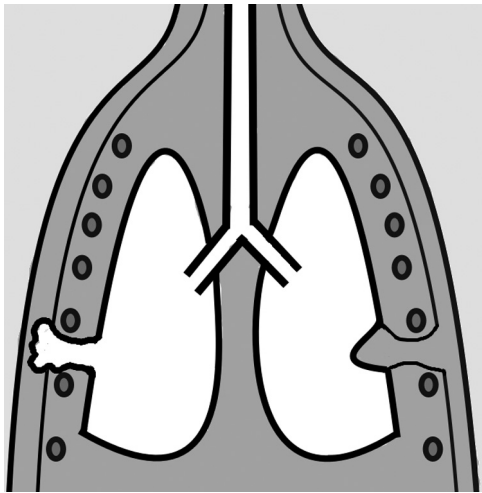


Fig. 1 Schematic diagram of intercostal lung hernia (right hemithorax) and inverted intercostal hernia (left hemithorax).

Case 2: A 73-year-old male patient with a history of smoking 22 packs a year was admitted with long-standing complaints of intermittent cough and chest pain. There was no history of trauma or thoracic surgery. An opacity was detected in the middle zone of the right hemithorax in PA chest radiograph (► **Fig. 3A**). On CT, herniation of the chest wall soft tissue with fat density in the anterolateral side of the right hemithorax from the fourth intercostal space to the intrathoracic area was detected (► **Fig. 3B**). The hernia was causing mild compression in the soft tissue lung parenchyma. It was reported as a spontaneous inverted intercostal lung hernia. As a result of lung function tests and imaging, it was determined that the patient had mild emphysema and his breathing was relieved with a bronchodilator. Treatment options and possible complications of inverted intercostal hernia were explained and the patient refused to undergo surgery. It was learned that the patient had no complaints such as pain or respiratory symptoms during the 6-month clinical follow-up.

Discussion

Spontaneous intercostal lung hernias usually develop as a result of a sudden increase in intrathoracic pressure. It may occur due to reasons such as intense coughing, sneezing, blowing a musical instrument, or heavy lifting, as well as local weaknesses in the chest wall resulting in rib or cartilage fracture.^{6,7} Associated comorbidities are mainly central obesity, male gender, smoking history, chronic obstructive pulmonary disease, and steroid use. The mechanism underlying the development of the lung herniation has been described as being triggered by increased intrathoracic pressures and chest wall forces due to severe coughing or straining. It is thought that herniation occurs mostly in the middle third of the rib and is the result of shear forces in opposite directions from the serratus anterior and external oblique muscles.^{8,9} The Morel-Lavallée classification is used to classify lung hernias into subtypes based on their anatomic location (cervical, thoracic, diaphragmatic, and mediastinal) and etiology (congenital, acquired).⁶ In the medium to long term, potential complications of lung herniation range from mild to severe, including chronic pain, exertional dyspnea, atelectasis, hemoptysis, asphyxiation, acute respiratory distress, and systemic inflammatory response.⁸

Inverted intercostal hernia is believed to occur mostly in patients who have undergone chest surgery, especially due to increased muscle tension in the chest wall. Progressive muscle weakness and muscle wasting, structural disorders, and inadequate or impaired closure of the thoracic wall are potential factors that may play a role in the etiology.¹⁰ CT imaging plays an important role in the diagnosis and monitoring of chest wall hernias. As radiation-free and noninvasive alternatives to CT, ultrasonography and magnetic resonance imaging can be considered imaging tools in the assessment of chest wall abnormalities.⁶ There is still no consensus on the conservative or surgical treatment of lung herniation. Surgery can be done immediately or delayed, depending on the clinical

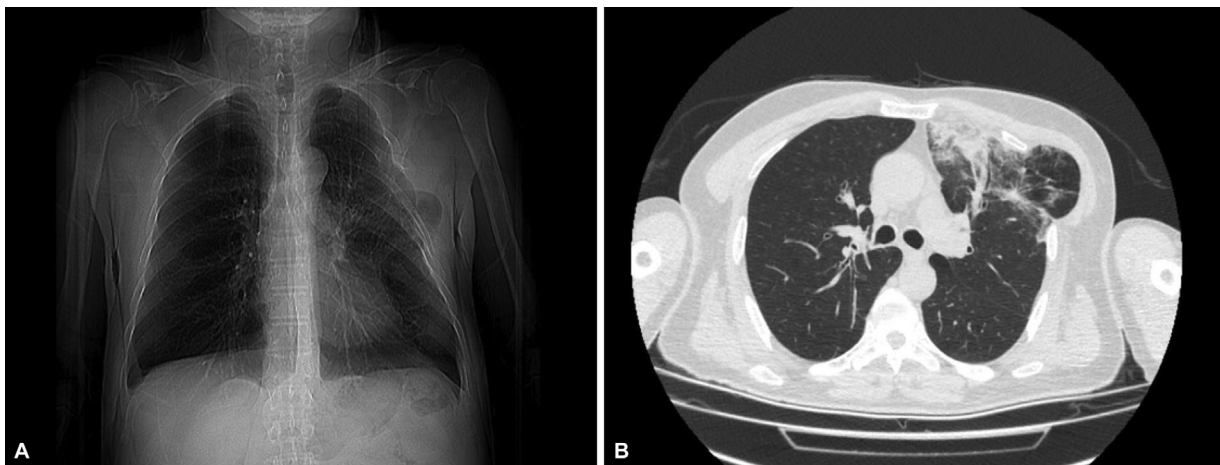


Fig. 2 (A) Chest X-ray posteroanterior (PA) view showing lung margins and radiolucency beyond the rib cage borders in the left midzone of the hemithorax. (B) Noncontrast-enhanced axial computed tomography (CT) image demonstrates the intercostal lung herniation through the fourth intercostal space. Also, consolidation with ground-glass opacities is seen.

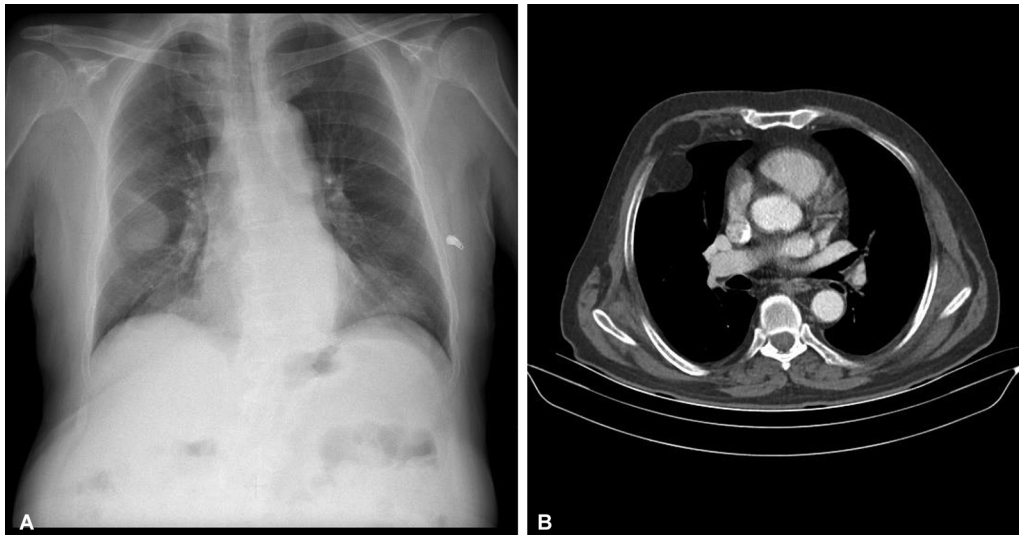


Fig. 3 (A) Chest X-ray posteroanterior (PA) image showing an opacity in the right midzone of the hemithorax. (B) Noncontrast-enhanced axial computed tomography (CT) image shows the inverted soft tissue intercostal herniation through the fourth intercostal space.

condition of the patient and the complications caused by herniation.^{8,11}

Treatment of symptomatic hernias is surgical and is determined by factors such as size of the herniated parenchyma and presence of pain, incarceration or strangulation of lung tissue, and paradoxical respiration with poor ventilation.^{5,11,12}

In conclusion, intercostal lung hernias and inverted intercostal hernias, unusual hernias, may mimic chest wall or lung tumors on direct radiographs and can be a source of misdiagnosis. Advanced imaging techniques play an important role in the diagnosis and management of these abnormalities, accurately identifying type, location, contents, and associated complications of the hernia.

Conflict of Interest

None declared.

References

- 1 Chaturvedi A, Rajiah P, Croake A, Saboo S, Chaturvedi A. Imaging of thoracic hernias: types and complications. *Insights Imaging* 2018; 9(06):989–1005
- 2 Maeda T, Sato R, Luthe SK, Russell MC. Spontaneous intercostal lung hernia. *Am J Med* 2017;130(09):e399–e400
- 3 Seder CW, Allen MS, Nichols FC, et al. Primary and prosthetic repair of acquired chest wall hernias: a 20-year experience. *Ann Thorac Surg* 2014;98(02):484–489
- 4 Iwata T, Yasuoka T, Hanada S, et al. Inverted intercostal hernia of soft tissue manifested as slow-growing chest wall tumor after thoracotomy. *Ann Thorac Surg* 2010;90(04):1355–1357
- 5 Peixoto MSBC, Moreira BL, Santana PRP, Ferreira AR, Terra RM. Postoperative inverted intercostal hernia incidentally detected by chest computed tomography in a patient with COVID-19. *Radiol Case Rep* 2022;17(09):3336–3338
- 6 Detorakis EE, Androulidakis E. Intercostal lung herniation—the role of imaging. *J Radiol Case Rep* 2014;8(04):16–24
- 7 O’Shea M, Cleasby M. Images in clinical medicine. Lung herniation after cough-induced rupture of intercostal muscle. *N Engl J Med* 2012;366(01):74
- 8 Ugolini S, Abdelghafar M, Vokkri E, et al. Case report: spontaneous lung intercostal hernia series and literature review. *Front Surg* 2023;9:1091727
- 9 Brock MV, Heitmiller RF. Spontaneous anterior thoracic lung hernias. *J Thorac Cardiovasc Surg* 2000;119(05):1046–1047
- 10 Weissberg D, Refaely Y. Hernia of the lung. *Ann Thorac Surg* 2002; 74(06):1963–1966
- 11 de Wijs MJ, Verhagen AF, Tan E. Post-traumatic lung herniation [in Dutch]. *Ned Tijdschr Geneesk* 2012;156(39):A4863
- 12 Bhalla M, Leitman BS, Forcade C, Stern E, Naidich DP, McCauley DI. Lung hernia: radiographic features. *AJR Am J Roentgenol* 1990; 154(01):51–53