




Spinal Neuronavigation for Lumbar Plate Fixation in Miniature Breed Dogs

Angela Papacella-Beugger¹ Franck Forterre²  Eva Samer³  Julien Guevar³  Andrea Müller¹
Bastien Planchamp² Alexia Progin³ Daniela Schweizer¹ 

¹Division of Clinical Radiology, Vetsuisse Faculty, University of Bern, Switzerland

²Division of Surgery, Vetsuisse Faculty, University of Bern, Switzerland

³Division of Clinical Neurology, Vetsuisse Faculty, University of Bern, Switzerland

Address for correspondence Daniela Schweizer, Prof. Dr. med. vet., Division of Clinical Radiology, Vetsuisse Faculty, University of Bern, Switzerland (e-mail: daniela.schweizer@unibe.ch).

Vet Comp Orthop Traumatol

Abstract

Objective The main aim of this pilot study was to assess the feasibility of spinal neuronavigation for plate fixation of lumbar vertebrae in miniature breed dogs using a surgical navigation system in combination with a custom-made reference array.

Study Design This was an experimental cadaveric study in five miniature breed dogs.

Methods A 4-hole locking plate with four 2.0-mm locking screws was placed on two adjacent lumbar vertebrae using a neuronavigation system consisting of a mobile cone beam computed tomography linked to a navigation system. The procedure was performed by a novice surgeon. The plate and screw positions were assessed for surgical safety using predefined criteria. Surgical accuracy was determined by the deviation of entry and exit points between pre- and postoperative images.

Results A total of five plates and 20 screws were placed. In 85% (17/20), screws were placed appropriately. The median entry point deviation was 1.8 mm (range: 0.3–3.7) and the median exit point deviation was 1.6 mm (range: 0.6–5).

Conclusion Achievement of surgical accuracy in the placement of screws for fixation of lumbar vertebral plates in small breed dogs using neuronavigation with a custom-made reference array by a novice surgeon resulted in surgical safe plate placement in four of the five cadavers. Therefore, we judge the method as promising, however, further studies are necessary to allow the transfer of image-guided navigation for lumbar plate fixation into the clinic.

Keywords

- ▶ canine
- ▶ neuronavigation
- ▶ lumbar
- ▶ stealth station

Introduction

Spinal trauma is a common cause of acute spinal cord injury in dogs and includes vertebral fracture, luxation, subluxation, or traumatic disc extrusion. Vertebral fracture and luxation in dogs and cats are most frequently seen in the thoracolumbar spine, followed by the lumbar spine.^{1,2} Radiographs have only a moderate sensitivity to diagnose fractures and subluxations.³ Therefore, computed tomography (CT) is the gold standard in veterinary medicine for diagnosing bone

lesions in spinal trauma patients.^{3,4} Treatment options are grossly divided into conservative and surgical therapies. Therapy depends on factors such as initial neurological status and general condition, type of injury, clinician's preference, and financial situation of the owner.^{5,6} Surgical therapy is usually recommended for decompression of the spinal cord and unstable spinal column injuries.^{5,7,8}

The unstable spinal column can be stabilized with either a dorsal fixation of the dorsal spinous process with plastic or metal plates, with multiple Steinmann pins, with or without

received

January 6, 2023

accepted after revision

May 21, 2024

© 2024. Thieme. All rights reserved.

Georg Thieme Verlag KG,

Rüdigerstraße 14,

70469 Stuttgart, Germany

DOI <https://doi.org/>

10.1055/s-0044-1787707.

ISSN 0932-0814.

polymethylmethacrylate with pedicle screws and rods or vertebral body plating.^{9–13} Each technique has biomechanical advantages and disadvantages, and the choice depends on the surgeon's preference.^{14–19} In general, an insertion angle of at least 60 degrees to the sagittal plane of the vertebral body for screws and pins in the lumbar region is considered to be safe to avoid neurovascular structures.²⁰ In small and miniature breed dogs, there is a higher risk of misplacement and mispositioning of pins or screws resulting in injury to neurovascular structures.^{21,22} In human patients, similar challenges can be overcome with the help of image-guided neuronavigation, which offers greater safety and accuracy in spinal surgery.^{23,24} Advantages of neuronavigation include not only higher precision of surgery and shorter surgery time,^{23,25,26} but also less radiation exposure compared to intraoperative fluoroscopy.²⁷ In veterinary medicine, publications on the use of neuronavigation are scarce and include brain biopsy procedures^{28–30} and minimally invasive spinal surgery applications in dogs.³¹

The objectives of this pilot study are to assess the feasibility, accuracy, and safety of spinal neuronavigation for plate fixation of lumbar vertebrae in miniature breed dogs performed by a novice surgeon.

Materials and Methods

Specimens and Preparation

Five miniature dogs (Chihuahuas [two male and two female] and a Yorkshire terrier [one male]) euthanized for reasons unrelated to this study and without a history of vertebral column pathology were included in this *ex vivo* study. The five skeletally mature cadavers had a median body weight of 1.38 kg (range: 1.17–1.7). All owners signed an informed consent form, permitting the use of tissues and images for

teaching and research purposes. The study was in accordance with local ethical regulations.

The cadavers were frozen at -20°C and then thawed at room temperature over 24 to 48 hours.

Cadavers were positioned in sternal recumbency on a carbon fibre table with slight axial rotation such that the dorsal aspect of the cadaver was rotated away from the surgeon by approximately 30 degrees. Dogs were held in position using a vacuum cushion, medical pads, and adhesive tape. The left lumbar region was clipped and a standard dorsolateral surgical approach with retraction of the epaxial musculature was performed on the left side to expose the dorsolateral surfaces of the vertebrae from L2 to L5.³²

Navigation Procedure

Conventional human reference arrays are not intended for small animals and are poorly adapted for miniature breeds. A custom-made solution was therefore designed. The original reference array (Reference array, StealthStation S7, Medtronic, Inc., Littleton, MA) was first measured manually and then simulated with planning software (Autodesk Fusion 360, Inc., CA). A 3D printer (Prusa i3 MK2, Prusa Research, Praha, Czech Republic) produced a tracker made of polylactide. Differently shaped adapters for fixation of the tracker at the dorsal spinous processes were designed and 3D printed using polylactide, see **► Fig. 1**.³³ The resulting printed reference array weighed 12 g compared to 59 g of the original reference array. The reference array was attached to the adapters by press fit and the adapters were fixed with three 1.25-mm Kirschner wires (Kirschner wire with trocar tip, Synthes) to the spinous process. This resulted in a rigid fixation of the reference array to the spinous process (**► Fig. 2**).

The cadaver was placed on a radiolucent carbon fibre table and centered in the middle of the O-arm (O-Arm, Medtronic,




Fig. 1 Comparison of the original and custom-made patient tracker. The bulky patient tracker from human medicine (A) is too heavy and big for fixation at the dorsal spinous process of miniature breed dogs. Therefore, a custom-made 3D-printed reference array (B) was connected via an adapter (1) for fixation to the spinous process. The reflective spheres (2) can be attached (3) to both reference arrays.

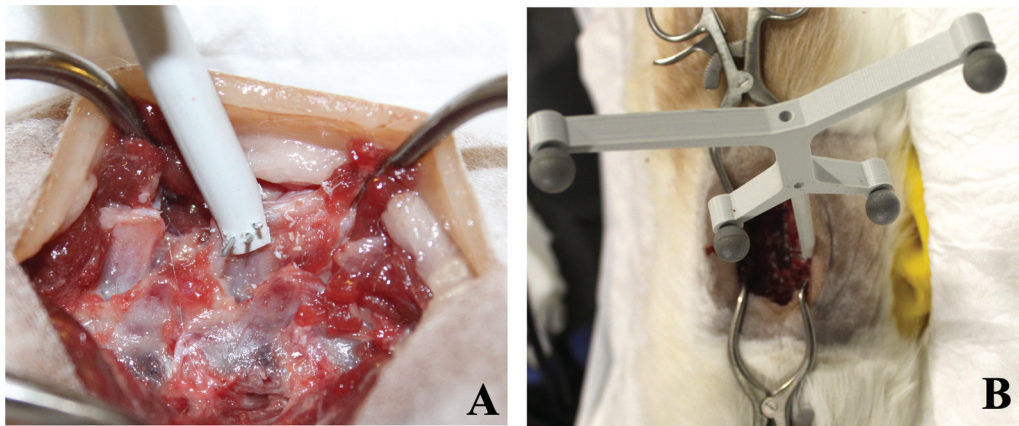


Fig. 2 During surgery, the adapter (A) was fixated to the spinous process with three Kirschner wires inserted perpendicular through the spinous process. The reference array (B) is then connected to the adapter.

Inc., Littleton, MA), which is a mobile cone beam computed tomography (CBCT) of the navigation system. It also has fluoroscopy capability, which is used to confirm adequate positioning of the region of interest before 3D volumetric data are acquired. The patient tracker, fitted with reflective beads (fiducials) had been attached to the patient spinous process.

The infrared camera (Infrared Camera, StealthStation S7, Medtronic, Inc., Littleton, MA) with two lenses for geometric triangulation was positioned so that the reflective markers of

the patient tracker and the infrared light-emitting tracker of the CBCT were simultaneously detected by the camera during scanning, see ►**Fig. 3**. As described in Guevar and colleagues, the system, therefore, calculates the distance between the patient tracker and the CT data.³¹ To perform the navigation, a pointer device or another tracker device fitted with more fiducials is brought into the visual field of the infrared camera and the distance between the tracker and the CT data is automatically calculated following a calibration step. From




Fig. 3 During neuronavigation, the gantry of the mobile cone beam computed tomography (CBCT) (A) is positioned around the patient. The software of the navigation system (C) can match the acquired images with the patient's anatomy if the infrared camera (B) is positioned in front of the patient tracker (D) and the indicator box of the CBCT (E) during scanning. CBCT, cone beam computed tomography.

there, the O-arm can be removed from the operation suite and the surgeon navigates in real-time. The calibration step allows the system to know the exact distance between the tip of the instrument being used and the fiducials on the tracker attached to it. Throughout the procedure, the surgeon needs to be aware of three important aspects. First, the surgeon should not stand in the way of the trajectory between the infrared camera, the navigated instruments, and the patient tracker. Second, the surgeon should make sure that there is a correct correlation between the patient and what is seen on the screen before and during the procedure. This is done by positioning the navigated pointer (Blunt Tip Pointer, Medtronic, Inc., Littleton, MA) on different bony landmarks in the three-orientation axis. Third, the patient tracker should never be displaced or touched during the procedure as it would lead to inaccurate navigation. Volume acquisition by the CBCT results in image reconstruction of a cylindrical volume of 21 cm in diameter and 16 cm in height with an acquisition matrix of 512×512 , a spatial resolution of $0.415 \times 0.415 \times 0.833$ mm, and a pixel pitch of 0.194 mm.

Surgical Procedure

Two adjacent vertebral bodies excluding the thoracolumbar and lumbosacral junction were randomly selected by the preference of the novice surgeon for later plate osteosynthesis with a 4-hole plate (Nonlocking 2.0 mm plate, Zrinski, D.O.O, Malinska, Croatia; ►Fig. 4). Osteotomy of the left transverse processes was performed using a burr. The surgical procedure of a 4-hole plate fixation of two lumbar vertebrae was performed by a novice surgeon without prior neurosurgery experience. Since the surgeon was right-handed, the plate was always applied to the left side.

Using the neuronavigation system planning function, the screw trajectories were planned on multiplanar and volume-rendered reconstructions, all displayed on one screen to plan

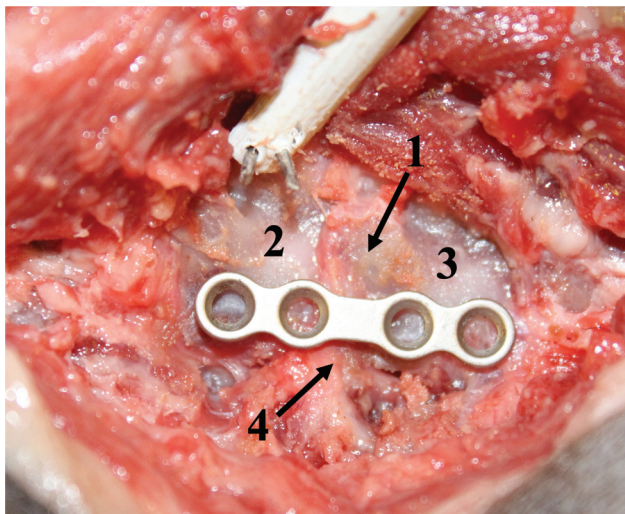


Fig. 4 The position of the plate was planned so that the dorsal margin of the plate was ventral to the neuroforamina (1), two plate holes were positioned on the cranial of the two vertebral bodies (2), and two plate holes were positioned on the caudal vertebral body (3), and no hole was overlying the intervertebral disc space (4).

two bicortical screws in each adjacent vertebra. For each trajectory, an entry point (cis cortex) and exit point (trans cortex) for the vertebra were defined by the surgeon. After planning the most cranial screw trajectory, a surgical drill (Colibri, Synthes, GmbH, Oberdorf, Switzerland) instrumented with a small tracker (SureTrak 2 Silver Passive, Medtronic, Inc., Littleton, MA) on the instrument shaft was used to drill each trajectory without a drill sleeve into the vertebrae following the onscreen plan.

This allows for real-time visual feedback on the screen during drilling. Then, a 2.0-mm nonlocking screw (2.0 mm non-locking screws, Zrinski, D.O.O, Malinska, Croatia) with a length of 12 mm was placed within the most cranial plate hole. According to the position of the plate hole, the entry point of the most caudal screw (screw 4) was determined, its trajectory was planned, the corridor was drilled using navigation, and the screw was inserted. The procedure was repeated for the second and third plate holes (screws 2 and 3).

Postoperative Assessment of Surgical Safety

After plate fixation, postoperative CBCT scans of the spine were acquired to evaluate the position of screws and plate concerning surgical safety. The images were assessed by a board-certified surgeon (F.F.) and board-certified radiologist (D.S.) based on six surgical safety criteria. Surgical safety was defined if no nervous structures were injured. Each criterion was assessed as “perfect,” if there was no room for improvement, “sufficient” if there was room for improvement but no nervous structures were injured, and “insufficient” if vital structures had been injured. If at least one of the six criteria was graded as “insufficient”, the corridor was graded as “poor.” If one of the six criteria was evaluated as “sufficient,” the corridor was graded as “acceptable,” see ►Appendix Table A1 (available in the online version).

Postoperative Assessment of Surgical Accuracy

For comparison of planned trajectories with the actual drill corridors, 3D coordinates of the entry and exit points were compared. Because the navigation software does not provide 3D coordinates nor allows for export of data according to DICOM standard (digital imaging and communication in medicine, www.dicomstandard.org), first, screenshots of the planned trajectories in the dorsal, sagittal, and transverse planes were exported from the navigation system and imported into imaging software (Horos, Project Horos, Annapolis, MD) as previously described.^{26,34}

To compare the coordinates of the planned trajectories with the ones of the actual drill corridors, postoperative CT images were acquired after the removal of all implants. Pre- and postoperative CT images were fused as previously described³⁴ and the 3D coordinates of all entry and exit points of all screw corridors were extracted (►Fig. 5). The difference between the coordinates of the entry and exit points of the planned trajectories and from the drilled corridors were calculated using the Euclidean distance formula ($d = \sqrt{(x_2 - x_1)^2 + (y_2 - y_1)^2 + (z_2 - z_1)^2}$) and expressed as entry and exit point deviation.

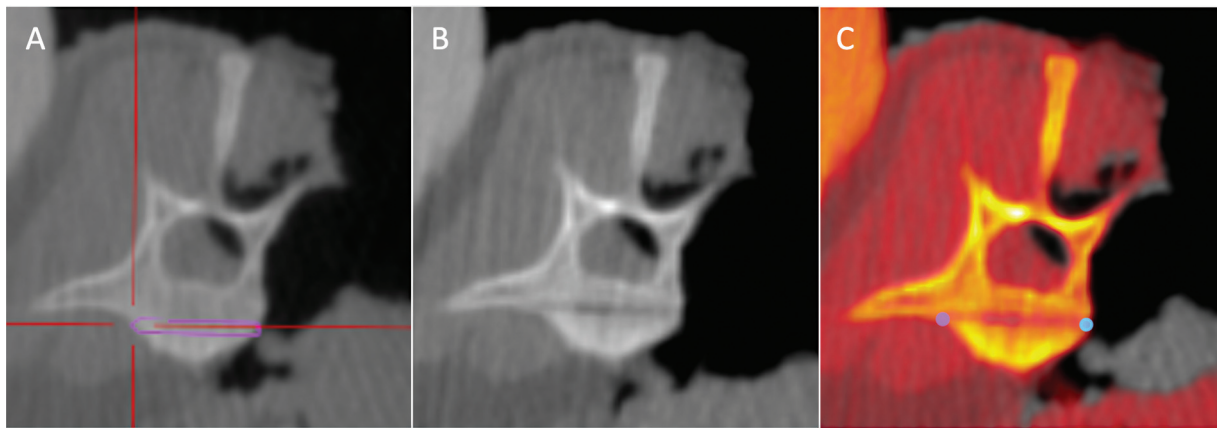


Fig. 5 Transverse reconstruction of the intraoperative CT showing the lumbar vertebra with the planned trajectory (A, pink corridor). Postsurgical CT images after removal of the screw with the drilled screw corridor visible as a hypoattenuating line through the vertebral body (B). Fusion image of the intraoperative CT image (in grey values) and postoperative CT image (orange overlay) showing the entry point in blue and exit point in pink of the planned trajectory (C).

Statistical Analysis

A power analysis was not performed to estimate the appropriate sample size required as we were not comparing technique accuracy between two operators or comparing different techniques. The Shapiro–Wilk test was used to establish the samples (entry and exit point deviations) distribution. Examination of the distribution of the deviation data revealed a normal distribution for the entry point deviations but a deviation from normal distribution for the exit point deviations. A Wilcoxon signed-rank test was used to compare the entry and exit point deviations. The level of significance was set to $p \leq 0.05$. All tests were conducted using MedCalc®v22.019.

Results

Feasibility

The use of the original O-arm navigation tracker resulted in bending/fracture of the spinous process and was inadequate for miniature dogs. The use of a custom-made 3D-printed tracker was adequately recognized by the navigation system and the navigation procedure was successfully performed in all five dogs. In one dog, the plate was placed on L2–L3, and in two dogs each, the plate was placed on vertebrae L3–L4 and L4–L5.

Accuracy

The deviations of 20 entry points and 20 exit points between the planning and postoperative imaging were evaluated, see ► **Appendix Table A2** (available in online version only). The median entry point deviation was 1.8 mm (range: 0.3–3.7) and median exit point deviation was 1.6 mm (range: 0.6–5). No significant difference was found between the entry and exit point deviations (p -value = 0.8126; ► **Appendix Table A2** and ► **Appendix Fig. A1** [available in online version only]).

Safety

The position of four out of five plates was adequate; one plate was inadequately positioned being too dorsal and not aligned parallel to the vertebral canal. Sixteen of 20 screws were

assessed as well positioned, 1/20 as acceptable, and 3/20 as poor. This resulted in 85% of screws being acceptably or well-positioned. Three screws were assessed as poorly positioned as they penetrated the spinal canal. All poorly positioned screws were placed in cadaver 2, with the second screw too far dorsally positioned resulting in a plate in too dorsal position impairing the neuroforamina.

Discussion

In this study, a commercially available neuronavigation system in combination with a custom-made 3D-printed tracker was successfully used to plan screw trajectories and to subsequently insert screws for lumbar plate fixation in miniature dog cadavers. Using this combination, most screws were well-positioned and neuronavigation could successfully be used for accurate and safe stabilization of the lumbar spine using four screws and one plate by a novice surgeon.

The safety of the procedure in cadavers of dogs is paramount prior to its translation to client-owned dogs. In this study, it was found that four of the five plates were well-positioned and 85% of the 20 screws did not affect vital structures. All three poorly positioned screws occurred in the second cadaver following poor handling of the drill by the novice surgeon, resulting in a too-dorsal position of one screw and consequently an inadequately placed plate. This plate was evaluated as surgically unsafe, since the plate was positioned too dorsal on the vertebral bodies and therefore compromised the spinal nerves exiting the neuroforamina. Unlike inserting pins or single screws, one difficulty of navigated plate fixation is that the entry point of each screw is given by the corresponding plate hole and if one screw is misplaced, the following ones will likely be misplaced, too. This is also true for non-navigated surgeries and more experience with navigated neurosurgery will show, if image-guide navigation will reduce such errors compared to nonimage-guided surgeries. The learning curve of such a system is also well-documented in human surgery. Indeed,

trainees using navigation may have a better understanding of the procedure and learn standard techniques with a shorter learning curve, probably due to the immediate feedback of navigation systems.²⁵

Accuracy during spinal surgery is especially important for smaller patients. In this context, there is no doubt that neuronavigation can help veterinary neurosurgeons as well. Surgical accuracy is one of the most important quality measurements for a neuronavigation system. In the present study, the overall deviations of the system for both entry and exit points were below 2 mm. This is similar to the manufacturer's specifications, referencing the imaging system combined with the navigation system allows for an accuracy of ≤ 2 mm. When the system was used in a clinical setting in humans, the surgical accuracy for screw placement in unstable pelvic ring fractures resulted in an exit point deviation of 2.5 ± 0.9 mm for 18 screws.²⁶ Comparing the entry and exit point deviations of the current study to a previously performed spinal navigation study, the difference between entry point deviations was small (1.9 mm of the current study to 2.208 mm of the previous study), however the exit point deviation of the current study was smaller (1.6 mm) compared to the previous study (3.003 mm). This difference between the exit point deviations between the current study and the study from Guevar and colleagues may be due to wider vertebral bodies and longer trajectories or influenced by the fact that the procedure in the latter was minimally invasive.³¹ However, despite the navigation system being identical, the techniques differed, and comparison conclusions may not be valid.

Limitations of the study include the low number of dogs, the stabilization of different lumbar vertebrae, the possible operator error in performing the comparisons between planned and surgery trajectories, performing stabilization on intact spines, and integrity of the anatomical structures were only examined by postoperative scans. First, the miniature breed dog cadavers represent a unique population, and their availability is limited. Second, it is possible that not using identical vertebrae might affect the results. However, these anatomical variations represent the reality in clinical settings. Third, to compare the coordinates of plans and results and calculate the accuracy of screw placement, screenshots of the surgical plans needed to be exported and manually merged with the postoperative CT images as suggested by Takeba and colleagues.²⁶ This method is time-consuming and intra- and interexaminer differences might occur. Software that enables the automated comparison of navigation plans and postoperative images needs to be developed. Samer and colleagues, however demonstrated that intraclass correlation coefficients were adequate using this method.³⁴ Fourth, the use of intact spine is an important first step before it is used in clinically affected patients. Further studies would be needed to see if the system's accuracy and safety differ in traumatized spines. As fifth limitation, one could argue that a dissection of the spine can provide even more accurate evidence of the integrity of vital anatomical structures than a postoperative CT scan alone.

Conclusion

In this cadaver study, we showed that spinal neuronavigation using a commercially available navigation system with a custom-made patient tracker is feasible for lumbar plate fixation. We showed that the method can be performed in a particularly challenging setting choosing miniature breed dogs and a novice surgeon. Despite this, the median surgical accuracy was ≤ 2 mm. We therefore assume that with proper surgical training results would be superior to those published here. Therefore, we judge the method as promising, however, further specific studies are necessary to allow the transfer of image-guided navigation for lumbar plate fixation or pedicle screw fixation into the clinic.

Authors' contribution

A.P.-B., F.F., E.S., J.G., B.P., A.P. and D.S. contributed to the conception, study design, acquisition of data, data analysis and interpretation. All authors drafted, revised, and approved the submitted manuscript and are publicly responsible for the relevant content.

Conflict of Interest

None declared.

Acknowledgment

The authors would like to thank Davide Papacella, Suzanne Petit, and Christoph Tschantré for their technical support.

References

- 1 Bali MS, Lang J, Jaggy A, Spreng D, Doherr MG, Forterre F. Comparative study of vertebral fractures and luxations in dogs and cats. *Vet Comp Orthop Traumatol* 2009;22(01):47–53
- 2 Bruce CW, Brisson BA, Gyselinck K. Spinal fracture and luxation in dogs and cats: a retrospective evaluation of 95 cases. *Vet Comp Orthop Traumatol* 2008;21(03):280–284
- 3 Kinns J, Mai W, Seiler G, et al. Radiographic sensitivity and negative predictive value for acute canine spinal trauma. *Vet Radiol Ultrasound* 2006;47(06):563–570
- 4 Holmes JF, Mirvis SE, Panacek EA, Hoffman JR, Mower WR, Velmahos GCNEXUS Group. Variability in computed tomography and magnetic resonance imaging in patients with cervical spine injuries. *J Trauma* 2002;53(03):524–529, discussion 530
- 5 Bagley RS. Spinal fracture or luxation. *Vet Clin North Am Small Anim Pract* 2000;30(01):133–153, vi–vii
- 6 Carberry C, Flanders J, Dietze A, Gilmore D, Trotter E. Nonsurgical management of thoracic and lumbar spinal fractures and fracture/luxations in the dog and cat: a review of 17 cases. *J Am Anim Hosp Assoc* 1989;25:43–54
- 7 Matthiesen D. Thoracolumbar spinal fractures/luxations: surgical management. *Compend Contin Educ Vet* 1983;5(10):867–878
- 8 Park EH, White GA, Tieber LM. Mechanisms of injury and emergency care of acute spinal cord injury in dogs and cats. *J Vet Emerg Crit Care (San Antonio)* 2012;22(02):160–178
- 9 Swaim SF. Vertebral body plating for spinal immobilization. *J Am Vet Med Assoc* 1971;158(10):1683–1695
- 10 Blass CE, Seim HB III. Spinal fixation in dogs using Steinmann pins and methylmethacrylate. *Vet Surg* 1984;13(04):203–210
- 11 Dulisch ML, Withrow SJ. The use of plastic plates for fixation of spinal fractures in the dog. *Can Vet J* 1979;20(11):326–332

- 12 Lumb WV, Brasmer TH. Improved spinal plates and hypothermia as adjuncts to spinal surgery. *J Am Vet Med Assoc* 1970;157(03):338–342
- 13 McNulty J, Lenehan T, Maletz L. Modified segmental spinal instrumentation in repair of spinal fractures and luxations in dogs. *Vet Surg* 1986;15(02):143–149
- 14 Garcia JNP, Milthorpe BK, Russell D, Johnson KA. Biomechanical study of canine spinal fracture fixation using pins or bone screws with polymethylmethacrylate. *Vet Surg* 1994;23(05):322–329
- 15 Knell SC, Bürki A, Hurter K, Ferguson SJ, Montavon PM. Biomechanical comparison after in vitro laminar vertebral stabilization and vertebral body plating of the first and second lumbar vertebrae in specimens obtained from canine cadavers. *Am J Vet Res* 2011;72(12):1681–1686
- 16 Krag MH. Biomechanics of thoracolumbar spinal fixation. A review. *Spine* 1991;16(3 Suppl):S84–S99
- 17 Shores A, Nichols C, Koelling HA, Fox WR. Combined Kirschner-Ehmer apparatus and dorsal spinal plate fixation of caudal lumbar fractures in dogs: biomechanical properties. *Am J Vet Res* 1988;49(11):1979–1982
- 18 Sturges BK, Kapatkin AS, Garcia TC, et al. Biomechanical comparison of locking compression plate versus positive profile pins and polymethylmethacrylate for stabilization of the canine lumbar vertebrae. *Vet Surg* 2016;45(03):309–318
- 19 Walter MC, Smith GK, Newton CD. Canine lumbar spinal internal fixation techniques a comparative biomechanical study. *Vet Surg* 1986;15(02):191–198
- 20 Watine S, Cabassu JP, Catheland S, Brochier L, Ivanoff S. Computed tomography study of implantation corridors in canine vertebrae. *J Small Anim Pract* 2006;47(11):651–657
- 21 Gage E. Surgical repair of spinal fractures in small-breed dogs. *Veterinary medicine, small animal clinician. Vet Med Small Anim Clin* 1971;66(11):1095–1101
- 22 Jeffery ND. Vertebral fracture and luxation in small animals. *Vet Clin North Am Small Anim Pract* 2010;40(05):809–828
- 23 Van de Kelft E, Costa F, Van der Planken D, Schils F. A prospective multicenter registry on the accuracy of pedicle screw placement in the thoracic, lumbar, and sacral levels with the use of the O-arm imaging system and StealthStation Navigation. *Spine* 2012;37(25):E1580–E1587
- 24 Yang P, Chen K, Zhang K, Sun J, Yang H, Mao H. Percutaneous short-segment pedicle instrumentation assisted with O-arm navigation in the treatment of thoracolumbar burst fractures. *J Orthop Translat* 2019;21:1–7
- 25 Jenny JY, Picard F. Learning navigation - learning with navigation. A review. *SICOT J* 2017;3:39
- 26 Takeba J, Umakoshi K, Kikuchi S, et al. Accuracy of screw fixation using the O-arm® and StealthStation® navigation system for unstable pelvic ring fractures. *Eur J Orthop Surg Traumatol* 2018;28(03):431–438
- 27 Izadpanah K, Konrad G, Südkamp NP, Oberst M. Computer navigation in balloon kyphoplasty reduces the intraoperative radiation exposure. *Spine* 2009;34(12):1325–1329
- 28 Chen AV, Wininger FA, Frey S, et al. Description and validation of a magnetic resonance imaging-guided stereotactic brain biopsy device in the dog. *Vet Radiol Ultrasound* 2012;53(02):150–156
- 29 Gutmann S, Tästensen C, Böttcher IC, et al. Clinical use of a new frameless optical neuronavigation system for brain biopsies: 10 cases (2013–2020). *J Small Anim Pract* 2022;63(06):468–481
- 30 Meneses F, Maiolini A, Forterre F, Oevermann A, Schweizer-Gorgas D. Feasibility of a frameless brain biopsy system for companion animals using cone-beam CT-based automated registration. *Front Vet Sci* 2022;8:779845
- 31 Guevar J, Samer ES, Precht C, Rathmann JMK, Forterre F. Accuracy and safety of neuronavigation for minimally invasive stabilization in the thoracolumbar spine using polyaxial screws-rod: a canine cadaveric proof of concept. *Vet Comp Orthop Traumatol* 2022;35(06):370–380
- 32 Forterre F, Spreng D, Rytz U, Jaggy A, Schawalder P. Thoracolumbar dorsolateral laminectomy with osteotomy of the spinous process in fourteen dogs. *Vet Surg* 2007;36(05):458–463
- 33 Ramot Y, Haim-Zada M, Domb AJ, Nyska A. Biocompatibility and safety of PLA and its copolymers. *Adv Drug Deliv Rev* 2016;107:153–162
- 34 Samer ES, Forterre F, Rathmann JMK, Stein VM, Precht CM, Guevar J. Accuracy and safety of image-guided freehand pin placement in canine cadaveric vertebrae. *Vet Comp Orthop Traumatol* 2021;34(05):338–345