



# Delayed Rupture from a Pseudoaneurysm after Mechanical Thrombectomy: A Case Report

Yukinori Takase<sup>1,\*</sup> Tatsuya Tanaka<sup>1,2,\*</sup> Hirofumi Goto<sup>3</sup> Nobuaki Momozaki<sup>4</sup> Eiichiro Honda<sup>5</sup>  
Tatsuya Abe<sup>6</sup> Akira Matsuno<sup>2</sup>

<sup>1</sup>Department of Neurosurgery, Kouhoukai Takagi Hospital, Okawa, Japan

<sup>2</sup>Department of Neurosurgery, International University of Health and Welfare Narita Hospital, Narita, Japan

<sup>3</sup>Department of Neurology, Imari Arita Kyoritsu Hospital, Arita, Japan

<sup>4</sup>Department of Neurosurgery, Imari Arita Kyoritsu Hospital, Arita, Japan

<sup>5</sup>Department of Neurosurgery, Shiroishi Kyoritsu Hospital, Shiroishi, Japan

<sup>6</sup>Department of Neurosurgery, Faculty of Medicine, Saga University, Saga, Japan

**Address for correspondence** Tatsuya Tanaka, MD, PhD, Department of Neurosurgery, International University of Health and Welfare Narita Hospital, 852 Hatakeda, Narita City, Chiba 286-0124, Japan (e-mail: s96047@hotmail.com).

Asian J Neurosurg 2024;19:556–562.

## Abstract

Pseudoaneurysm following mechanical thrombectomy (MT) is a rare but possible complication associated with endovascular procedures. This report presents a case of delayed rupture of a pseudoaneurysm after MT with a stent retriever, which was confirmed by open surgery. During hospitalization, an 85-year-old woman had right hemiplegia and aphasia. Magnetic resonance imaging and angiography revealed acute ischemic changes in the left middle cerebral artery because of M2 segment occlusion. MT was performed to address persistent M2 occlusion. Retrieving from distal vessels with the fully deployed Solitaire 4 × 20 mm stent retriever was considered dangerous, we resheathed the stent, but the microcatheter jumped distally. Angiography through microcatheter revealed contrast leakage into the subarachnoid space. The diagnosis was vessel perforation caused by the microcatheter. The lesion was treated with temporary balloon occlusion for 5 minutes using a balloon-guiding catheter, combined with the reversal of heparin anticoagulation by protamine, and a systolic blood pressure reduction to below 120 mm Hg. Anticoagulation was initiated after confirming that postprocedural subarachnoid hemorrhage (SAH) decreased 1 day after the procedure. Fourteen days after the procedure, computed tomography and angiography revealed a massive hematoma with a newly formed small pseudoaneurysm at the site of vessel rupture. Open surgery was performed to close the small artery rupture using a clip. Delayed rupture of the pseudoaneurysm occurred after MT using a stent retriever. If SAH is observed after MT, performing follow-up computed tomography angiography or magnetic resonance angiography is recommended to consider pseudoaneurysm formation.

## Keywords

- ▶ acute ischemic stroke
- ▶ subarachnoid hemorrhage
- ▶ pseudoaneurysm
- ▶ mechanical thrombectomy
- ▶ stent retriever
- ▶ complication
- ▶ vessel perforation

\* These two authors contributed equally to this work.

article published online  
June 7, 2024

DOI <https://doi.org/10.1055/s-0044-1787672>.  
ISSN 2248-9614.

© 2024. Asian Congress of Neurological Surgeons. All rights reserved.

This is an open access article published by Thieme under the terms of the Creative Commons Attribution-NonDerivative-NonCommercial-License, permitting copying and reproduction so long as the original work is given appropriate credit. Contents may not be used for commercial purposes, or adapted, remixed, transformed or built upon. (<https://creativecommons.org/licenses/by-nc-nd/4.0/>)

Thieme Medical and Scientific Publishers Pvt. Ltd., A-12, 2nd Floor, Sector 2, Noida-201301 UP, India

## Introduction

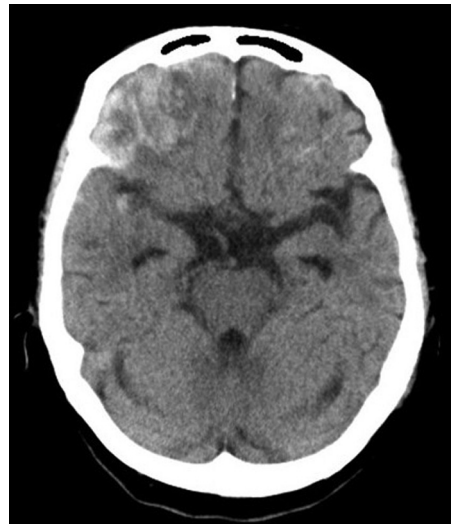
Mechanical thrombectomy (MT) is safe and effective for treating acute ischemic stroke due to large vessel occlusion.<sup>1</sup> However, MT is associated with several procedure-related complications, which include vessel injury, embolization to a different or distant target vessel territory, access site difficulties, use of radiographic contrast, and postprocedural intracranial hemorrhage.<sup>2</sup> Vessel perforation is the most serious bleeding complication associated with vascular injury and can lead to disability or death. It is typically detected on angiography because of contrast extravasation or device protrusion outside the vessel. Pseudoaneurysms associated with endovascular procedures are rare but can occur after MT in cases with vessel injury.<sup>3–7</sup>

In this case report, we present a case of delayed rebleeding from a pseudoaneurysm after MT with a stent retriever confirmed by open surgery.

## Case Description

An 85-year-old woman with a history of hypertension, diabetes mellitus, and atrial fibrillation was transported to the hospital via an ambulance following a traffic-related injury. The patient was not taking any antiplatelet or anticoagulant medications. Head computed tomography (CT) revealed traumatic intracranial hemorrhage (►Fig. 1), and the patient was admitted to the neurosurgery department.

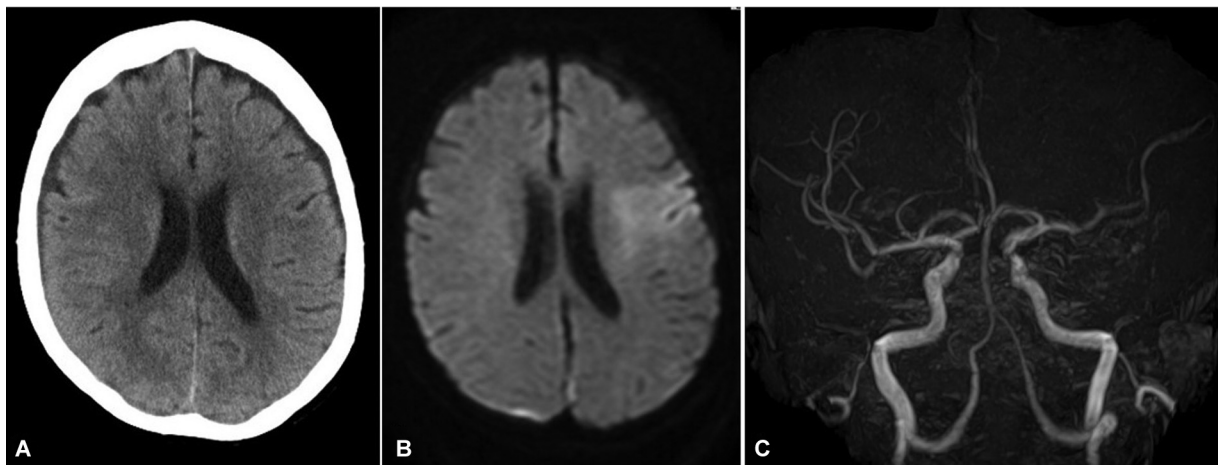
A blood test on day 3 showed an elevated D-dimer level of 4.33 µg/mL. On day 4, 1.5 hours after the final safety assessment, the patient had aphasia and paralysis on her right side. CT revealed no new intracranial hemorrhage or early ischemic findings (►Fig. 2A). Brain magnetic resonance imaging revealed hyperintense areas in the left middle cerebral artery (MCA) region using diffusion-weighted imaging (DWI) (►Fig. 2B). Magnetic resonance angiography (MRA) detected an occlusion in the distal M2 segment of the left MCA (►Fig. 2C), indicating a cardiogenic embolism. A DWI–clinical mismatch was observed, and recanalization therapy was performed.



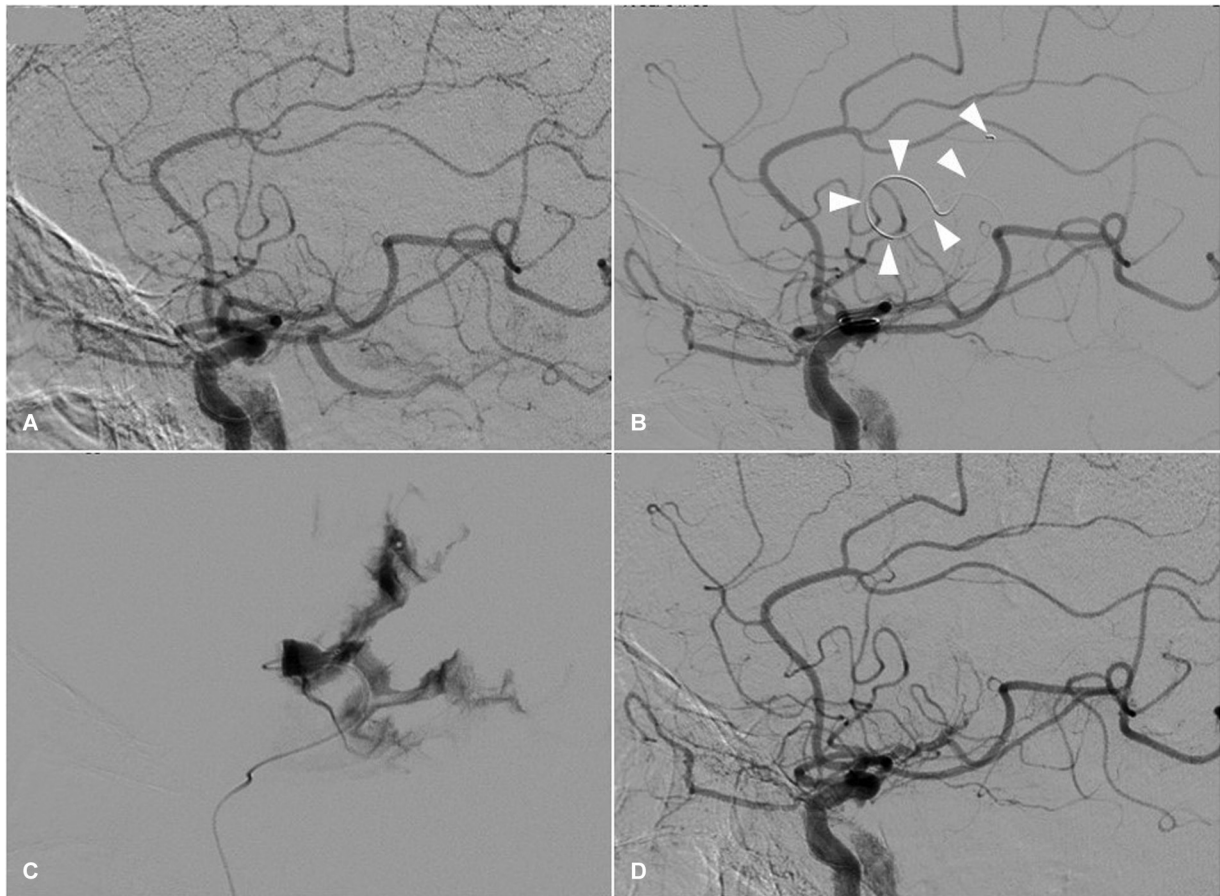
**Fig. 1** Initial head computed tomography after trauma showing bilateral contusions.

## Endovascular Procedure

An endovascular procedure was performed under local anesthesia via femoral access. A 9-French balloon-guiding catheter was placed in the cervical portion of the left internal carotid artery. Initial angiography confirmed occlusion of the M2 segment of the left MCA (►Fig. 3A). The occlusion was crossed using a Marksman microcatheter (Medtronic, Minneapolis, Minnesota, United States) and a CHIKAI microguidewire 0.014 200 cm (Asahi Intec, Aichi, Japan). Angiography through the microcatheter showed the distal artery to be normal, a Solitaire 4 × 20 mm stent retriever (Medtronic) was fully deployed across the occluded lesion. Considering that it would be dangerous to retrieve the stent retrieval device in the distal vessel, we resheathed the stent, but the microcatheter jumped distally (►Fig. 3B). Angiography through the microcatheter revealed contrast leakage into the subarachnoid space (►Fig. 3C). The diagnosis was vessel perforation caused by the microcatheter. We treated the lesion with temporary balloon occlusion for 5 minutes using a balloon guide catheter,



**Fig. 2** (A) Head computed tomography showing no new intracranial hemorrhage or early ischemic findings. (B) Magnetic resonance diffusion-weighted imaging showing acute ischemic change involving the left middle cerebral artery territory. (C) Magnetic resonance angiography showing occlusion of the distal M2 portion of the left middle cerebral artery.



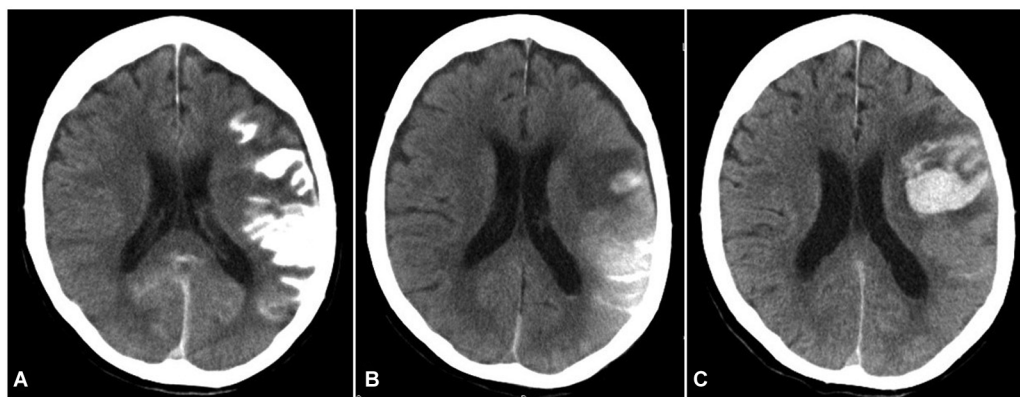
**Fig. 3** (A) Initial angiographic images of the left internal carotid artery (ICA) showing occlusion of the distal M2 portion of the left middle cerebral artery (MCA). (B) An angiographic image of the left ICA; the microcatheter (arrow heads) jumped distally during stent retriever resheath. (C) Angiography through the microcatheter showing contrast leakage into the subarachnoid space. (D) Left ICA angiographic images showing arrest of extravasation without recanalization of the medial vessel of the M2 segment.

combined with the reversal of heparin anticoagulation with protamine and a systolic blood pressure reduction to below 120 mm Hg. Serial control angiography revealed no further contrast leakage after the removal of the microcatheter (► Fig. 3D).

Brain CT revealed a localized subarachnoid hemorrhage (SAH) in the left cerebral cortical sulci (► Fig. 4A).

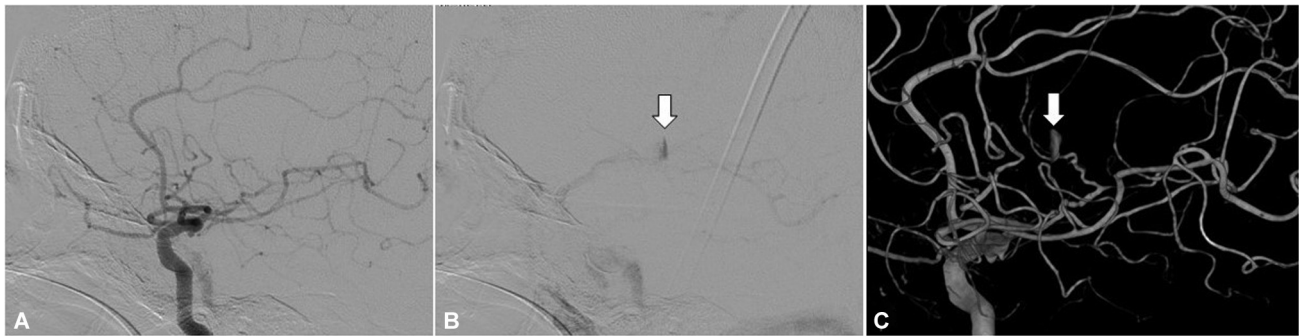
#### Postoperative Course

The patient's neurological symptoms improved the day after the procedure. CT revealed decreased SAH and slight cerebral infarction (► Fig. 4B). Oral apixaban (5 mg daily) was started and continued after 24 hours of the procedure. However, on the 14th postoperative day, the patient had a headache and consciousness disturbance. CT revealed a left frontal

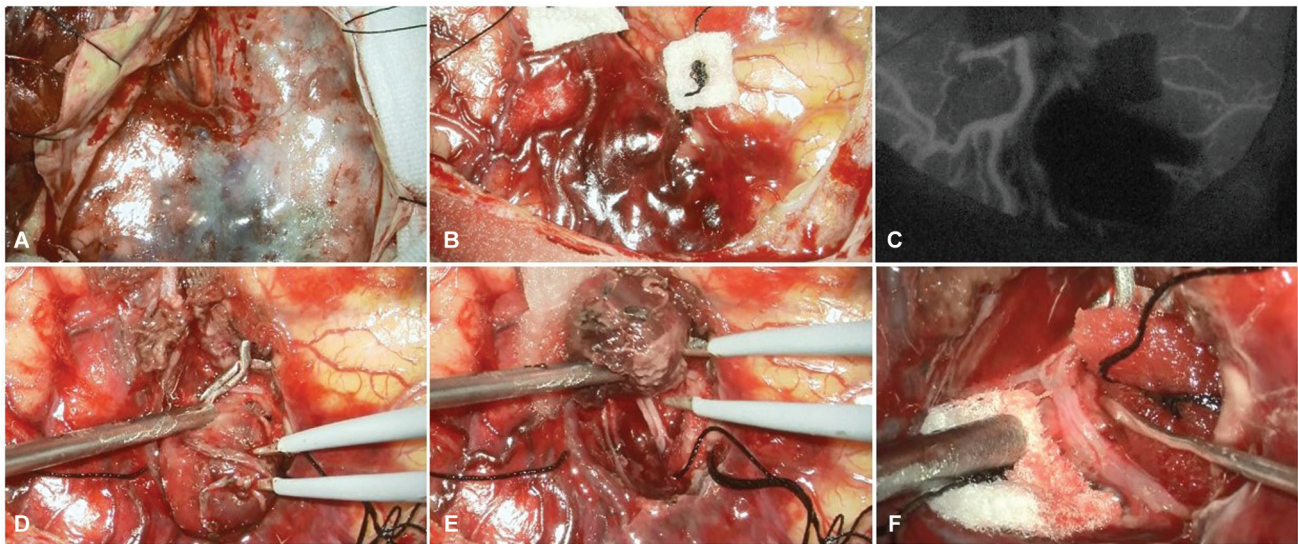


**Fig. 4** (A) A computed tomography (CT) scan obtained immediately after the endovascular procedure showing subarachnoid hemorrhage (SAH). (B) A CT scan acquired 1 day following the procedure showing decreased SAH and cerebral infarction. (C) A CT scan taken 14 days after the procedure showing a massive hematoma.





**Fig. 5** (A) Angiographic images of the left internal carotid artery (ICA) in the arterial phase showing occlusion of the distal M2 portion of the left middle cerebral artery (MCA). (B) Angiographic images of the left ICA in the venous phase showing formation of a pseudoaneurysm (arrow). (C) Three-dimensional digital subtraction angiography obtained 14 days after the procedure showing formation of a pseudoaneurysm (arrow) in the M2 portion of the MCA.



**Fig. 6** Intraoperative photographs. (A) Thick subarachnoid hemorrhage was observed on the surface of the brain. (B, C) Indocyanine green imaging reveals a thrombosed aneurysm and avascular area. (D) The proximal vessel of the pseudoaneurysm was clipped to control blood flow. (E) The pseudoaneurysm was removed. (F) A small artery is ruptured.

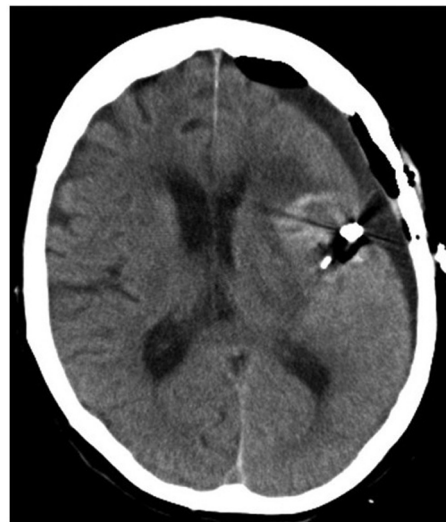subcortical hemorrhage (►Fig. 4C), and angiography revealed pseudoaneurysm in the M3 segment of the MCA (►Fig. 5). A craniotomy was performed to prevent rebleeding from the pseudoaneurysm.

### Open Surgery

A left frontotemporal craniotomy was performed, and a branch of the superficial temporal artery (STA) was preserved for STA-MCA bypass. A thick SAH was observed in the Sylvian fissure (►Fig. 6A). The Sylvian fissure was opened to the distal segment of M2. The hard thrombus around the artery was then removed, revealing an aneurysm in the same location as in the preoperative angiogram (►Fig. 6B).

Indocyanine green confirmed the absence of antegrade blood flow (►Fig. 6C). The proximal vessel of the pseudoaneurysm was clipped to control blood flow (►Fig. 6D).

Removal of pseudoaneurysm revealed a ruptured small artery (►Fig. 6E and F). Thus, the small artery was clipped; no rebleeding occurred after surgery (►Fig. 7). Six months later,



**Fig. 7** Computed tomography after open surgery showing the clip and removal of a massive hematoma.

**Table 1** Previous reports of pseudoaneurysm after mechanical thrombectomy

Author, year	Age/Sex	Occlusion site	Intravenous tPA	Thrombectomy device	Location of pseudoaneurysm	Rupture of pseudoaneurysm	Timing of confirmed pseudoaneurysm	Mechanism of pseudoaneurysm formation	Treatment	Outcome
Jeong et al, 2016	60/Female	Rt. MCA (M1)	No	Aspiration catheter	Rt. MCA (M1)	No (angiography for follow-up of cerebral vasospasm)	Day 15	Direct injury	EVT coil	Mild weakness with her left hand
Misaki et al, 2016	79/Female	Lt. MCA (M2)	No	Stent retriever	Lt. MCA (M2)	Yes	8 h	Small artery avulsion associated with vessel deviation	Open surgery (clipping) clip for the injured distal M2 segment of MCA	NIHSS 15
Helou et al, 2019	57/Female	Lt. ICA	NA	Stent retriever and aspiration catheter	Left cavernous ICA	No (complete ptosis of the left eye with minimally reactive pupil, a third nerve palsy)	4 wk	Dissection	EVT pipeline with coil	mRS 5 Severe aphasia and right hemiparesis
Imahori et al, 2020	84/Female	Lt. MCA (M2)	Yes	Stent retriever	Lt. MCA (M2)	Yes	Day 4	Small artery avulsion	Open surgery (microsurgical suturing)	Severe aphasia and right hemiparesis
Shim et al, 2022	NA (elderly patient)	Lt. ACA	Yes	Stent retriever	Acom	Yes	Day 20	Small artery avulsion associated with vessel deviation	No	Dead
Our case	83/Female	Lt. MCA (M2)	No	Stent retriever	Lt. MCA (M3)	Yes	Day 14	Direct injury	Open surgery (clipping) Trapping for the injured distal M3 segment of MCA	mRS 3 Aphasia and right hemiparesis

Abbreviations: ACA, anterior cerebral artery; Acom, anterior communicating artery; EVT, endovascular therapy; ICA, internal carotid artery; Lt, left; MCA, middle cerebral artery; mRS, modified Rankin Scale; NA, not available; NIHSS, National Institutes of Health Stroke Scale; Rt, right; tPA, tissue plasminogen activator.

the patient was discharged with a modified Rankin Scale score of 3, aphasia, and mild right-sided paralysis.

## Discussion

In our case, delayed rebleeding from a pseudoaneurysm occurred after MT using a stent retriever. The pseudoaneurysm was treated by open surgery. Angiographic and intraoperative findings revealed a mechanism of pseudoaneurysm formation due to small artery rupture caused by catheter jumping during resheathing of the stent retriever.

In previous reports, pseudoaneurysm formation after MT has been reported in six cases, including our case, four following stent retriever usage, one following the aspiration method, and one following the stent retriever and aspiration method (▶Table 1).<sup>3–7</sup> The mechanisms were direct injury from the aspiration method or microcatheter,<sup>3</sup> dissection of unknown cause,<sup>5</sup> and avulsion of small vessels resulting from the stent retriever method.<sup>4,6,7</sup> Therefore, care should also be taken to avoid these complications during the procedure. Several techniques, such as partial deployment of the stent retriever and the use of a distal access catheter, have been reported to be useful for avoiding stretching.<sup>8,9</sup> In five cases, SAH occurred immediately after MT.<sup>3,4,6,7</sup> The time when a pseudoaneurysm is confirmed varies from 8 hours to 4 weeks. Five cases of pseudoaneurysm rupture<sup>3,4,6,7</sup> and one case of third nerve palsy<sup>5</sup> have been reported. Treatment included endovascular treatment in two cases,<sup>3,5</sup> open surgery in three cases,<sup>4,6</sup> and conservative treatment in one case.<sup>7</sup> Open surgery has the advantage of more complete treatment of the pseudoaneurysm and removal of the hematoma. The outcomes were poor, one patient died<sup>7</sup> and five patients experienced hemiparesis and aphasia.<sup>3–6</sup>

Procedure-related SAH after MT has been reported as a benign clinical feature that does not require additional surgical procedures.<sup>2,10,11</sup> However, if there is contrast leakage during the intervention, it is due to vessel perforation or dissection and requires treatment. The treatment of procedure-related SAH after MT with contrast medium leakage is not well known.<sup>2,10,11</sup> In this case, the balloon of the guiding catheter was inflated to temporarily occlude the internal carotid artery to stop the bleeding. Additionally, antihypertensive therapy and heparin reversal therapy with protamine were performed. If angiography shows contrast leakage after repeated temporary balloon occlusions, the injured artery should be sacrificed to stop the bleeding. In such cases, permanent microcatheter placement or embolization with coils or N-butyl-2-cyanoacrylate or Gelfoam may be treatment options.<sup>12–15</sup>

Recently, MT has been cautiously performed even for medium vessel occlusion.<sup>16–18</sup> Distal artery occlusion, a higher number of thrombectomy device passes, and intravenous tissue plasminogen activator use are known risk factors for SAH after MT.<sup>19</sup> It may increase the incidence of hemorrhagic complications.

As SAH after MT is not uncommon, we believe that any case of SAH after MT can be followed up with CT angiography (CTA) or MRA to check for pseudoaneurysm.

## Conclusion

Delayed rupture of the pseudoaneurysm occurred 2 weeks after MT using a stent retriever. The pseudoaneurysm was treated with open surgery.

If SAH is observed after MT, follow-up CTA or MRA should be performed to check the pseudoaneurysm.

### Availability of Data and Materials

The data used in this study will be available upon request to the corresponding author.

### Patients' Consent

Written informed consent to publish this report was obtained from the patient the journal's patient consent policy.

### Funding

None.

### Conflict of Interest

None declared.

### Acknowledgment

We thank Enago ([www.enago.com](http://www.enago.com)) for the English language editing.

## References

- Goyal M, Menon BK, van Zwam WH, et al; HERMES collaborators. Endovascular thrombectomy after large-vessel ischaemic stroke: a meta-analysis of individual patient data from five randomised trials. *Lancet* 2016;387(10029):1723–1731
- Balami JS, White PM, McMeekin PJ, Ford GA, Buchan AM. Complications of endovascular treatment for acute ischemic stroke: prevention and management. *Int J Stroke* 2018;13(04):348–361
- Jeong EO, Kwon HJ, Choi SW, Koh HS. Pseudoaneurysm formation after repetitive suction thrombectomy using a penumbra suction catheter. *J Cerebrovasc Endovasc Neurosurg* 2016;18(03):296–301
- Misaki K, Uchiyama N, Mohri M, et al. Pseudoaneurysm formation caused by the withdrawal of a Trevo ProVue stent at a tortuous cerebral vessel: a case report. *Acta Neurochir (Wien)* 2016;158(11):2085–2088
- Helou E, Sweid A, Tjoumakaris S, et al. Case report of de novo cavernous carotid artery aneurysm following an acute stroke intervention for a carotid occlusion. *World Neurosurg* 2019;128:336–339
- Imahori T, Okamura Y, Sakata J, Shose H, Yamanishi S, Kohmura E. Delayed rebleeding from pseudoaneurysm after mechanical thrombectomy using stent retriever due to small artery avulsion confirmed by open surgery. *World Neurosurg* 2020;133:150–154
- Shim DH, Do Y, Do JK, Youn SW. Delayed rupture of an anterior communicating artery pseudoaneurysm caused by distal occlusion thrombectomy using a stent retriever: a case report and mechanism of injury. *Neurointervention* 2022;17(02):121–125
- Goto S, Ohshima T, Ishikawa K, et al. A stent-retrieving into an aspiration catheter with proximal balloon (ASAP) technique: a technique of mechanical thrombectomy. *World Neurosurg* 2018;109:e468–e475
- Imahori T, Tanaka K, Koyama J, et al. Mechanical thrombectomy using the trevo provue in 50 consecutive patients with anterior circulation stroke: a single-center experience after approval of

- the stent retriever in Japan. *Neurol Med Chir (Tokyo)* 2017;57(03):128–135
- 10 Emprechtlinger R, Piso B, Ringleb PA. Thrombectomy for ischemic stroke: meta-analyses of recurrent strokes, vasospasms, and subarachnoid hemorrhages. *J Neurol* 2017;264(03):432–436
  - 11 Yilmaz U, Walter S, Körner H, et al. Peri-interventional subarachnoid hemorrhage during mechanical thrombectomy with stent retrievers in acute stroke: a retrospective case-control study. *Clin Neuroradiol* 2015;25(02):173–176
  - 12 Nguyen TN, Lanthier S, Roy D. Iatrogenic arterial perforation during acute stroke interventions. *AJNR Am J Neuroradiol* 2008;29(05):974–975
  - 13 Akpınar SH, Yilmaz G. Periprocedural complications in endovascular stroke treatment. *Br J Radiol* 2016;89(1057):20150267
  - 14 Xu H, Guan S, Liu C, et al. Rescue glue embolization of vessel perforation during mechanical thrombectomy for acute ischemic stroke: technical note. *World Neurosurg* 2019;121:19–23
  - 15 Kang JY, Yi KS, Cha SH, et al. Gelfoam embolization for distal, medium vessel injury during mechanical thrombectomy in acute stroke: a case report. *World J Clin Cases* 2021;9(20):5668–5674
  - 16 Haussen DC, Al-Bayati AR, Eby B, et al. Blind exchange with minipinning technique for distal occlusion thrombectomy. *J Neurointerv Surg* 2020;12(04):392–395
  - 17 Pérez-García C, Moreu M, Rosati S, et al. Mechanical thrombectomy in medium vessel occlusions: blind exchange with minipinning technique versus mini stent retriever alone. *Stroke* 2020;51(11):3224–3231
  - 18 Yoshimoto T, Tanaka K, Koge J, et al. Blind exchange with minipinning technique using the tron stent retriever for middle cerebral artery M2 occlusion thrombectomy in acute ischemic stroke. *Front Neurol* 2021;12:667835
  - 19 Lee H, Qureshi AM, Mueller-Kronast NH, et al. Subarachnoid hemorrhage in mechanical thrombectomy for acute ischemic stroke: analysis of the STRATIS registry, systematic review, and meta-analysis. *Front Neurol* 2021;12:663058