



# Extramedullary Intracranial Plasmacytomas: A Systematic Review of Literature

Lucca B. Palavani<sup>1</sup> Atharva Bapat<sup>2</sup> Sávio Batista<sup>3</sup> João Pedro Mendes<sup>3</sup> Leonardo B. Oliveira<sup>4</sup>  
Raphael Bertani<sup>5</sup>

<sup>1</sup> Department of Medicine, Max Planck University Center, São Paulo, Brazil

<sup>2</sup> Trivandrum Medical College, Thiruvananthapuram, Kerala, India

<sup>3</sup> Faculty of Medicine, Federal University of Rio de Janeiro, Rio de Janeiro, Brazil

<sup>4</sup> Department of Medicine, State University of Ponta Grossa, Paraná, Brazil

<sup>5</sup> Department of Neurosurgery, University of São Paulo, São Paulo, Brazil

**Address for correspondence** Leonardo B. Oliveira, MS, Faculty of Medicine, State University of Ponta Grossa, Campus de Uvaranas - Av. General Carlos Cavalcanti, 4748, CEP 84.030-900, Ponta Grossa, Paraná, Brazil (e-mail: leobarrosoliveira09@gmail.com).

Asian J Neurosurg

## Abstract

Extramedullary plasmacytoma (EMP) is an uncommon disorder characterized by the development of abnormal plasma cell tumors outside the bone marrow. These tumors are typically observed in various locations, including the upper respiratory tract, gastrointestinal tract, and other soft tissues. Among the less explored manifestations of EMP is intracranial EMP, which remains poorly understood due to the limited literature available on the subject. The objective was to comprehend the population characteristics, localization, type, treatment, and outcomes of intracranial EMP. A systematic review of the literature for EMPs was conducted following the Preferred Reporting Items for Systematic Reviews and Meta-Analysis guidelines. The term “extramedullary plasmacytoma AND multiple myeloma” was used for the search. The search terms were queried using PubMed, Embase, Scopus, Cochrane, and Web of Science databases. We included only those studies that presented clinical studies with patients diagnosed with intracranial plasmacytomas. In this study, a total of 84 patients from 25 studies were analyzed. The average age of diagnosis was 57.25 years, with a slightly higher proportion of females (57%) compared to male patients (43%). The most common locations of intracranial plasmacytomas were the clivus (29.7%), frontal lobe (18.9%), parietal lobe (8.1%), occipital lobe (6.7%), temporal lobe (6.7%), and sphenoid (4%). Chordoma and meningioma were the most common differential diagnoses encountered during clinical investigations. Treatment modalities included radiotherapy (RT), chemotherapy (QT), surgical resection (SR), and conservative approaches. The most frequent treatment combinations were SR + RT (19%) and RT only (17.8%). Mortality was reported in 48% of the cases, with complete resolution observed in 10 cases and partial resolution in 3 cases. The average follow-up duration was 37.5 months. The clivus is the most frequently reported site of extramedullary intracranial plasmacytoma (EMIP) occurrence, representing 29.7% of cases. Chordomas were commonly observed alongside EMIPs and emerged as the primary differential

## Keywords

- ▶ plasmacytomas
- ▶ extramedullary plasmacytomas
- ▶ intracranial plasmacytomas
- ▶ chordomas
- ▶ solitary plasmacytomas

DOI <https://doi.org/10.1055/s-0044-1787535>.  
ISSN 2248-9614.

© 2024. Asian Congress of Neurological Surgeons. All rights reserved.

This is an open access article published by Thieme under the terms of the Creative Commons Attribution-NonDerivative-NonCommercial-License, permitting copying and reproduction so long as the original work is given appropriate credit. Contents may not be used for commercial purposes, or adapted, remixed, transformed or built upon. (<https://creativecommons.org/licenses/by-nc-nd/4.0/>)

Thieme Medical and Scientific Publishers Pvt. Ltd., A-12, 2nd Floor, Sector 2, Noida-201301 UP, India

diagnosis. RT was the predominant treatment modality, with SR considered when feasible. RT alone demonstrated the highest effectiveness in managing EMIPs (30%), while QT as a sole intervention showed lower efficacy. However, a combination of dexamethasone, lenalidomide, and targeted RT displayed promising results, offering improved tumor response and increased safety.

## Introduction

Multiple myeloma (MM) is the second most common hematological malignancy.<sup>1</sup> It falls under the plasma cell dyscrasias category, ranging from monoclonal gammopathy of unknown significance to MM. Plasmacytomas are cancers of plasma cells that form atypical plasma cell tumors and are associated with the production of monoclonal immunoglobulin or light chains.<sup>2</sup> Incidence of plasmacytomas related to MM range from 7 to 17% at diagnosis to 6 to 20% during the course of the disease.<sup>3</sup>

Solitary bone plasmacytomas (SBPs) account for 8% of all plasma cell tumors and are of two main types, the most frequent one being SBP which accounts for 5% of cases, and solitary extramedullary plasmacytoma (EMP) which accounts for 3% of all cases.<sup>4</sup> The extramedullary disease is linked with aggressive progression of the disease and biological and histological features of poor prognosis.<sup>5</sup> Studies have shown that patients presenting with EMP have a lower chance of the disease progressing to MM as opposed to patients presenting with SBP.<sup>4,6,7</sup>

EMP are a rare occurrence, the most common site being the upper respiratory tract and the gastrointestinal (GI) tract, with the GI tract accounting for 5% of all EMP cases.<sup>8</sup> The presence of an EMP at the time of diagnosis is associated with a poorer outcome in comparison with cases where EMP develops as a complication of the disease, with a median overall survival of 28 versus 68 months.<sup>9</sup> The treatment of EMP requires a multidisciplinary approach involving surgery, pathology, hematology, and radiology. Here, we conduct a systematic review of all patients reported in the literature regarding extramedullary intracranial plasmacytomas (EMIPs), highlighting population characteristics, localization, type, treatment, and outcomes, to better understand this rare clinical presentation.

## Materials and Methods

### Literature Search

A systematic review of the literature for EMPs was conducted per the Preferred Reporting Items for Systematic Reviews and Meta-Analysis guidelines. The strategy “extramedullary plasmacytoma AND multiple myeloma” was used for the search. The search terms were queried using PubMed, Embase, Scopus, Cochrane, and Web of Science databases.

### Inclusion and Exclusion Criteria

Literature in English that presented intracranial plasmacytomas until the present day was considered. We included only those studies that presented clinical studies with

patients diagnosed with intracranial plasmacytomas. Non-English papers, letters to the editor, and commentaries were excluded from the initial review.

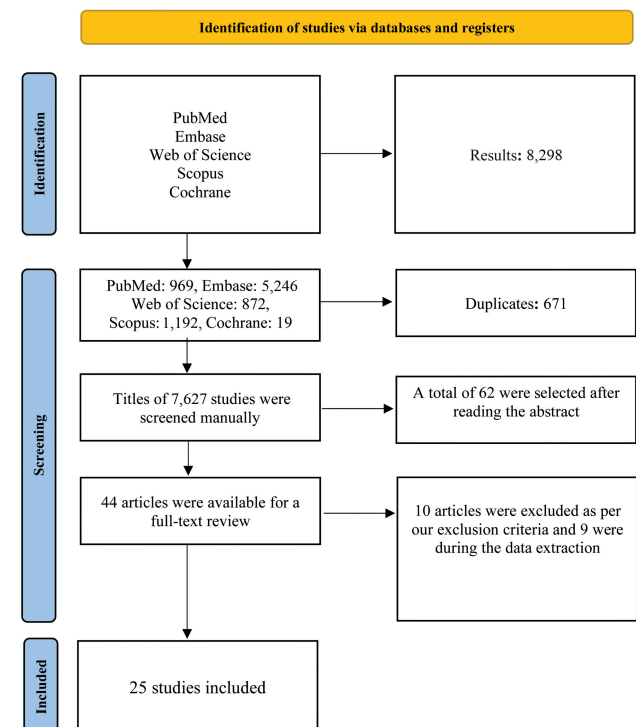
## Results

### Study Selection

We found 8,298 articles, 969 in PubMed, 5246 in Embase, 872 in Web of Science, 1,192 in Scopus, and 19 in Cochrane databases. Of these, 671 were removed as duplicates. Titles of 7,627 studies were screened manually. A total of 62 were selected after reading the abstract and 44 articles were available for a full-text review. Next, 10 articles were excluded as per our exclusion criteria and 9 were excluded during the data extraction. Finally, 25 studies were included in this review. The search is described in ►Fig. 1.

### Patient Baseline

A total of 84 patients from 25 studies were identified, of which 19 studies were case reports and 6 case series, with



**Fig. 1** Preferred Reporting Items for Systematic Reviews and Meta-Analysis (PRISMA) flow diagram for extramedullary intracranial plasmacytomas study selection.

years of publication varying from 1982 until 2022. The average diagnostic patient's age was 57.25 (standard deviation [SD] 13.7), of 82/84 patients 57% were female and 43% were male, not showing a clear difference in the sex proportion. Seventy-four of 84 locations were reported, in which the most common locations found were clivus 22/74 (29.7%), frontal lobe 14/74 (18.9%), parietal lobe 6/74 (8.1%), occipital lobe 5/74 (6.7%), temporal lobe 5/74 (6.7%), and sphenoid 3/74 (4%).

For 29/84 patients, related to the rare presentation, differential diagnosis was reported during clinical investigation. The most related were chordoma (41.3%) and meningioma, 10 (34.5%). Kappa and lambda tumor presentations date were reported in 48/84, appearing in a proportion of 71 and 29%, respectively. Detailed patient results are better detailed in ►Table 1.

### Treatment and Outcomes

Treatment modalities in intracranial plasmacytomas reported in 63/84 studies of the literature were radiotherapy (RT), chemotherapy (QT), surgical resection (SR), and conservative (C). The most common treatment combinations were SR + RT, used in 16/84 patients (19%), and 15/84 RT only (17.8%). Other treatment modalities were distributed as 9/84 QT only (10.7%), 9/84 QT + RT (10.7%), 8/84 SR only (9.5%), and 3/84 SR + QT + RT (3.5%). Also, two patients were treated conservatively.

Outcomes were reported in 27/84 studies, and mortality was presented in 13 (48%) of these patients, of which 1 was not related directly to plasmacytoma, but due to septic shock during hospitalization. Ten cases were resolved completely and 3 studies were partial. One remission was seen in a patient treated by RT. The average follow-up of 19/84 studies was 37.5 months (SD 43.8).

### Discussion

EMIP represents a rare manifestation of plasma cell neoplasms, one of the notable features of EMIP is its propensity to affect the central nervous system, leading to distinct clinical presentations and diagnostic challenges, as shown in our sample.<sup>2,4,5,7,8</sup>

Based on our study, diagnosing EMIP cases is a complex task due to their exceptional nature. As highlighted by Aguado et al,<sup>5</sup> the diagnosis is further complicated by the frequent loss of the ability to synthesize fully functional immunoglobulins, resulting in the production of only light chains or even nonsecretory cases. However, certain diagnostic criteria can be established based on multiple investigations, including radiological, hematological, biochemical, and histological assessments.<sup>2,8,11</sup> Radiologically, EMIP often presents as enhancing masses on imaging studies, with variable contrast enhancement patterns and a predilection for specific anatomical locations, such as the skull base, dura mater, or cranial nerves. Additionally, EMIP can manifest as isolated lesions or as part of a broader systemic disease spectrum. Distinguishing between primary EMIP and secondary involvement in the setting of MM is essential

for guiding treatment decisions and predicting overall outcomes.<sup>19,20,35</sup> The difficulty in diagnosing EMIP, coupled with its rarity, justifies the limited availability of robust treatment and radiographic data. Nevertheless, our study reveals a correlation between specific treatments and their outcomes.

Regarding prognosis, our study shows that EMIP is heterogeneous, influenced by factors such as patient age, overall health, tumor size, and response to treatment.<sup>15</sup> Challenges arise in achieving complete SR due to the intricate anatomical locations often involved. According to Mendenhall et al,<sup>6</sup> QT does not improve survival in EMIP cases, our study showed that most cases analyzed were resolved through a combination of SR and RT or RT alone. Analyzing the 12 reported deaths after treatment (studies 9, 16, 19), we observed that one case (8.3%) was treated with SR + QT, six cases (50%) with QT alone, two cases (16.6%) with RT alone, one case (8.3%) with QT + RT, one case (8.3%) with SR alone, and one case (8.3%) with C. The literature suggests that QT alone is not the optimal solution for EMIP cases. Among the 10 studies with complete data (studies 4, 5, 8, 12, 16, 19, and 25 in ►Table 1), only one case (10%) achieved complete resolution after QT treatment. The most successful approaches were RT alone in three cases (30%), QT + RT in three cases (30%), SR alone in one case (10%), and SR + RT in one case (10%). However, one case out of the 10 studies was not cited (study 25). While the best treatment for EMIP remains unclear,<sup>2,6,8</sup> our findings indicate that RT is the most commonly used treatment, with SR considered for localized EMIP cases.

The relationship between MM and EMIP has remained unclear since 1979, only through meticulous studies of each patient with plasma cell dysplasia can we gather the necessary information to understand better the nature of plasma cell tumors and their potential connections.<sup>7,36,37</sup> Currently, studies are ongoing to determine whether the pathophysiology of SBP is the same as that of plasmacytomas occurring in MM and whether there are differences in treatment approaches.<sup>20,27,38,39</sup> Focal RT, often in combination with dexamethasone, is the treatment of choice for local control, particularly in emerging situations.<sup>5</sup> Additionally, lenalidomide has shown promising results in inducing rapid responses in patients with EMIP. The combination of RT, dexamethasone, and lenalidomide has demonstrated increased efficacy and safety in specific clinical settings, as supported by the literature.<sup>5</sup>

As previously mentioned, RT in combination with other treatments is the most used option in the literature (►Table 1), accounting for 43 out of 84 cases (51%). It is noteworthy that among the 12 deaths reported after treatment, 3 occurred following an RT intervention (25%). These data further strengthen the efficacy of RT in EMIP cases. As reported by et al,<sup>35,40</sup> four patients underwent RT and surpassed the 3-year survival mark. Additionally, one patient received a treatment regimen consisting of intrathecal injection of dexamethasone (10 mg) and cytarabine (50 mg), followed by a combination QT with Velcade, and subsequent RT, resulting in a survival period exceeding 18 months post

**Table 1** Patients' baseline characteristics and outcomes

Study	Year	Age	Sex	Localization	Type	Size	Differential diagnosis	Treatment	Follow-up	Outcome
Bin Waqar et al <sup>10</sup>	CR	60	M	Clivus	L	3.3 × 3.2 × 3.5 cm	Chordoma, lymphoma, metastasis	QT + RT	NA	Alleviated initial symptoms - visual field improvement, resolution of anisocoria and ptosis
	CR	64	F	Frontal	K	NA	NA	SR + QT + RT	NA	NA
Gallina et al <sup>11</sup>		59	F	Parasagittal/dura	L	NA	Meningioma	SR + RT	NA	NA
	CR	39	M	Sphenoid	NA	NA	Meningioma	NA	24 mo	Alleviated initial symptoms - right eye blind, left superior temporal quadrantanopia
Savas et al <sup>13</sup>	CR	52	M	Parieto-occipital	K	11 × 9 cm	NA	QT	NA	Resolved
Wong et al <sup>14</sup>	CR	63	F	Clivus	K	NA	NA	RT	NA	Resolved
Lorberboym et al <sup>15</sup>	CR	56	F	Sphenoid	K	NA	Chordoma, chondrosarcoma	SR + QT + RT	NA	NA
Alafaci et al <sup>16</sup>	CR	65	M	Clivus	K	NA	Pituitary adenoma	QT + RT	6 mo	NA
Patel et al <sup>17</sup>	CR	42	F	Occipital	L	6 × 4 cm	NA	SR + RT	NA	Resolved
Rahmah et al <sup>18</sup>	CR	33	M	Occipital	NA	3.1 × 3.1 × 2.3 cm	Meningioma	SR + QT	12 mo	Death
Kashyap et al <sup>19</sup>	CR	40	M	Clivus	K	4.0 × 2.5 cm	NA	QT + RT	2 mo	Alleviated initial symptoms - resolved diplopia, decreased the intensity of headaches
Bhattacharya et al <sup>20</sup>	CR	30	F	Temporal	L	NA	NA	QT	NA	Death, d/t septic shock
Sahin et al <sup>21</sup>	CR	57	F	Temporal	K	2.2 × 2.6 cm	Meningioma	RT	NA	Resolved
Schwartz et al <sup>22</sup>	CS	43	F	Petrous	L	NA	NA	SR + RT	NA	NA
	CS	55	F	Clivus	L	NA	NA	RT	NA	NA
	CS	73	F	Petrous	K	NA	NA	RT	NA	NA
	CS	49	M	Clivus	K	NA	NA	SR + RT	NA	NA
	CS	54	F	Cranial base	L	NA	NA	SR	NA	NA
	CS	82	F	Frontal	L	NA	NA	SR	NA	NA
	CS	77	F	Falx cerebri	K	NA	NA	SR + RT	NA	NA
	CS	68	F	Frontal	K	NA	NA	RT	NA	NA
	CS	37	F	Temporal	L	NA	NA	SR + RT	NA	NA

Table 1 (Continued)

Study	Year	Age	Sex	Localization	Type	Size	Differential diagnosis	Treatment	Follow-up	Outcome	
Ma et al <sup>23</sup>	2019	59	M	Clivus	NA	NA	Chordoma	NA	NA	NA	
		45	F	NA	NA	NA	Meningioma	NA	NA	NA	
		35	M	NA	NA	NA	NA	NA	NA	NA	NA
		42	M	Clivus	NA	NA	NA	Chordoma	NA	NA	NA
		56	F	NA	NA	NA	NA	NA	NA	NA	NA
		54	M	Clivus	NA	NA	NA	Chordoma	NA	NA	NA
		58	F	NA	NA	NA	NA	Meningioma	NA	NA	NA
		47	F	Clivus	NA	NA	NA	Chordoma	NA	NA	NA
		68	M	NA	NA	NA	NA	NA	NA	NA	NA
		64	M	Clivus	NA	NA	NA	Chordoma	NA	NA	NA
		47	F	Clivus	NA	NA	NA	Chordoma	NA	NA	NA
		73	F	Clivus	NA	NA	NA	Chordoma	NA	NA	NA
		55	F	NA	NA	NA	NA	Meningioma	NA	NA	NA
		50	M	Clivus	NA	NA	NA	Chordoma	NA	NA	NA
		54	F	Clivus	NA	NA	NA	Chordoma	NA	NA	NA
57	F	NA	NA	NA	NA	Meningioma	NA	NA	NA		
69	F	NA	NA	NA	NA	Squamous carcinoma	NA	NA	NA		
Bindal et al <sup>24</sup>	1995	51	F	Sphenoid	NA	NA	NA	SR + RT	NA	NA	
		51	F	Parietal	NA	NA	NA	SR + RT	NA	NA	
		43	F	Falx cerebri	NA	NA	NA	SR + RT	NA	NA	NA
		30	M	Clivus	NA	NA	NA	SR + RT	NA	NA	NA
		47	M	Parietal	NA	NA	NA	SR + RT	NA	NA	NA
		65	M	Parietal	NA	NA	NA	SR	NA	NA	NA
		75	M	Posterior	NA	NA	NA	SR + RT + QT	NA	NA	NA
		82	F	Parietal	NA	NA	NA	SR	NA	NA	NA
Wilberger and Prayson <sup>25</sup>	2016	74	F	NA	L	NA	NA	NA	NA	NA	
		37	F	Occipital	K	NA	NA	QT	180 mo	Death	
		68	M	Cranial base	K	NA	NA	QT + RT	NA	NA	
		65	F	Frontal	K	NA	NA	QT	0.16 mo	Death	

(Continued)

**Table 1** (Continued)

Study	Year	Age	Sex	Localization	Type	Size	Differential diagnosis	Treatment	Follow-up	Outcome
Gagliardi et al <sup>26</sup>	CS	69	M	Frontal	L	NA	NA	RT	120 mo	Death
		72	M	Cranial base	L	NA	NA	QT	48 mo	Death
		44	F	Frontal	L	NA	NA	QT + RT	9 mo	Death
		61	M	Frontal	K	NA	NA	QT	12 mo	Death
		35	M	Frontal	K	NA	NA	QT + RT	60 mo	Resolved
		71	F	Sella turcica	K	NA	NA	QT	36 mo	Death
		30	F	Medulla	K	NA	NA	RT	48 mo	Resolved
		69	M	Frontal	K	NA	NA	QT + RT	48 mo	Resolved
		66	F	Frontal	K	NA	NA	QT	1 mo	Death
Cerrese et al <sup>27</sup>	CS	65	M	Parieto-occipital	K	NA	NA	QT + RT	3 mo	Resolved
		50	F	Clivus	K	NA	Pituitary adenoma	SR + RT	NA	NA
		68	M	Clivus	K	NA	Chordoma	SR + RT	NA	NA
		57	M	Clivus	K	NA	Chordoma	SR + RT	NA	NA
		53	F	Clivus	K	NA	Pituitary adenoma	SR + RT	NA	NA
		67	F	Frontal	K	NA	NA	SR	NA	NA
		79	M	Frontal	K	NA	NA	SR	NA	NA
		72	M	Occipital	K	NA	NA	NA	NA	NA
		62	F	Clivus	K	NA	NA	NA	NA	NA
Malhotra et al <sup>28</sup>	CR	80	F	Clivus	NA	NA	NA	RT	NA	NA
		82	M	Cavernous sinus	K	NA	NA	QT	NA	NA
		74	F	Diffuse	L	NA	NA	C	NA	NA
		58	F	Parietal	NA	NA	NA	RT	NA	Death
		69	F	Temporal	NA	NA	NA	SR	NA	Death
		67	F	Temporal	NA	NA	NA	C	NA	Death
		79	M	Frontal	NA	NA	NA	SR	24 mo	Resolved
		45	M	Parietal	NA	7.5 × 7.5 × 4.5 cm	Meningioma	RT	NA	Remission
		37	M	Posterior	NA	5.5 × 3.5 × 3.1 cm	Meningioma, lymphoma	RT	NA	NA
Kujat et al <sup>31</sup>	CR	67	NA	Cerebellar	K	NA	NA	RT	NA	NA
		45	NA	NA	K	NA	NA	QT + RT	NA	NA

**Table 1** (Continued)

Study	Year	Age	Sex	Localization	Type	Size	Differential diagnosis	Treatment	Follow-up	Outcome
Rivas et al <sup>32</sup>	1994	54	F	Frontal	NA	NA	NA	RT	36 mo	NA
Gregorio and Soyeml <sup>33</sup>	2019	45	M	Third ventricle	NA	NA	NA	RT	36 mo	NA
Kumar et al <sup>34</sup>	2019	39	M	Parasellar	K	5.0 × 4.4 cm	MM	SR + RT	NA	NA
		59	F	Occipital	K	2.6 × 1.4 cm	Carcinomatosis	RT	NA	Resolved

Abbreviations: C, conservative; CR, case report; CS, case series; F, female; K, kappa; L, lambda; M, male; MM, multiple myeloma; NA, not available; QT, chemotherapy; RT, radiotherapy; SR, surgical resection.

the onset of head EMIP. It appears that the inclusion of Velcade in combination with QT, along with RT, could potentially extend survival rates.<sup>35</sup> The role of RT is pivotal in the management of EMIP contributing to both local disease control and potential systemic effects. Despite therapeutic advances, recurrences are not uncommon, underscoring the importance of long-term follow-up and continued vigilance in monitoring patients for signs of disease persistence or progression. Collaboration between neurosurgeons, hematologists, and radiation oncologists is crucial for optimizing treatment strategies and enhancing patient outcomes.<sup>35,38,40</sup>

Histopathologically, EMIP shares commonalities with other plasma cell disorders, revealing monoclonal plasma cell infiltration and the potential for amyloid deposition.<sup>10</sup> Immunohistochemical staining, particularly for plasma cell markers such as CD138 and kappa or lambda light chains, is instrumental in confirming the diagnosis and differentiating EMIP from other intracranial lesions, as mentioned by some previous authors.<sup>9</sup> Although kappa and lambda levels may serve as serum markers of EMIP, it is not safe to draw definitive prognostic conclusions based solely on their levels.<sup>9,10,24</sup> In Schols and Tick's study,<sup>9</sup> despite an increase in immunoglobulin A lambda levels, no organs were affected in their case. However, Ahnach et al<sup>2</sup> reported an association between illness progression and lambda levels in EMIP cases, showing a divergence among the studies presented in the literature.

### Limitations

This study has limitations. EMIP is a rare presentation of plasmacytoma, the plenty of information about this topic is limited, but it was neatly sidestepped for our data synthesis and careful search, besides that, the coming studies can explore and report the molecular level as kappa and lambda of EMIP cases or differential diagnosis, it would contribute to make new comparisons and investigate more deeply possible differences and/or similarities.

### Conclusion

Based on our comprehensive literature review of EMIPs, several key findings emerge. The predominant site for EMIP occurrence appears to be the clivus, accounting for 29.7% of the EMIP cases examined in the literature. Chordomas, which happen to be the most common differential diagnosis, were frequently observed in conjunction with EMIPs.

In terms of treatment modalities, RT emerged as the most employed approach for managing EMIP tumors. When feasible, based on tumor size and localization, SR was also considered. Notably, RT alone (30%) was the most effective intervention. Conversely, QT as the sole management option demonstrated lower efficacy compared to RT. However, a combination of dexamethasone, lenalidomide, and targeted RT exhibited more promising results, demonstrating improved tumor response while maintaining a higher level of safety.

**Conflict of Interest**

None declared.

**References**

- 1 Kazandjian D. Multiple myeloma epidemiology and survival: a unique malignancy. *Semin Oncol* 2016;43(06):676–681
- 2 Ahnach M, Marouan S, Rachid M, et al. Extramedullary plasmacytoma relapsing at different sites: an unusual presentation. *Pan Afr Med J* 2013;14:34
- 3 Oriol A. Multiple myeloma with extramedullary disease. *Adv Ther* 2011;28(Suppl 7):1–6
- 4 Leibel SA, Phillips TL. Textbook of radiation oncology. In: Meloni D, Shreiner J, eds. 2nd ed. Philadelphia, PA: Elsevier; 2004:1435–1438
- 5 Aguado B, Iñigo B, Sastre JL, Oriol A. Extramedullary plasmacytomas in the context of multiple myeloma. *Adv Ther* 2011;28(Suppl 7):7–13
- 6 Mendenhall WM, Mendenhall CM, Mendenhall NP. Solitary plasmacytoma of bone and soft tissues. *Am J Otolaryngol* 2003;24(06):395–399
- 7 Corwin J, Lindberg RD. Solitary plasmacytoma of bone vs. extramedullary plasmacytoma and their relationship to multiple myeloma. *Cancer* 1979;43(03):1007–1013
- 8 Lin QT, Cai XR. Extramedullary plasmacytoma involving rectum: a case report and literature review. *Radiol Case Rep* 2021;16(04):785–788
- 9 Schols SE, Tick LL. Recurrent extramedullary plasmacytoma in asymptomatic multiple myeloma: a case report. *J Med Case Rep* 2015;9:37
- 10 Bin Waqar SH, Rehan A, Salahi N, Zhonghua L, McFarlane I. An exceptional case of diplopia and ptosis: extramedullary plasmacytoma of the clivus with multiple myeloma. *Cureus* 2022;14(03):e23219
- 11 Gallina P, Mascalchi M, Mouchaty H, Buccoliero A, Perrini P. Misleading imaging features of intracranial dural plasmacytoma: report of two cases. *Br J Neurosurg* 2004;18(06):643–646
- 12 Hogan MC, Lee A, Solberg LA, Thomé SD. Unusual presentation of multiple myeloma with unilateral visual loss and numb chin syndrome in a young adult. *Am J Hematol* 2002;70(01):55–59
- 13 Savas MC, Benekli M, Haznedaroğlu IC, Dündar SV. Bulky plasmacytoma of the skull with intracranial involvement. *Am J Hematol* 1997;54(02):173
- 14 Wong ET, Lu XQ, Devulapalli J, Mahadevan A. Cyberknife radiosurgery for basal skull plasmacytoma. *J Neuroimaging* 2006;16(04):361–363
- 15 Lorberboym M, Segal D, Machac J, Sen C, Sacher M. Avid uptake of technetium-99m-HMPAO by an intracranial plasmacytoma during carotid balloon test occlusion. *J Nucl Med* 1995;36(05):800–803
- 16 Alafaci C, Grasso G, Conti A, Caffo M, Salpietro FM, Tomasello F. Cyberknife radiosurgery for cranial plasma cell tumor. *Turk Neurosurg* 2014;24(02):272–275
- 17 Patel AJ, Adams GJ, Humphries WE, et al. Multiple myeloma presenting as solitary mass in the posterior fossa. *J Clin Neurosci* 2010;17(11):1457–1459
- 18 Rahmah N, Brotoarianto H, Andor E, Kusnarto G, Muttaqin Z, Hongo K. Dural plasmacytoma mimicking meningioma in a young patient with multiple myeloma. *Bijl* 2009;5(02):e5
- 19 Kashyap R, Kumar R, Kumar S. Cranial nerve palsy in multiple myeloma and solitary plasmacytoma. *Asia Pac J Clin Oncol* 2010;6(04):251–255
- 20 Bhattacharya B, Chattopadhyay B, Chatterjee A, Boler AK, Debnath NB. Multiple cranial nerve palsies in a case of intracranial plasmacytoma and multiple myeloma: a report. *J Solid Tumors* 2014;4(01):38
- 21 Sahin F, Saydam G, Ertan Y, Calli C, Dönmez A, Tombuloglu M. Dural plasmacytoma mimicking meningioma in a patient with multiple myeloma. *J Clin Neurosci* 2006;13(02):259–261
- 22 Schwartz TH, Rhiew R, Isaacson SR, Orazi A, Bruce JN. Association between intracranial plasmacytoma and multiple myeloma: clinicopathological outcome study. *Neurosurgery* 2001;49(05):1039–1044, discussion 1044–1045
- 23 Ma XJ, Li D, Wang L, et al. Clinical features, radiological profiles, and surgical outcomes of primary intracranial solitary plasmacytomas: a report of 17 cases and a pooled analysis of individual patient data. *J Neurooncol* 2019;142(02):263–272
- 24 Bindal AK, Bindal RK, van Loveren H, Sawaya R. Management of intracranial plasmacytoma. *J Neurosurg* 1995;83(02):218–221
- 25 Wilberger AC, Prayson RA. Intracranial involvement by plasma cell neoplasms. *Am J Clin Pathol* 2016;146(02):156–162
- 26 Gagliardi F, Losa M, Boari N, et al. Solitary clival plasmacytomas: misleading clinical and radiological features of a rare pathology with a specific biological behaviour. *Acta Neurochir (Wien)* 2013;155(10):1849–1856
- 27 Cerase A, Tarantino A, Gozzetti A, et al. Intracranial involvement in plasmacytomas and multiple myeloma: a pictorial essay. *Neuroradiology* 2008;50(08):665–674
- 28 Malhotra I, Chandra AB, Huang Y. Initial presentation of multiple myeloma as intraparenchymal brain mass. *Blood* 2013;122(21):5402–5402
- 29 Anoop TM, Jain N, Nair SG. Intracranial plasmacytoma mimicking meningioma. *J Neurosci Rural Pract* 2014;5(01):87
- 30 Daghighi MH, Poureisa M, Shimia M, Mazaheri-Khamene R, Daghighi S. Extramedullary plasmacytoma presenting as a solitary mass in the intracranial posterior fossa. *Iran J Radiol* 2012;9(04):223–226
- 31 Kujat C, Reiche W, Koch B, Moringlane JR. Seltene intrakranielle Plasmazytommanifestationen. Fallberichte und Literaturübersicht bei diffusem Plasmazytom, bei primär solitär extramedullärem Plasmazytom und bei primär solitär ossärem Plasmazytom. [Rare intracranial plasmacytoma manifestations. Case reports and review of the literature in diffuse plasmacytoma, in primary solitary extramedullary plasmacytoma in primary solitary osseous plasmacytoma] *Radiologe* 1996;36(11):914–920
- 32 Rivas L, Guzmán JR, Mora-La Cruz E, Cardozo J. Plasmocitoma solitario intracraneal extramedular. Reporte de dos casos. [Extramedullary intracranial solitary plasmacytoma. Report of 2 cases] *Invest Clin* 1994;35(03):155–167
- 33 Gregorio LM, Soyemi TO. Multiple myeloma presenting as dural plasmacytoma. *Radiol Case Rep* 2019;14(08):1007–1013
- 34 Kumar A, Nayak B, Krishnamurthy BH, Patro SK, Sahoo PK. Primary cerebral plasmacytoma: a rare case report with review of literature. *Indian J Neurosurg* 2019;08(02):123–126
- 35 Sun WJ, Zhang JJ, An N, Shen M, Huang ZX, Li X. Clinical analysis of 40 multiple myeloma patients with extramedullary plasmacytoma of the head. *J Int Med Res* 2016;44(06):1462–1473
- 36 Chauhan R, Trivedi V, Rani R, Singh U. A study of head and neck cancer patients with reference to tobacco use, gender, and subsite distribution. *South Asian J Cancer* 2022;11(01):46–51
- 37 In GK, Thomas JS, Silk AW. Cutaneous malignancies of the head and neck. *Hematol Oncol Clin North Am* 2021;35(05):991–1008
- 38 Brenner B, Carter A, Tatarsky I, Gruszkiewicz J, Peyser E. Incidence, prognostic significance and therapeutic modalities of central nervous system involvement in multiple myeloma. *Acta Haematol* 1982;68(02):77–83
- 39 Cook J, Song S, Ventimiglia A, Luhrs C. Incidental discovery of multiorgan extramedullary plasmacytomas in the setting of newly diagnosed multiple myeloma and delayed hemolytic transfusion reaction. *Case Rep Hematol* 2017;2017:4531858
- 40 Wang SSY, Lee MB, George A, et al. Five cases of orbital extramedullary plasmacytoma: diagnosis and management of an aggressive malignancy. *Orbit* 2019;38(03):218–225