




Cavernous Sinus Meningioma of the Oculomotor Nerve in a Child: A Surgical Case Study

Gakuji Maruyama¹ Tetsuro Sameshima¹ Takashi Tsuchida² Kazuhiko Kurozumi¹

¹Department of Neurosurgery, Hamamatsu University School of Medicine, Hamamatsu, Japan

²Department of Pathology, Hamamatsu University School of Medicine, Hamamatsu, Japan

Address for correspondence Tetsuro Sameshima, MD, PhD, Department of Neurosurgery, Hamamatsu University School of Medicine, 1-20-1, Handayama, Higashi-ku, Hamamatsu City, Shizuoka 431-3192, Japan (e-mail: tetsurosameshima@gmail.com).

Asian J Neurosurg 2024;19:338–341.

Abstract

Keywords

- ▶ cavernous sinus
- ▶ meningioma
- ▶ neurosurgery
- ▶ oculomotor nerve
- ▶ pediatrics

Pediatric cavernous sinus meningiomas are rare. Herein, we present the case of a 5-year-old boy who presented with progressive left oculomotor nerve palsy. A head magnetic resonance imaging revealed a mass lesion in the left cavernous sinus, following which tumor resection was performed. The tumor strongly adhered to the left oculomotor nerve without adherence to the walls of the cavernous sinus; however, its border with the nerve was unclear. Histopathological analysis led to the diagnosis of fibrous meningioma. To the best of our knowledge, this is the first case study to report the pediatric development of a cavernous sinus meningioma in the oculomotor nerve.

Introduction

Meningiomas represent the most common type of primary benign brain tumors, which mostly develop in adults. Meningiomas are rarely found in children, particularly cavernous sinus meningiomas. Herein, to our understanding, we report the first case of pediatric cavernous sinus meningioma in the oculomotor nerve.

Clinical Summary

The patient was a 5-year-old boy, who was taken to a local ophthalmologist at 2 years of age with the chief complaint of adduction failure of the left eye; however, the cause remained unidentified. He developed constant exotropia 6 months later, and left eyelid ptosis became noticeable at 4 years of age. He was diagnosed with progressive left oculomotor nerve palsy. Computed tomography and head

magnetic resonance imaging (MRI) revealed a mass lesion measuring approximately 8 mm accompanied by calcification in the left cavernous sinus (▶**Fig. 1**). Findings at the initial visit included abduction of the left eye, ptosis, pupillary dilation, loss of light reflex, and superior, inferior, and medial total motor palsy, indicating that the patient had total oculomotor nerve palsy. The preoperative diagnosis was oculomotor nerve schwannoma. The surgery was performed as follows. A left frontotemporal craniotomy was performed and the anterior clinoid process was removed before the walls of the cavernous sinus were opened to expose the tumor. Preservation of the oculomotor nerve was considered impossible as the tumor was fusiform, did not adhere to the walls of the cavernous sinus, and showed complete tumor transition from the oculomotor nerve with a completely unclear border (▶**Fig. 2**). Therefore, the oculomotor nerve was cut and total tumor resection was performed. Nerve grafting was not performed because the edge of the nerve

article published online
June 5, 2024

DOI <https://doi.org/10.1055/s-0044-1787533>.
ISSN 2248-9614.

© 2024. Asian Congress of Neurological Surgeons. All rights reserved.

This is an open access article published by Thieme under the terms of the Creative Commons Attribution-NonDerivative-NonCommercial-License, permitting copying and reproduction so long as the original work is given appropriate credit. Contents may not be used for commercial purposes, or adapted, remixed, transformed or built upon. (<https://creativecommons.org/licenses/by-nc-nd/4.0/>)

Thieme Medical and Scientific Publishers Pvt. Ltd., A-12, 2nd Floor, Sector 2, Noida-201301 UP, India

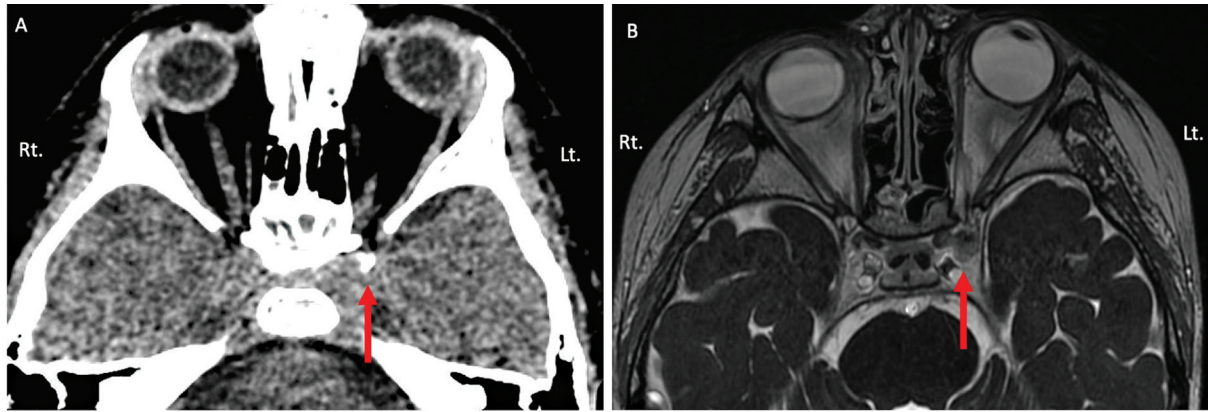


Fig. 1 Head computed tomography (CT) and magnetic resonance imaging (MRI) of the patient. (A) CT reveals calcified lesion near the left superior orbital fissure (red allow). (B) Contrast-enhanced fast imaging employing steady-state acquisition (FIESTA) shows a nodular lesion in the cavernous sinus (red allow).

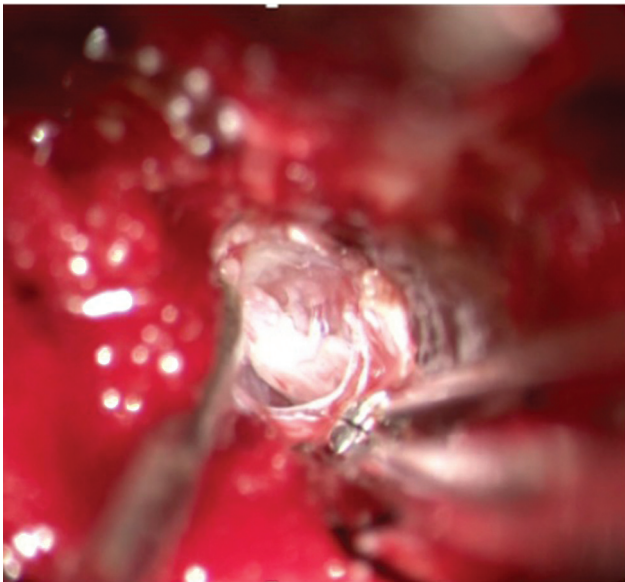


Fig. 2 Surgical microscope image shows the tumor developed in the oculomotor nerve.

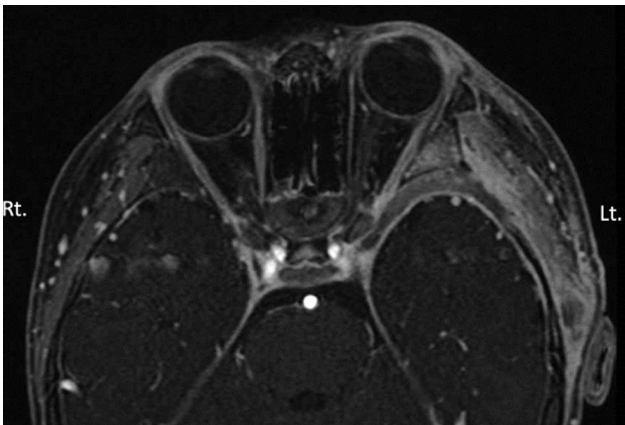


Fig. 3 Postoperative magnetic resonance imaging (MRI) shows the total tumor removal.

was outside the operative field. Instead, the patient underwent additional surgery for left oculomotor nerve palsy at the department of ophthalmology for aesthetic purposes. Postoperative MRI confirmed the complete removal of the tumor (►Fig. 3). The patient had no genetic mutations or family history of neurofibromatosis type 2.

Pathological Findings

As histopathological findings, hematoxylin and eosin staining revealed the proliferation of spindle-shaped to epithelioid tumor cells between intertwined/proliferating collagen fibers with some calcification. There was minimal atypicity without mitosis or necrosis (►Fig. 4A). Immunostaining revealed epithelial membrane antigen (+), somatostatin receptor type 2 (+), glial fibrillary acidic protein (–), S-100 protein (–), signal transducer and activator of transcription 6 (–), and the Ki-67 labeling index of < 3%. These findings led to a diagnosis of fibrous meningioma (World Health Organization classification grade 1) (►Fig. 4B). S-100 protein staining revealed tumor cell invasion of nerve fibers (►Fig. 4C).

Discussion

Pediatric meningiomas are uncommon, accounting for 0.4 to 4.6% of all cases of primary brain tumors in children and 1.5 to 2.0% of all cases of meningiomas.¹ Moreover, of 677 patients who developed meningiomas at ≤ 20 years of age, 4 (0.6%) had cavernous sinus meningiomas.² Furthermore, there is a paucity of reports regarding histopathological findings as the tumors are rarely removed. As far as we know, only three cases of pediatric cavernous sinus meningiomas emerging as oculomotor nerve palsy have been previously reported.^{3–5}

In our patient, the initial symptom was progressive oculomotor nerve palsy and the preoperative diagnosis was oculomotor nerve schwannoma. Based on intraoperative findings, including complete tumor transition of the oculomotor nerve

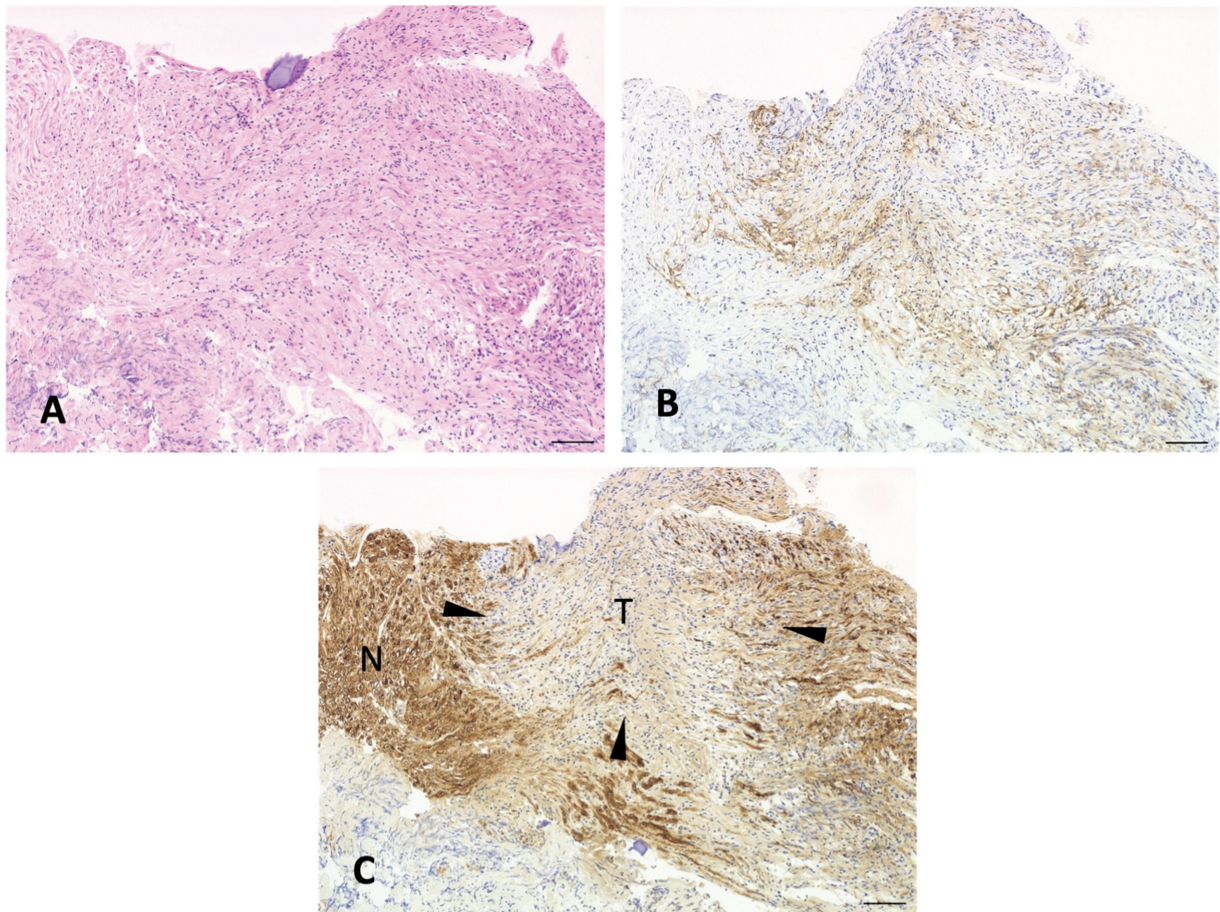


Fig. 4 Histological and immunostaining features of the tumor. (A) Hematoxylin and eosin (HE) staining reveal spindle-shaped to epithelioid cell-like tumor cell proliferation between the intricate and proliferating collagen fibers, with some calcification. No existing mitosis or necrosis is observed. (B) Immunostaining for epithelial membrane antigen (EMA) is positive. (C) Immunostaining for S-100 protein reveals the tumor invasion of the oculomotor nerve. The arrowheads show the extent of tumor invasion. T, tumor; N, nerve. Scale bars: 100 μ m (A–C).

and the unclear tumor border with the nerve, preservation of the oculomotor nerve was considered impossible and the whole tumor alongside the oculomotor nerve was surgically removed. No adhesion was observed to the walls of the cavernous sinus. Postoperative histopathological examination revealed tumor cell infiltration into the nerve fibers. Two cases of meningiomas of the oculomotor nerve have previously been reported; however, the patients were adults and the lesions were located in the cistern in both cases.^{6,7} One case reported by Hart et al involved a malignant meningioma, and our intraoperative findings resembled those of a meningotheial meningioma case reported by Sharifi et al. However, ours was the first pediatric case of meningioma affecting the cavernous sinus. In other reported cases of cranial nerve meningiomas, the affected sites were the trigeminal and accessory nerves.^{8,9} Fujimoto et al have reported a case of meningioma arising from the left mandibular nerve without dural attachment in a 69-year-old woman who presented with progressive left facial sensory disorder. Mohri et al have reported an extramedullary meningioma at the foramen magnum originating from the spinal accessory nerve that manifested as left-sided spinal accessory nerve palsy.

The origin of meningiomas is considered meningotheial cells or arachnoid cap cells. Arachnoid cap cells reportedly stretch widely along the nerves beyond the dura penetration site of the cranial and spinal nerves.^{10,11} Since a case of meningioma arising from extracranial perineural cells has been previously reported,¹² Fujimoto et al have hypothesized that meningiomas without dural attachment originate from ectopic arachnoid cap cells within the nerve sheath and the perineural cells,⁸ and we consider that our case is likely to be similar.

Some patients with meningiomas of the cavernous sinus present with progressive oculomotor disturbance even when the tumor size is small; however, such cases may include meningiomas arising from ectopic arachnoid cap cells of cranial nerves, such as our case.

Conclusion

We described a case of pediatric cavernous sinus meningioma. This is a rare phenomenon, and, to the best of our knowledge, this was the first study to report such a case wherein the intraoperative and histopathological findings

suggest that the tumor developed in the oculomotor nerve. Further research should be done.

Authors' Contributions

G.M. drafted the original article. T.S. critically revised the article and a surgeon for this case. T.T. acquired the clinical data. K.K. supervised drafting the article. All authors have read and approved the final manuscript.

Patients' Consent

Written informed consent was obtained from the patient for publication of this case report and accompanying images.

Funding

None.

Conflict of Interest

None declared.

Acknowledgment

We would like to thank Dr. Miho Sato of the Department of ophthalmology, Hamamatsu University School of Medicine for her assistance.

References

- Gao X, Zhang R, Mao Y, Wang Y. Childhood and juvenile meningiomas. *Childs Nerv Syst* 2009;25(12):1571–1580
- Kotecha RS, Pascoe EM, Rushing EJ, et al. Meningiomas in children and adolescents: a meta-analysis of individual patient data. *Lancet Oncol* 2011;12:1229–1239
- Ersahin Y, Ozdamar N, Demirtaş E, Karabiyikoğlu M. Meningioma of the cavernous sinus in a child. *Childs Nerv Syst* 1999; 15:8–10
- Kuratsu J, Okamura A, Kamiryo T, Ushio Y. A pediatric patient with meningioma arising from the cavernous sinus wall. *Acta Neurochir (Wien)* 1997;139:259–260
- Louis M, Goga D, François P, Laure B. Ptosis secondary to cavernous sinus meningioma. *J Fr Ophthalmol* 2013;36:e197–e200
- Sharifi G, Lotfinia M, Omidbeigi M, Asaadi S, Zerehpooosh FB. Meningothelial meningioma of the oculomotor nerve: a case report and review of the literature. *Surg Neurol Int* 2020; 11:314
- Hart AJ, Allibone J, Casey A, Thomas D. Malignant meningioma of the oculomotor nerve without dural attachment. *J Neurosurg* 1998;88:1104–1106
- Fujimoto Y, Kato A, Taniguchi M, Maruno M, Yoshimine T. Meningioma arising from the trigeminal nerve: a case report and literature review. *J Neurooncol* 2004;68:185–187
- Mohri M, Yamano J, Saito K, Nakada M. Spinal accessory nerve meningioma at the foramen magnum with medullar compression: a case report and literature review. *World Neurosurg* 2019; 289:158–161
- Geoffray A, Lee YY, Jing BS, Wallace S. Extracranial meningiomas of the head and neck. *AJNR Am J Neuroradiol* 1984;5:599–604
- Lopez DA, Silvers DN, Helwig EB. Cutaneous meningiomas – a clinicopathological study. *Cancer* 1974;34:728–744
- Tomaru U, Hasegawa T, Hasegawa F, Kito M, Hirose T, Shimoda T. Primary extracranial meningioma of the foot: a case report. *Jpn J Clin Oncol* 2000;30:313–317