



# Wrist Arthrodesis

## Artrodesis de muñeca

Moisés Vallés Andreu<sup>1</sup> Juan Andrés González García<sup>1</sup> Carmen Guardiola Herráez<sup>1</sup>  
Francisco Martínez Martínez<sup>1</sup>

<sup>1</sup>Orthopaedic Surgery Department, Hospital Clínico Universitario Virgen de la Arrixaca, Universidad de Murcia, Murcia, Spain

Rev Iberam Cir Mano 2024;52(1):e3–e15.

Address for correspondence

Francisco Martínez Martínez, Orthopaedic Surgery Department, Hospital Clínico Universitario Virgen de la Arrixaca, Universidad de Murcia, Murcia, Spain  
(e-mail: fmtnez@gmail.com).

### Abstract

Wrist arthrodesis, both total and partial, are therapeutic options for the treatment of post-traumatic, degenerative or rheumatic arthropathies. The objective of these surgeries is to eliminate pain and stabilize the wrist to the detriment of loss of mobility, allowing patients to resume their daily activities without pain. Partial arthrodesis aim to preserve some mobility by fusing only certain joints, leaving only non-pathological joints mobile, while total arthrodeses involve total fusion of the wrist, offering definitive solutions for severe pain and instability.

Performing these techniques through arthroscopic surgery offers results similar to those of open surgery, with the additional benefit of minimizing complications, reducing recovery time and improving the postoperative aesthetic result.

### Keywords

- ▶ wrist
- ▶ arthrodesis
- ▶ arthroscopy
- ▶ pain
- ▶ instability

### Resumen

Las artrodesis de muñeca, tanto totales como parciales, son opciones terapéuticas para el tratamiento de las artropatías postraumáticas, degenerativas o reumáticas. El objetivo de estas cirugías es eliminar el dolor y estabilizar la muñeca con el detrimento de pérdida de movilidad, permitiendo a los pacientes retomar sus actividades diarias sin dolor. Las artrodesis parciales tienen como objetivo conservar cierta movilidad al fusionar solo ciertas articulaciones dejando móviles solo las articulaciones no patológicas, mientras que las artrodesis totales involucran la fusión total de la muñeca, ofreciendo soluciones definitivas para el dolor intenso e inestabilidad.

La realización de estas técnicas mediante cirugía artroscópica ofrece resultados similares a los de la cirugía abierta, con el beneficio adicional de minimizar las complicaciones, reducir el tiempo de recuperación y mejorar el resultado estético postoperatorio.

### Palabras clave

- ▶ muñeca
- ▶ artrodesis
- ▶ artroscopia
- ▶ dolor
- ▶ inestabilidad

### Introduction

The main goal of the treatment of degenerative wrist is to provide symptomatic relief while maintaining maximum possible strength and mobility. The management can range from conservative to fusion of the wrist joint,

the latter being possible through partial or total arthrodesis.

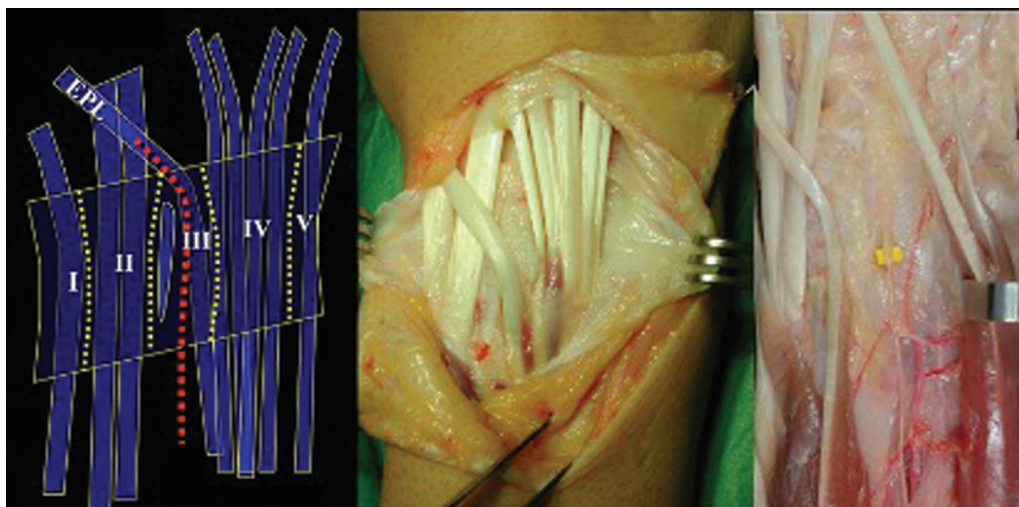
Biomechanical studies have shown that procedures on this joint considerably alter load transmission and intra-carpal kinematics. Therefore, after surgery, strength and movements will never be the same as before surgery.

DOI <https://doi.org/10.1055/s-0044-1787271>.  
ISSN 1698-8396.

© 2024. SECMA Foundation. All rights reserved.

This is an open access article published by Thieme under the terms of the Creative Commons Attribution-NonDerivative-NonCommercial-License, permitting copying and reproduction so long as the original work is given appropriate credit. Contents may not be used for commercial purposes, or adapted, remixed, transformed or built upon. (<https://creativecommons.org/licenses/by-nc-nd/4.0/>)

Thieme Revinter Publicações Ltda., Rua do Matoso 170, Rio de Janeiro, RJ, CEP 20270-135, Brazil



**Fig. 1** Approach at the level of the third dorsal compartment with a radial retinacular flap from the second compartment and ulnar from the fourth compartment. In the floor of the fourth compartment lies the posterior interosseous (PIO) nerve.

According to some authors, a balance of motion of  $5^{\circ}$  to  $54^{\circ}$  of flexion and  $30^{\circ}$  to  $60^{\circ}$  of extension is required to perform a given task, so a limitation of the joint range of the wrist does not result in its non-functionality.<sup>3</sup> However, Adams et al.<sup>4</sup> showed that the perception of a restriction in wrist mobility produces a greater impact on its performance than the loss of it itself, without significant differences between a partial and total limitation. Therefore, preserving range of motion above all else should not be a priority goal.

### Surgical Technique

The surgery performed under regional anesthesia and ischemia. The incision is made at the level of the Lister tubercle, from the distal radius to the base of the third metacarpal. The extensor retinaculum is opened at the third compartment (extensor pollicis longus) with a radial retinacular flap including the second compartment and the first, if necessary, and an ulnar retinacular flap including the fourth compartment and the fifth, if necessary (→ **Figure 1**).

In the floor of the fourth compartment is the posterior interosseous nerve (PIO). In the capsule, you can identify the dorsal radiopyramidal ligament and the dorsal intercarpal ligament (which are actually capsular reinforcements and are not always easy to identify).

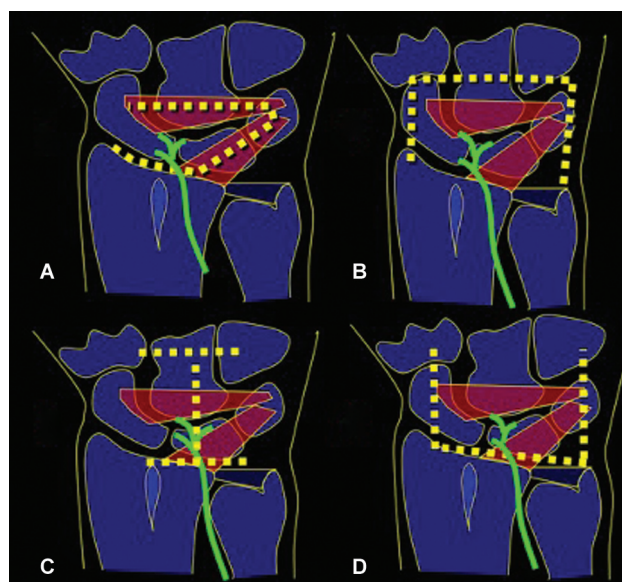
Dorsal capsulotomy can be performed through (→ **Figure 2**):

1. Radial-based capsular flap including part of the dorsal and intercarpal radiopyramidal ligament, described by Berger et al.,<sup>5</sup> with this capsulotomy, a neurectomy of the PIO is performed, which is why it is indicated in degenerative processes to achieve denervation in cases in which it is not necessary to preserve the proprioception (→ **Figure 3**).
2. Proximal-based capsular flap if the PIO nerve is to be preserved, as described by Hagert et al.,<sup>6</sup> and thus proprioception; the nerve is included in the capsular flap,

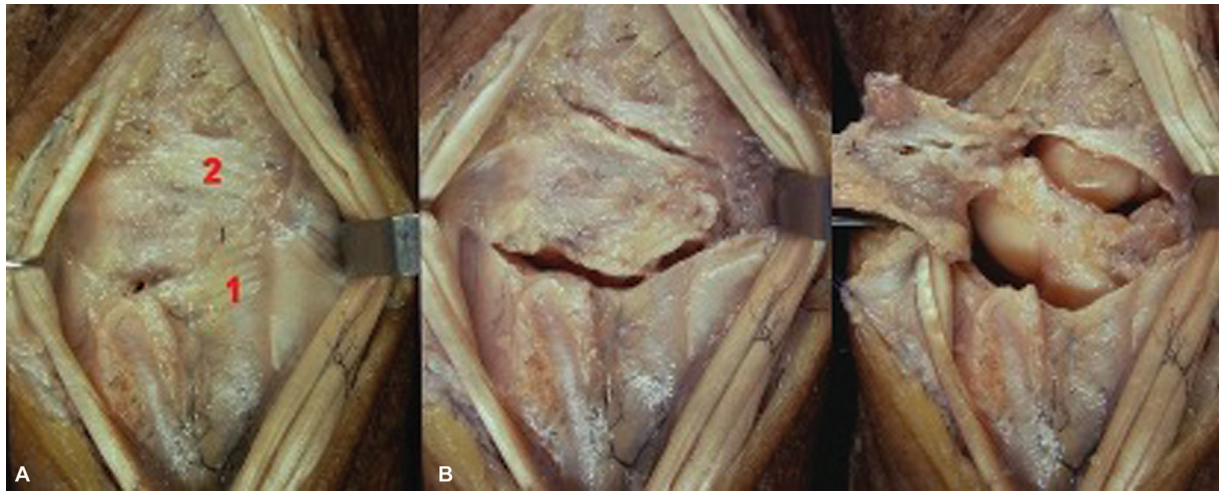
avoiding its neurectomy.<sup>5</sup> It is performed in wrists without degenerative signs, in which denervation is not desired, aiming to maintain proprioception (→ **Figure 4**).

3. “H” capsular flap – with two capsular flaps, radial and ulnar, to expose the carpus. It is used in wrist arthrodesis and the flaps are then used to cover the osteosynthesis material.
4. Distal-based capsular flap, which is used in wrist prostheses, after completing the arthroplasty, capsular reinsertion in the radius with transosseous suture or anchors is performed (→ **Figure 4**).

The carpus is exposed, refreshing the articular surfaces intended for fusion in the case of arthrodesis, and extracting



**Fig. 2** Different types of dorsal capsulotomy. (A) Radial-based capsular flap, described by Berger et al.<sup>5</sup> (B) Proximal-based capsular flap to respect the PIO, described by Hagert et al.<sup>6</sup> (C) “H-shaped” capsular flap, used for arthrodesis. (D) Distal-based capsular flap, used in arthroplasties.



**Fig. 3** Radial base approach (Berger et al.<sup>5</sup>). (A) Dorsal radiopyramidal ligament. (B) Dorsal intercarpal ligament.

cancellous graft from the distal radius through the same incision, if necessary, or resecting the first row of the carpus and osteotomy plus reaming in the case of arthroplasties. After performing the arthrodesis, plane closure and postoperative immobilization are performed.

### Partial Arthrodesis

Partial carpal arthrodesis is a therapeutic alternative for the treatment of all types of arthropathies. This is a procedure capable of reducing pain and eliminating instability, while maintaining the mobility of healthy joints. Selective arthro-

desis of any joint results in a compensatory increase in the mobility of the other joints.<sup>7</sup>

As in any surgical technique, when indicated, we must know the expectations that we can offer the patient so that they understand and accept them. For surgical planning, a radiological study of both wrists must be performed to measure the different angles and carpal height, and, sometimes, a computed tomography (CT) scan to correctly assess the extent of the degenerative arthropathy of the patient.

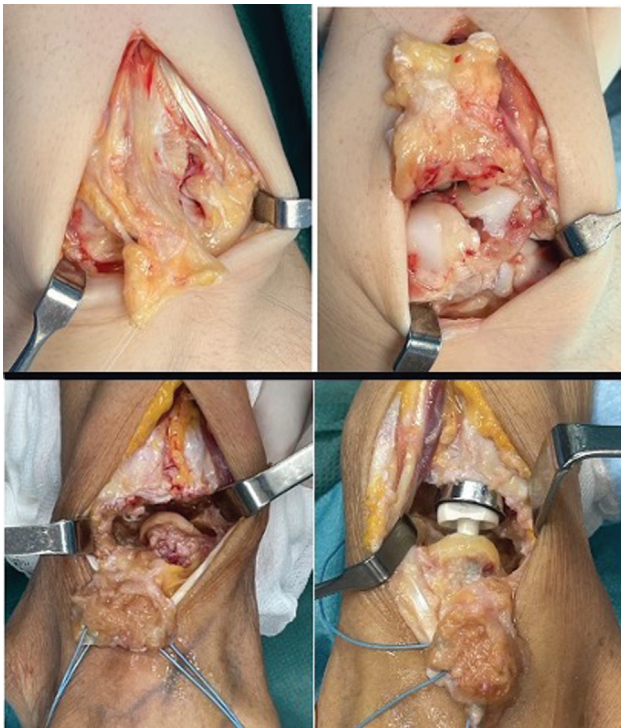
It is advisable to provide bone graft at the arthrodesis sites to avoid losing carpal height. The most commonly used graft is from the ipsilateral distal radius, which enables the performance of this surgery with regional anesthesia. In the case of using an iliac crest graft, general anesthesia is required.

Currently, the trend is to perform these arthrodeses arthroscopically, and various authors<sup>8-10</sup> have published similar results to those obtained through open surgery. Theoretically, arthroscopic surgery offers the advantages of a minimally-invasive approach, reduces the risk of stiffness secondary to dorsal capsulotomy, and increases the consolidation rate due to decreased damage to the neurovascular structures and greater respect for the soft tissues. These are demanding surgical techniques, which require extensive experience in the management of arthroscopy and which, currently, require surgical time equal to or greater than that of open surgery.

Different complications have been described,<sup>11</sup> and the most frequent is the appearance of pseudoarthrosis,<sup>12</sup> although its incidence has decreased thanks to improvements in the surgical technique and osteosynthesis materials.<sup>13</sup>

### Radioscapholunate Arthrodesis

Radioscapholunate (RSL) arthrodesis, described by Gordon and King<sup>14</sup> in 1961, is a palliative surgical technique for wrists with radiocarpal arthritis without involvement of the midcarpal joint, thus preserving some wrist mobility. This mobility, especially in flexion and extension arcs, is distributed between both joints. However, various studies



**Fig. 4** Above is a proximal base capsular approach (Hagert et al.<sup>6</sup>) for the treatment of a scapholunate lesion. Below is a distal base capsular approach for a radiocarpal prosthesis.

conducted on cadavers differ in their assessment of the contribution of each joint to these coordinated movements.<sup>15</sup>

The first series of RSL arthrodesis show a range of motion of around 30 to 40% compared to the normal range.<sup>16,17</sup> In an attempt to improve these results, various surgical procedures have been associated with RSL arthrodesis, such as resection of the distal pole of the scaphoid bone<sup>18</sup> associated or not with excision of the pyramidal bone<sup>19</sup> (►Figure 5). Nevertheless, Holleran et al.<sup>20</sup> published a study on a cadaver comparing RSL arthrodesis isolated or associated with the resection of the distal pole of the scaphoid bone, in which they reported that performing this surgical procedure increases the friction forces between the lunate and the capitate, which usually causes long-term degenerative changes in the midcarpal joint.

The indication for this surgical technique<sup>21</sup> is wrists with painful radiocarpal osteoarthritis, as long as the midcarpal joint is preserved. Among them, the sequelae of intra-articular fractures of the distal radius stand out in frequency (►Figure 6). According to an article published by Knirk and Jupiter,<sup>22</sup> 91% of the cases of this type of fracture with joint incongruity lead to long-term degenerative changes at that level, causing radiocarpal osteoarthritis.

Another common etiology is wrists with scaphoid non-union advanced collapse (SNAC) lesions, characterized by advanced carpal collapse due to scaphoid pseudoarthrosis, or scapholunate advanced collapse (SLAC) lesions,<sup>23</sup> resulting from scapholunate injuries with flexion and pronation instability of the scaphoid, which present with mechanical pain and loss of wrist mobility in all planes. In 1984, Watson and Ballet<sup>24</sup> described SLAC-type injuries as the most frequent cause of degenerative wrist arthritis (55%). In cases of wrists with SNAC or SLAC lesions, RSL arthrodesis is indicated in early stages, since, in more advanced stages, the midcarpal joint is already affected. Likewise, this palliative surgical technique may also be indicated in the initial stages of avascular necrosis of the lunate or

Kienböck disease. Furthermore, this technique is also indicated in arthritic wrists due to deposition or rheumatic diseases.

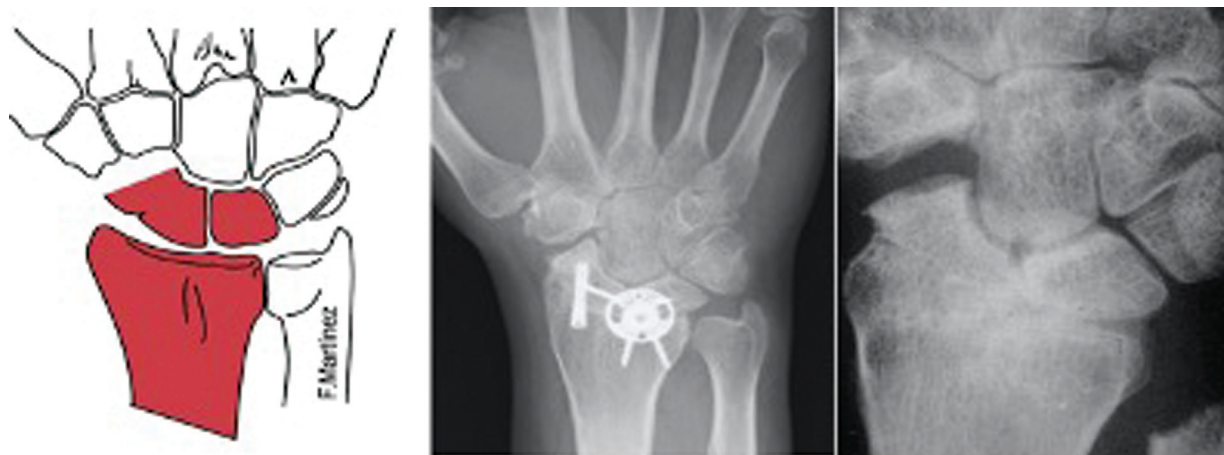The results in the published literature regarding consolidation rates vary depending on the osteosynthesis material used, including Kirschner wires (KWs), T-plates, compression screws, or staples, with cannulated screws showing the highest consolidation rates and fewer complications.<sup>25</sup>

Ulnar translation of the carpus can occur in the advanced stages of a SNAC wrist; it is defined as the condition in which the lunate is in an abnormal position towards the palmar and ulnar edge of the wrist, with less than 50% of its proximal joint surface in contact with the lunar fossa of the radius. In these cases, it is difficult to achieve realignment of the lunate back into its fossa of the radius, making it challenging to perform a proper lunate-capitate fusion or four-corner arthrodesis. Therefore, this arthrodesis is often the best treatment option if total wrist arthrodesis is not chosen.

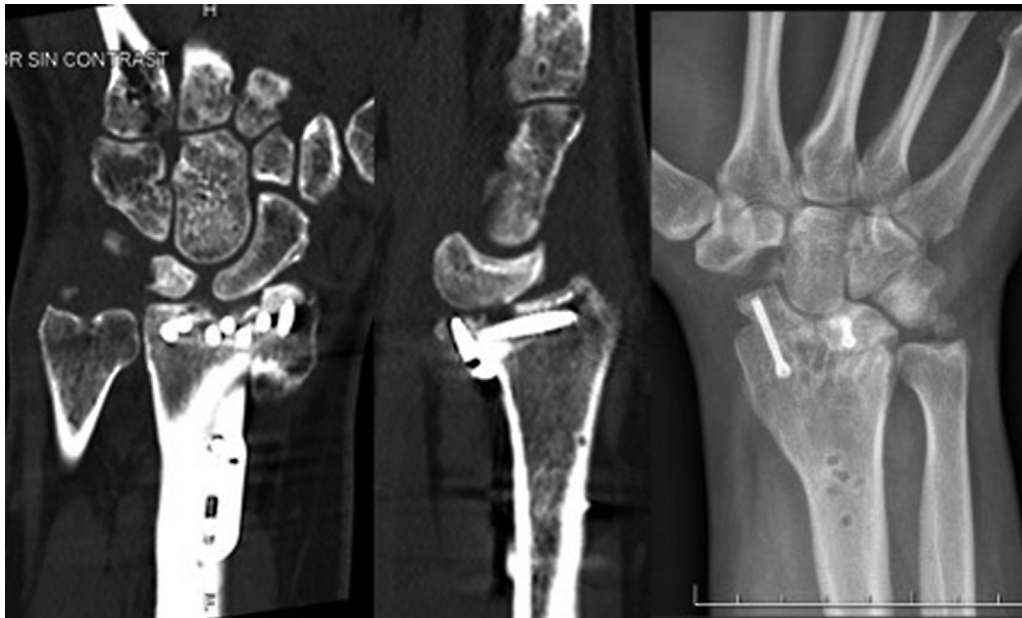As previously mentioned, the main contraindication of this technique is the presence of significant osteoarthritis of the midcarpal joint.

#### Radiolunate arthrodesis

Radiolunate (RL) arthrodesis is indicated in isolated cases of radiolunate osteoarthritis (usually as a sequel to die-punch type distal radius fractures) or in cases of radiocarpal instability with ulnar translation of the joint (►Figure 7). Similarly, RL arthrodesis can be used to prevent volar and ulnar translation of the carpus in patients with rheumatoid arthritis.<sup>26</sup> However, it is contraindicated in those patients with alterations of the lunate-capitate joint, since the mobility of the wrist will depend on this joint once the radius and lunate are fused. We consider that this palliative surgical technique may also be indicated, like the previous one, in the initial stages of avascular necrosis of the lunate or in cases of Kienböck disease in which a large part of the bone is vascularized.



**Fig. 5** Radioscapholunate (RSL) arthrodesis. In the central image, osteosynthesis combined with a circular plate plus compression screw can be observed. On the right, proper consolidation is seen after removal of material; note the distal pole resection of the scaphoid.

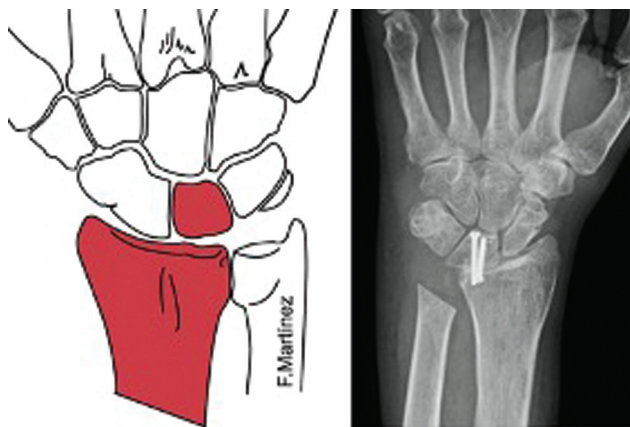


**Fig. 6** Radioscapholunate arthrodesis. The computed tomography (CT) scan shows volar subluxation of the carpus after distal radius fracture with a volar marginal fragment. On the right, RSL arthrodesis is observed after plate removal; note the distal pole resection of the scaphoid.

Motomiya et al.<sup>27</sup> published a series of 22 wrists from 19 patients submitted to RL arthrodesis for the treatment of rheumatoid arthritis. They reported a rate of 100% of consolidation with significant improvement in grip strength and supination capacity. Despite the decrease in the range of flexion and extension at the end of patient follow-up, the degree of patient satisfaction with this technique was very high.

#### Four-Corner Arthrodesis

Four-corner arthrodesis, described by Watson and Ballet in 1984,<sup>24</sup> is a midcarpal arthrodesis that involves the fusion of the articular surfaces of the lunate, capitate, triquetrum and hamate. Its main indication is for SLAC or SNAC wrists with degenerative arthropathy that affects the radioscaphoid and midcarpal joints. It can also be indicated for midcarpal and lunopyramidal instability.<sup>28</sup> Indemnity of the cartilage of the lunate fossa of the radius is required, and magnetic resonance imaging (MRI) is the imaging test of choice to verify it (► **Figure 8**).



**Fig. 7** Radiolunate arthrodesis.

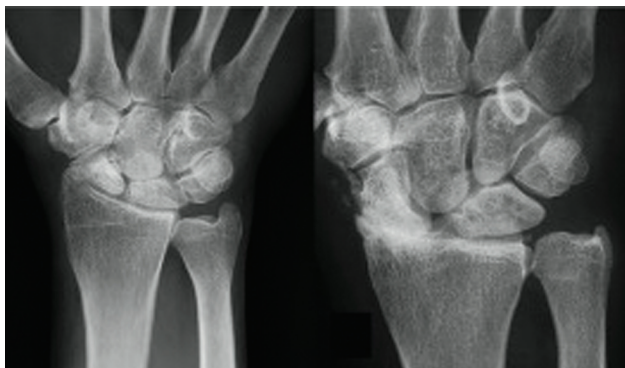
Scaphoid excision is usually associated with four-corner arthrodesis if the patient has an advanced degenerative disease resulting from scapholunate dissociation or scaphoid nonunion (► **Figures 9–10**). Because most of the carpal bones are fused, movement is performed through the radiolunate joint, so the only contraindication to this procedure is radiolunate osteoarthritis.<sup>29</sup>

Excision of the scaphoid and midcarpal fusion enables the suppression of pain while preserving acceptable residual mobility, with good long-term clinical results<sup>30</sup> (► **Figure 11**). In the series by Watson et al.,<sup>31</sup> pain was significantly reduced, and the average range of motion was of 37% flexion and 33% of extension. Krimmer et al.<sup>29</sup> compared the results of four-corner arthrodesis and total wrist arthrodesis in patients with SLAC and SNAC wrists, and concluded that the functional results are better with partial arthrodesis.

Cohen and Kozin<sup>32</sup> studied the effect of four-corner arthrodesis on range of motion; they observed an average extension of 49°, a flexion of 31°, with a 58% flexion-extension arc and a grip strength of 79% compared to the contralateral side. This study demonstrated a greater range of radioulnar deviation compared to proximal carpectomy.

In their review, Lulan et al.<sup>33</sup> describe that the range of wrist mobility is of approximately 50%, but the dart-thrower's movement is eliminated, and this is considered a limitation of the technique; pain decreases by 50 to 60%, and almost half of the patients are pain-free; the strength is of 60 to 80% compared to the contralateral side;<sup>30</sup> the nonunion rate ranges from 3 to 9%. The piriformis can be resected with improved function,<sup>34</sup> but the rate of pseudoarthrosis increases.

Kadji et al.<sup>34</sup> reviewed results published from 1946 to 1993 and concluded that the nonunion rate with four-corner arthrodesis ranged from 4 to 50%, with an average of 8.4%.



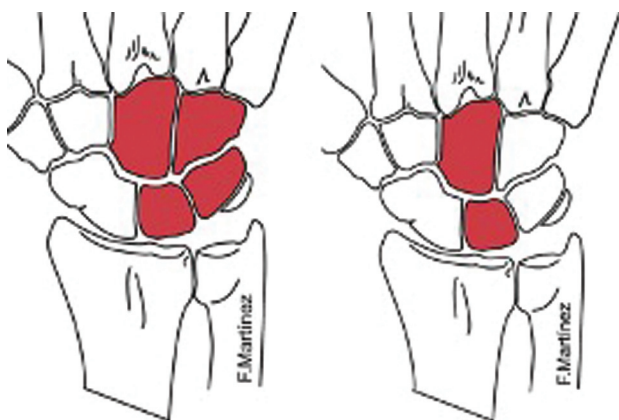
**Fig. 8** On the left, scaphoid nonunion advance collapse (SNAC) wrist, and on the right, scapholunate advance collapse (SLAC) wrist. Integrity of the radiolunate joint, an essential criterion for four-corner arthrodesis.

The technique consists of excision of the scaphoid and fusion of the midcarpal joint (capitate-lunate-pyramidal-hamate) providing bone graft to fuse all the bones together, although more and more publications indicate that it is enough to perform lunate-capitate arthrodesis to generate the necessary stability.

A relevant technical aspect is the correction of the position of the lunate dorsally (dorsal intercalated segment instability, DISI) and fixing it in a neutral position, which is achieved by flexing the wrist and placing a temporary radiolunate needle to avoid dorsal impingement and improve extension, and the contribution of graft to avoid loss of carpal height.

There are various options for fixation in this surgery, though complications associated with plates<sup>35</sup> alongside the promising outcomes reported with percutaneous osteosynthesis using cannulated screws suggest the latter as the optimal choice. Moreover, it enables the arthroscopic implementation of this technique.<sup>19</sup>

Comparing this technique with proximal carpectomy, it has the advantage of preserving the radiolunate joint and maintaining the height of the carpus, which enables the preservation of greater grip strength in these patients (80%).



**Fig. 9** On the left, four-corner arthrodesis and, on the right, lunate-capitate arthrodesis.

Although longer postoperative immobilization times are needed, the percentage of consolidation in series such as the one by Ashmead et al.,<sup>36</sup> with 100 operated patients, was high (97%).

### Lunate-capitate Arthrodesis

The lunate-capitate arthrodesis is a variant of four-corner arthrodesis that preserves its advantages while minimizing its drawbacks. Since fewer bones are fused, there is a reduced risk of complications such as pseudoarthrosis or failure of the material used (► **Figure 8**). The indications and contraindications for lunate-capitate arthrodesis are the same as those of four-corner fusion. In this procedure, like the previous one, the scaphoid must be excised (and the piriformis may also be excised), and then the proposed arthrodesis must be performed<sup>37</sup> (► **Figure 12**).

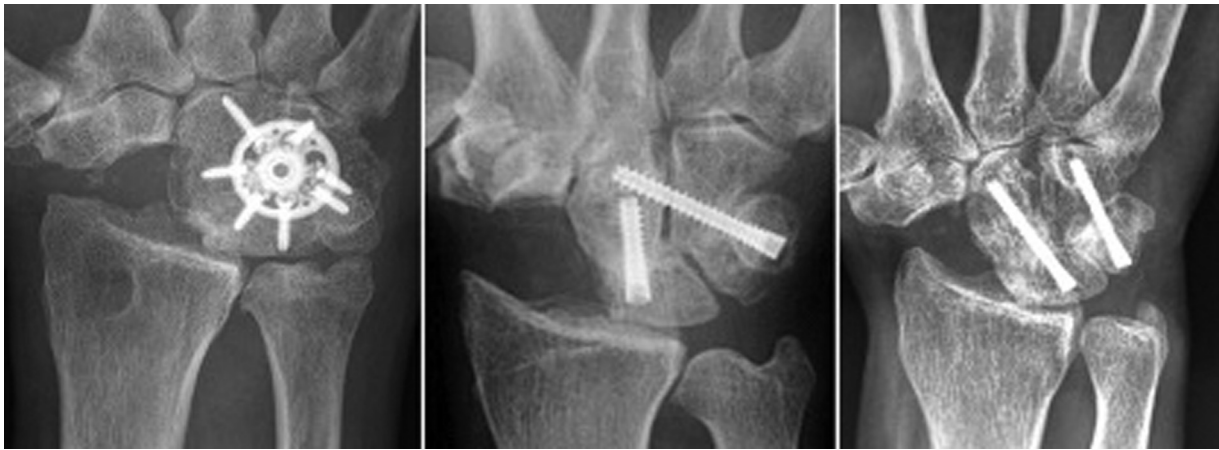The published results regarding bone consolidation are comparable to those of four-corner arthrodesis. Kirschenbaum et al.<sup>38</sup> and Viegas et al.<sup>39</sup> reported a high nonunion rate with this arthrodesis, which, according to the series, can reach 33%. However, lunate-capitate arthrodesis is an effective alternative method to treat SLAC and SNAC wrists, and it has a mean range of flexion-extension motion of 60°. Ferreres et al.<sup>40</sup> studied 17 patients who had been treated with lunate-capitate arthrodesis after a follow-up of 8 to 12 years, and they concluded that the results are similar to those of the four-corner fusion, it is technically easier to perform, and, in addition, it can improve mobility in radioulnar deviation.<sup>41</sup>

Recent studies<sup>76</sup> on the innervation of the radiopyramidal ligament have given importance to preserving the movement of the lunate-pyramidal ligament to maintain proprioception. So, if the lunate-capitate arthrodesis is combined with an excision of the triquetrum in addition to the scaphoid, to gain mobility, the proprioceptive role of the radiopyramidal ligaments may be compromised, which is why we usually do not perform it.

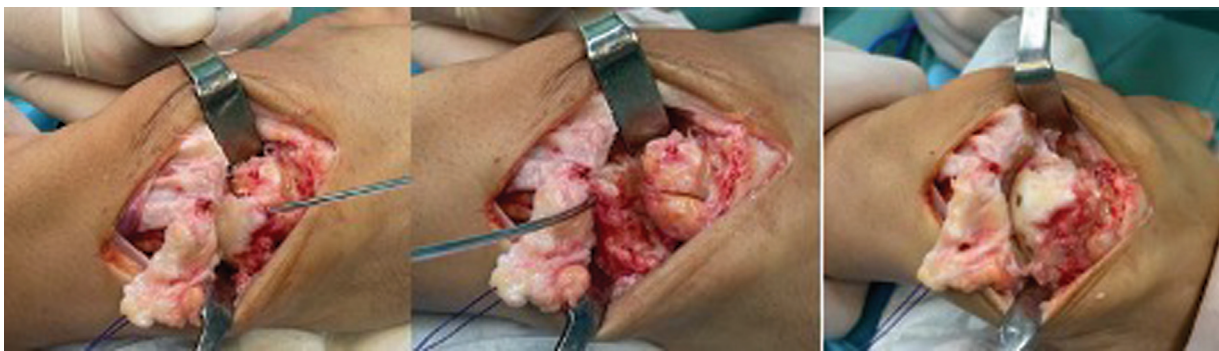### Scaphocapitate Arthrodesis

Scaphocapitate arthrodesis is primarily indicated for chronic scapholunate instability with irreducible rotational subluxation of the scaphoid, stage-1 SLAC wrist if radial styloidectomy is added, scaphoid nonunion, advanced Kienböck disease, and midcarpal instability<sup>31</sup> (► **Figures 13–14**). The contraindications would be alterations in the radioscapoid joint, since performing this surgical technique would aggravate its symptoms.

Mechanically, it is similar to scapho-trapezio-trapezoid (STT) arthrodesis, in which a modification is made in the transmission of loads to unload the lunate and maintain normal carpal alignment, avoiding rotary subluxation of the scaphoid.<sup>42</sup> The results reported in the literature show a predictable improvement in pain and grip strength. This is due to the stabilization of the scaphoid and the relocation of its proximal pole in relation to the scaphoid fossa on the radius.<sup>43</sup> However, this procedure may result in decreased range of motion of the wrist. This reduction occurs due to the restriction of movements of the



**Fig. 10** Clinical cases of four-corner arthrodesis with different types of stabilization.



**Fig. 11** Proximal-based capsular flap to maintain capsular proprioception. A joystick-type needle is placed in the lunate to correct dorsal intercalated segment instability (DISI) and mobilize the lunate to curette the midcarpal joint; graft addition is advised. On the right, result after screw placement.

scaphoid relative to the trapezium during wrist movements, especially in flexion and radial deviation.<sup>39</sup> It is essential to perform the arthrodesis with a radioscapoid angle between 30 and 60°, so that it enables 60% of the movement of a healthy wrist and is sufficient for activities of daily living.<sup>44</sup>

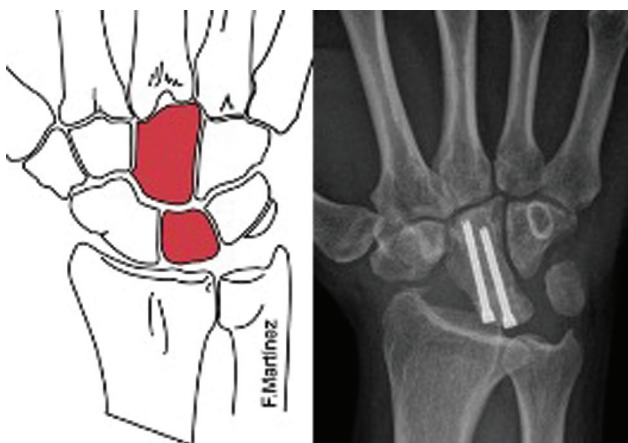
The pseudoarthrosis rate is reported to be between 0 and 23%. The large contact surface between the two bones and the provision of cancellous bone graft enable good consoli-

dation in most cases.<sup>45</sup> No studies provide data supporting the benefits in terms of pain and range of motion of routinely adding styloidectomy, although it is recommended to avoid scaphoid impingement and symptomatic osteoarthritis.

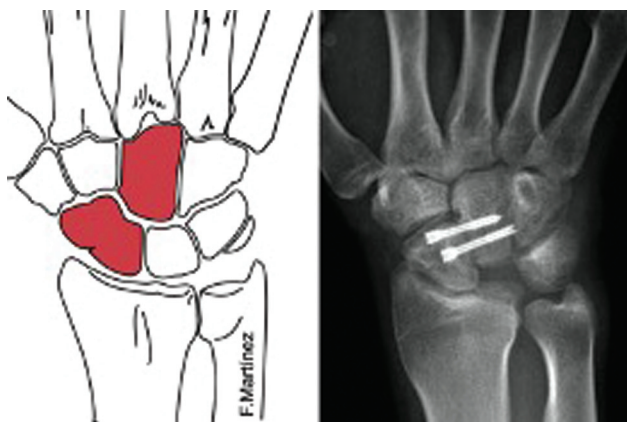
#### Scapho-trapezio-trapezoid Arthrodesis

Scapho-trapezio-trapezoid (STT) arthrodesis, described by Watson and Hempton<sup>46</sup> in 1980, has as its main indications isolated scapho-trapezio-trapezoid osteoarthritis, chronic scapholunate instability with non-reducible rotary subluxation of the scaphoid, and advanced Kienböck disease<sup>31</sup> (→ **Figure 15**). The objective of this arthrodesis is to alter the load transfer across the radiocarpal joint, reducing the loads transmitted to the radiolunate joint (approximately between 35 and 40%) while increasing the loads transmitted to the radioscapoid joint (approximately between 15 and 20%). Similarly, the lunate-capitate joint is unloaded (around 40%), while the scaphocapitate joint is overloaded (around 140%). However, it results in a decrease of 30 to 40% in wrist flexion-extension and 40 to 50% in radialulnar deviation.<sup>47</sup>

The results of STT arthrodesis are controversial. Various authors<sup>48</sup> report good clinical results regarding range of motion, decreased pain and good grip capacity. However, various complications are also reported,<sup>49</sup> such as avascular



**Fig. 12** Lunate-capitate arthrodesis. In this case, in addition to the scaphoid, the pisiform was also resected.



**Fig. 13** Scaphocapitate arthrodesis.

necrosis, progressive carpal instability, styloscapoid impingement and persistence of pain secondary to overload in the radioscaphoid compartment. The average nonunion rate in relevant published studies ranges from 4% for Watson et al<sup>50</sup> to 31% for Goubier et al.<sup>49</sup>

Roger and Watson<sup>51</sup> found a styloid impingement rate of 33%. They attributed this fact to the limitation of the scaphoid to flex when a radial deviation of the wrist occurs, causing impingement. To reduce secondary osteoarthritis and radioscaphoid impact, it is advisable to fuse the scaphoid with a flexion of 40 to 60° and perform a radial styloidectomy. Another possibility in arthritis consists of resecting the distal pole of the scaphoid, with or without associated interposition arthroplasty, and this procedure can be performed using an arthroscopic technique. The most commonly used material for bone fixation is the KW, although screws, staples or plates can be used.<sup>48</sup>

### Scapholunate Arthrodesis

The main indications are scapholunate instability in scapholunate dissociation, non-union fracture of the proximal pole of the scaphoid or scaphoid nonunion (→Figure 16).

The literature on the long-term results of this procedure is scarce,<sup>52</sup> but persistent pain in the wrist and a high rate of nonunion have been reported, reaching 87% in some series<sup>52</sup>, which is related to the retrograde intraosseous vascular flow of the proximal scaphoid, the scarce contact surface, and the difficulty in achieving compression through the fusion area without changing the curvature of the midcarpal joint.<sup>24</sup> Currently, with the clinical and surgical results obtained, its use cannot be recommended.

### Lunotriquetral Arthrodesis

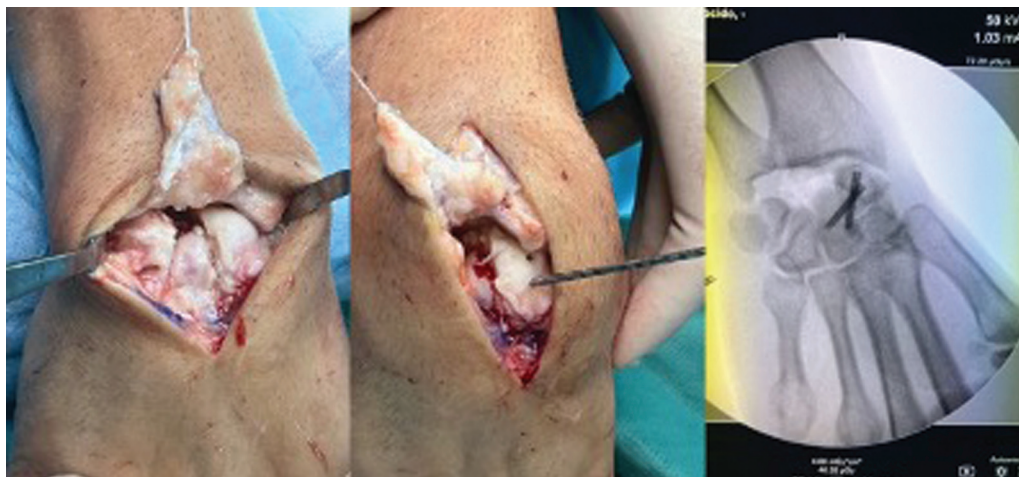Isolated lunotriquetral (LT) arthrodesis is indicated in cases of chronic lunotriquetral instability without associated volar intercalated segment instability (VISI) deformity with persistent pain, in which other procedures have failed, or in patients who have developed early degenerative changes (→Figure 16). Additionally, it is also indicated for rare cases of incomplete degenerative lunotriquetral synostosis.<sup>53</sup>

This arthrodesis is based on the fact that patients with congenital LT coalition are normally asymptomatic, and that under normal circumstances there is little movement between both bones, which means that LT arthrodesis causes minimal loss of mobility.<sup>54</sup> Ambrose and Posner<sup>55</sup> theorize that LT fusion may increase pressure on the triangular fibrocartilage complex and the ulnar head, leading to secondary impaction syndrome.

The material used for bone fixation can be KWs,<sup>54,55</sup> a headless compression screw,<sup>56</sup> or a staple. It is advisable to provide a bone graft given the high risk of nonunion of up to 57% of the cases in the literature.<sup>12,56</sup> The clinical and functional results are unpredictable and variable.<sup>54,56</sup> Due to all this, as well as the best results reported with other procedures, LT arthrodesis should be used with caution.

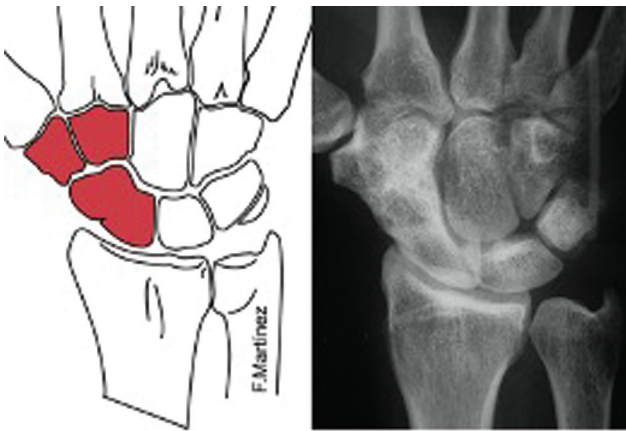
### Pyramidal-hamate Arthrodesis

Pyramidal-hamate arthrodesis is primarily indicated for the treatment of ulnar carpal instability and lunotriquetral



**Fig. 14** Scaphocapitate arthrodesis. Proximal-based capsular flap, resection of the lunate, and scaphocapitate arthrodesis. On the right, fluoroscopic control.



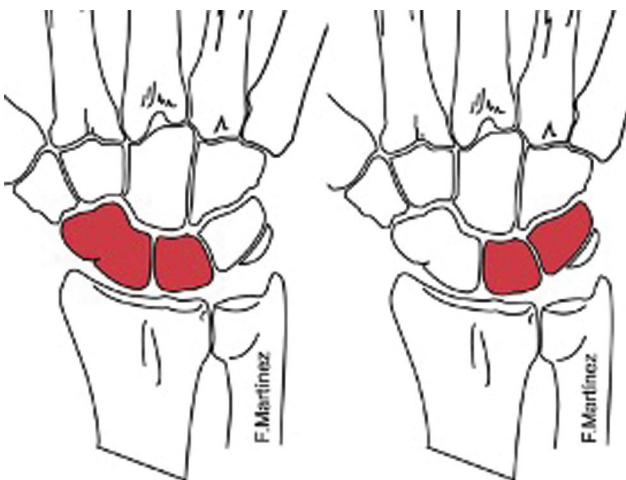


**Fig. 15** Scapho-trapezio-trapezoid arthrodesis. On the right, correct fusion is observed after the removal of the wires.

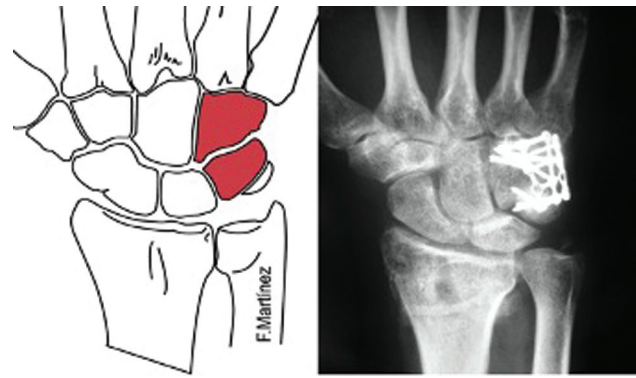
instability with VISI deformity (►Figure 17). Since it restricts midcarpal mobility, it is contraindicated in patients with radiocarpal alterations. Rao and Culver<sup>57</sup> have shown optimal results for palmar midcarpal instability, with 100% of patients being asymptomatic, but the results of dorsal midcarpal instability are less promising, with almost 50% of the patients experiencing persistent symptoms. This isolated arthrodesis is rare, as four-corner arthrodesis is preferred due to its higher union rate and similar range of motion.

### Scaphocapitate Arthrodesis

Scaphocapitate arthrodesis is indicated when there is arthritis affecting the scaphocapitate and lunocapitate joints. This can occur after a trans-scaphoid perilunate dislocation, as well as in cases of avascular necrosis of the capitate bone,<sup>58</sup> although in most instances, the cause is idiopathic. Arthrodesis is performed using screws or plates and usually yields good results, particularly for pain relief and improved wrist stability and grip strength.



**Fig. 16** On the left, scapholunate arthrodesis and, on the right, lunotriquetral arthrodesis.



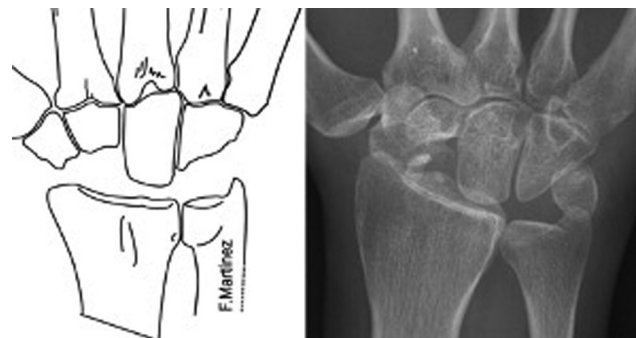
**Fig. 17** Pyramidal-hamate arthrodesis.

### Resection of the First Row of the Carpus

Resection of the first row of carpal bones is a technique performed since the early nineteenth century, which involves creating a new radiocarpal joint between the lunate surface of the radius and the head of the capitate bone (►Figure 18). It is about functionally simplifying a complex joint that is in poor condition.<sup>59</sup> Its indication is important in cases of advanced cartilaginous destruction of the radio-scapholunate joint too severe to benefit from conservative surgeries, such as in the final Watson stages of SNAC or SLAC wrist.<sup>60</sup>

During the intervention, which is carried out through a dorsal approach, the scaphoid, lunate, and triquetrum are resected, while the pisiform is retained. Thus, the capitate bone will act as the lunate, with radial deviation limited by the impact between the radius and the trapezium. Postoperatively, the joint is immobilized for a brief period (3 weeks). Relative contraindications include inflammatory arthropathies and patients performing heavy manual work. When the technique fails, salvage with total arthrodesis can be performed, with the only drawback being a loss of carpal height.

However, this surgery should only be performed if the cartilage of the lunate surface of the radius and the head of the capitate bone are preserved. It is important to note that there will be some joint incongruity between the contact surfaces, leading to increased joint pressure and



**Fig. 18** Resection of the first row of the carpus.

anteroposterior translation of the capitate head during movement, which may result in degenerative joint disease radiologically, although not always clinically correlated.<sup>61</sup>

As a result, we achieve a functional wrist in a few months for social activities and low-demand jobs. There is a decrease in pain, while preserving mobility and maintaining acceptable strength.<sup>62</sup> Compared with four-corner arthrodesis, a better range of motion and lower complication rates are obtained without differences in the conversion rate to total arthrodesis.<sup>63</sup>

In some centers, a resurfacing implant is used at the level of the capitate head, showing an average range of flexion-extension of 65°, radioulnar deviation of 45° and adequate functionality measured with the Quick Disabilities of the Arm, Shoulder and Hand (QuickDASH) questionnaire, which translates into a significant improvement compared to pre-operative values.<sup>64</sup> Furthermore, with this intervention, 20-year survival rates of 65% have been reported with approximately 50% of patients without pain, with worse results in manual workers and young people.<sup>65</sup>

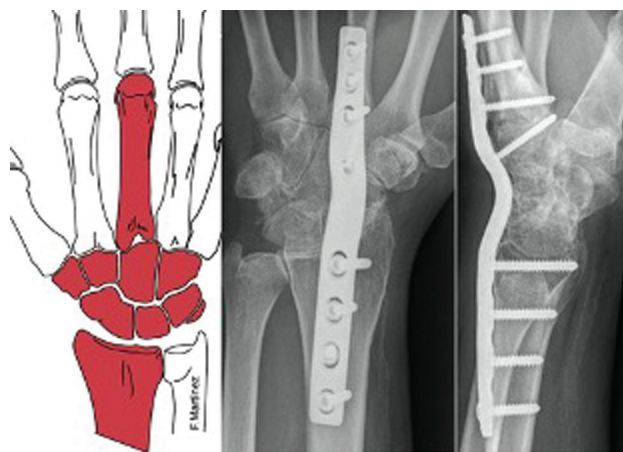
### Total Radiocarpal Arthrodesis

Radiocarpal arthritis is the leading cause of pain, weakness, and functional impairment in the wrist, with distal radius fractures being the most common cause. Around 20% of fractures result in significant arthritis in the radiocarpal and/or distal radioulnar joints, and this figure increases to 65% for intra-articular fractures.<sup>22</sup>

In active patients, when conservative treatment or mobility preservation techniques fail, total wrist arthrodesis has been shown to be a valid option for primary treatment or rescue of partial arthrodesis. This treatment relieves pain and improves function and grip strength.<sup>66</sup> Among the main indications for this technique are idiopathic arthritis, post-traumatic osteoarthritis, inflammatory arthropathies, cerebral palsies, brachial plexus injuries with unstable wrists, congenital deformities, osteonecrosis of the carpal bones (Preiser or Kienböck diseases), SNAC or SLAC wrist, or it can be used as a rescue for previous techniques that have failed.<sup>67</sup>

The presence of active infection, soft tissue coverage defects or the state of open physes represent absolute contraindications for surgery. As relative contraindications, the technique is not recommended in elderly patients with low functional demand (in whom arthroplasty may be a better alternative) or in tetraplegia with modified mobility and clamp patterns.

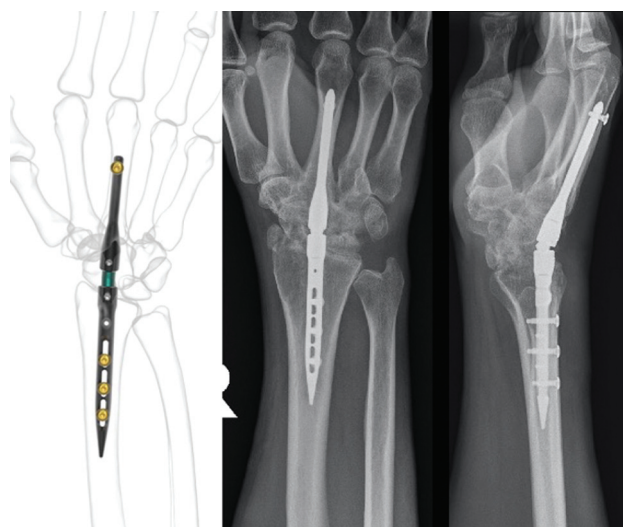
The classic technique involves fixation of the radiocarpal and midcarpal joints using a dorsal plate (► **Figure 19**) or intramedullary nail (► **Figure 20**) extending from the distal third of the radius to the third metacarpal. It is performed through a longitudinal dorsal approach over the Lister tubercle, with opening of the dorsal retinaculum through the third compartment (► **Figure 21**). The extensor pollicis longus tendon is left in the closure between the subcutaneous tissue and the extensor retinaculum to avoid friction with the plate and rupture. Capsulotomy can be performed in an



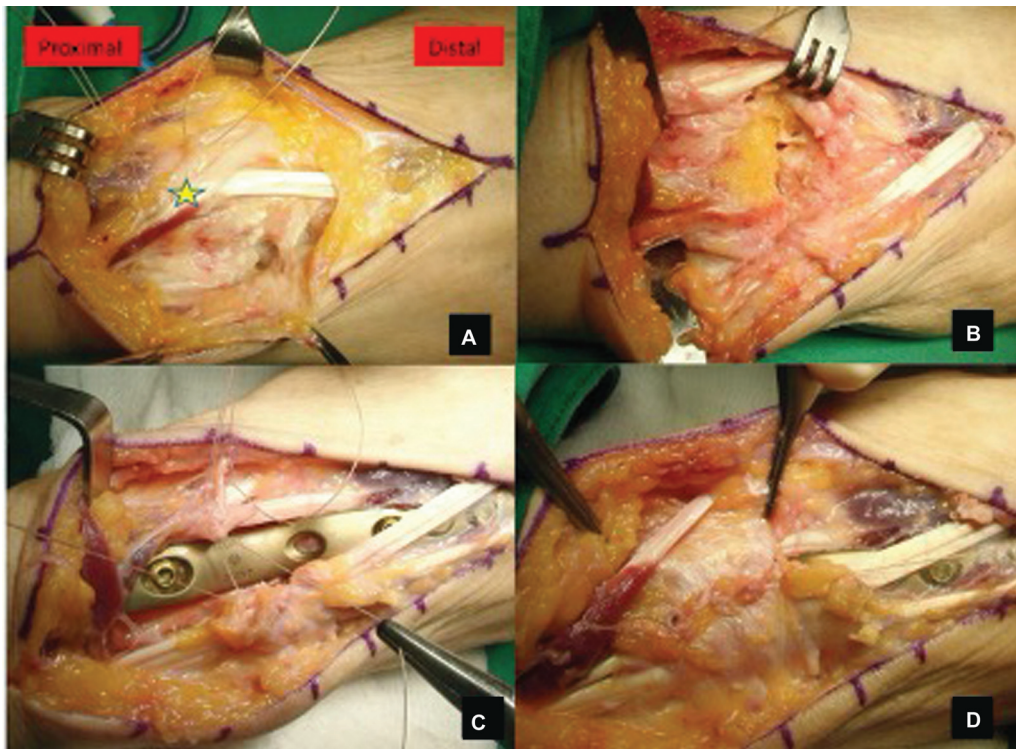
**Fig. 19** Total wrist arthrodesis with fixed-angle plate.

“H” shape with two radial and ulnar capsular flaps, which will then serve to protect the plate in the carpal area. After cartilage excision, graft filling is advised, which can be harvested from the radius or iliac crest. Nowadays, there are premolded fixed-angle dorsal plates that facilitate surgery with minimal extension, placed along the radio-scapho-lunate-capitate-third metacarpal axis. Due to their mechanical stability, they usually do not require postoperative immobilization.<sup>68</sup>

There is some controversy regarding the fusion of the carpometacarpal joint of the third radius. Some authors<sup>69</sup> argue against fusion, as it can be a site of frequent complications and cause pain after plate removal. Preserving this joint enables the preservation of a small degree of hand mobility, including 7° of flexion-extension, 4° of radioulnar deviation, and 5° of pronosupination.<sup>69</sup> Preserving carpometacarpal mobility in the context of total arthrodesis can improve grip strength and fist-making ability, but on the flip side, it can lead to hypermobility and pain due to overloading of this joint in a fused wrist.<sup>70</sup> Additionally, there is a division regarding the position the hand should adopt. Typically, the



**Fig. 20** Total wrist arthrodesis with intramedullary nail.



**Fig. 21** (A) Opening of the dorsal retinaculum at the third compartment (star above the extensor pollicis longus); (B) excision of cartilage and bone grafting; (C) stabilization with fixed-angle plate; and (D) closure of retinaculum not involving extensor pollicis longus.

wrist is placed in slight dorsiflexion and ulnar deviation to optimize grip power. In individuals with bilateral involvement, the non-dominant hand should be positioned in 5 to 10° of flexion to facilitate perineal hygiene.<sup>71</sup>

Total wrist arthrodesis stabilizes the radiocarpal joint, eliminates wrist pain, and enables neighboring joints, both proximal and distal, to perform gripping and palm functions, and it also ensures proper development of the kinematic chain of the upper limb. However, it is important to consider that patients may report difficulties with personal hygiene and working in confined spaces. Nevertheless, despite some expected limitations, patients report high levels of long-term satisfaction.<sup>72</sup>

While the standard procedure is performed openly, it can also be performed through arthroscopy with less damage to the extensor compartments and a better esthetic outcome. According to the technique by Nazerani et al.,<sup>73</sup> the cartilage can be debrided through the radiocarpal and midcarpal portals, and the joints can be fixed using four self-tapping cannulated screws percutaneously under fluoroscopic control.

Alternatively, intramedullary systems are recommended in rheumatic patients and in those with poor soft tissue coverage. Generally, locking pins or intramedullary nails can be used.<sup>74</sup> With this last method of intramedullary fixation, high fusion rates have been reported, reaching 100% in some series, but also high revision rates, especially due to migration of the distal screw.<sup>75</sup>

Among the most common complications that can occur are implant failure, tendon ruptures, and peri-implant fractures. On the other hand, some patients do not become accustomed to a non-mobile wrist and continue to experience reduced function and persistent pain. Therefore, whenever possible, motion-preserving surgery should be offered before total arthrodesis. And among the total fixation techniques, the surgeon must make a correct indication and consider the risks and benefits of each alternative for each individual patient.<sup>67</sup>

#### Conflict of Interests

The authors have no conflict of interests to declare.

#### References

- Palmer AK, Werner FW, Murphy D, Glisson R. Functional wrist motion: a biomechanical study. *J Hand Surg Am* 1985;10(01): 39–46
- Ryu JY, Cooney WP III, Askew LJ, An KN, Chao EY. Functional ranges of motion of the wrist joint. *J Hand Surg Am* 1991;16(03): 409–419
- Nelson DL. Functional wrist motion. *Hand Clin* 1997;13(01): 83–92
- Adams BD, Grosland NM, Murphy DM, McCullough M. Impact of impaired wrist motion on hand and upper-extremity performance(1). *J Hand Surg Am* 2003;28(06):898–903
- Berger RA, Bishop AT, Bettinger PC. New dorsal capsulotomy for the surgical exposure of the wrist. *Ann Plast Surg* 1995;35(01): 54–59

- 6 Hagert E, Ferreres A, Garcia-Elias M. Nerve-sparing dorsal and volar approaches to the radiocarpal joint. *J Hand Surg Am* 2010;35(07):1070–1074
- 7 Watson HK, Goodman ML, Johnson TR. Limited wrist arthrodesis. Part II: Intercarpal and radiocarpal combinations. *J Hand Surg Am* 1981;6(03):223–233
- 8 Baur EM. Arthroscopic-Assisted Partial Wrist Arthrodesis. *Hand Clin* 2017;33(04):735–753
- 9 de Villeneuve Bargemon JB, Peras M, Hasegawa H, Levadoux M. Arthroscopic Scaphocapitate Fusion: Surgical Technique. *Arthrosc Tech* 2022;11(07):e1289–e1294
- 10 Ho PC. Arthroscopic partial wrist fusion. *Tech Hand Up Extrem Surg* 2008;12(04):242–265
- 11 Siegel JM, Ruby LK. A critical look at intercarpal arthrodesis: review of the literature. *J Hand Surg Am* 1996;21(04):717–723
- 12 Vandesande W, De Smet L, Van Ransbeeck H. Lunotriquetral arthrodesis, a procedure with a high failure rate. *Acta Orthop Belg* 2001;67(04):361–367
- 13 Hastings H II, Weiss AP, Quenzer D, Wiedeman GP, Hanington KR, Strickland JW. Arthrodesis of the wrist for post-traumatic disorders. *J Bone Joint Surg Am* 1996;78(06):897–902
- 14 Gordon LH, King D. Partial wrist arthrodesis for old un-united fractures of the carpal navicular. *Am J Surg* 1961;102(03):460–464
- 15 Kobayashi M, Berger RA, Nagy L, et al. Normal kinematics of carpal bones: a three-dimensional analysis of carpal bone motion relative to the radius. *J Biomech* 1997;30(08):787–793
- 16 Bain GI, Watts AC. The outcome of scaphoid excision and four-corner arthrodesis for advanced carpal collapse at a minimum of ten years. *J Hand Surg Am* 2010;35(05):719–725
- 17 Calfee RP, Leventhal EL, Wilkerson J, Moore DC, Akelman E, Crisco JJ. Simulated radioscapulohumeral fusion alters carpal kinematics while preserving dart-thrower's motion. *J Hand Surg Am* 2008;33(04):503–510
- 18 Kraissarin J, Dennison DG, Berglund LJ, An KN, Shin AY. Biomechanical comparison of three fixation techniques used for four-corner arthrodesis. *J Hand Surg Eur Vol* 2011;36(07):560–567
- 19 Ozyurekoglu T, Türker T. Results of a method of 4-corner arthrodesis using headless compression screws. *J Hand Surg Am* 2012;37(03):486–492
- 20 Holleran AM, Quigley RJ, Rafiqah GH, Lee TQ. Radioscapholunate arthrodesis with excision of the distal scaphoid: comparison of contact characteristics to the intact wrist. *J Hand Surg Am* 2013;38(04):706–711
- 21 Inoue G, Tamura Y. Radiolunate and radioscapulohumeral arthrodesis. *Arch Orthop Trauma Surg* 1992;111(06):333–335
- 22 Knirk JL, Jupiter JB. Intra-articular fractures of the distal end of the radius in young adults. *J Bone Joint Surg Am* 1986;68(05):647–659
- 23 Strauch RJ. Scapholunate advanced collapse and scaphoid non-union advanced collapse arthritis—update on evaluation and treatment. *J Hand Surg Am* 2011;36(04):729–735
- 24 Watson HK, Ballet FL. The SLAC wrist: scapholunate advanced collapse pattern of degenerative arthritis. *J Hand Surg Am* 1984;9(03):358–365
- 25 Biswas D, Wysocki RW, Cohen MS, Fernandez JJ. Radioscapholunate arthrodesis with compression screws and local autograft. *J Hand Surg Am* 2013;38(04):788–794
- 26 Linscheid RL, Dobyns JH. Radiolunate arthrodesis. *J Hand Surg Am* 1985;10(6 Pt 1):821–829
- 27 Motomiya M, Iwasaki N, Minami A, Matsui Y, Urita A, Funakoshi T. Clinical and radiological results of radiolunate arthrodesis for rheumatoid arthritis: 22 wrists followed for an average of 7 years. *J Hand Surg Am* 2013;38(08):1484–1491
- 28 Bain GI, McGuire DT. Decision making for partial carpal fusions. *J Wrist Surg* 2012;1(02):103–114
- 29 Krimmer H, Krapohl B, Sauerbier M, Hahn P. [Post-traumatic carpal collapse (SLAC- and SNAC-wrist)—stage classification and therapeutic possibilities]. *Handchir Mikrochir Plast Chir* 1997;29(05):228–233
- 30 Neubrech F, Mühlendorfer-Fodor M, Pillukat T, Schoonhoven Jv, Prommersberger KJ. Long-term results after midcarpal arthrodesis. *J Wrist Surg* 2012;1(02):123–128
- 31 Watson HK, Weinzweig J, Guidera PM, Zeppleri J, Ashmead D. One thousand intercarpal arthrodeses. *J Hand Surg [Br]* 1999;24(03):307–315
- 32 Cohen MS, Kozin SH. Degenerative arthritis of the wrist: proximal row carpectomy versus scaphoid excision and four-corner arthrodesis. *J Hand Surg Am* 2001;26(01):94–104
- 33 Laulan J, Marteau E, Bacle G. Wrist osteoarthritis. *Orthop Traumatol Surg Res* 2015;101(01):S1–S9
- 34 Kadji O, Duteille F, Dautel G, Merle M. [Four bone versus capitohumeral limited carpal fusion. Report of 40 cases]. *Chir Main* 2002;21(01):5–12
- 35 Shindle MK, Burton KJ, Weiland AJ, Domb BG, Wolfe SW. Complications of circular plate fixation for four-corner arthrodesis. *J Hand Surg Eur Vol* 2007;32(01):50–53
- 36 Ashmead D IV, Watson HK, Damon C, Herber S, Paly W. Scapholunate advanced collapse wrist salvage. *J Hand Surg Am* 1994;19(05):741–750
- 37 Delattre O, Dupont P, Reau AF, Rouvillain JL, Mousselard H, Catonné Y [Shortening arthrodesis of three wrist bones]. *Ann Chir Main Memb Super* 1997;16(04):292–299
- 38 Kirschenbaum D, Schneider LH, Kirkpatrick WH, Adams DC, Cody RP. Scaphoid excision and capitohumeral arthrodesis for radioscapulohumeral arthritis. *J Hand Surg Am* 1993;18(05):780–785
- 39 Viegas SF, Patterson RM, Peterson PD, et al. Evaluation of the biomechanical efficacy of limited intercarpal fusions for the treatment of scapho-lunate dissociation. *J Hand Surg Am* 1990;15(01):120–128
- 40 Ferreres A, Garcia-Elias M, Plaza R. Long-term results of lunocapitate arthrodesis with scaphoid excision for SLAC and SNAC wrists. *J Hand Surg Eur Vol* 2009;34(05):603–608
- 41 van Riet RP, Bain GI. Three-corner wrist fusion using memory staples. *Tech Hand Up Extrem Surg* 2006;10(04):259–264
- 42 Moy OJ, Peimer CA. Scaphocapitate fusion in the treatment of Kienböck's disease. *Hand Clin* 1993;9(03):501–504
- 43 Luegmair M, Saffar P. Scaphocapitate arthrodesis for treatment of scapholunate instability in manual workers. *J Hand Surg Am* 2013;38(05):878–886
- 44 Minamikawa Y, Peimer CA, Yamaguchi T, Medige J, Sherwin FS. Ideal scaphoid angle for intercarpal arthrodesis. *J Hand Surg Am* 1992;17(02):370–375
- 45 Delétang F, Segret J, Dap F, Dautel G. Chronic scapholunate instability treated by scaphocapitate fusion: a midterm outcome perspective. *Orthop Traumatol Surg Res* 2011;97(02):164–171
- 46 Watson HK, Hempton RF. Limited wrist arthrodeses. I. The triscapephoid joint. *J Hand Surg Am* 1980;5(04):320–327
- 47 Gellman H, Kauffman D, Lenihan M, Botte MJ, Sarmiento A. An in vitro analysis of wrist motion: the effect of limited intercarpal arthrodesis and the contributions of the radiocarpal and midcarpal joints. *J Hand Surg Am* 1988;13(03):378–383
- 48 Cholley-Rouilleau M, Dap F, Dautel G, Athlani L. Scaphotrapezotrapezoid arthrodesis for isolated osteoarthritis: results at a mean 8 years' follow-up. *Hand Surg Rehabil* 2021;40(05):602–608
- 49 Goubier JN, Bauer B, Alnot JY, Teboul F. Traitement de l'arthrose scaphotrapézotrapézoidienne isolée par arthrodèse scaphotrapézotrapézoidienne: une série de 13 cas. *Chir Main* 2006;25(05):179–184
- 50 Watson HK, Wollstein R, Joseph E, Manzo R, Weinzweig J, Ashmead D IV. Scaphotrapezotrapezoid arthrodesis: a follow-up study. *J Hand Surg Am* 2003;28(03):397–404
- 51 Rogers WD, Watson HK. Radial styloid impingement after triscapephoid arthrodesis. *J Hand Surg Am* 1989;14(2 Pt 1):297–301

- 52 Zubairy AI, Jones WA. Scapholunate fusion in chronic symptomatic scapholunate instability. *J Hand Surg [Br]* 2003;28(04):311–314
- 53 Kirschenbaum D, Coyle MP, Leddy JP. Chronic lunotriquetral instability: diagnosis and treatment. *J Hand Surg Am* 1993;18(06):1107–1112
- 54 Guidera PM, Watson HK, Dwyer TA, Orlando G, Zeppieri J, Yasuda M. Lunotriquetral arthrodesis using cancellous bone graft. *J Hand Surg Am* 2001;26(03):422–427
- 55 Ambrose L, Posner MA. Lunate-triquetral and midcarpal joint instability. *Hand Clin* 1992;8(04):653–668
- 56 Sennwald GR, Fischer M, Mondy P. Lunotriquetral arthrodesis. A controversial procedure. *J Hand Surg [Br]* 1995;20(06):755–760
- 57 Sb R, Je C. Triquetrum arthrodesis for midcarpal instability. *The Journal of hand surgery [Internet]*. julio de 1995 [citado 21 de marzo de 2024];20(4). Disponible en: <https://pubmed.ncbi.nlm.nih.gov/7594284/>
- 58 Milliez PY, Kinh Kha H, Allieu Y, Thomine JM. [Idiopathic aseptic osteonecrosis of the capitate bone. Literature review apropos of 3 new cases]. *Int Orthop* 1991;15(02):85–94
- 59 Alnot JY, Apredoaei C, Frot B. Resection of the proximal row of the carpus. A review of 45 cases. *Int Orthop* 1997;21(03):145–150
- 60 Lane R, Tafti D, Varacallo M. Scapholunate Advanced Collapse. En: *StatPearls [Internet]*. Treasure Island (FL): StatPearls Publishing;2024 [citado 17 de marzo de 2024]. Disponible en: <http://www.ncbi.nlm.nih.gov/books/NBK537124/>
- 61 Tang P, Wei DH, Ueba H, Gardner TR, Rosenwasser MP. Scaphoid excision and 4-bone arthrodesis versus proximal row carpectomy: a comparison of contact biomechanics. *J Hand Surg Am* 2012;37(09):1861–1867
- 62 Welby F, Alnot JY. La résection de la première rangée des os du carpe: poignet post-traumatique et maladie de Kienböck. *Chir Main* 2003;22(03):148–153
- 63 Chammas PE, Hadouiri N, Chammas M, et al. Proximal row carpectomy generates better mid- to long-term outcomes than four-corner arthrodesis for post-traumatic wrist arthritis: A meta-analysis. *Orthop Traumatol Surg Res* 2022;108(07):103373
- 64 Pelet H, Delgove A, Morchikh A, et al. Long-term results of first row carpectomy with proximal capitate resurfacing using a pyrocarbon implant. *J Hand Surg Eur Vol* 2023;48(06):561–565
- 65 Wall LB, Didonna ML, Kiefhaber TR, Stern PJ. Proximal row carpectomy: minimum 20-year follow-up. *J Hand Surg Am* 2013;38(08):1498–1504
- 66 Berber O, Garagnani L, Gidwani S. Systematic Review of Total Wrist Arthroplasty and Arthrodesis in Wrist Arthritis. *J Wrist Surg* 2018;7(05):424–440
- 67 Rodriguezmerchan EC, Tabeayo Alvarez E, Shojaei B, Kachooei A. Total Wrist Arthrodesis: An Update on Indications Technique and Outcomes. *ABJS* 2023;11(03):
- 68 Lulan J, Bacle G, de Bodman C, et al. The arthritic wrist. II—the degenerative wrist: indications for different surgical treatments. *Orthop Traumatol Surg Res* 2011;97(04):S37–S41
- 69 El-Shennawy M, Nakamura K, Patterson RM, Viegas SF. Three-dimensional kinematic analysis of the second through fifth carpometacarpal joints. *J Hand Surg Am* 2001;26(06):1030–1035
- 70 Owen DH, Perriman DM, Policinski I, Damiani M, Smith PN, Roberts CJ. Total wrist arthrodesis with and without arthrodesis of the carpoMetacarpal joint (WAWWAM): study protocol. *BMC Musculoskelet Disord* 2021;22(01):766
- 71 Hayden RJ, Jebson PJJ. Wrist arthrodesis. *Hand Clin* 2005;21(04):631–640
- 72 Smith MB, Stirling PHC, McEachan JE. Long-term functional outcomes after total wrist arthrodesis. *Hand Surg Rehabil* 2022;41(05):595–598
- 73 Nazerani S, Nazerani T, Molayem A, Keramati MR. A Modified Surgical Technique for Minimally Invasive Arthroscopic Total Wrist Fusion. *J Wrist Surg* 2019;8(01):84–88
- 74 Orbay JL, Feliciano E, Orbay C. Locked intramedullary total wrist arthrodesis. *J Wrist Surg* 2012;1(02):179–184
- 75 Walker MR, Hoben GM, Best CM, Daley RA. Early Experience With Locked Intramedullary Wrist Arthrodesis. *J Hand Surg Am* 2021;46(07):620.e1–620.e6
- 76 Lluch A, Salvà G, Esplugas M, Llusà M, Hagert E, Garcia-Elias M. El papel de la propiocepción y el control neuromuscular en las inestabilidades del carpo. *Revista Iberoamericana de Cirugía de la Mano*. 2015;43(01):70–78