



Versatility of the Keystone Design Perforator Island Flaps in Resurfacing Soft Tissue Defects

Ranjit Kumar Sahu¹ Kaushik Mahadik¹ Sanjay Kumar Giri¹ Santanu Suba¹ Mainak Mallik¹
Ritesh Panda² Aparna Kanungo¹ Reena Minz¹ Sunil Kumar Rout³

¹Department of Burns and Plastic Surgery, All India Institute of Medical Sciences, Bhubaneswar, Odisha, India

²Department of Trauma & Emergency, All India Institute of Medical Sciences, Bhubaneswar, Odisha, India

³Department of Plastic and Reconstructive Surgery, Kalinga Institute of Medical Sciences, Bhubaneswar, Odisha, India

Address for correspondence Kaushik Mahadik, MBBS, MS, MCh, Department of Burns and Plastic Surgery, All India Institute of Medical Sciences, Sijua, Patrapada, Bhubaneswar 751019, Odisha, India (e-mail: drkaushikmahadik@gmail.com).

Indian J Plast Surg

Abstract

Background The keystone design perforator island flap (KDPIF) is unique among local flaps because of its high potential for adaptation. We describe our experience with the use of the keystone flap for the reconstruction of a variety of defects in different regions of the body concerning its versatility, surgical outcomes, complications, postoperative pain, operative time, and esthetic outcomes.

Methods A prospective observational study was conducted at our institute from June 2021 to June 2023 where the use of KDPIFs in resurfacing soft tissue defects of different etiopathogenesis was evaluated and the data were analyzed.

Results Forty-four patients were included in the study with soft tissue defects of various etiologies and at different locations. The largest flap raised was 18 × 10 cm and the smallest was 4 × 2 cm. The average intraoperative time for completion of the procedure was 74.86 minutes (range: 45–120 minutes). The success rate of flap survivability was 95.45% with two patients having total flap loss necessitating another reconstructive option. Partial flap dehiscence which healed secondarily was observed in two patients. Postoperative pain showed a significant fall of 83.7% from baseline and 82.9% of cases were extremely satisfied with the esthetic outcome.

Conclusion The keystone flap is a valuable reconstructive tool in the armamentarium of a plastic surgeon. It is technically reproducible, suitable to be done in resource-limited settings, and provides contiguous tissue with good vascularity and fewer complications.

Keywords

- ▶ keystone flap
- ▶ island flap
- ▶ local flap'

Introduction

The keystone design perforator island flap was first described by Felix C. Behan, an Australian plastic surgeon in 2003

where it was used to resurface defects mainly following the excision of skin tumors particularly melanoma.¹ It was named after its architectural counterpart that locks and supports the weight of arches, similarly the flap locks into

DOI <https://doi.org/10.1055/s-0044-1787177>.
ISSN 0970-0358.

© 2024. Association of Plastic Surgeons of India. All rights reserved. This is an open access article published by Thieme under the terms of the Creative Commons Attribution-NonDerivative-NonCommercial-License, permitting copying and reproduction so long as the original work is given appropriate credit. Contents may not be used for commercial purposes, or adapted, remixed, transformed or built upon. (<https://creativecommons.org/licenses/by-nc-nd/4.0/>)

Thieme Medical and Scientific Publishers Pvt. Ltd., A-12, 2nd Floor, Sector 2, Noida-201301 UP, India

Table 1 Types of keystone flaps

Type 1	Standard design
Type 2a Type 2b	Incising the deep fascia (a—secondary defect closed primarily, b—secondary defect requires skin graft)
Type 3	Double opposing keystone flaps
Type 4	Undermining of the flap up to a maximum of two-thirds of the flap dimension

and supports the defect by distributing tension evenly.² Since then this flap has been used extensively for resurfacing defects of various sizes occurring due to different etiologies almost all over the body.³ Being a local flap that replaces “like with like” tissue for reconstruction, it is not only technically simple to design and execute but also has good postoperative functional and esthetic outcomes.⁴

There are four types of keystone flaps described with several modifications which can be customized and designed according to the defect characteristics and location.¹ However, the applicability of which type of flap is most suitable for a particular defect region is ambiguous and depends on various factors such as surrounding skin laxity and mobility. The use of this flap particularly for large defects with deficient high-quality surrounding skin is associated with tension at the suture line toward the advancing edge of the flap despite having V-Y flaps laterally to aid in mobility.⁵ Furthermore, validation of reduced pain and esthetic evaluation of the flap has not been well documented.

There are four types of keystone flaps as described by Behan¹ (►Table 1). The decision of where to use which type of keystone flap is dependent on the tissue characteristics such as laxity and expansibility of skin adjacent to the defect. With this study, we have attempted to characterize which type of keystone flap is suitable for a particular region of the body by applying this technique for resurfacing a wide range of defects in various anatomical regions and analyzing the outcomes in terms of the success rate of flap survival and complications. A descriptive assessment of the flap characteristics along with operative time duration, postoperative pain, and esthetic outcomes was included to provide a comprehensive appraisal of the keystone flap.

Patients and Methods

Data from patients who underwent the keystone flap technique at our institute after informed consent were prospectively collected and analyzed for a period of 2 years between July 2021 and June 2023. Exclusion criteria were grossly infected wounds, postirradiation wound defects, extensive cicatrization of donor areas, and areas with less skin laxity which precluded the design of this flap. Apart from patient demographics, the defect etiology, defect location, flap dimensions, type of keystone flap used, the operative time duration in minutes, and outcome of the flap were recorded and tabulated. Total flap loss necessitating another reconstructive option at the end of 1 week was considered a failure of flap

surgery. Minor complications such as partial wound dehiscence which could be managed by secondary suturing was considered a successful result. The minimum follow-up period for all patients was 3 months postsurgery. Pain perception was analyzed and tabulated using the visual analog scale (VAS).⁶ Esthetic satisfaction was subjectively assessed using the Likert scale⁷ on postoperative day 1, postoperative day 7, postoperative day 21, and at 3 months follow-up.

Surgical Technique

Patients were operated on under general or local anesthesia according to feasibility. Excision of the defect was performed in an elliptical manner. The flap was designed based on the defect characteristics over the adjacent area having maximum skin laxity with the lateral lines directed perpendicular to the defect with the width of the flap being equal to 1.5 to 2 times that of the defect (►Fig. 1). After dissection and elevation of the flap, suturing was done in two layers using absorbable inverted deep dermal sutures followed by non-absorbable monofilament sutures. The first suture was taken at the leading edge of the flap which is also the area of maximum tension and the lateral portions of the flap were closed as V-Y advancements. Modifications to this standard design like incising the fascia, double opposing flaps, and undermining of flap restricted to less than 50% were done depending on the defect size and location to aid in the mobility of the flap.

Results

Forty-four patients ($N=44$) were included in our study out of which 31 were males and 13 were females, age ranging from 12 to 70 years with an average age of 38.18 years. Etiology of the defects were 24 cases following trauma (54.54%) which included patients with chronic traumatic nonhealing ulcers and defects with exposed bone or hardware, 13 patients (29.54%) had defects following excision of tumors such as lymphangioma circumscriptum, nevus, and low-grade basal cell carcinoma, 4 patients (9.09%) required resurfacing of pressure ulcers over the sacral region, and 3 patients (6.81%) had post-infective soft tissue defects following debridement (►Table 2).

According to the body regions, 7 keystone flaps were done for head and neck defects, 5 for anterior trunk defects over the chest and abdomen, 10 for posterior trunk defects including lower back, 3 for upper limb defects, and 19 flaps for lower limb defects. The largest flap raised was 18 × 10 cm and the smallest flap was 4 × 2 cm in dimensions. Concerning the type of keystone flap, 10 flaps were type 1 (22.72%), 13 flaps were type 2a (29.54%), 3 flaps were type 2b necessitating skin grafting for the secondary defect (6.81%), 15 flaps were type 3 (34.09%), and 3 flaps were type 4 (6.81%). The average operative duration was 74.86 minutes (range: 45–120 minutes).

Out of the 44 flaps, 2 flaps had complete necrosis necessitating debridement and reconstruction using another technique. Two patients developed partial wound dehiscence which healed secondarily within 3 weeks and hence was not considered a failure of flap surgery. Thus, the success rate in terms of flap survival was 95.45%. The mean pain VAS score

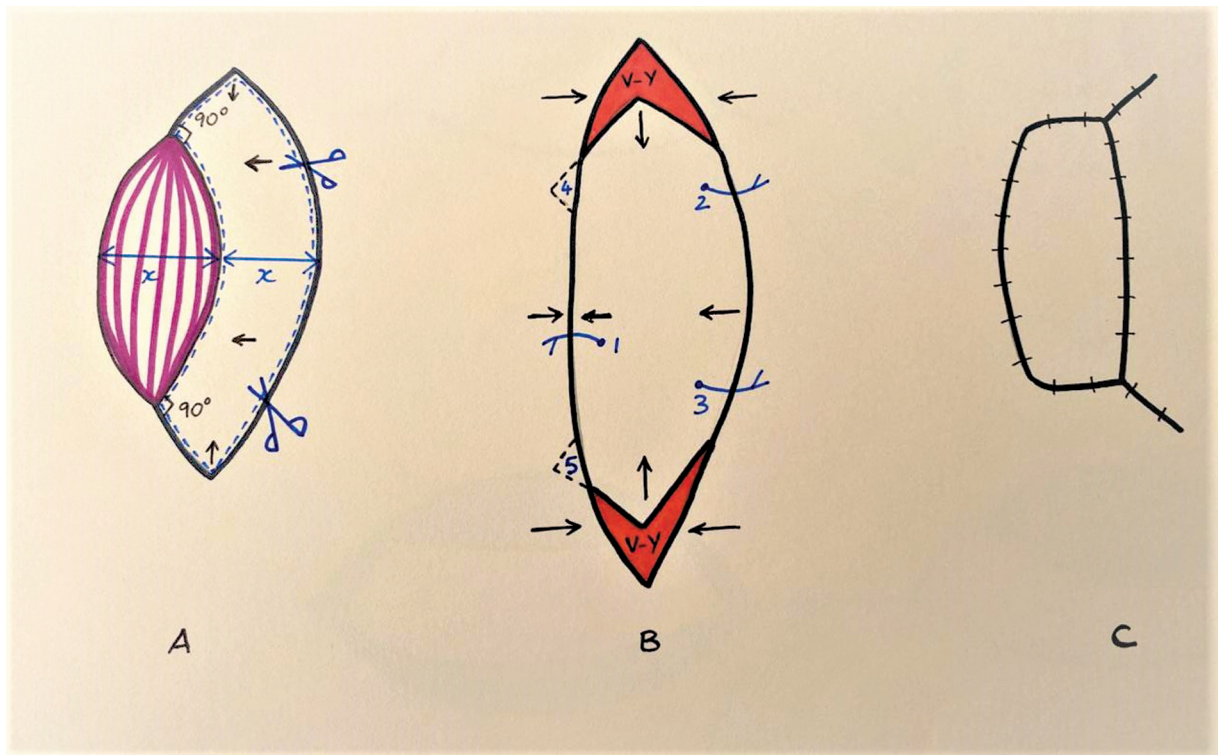


Fig. 1 (A–C) Keystone flap design.

Table 2 Demographic characteristics of patients including flap outcome

Case no.	Age/sex	Etiology	Defect location	Flap dimension (cm)	Type of KF	Operative time (min)	Outcome
1	14/F	Tumor excision	Trunk-P	7 × 5	2a	90	Healthy
2	22/M	Trauma	Trunk-A	6 × 4	1	90	Healthy
3	44/M	Pressure ulcer	Trunk-P	9 × 5	3	120	Healthy
4	27/M	Trauma	Trunk-P	12 × 6	3	120	Healthy
5	23/M	Tumor excision	H&N	7 × 3	1	60	Healthy
6	21/M	Trauma	Trunk-P	4 × 2	1	45	Healthy
7	20/M	Trauma	H&N	8 × 4	3	60	Flap necrosis
8	42/M	Trauma	LL	14 × 8	3	90	Healthy
9	32/M	Tumor excision	H&N	5 × 3	1	60	Healthy
10	36/M	Trauma	LL	14 × 10	3	120	Healthy
11	14/F	Trauma	LL	14 × 4	1	60	Healthy
12	70/M	Trauma	LL	12 × 6	3	60	Healthy
13	51/F	Postinfective	Trunk-A	14 × 8	2a	60	Healthy
14	66/M	Trauma	Trunk-A	6 × 3	1	90	Healthy
15	53/F	Tumor excision	LL	12 × 7	3	90	Healthy
16	37/M	Trauma	H&N	7 × 3	1	60	Healthy
17	54/M	Trauma	UL	8 × 4	2a	60	Healthy
18	23/M	Tumor excision	UL	10 × 4	2a	120	Healthy
19	53/F	Trauma	Trunk-P	12 × 5	3	90	Wound dehiscence
20	48/F	Tumor excision	H&N	8 × 5	2a	90	Healthy
21	12/F	Trauma	LL	9 × 5	3	90	Healthy

(Continued)

Table 2 (Continued)

Case no.	Age/sex	Etiology	Defect location	Flap dimension (cm)	Type of KF	Operative time (min)	Outcome
22	69/M	Tumor excision	Trunk-P	16 × 5	3	120	Healthy
23	45/M	Trauma	LL	6 × 4	3	60	Healthy
24	39/F	Trauma	LL	7 × 4	2a	90	Healthy
25	25/F	Pressure ulcer	Trunk-P	8 × 5	2a	60	Healthy
26	48/M	Trauma	LL	18 × 10	2a	120	Wound dehiscence
27	54/F	Pressure ulcer	Trunk-P	18 × 8	4	120	Healthy
28	22/M	Trauma	LL	17 × 8	2b	60	Healthy
29	40/M	Trauma	LL	5 × 3	3	45	Healthy
30	18/F	Tumor excision	LL	10 × 6	1	60	Healthy
31	49/M	Tumor excision	LL	12 × 8	2b	60	Healthy
32	40/M	Trauma	LL	5 × 3	2a	45	Healthy
33	34/M	Trauma	Trunk-P	8 × 4	4	60	Healthy
34	54/M	Tumor excision	H&N	9 × 4	1	60	Healthy
35	37/F	Tumor excision	Trunk-A	10 × 6	2a	60	Healthy
36	23/M	Tumor excision	LL	9 × 5	4	60	Flap necrosis
37	16/M	Trauma	LL	9 × 6	3	60	Healthy
38	36/F	Pressure ulcer	Trunk-P	10 × 5	3	60	Healthy
39	56/M	Tumor excision	H&N	8 × 6	3	45	Healthy
40	44/M	Trauma	LL	8 × 4	2a	60	Healthy
41	41/M	Postinfective	UL	5 × 3	1	60	Healthy
42	36/M	Postinfective	Trunk-A	7 × 4	2a	60	Healthy
43	40/M	Trauma	LL	8 × 4	2a	60	Healthy
44	52/M	Trauma	LL	6 × 4	2b	60	Healthy

Abbreviations: H&N, head and neck; KF, keystone flap; LL, lower limb; Trunk-A, anterior; Trunk-P, posterior; UL, upper limb.

Table 3 Comparison of flap survival rate between different studies done on keystone flap

Complications	Our study	Pripotnev and White	Bhat	Lanni et al	Gómez et al	Gupta et al	Mohan et al	Lo Torto et al
Number of cases	44	39	42	60	112	50	42	72
Flap survival rate	95.4%	100%	96.36%	100%	100%	95%	100%	97.2%

at the end of 3 months showed a significant fall of 83.7% from baseline by the Wilcoxon's sign rank test demonstrating that patients had reduced severity of pain relatively in comparison to the worst pain experienced by them in their lifetimes. The mean pain VAS score at baseline was 5.51 which reduced to 0.90 by 3 months. The Likert scale scores showed a significant rise from baseline to the end of 3 months, in terms of esthetic satisfaction with 28.6% cases being very satisfied to 80.5% cases at the end of 3 weeks and 82.9% cases were extremely satisfied.

Discussion

The keystone flap is unique among other locoregional flaps because of its high capacity for adaptation.⁸ Although the flap is based on randomly located vascular perforators, it is

usually described as a trilaminar flap with both suprafascial and infra fascial vascular dynamics.⁹ Designing the flap within dermatomal precincts increases the vascular reliability of the flap as delineated by the "angiotome" concept.¹⁰ Furthermore, it has been proposed that the effect of islanding a flap causes a local sympathectomy resulting in hyperemia due to vasodilation, resulting in the flap having a more robust vascularity.^{11,12} The design of the keystone flap permits closure as a V-Y advancement at the lateral edges aiding in transverse mobility toward the central axis into the defect enabling local biomechanics which redistributes and reduces overall tension across the flap.^{2,13}

In our experience among the two cases who developed flap necrosis, one was a type 3 keystone flap designed over the occipital region of the scalp to cover exposed hardware postcervical spine instrumentation. Designing any type of this

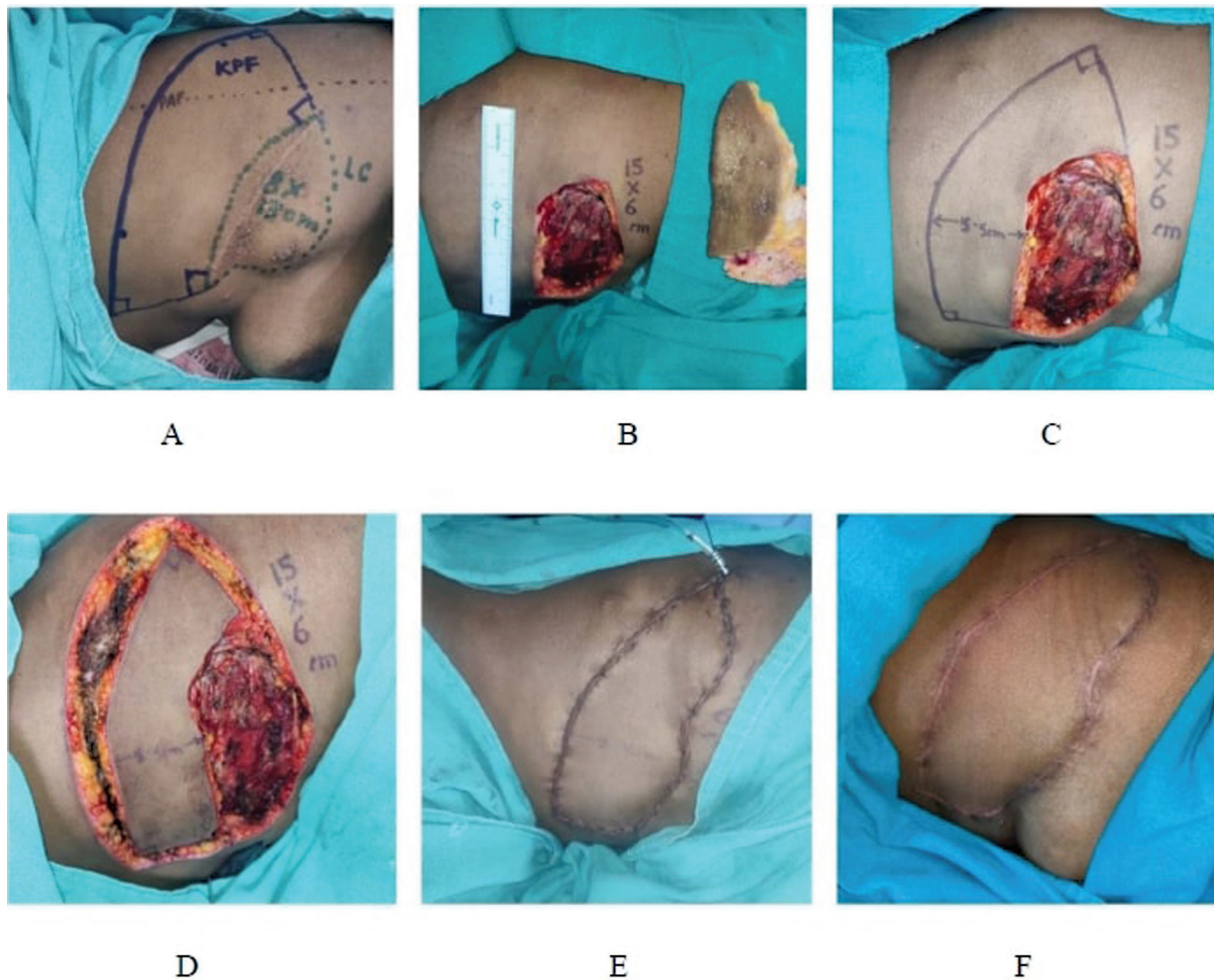


Fig. 2 A 37-year-old female patient with recurrent lymphangioma circumscriptum lesion over the right lateral chest wall underwent excision and reconstruction with type 2a keystone flap. (A) Flap preoperative marking and planning; (B) defect after excision; (C) flap marking intraoperative according to defect size; (D) flap dissection; (E) suturing of flap into defect; and (F) postoperative follow-up after 3 months.

flap in the scalp region is unreliable due to the inherent horizontally oriented vascular dynamics in the scalp which would be disrupted during islanding. Partial islanding of the flap as described by Yoo et al may aid in a more favorable result.¹⁴ In another case of flap failure, a type 4 keystone flap was designed to cover exposed hardware over the knee. Upon retrosection, excessive undermining in periarticular regions where mobility of the flap is already restricted may have disrupted the vascularity of the flap leading to necrosis. Nevertheless, a 95.45% success rate is consistent with several other studies confirming the reliability of this flap (► **Table 3**).^{3,8,15–19} Two patients had minor wound dehiscence which healed secondarily without any consequences.

We utilized different types of keystone flaps to resurface defects in various regions of the body and attempted to determine which type of keystone flap would be best suitable for a defect in a particular region. In our perspective, type 1 keystone flap is best suitable over the head and neck, chest, and abdominal region where mobility of tissue is possible without incising the deep fascia, types 2a and 2b are more suitable over the upper and lower limbs where the fascia has to be incised for mobilization, type 3 can be used over the back especially for coverage of pressure ulcers as well as for

larger defects. Type 4 flaps are suitable for lower limb defects; however, undermining should be restricted to less than 50% to safeguard flap vascularity.

The decreased pain perception could be attributed to the islanding of the flap which is associated with a relatively pain-free postoperative period due to temporary local neurapraxia of cutaneous nerves followed by subsequent return of sensation in the late postoperative period.²⁰ Owing to its characteristic of being a local flap, it provides tissue that is identical to that which existed over the defect. This fact coupled with the redistribution of tension across the suture line results in a more favorable esthetic profile upon healing. Although the esthetic satisfaction among patients was high and none of the cases developed any abnormal scar healing patterns such as keloids or hypertrophic scar, there was scar widening that was observed. This could be as a consequence of excess tension during closure especially at the curvilinear edge of the flap. The presence of scar widening was more remarkable in type 3 keystone flaps over the other types.

The strength of this study is that we have successfully demonstrated the use of the keystone flap in majority of the body parts for a wide range of body defects. The flap

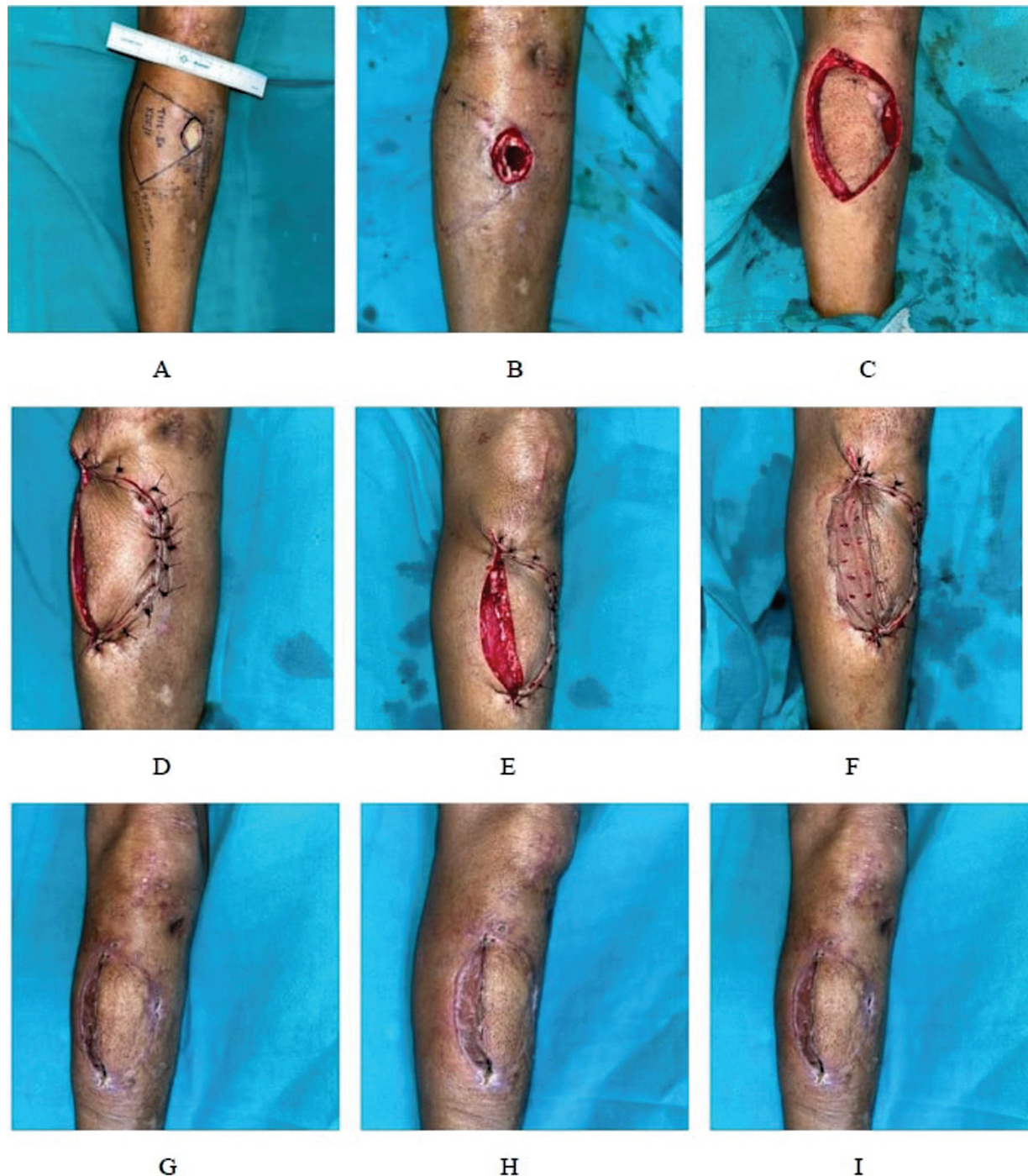

Fig. 3 A 52-year-old male patient with posttraumatic defect over the right proximal one-third of leg reconstructed with type 2b keystone flap. (A) Preoperative planning; (B) defect after debridement; (C) flap dissected; (D) flap inset and suturing done with split-thickness skin graft of curvilinear edge; and (G–I) postoperative follow-up after 3 months.

characteristics have been studied holistically with its survivability being the central parameter but several other additive observations have been recorded and analyzed (►Figs. 2–4).

The limitations of this study are the small sample size despite our best efforts to utilize the keystone flap in various regions of the body. Another limitation of this study is the lack of a control cohort in this study for better comparison and analysis of parameters to demonstrate the efficacy of this flap. The patients have been followed up for a period of

3 months; however, longer follow-ups may allow us to gather better evidence in favor of this flap. Furthermore, there is a possibility of operator bias as all the cases were not performed by a single surgeon.

Conclusion

The keystone flap is an excellent, straightforward, and reliable random pattern island flap for the reconstruction of

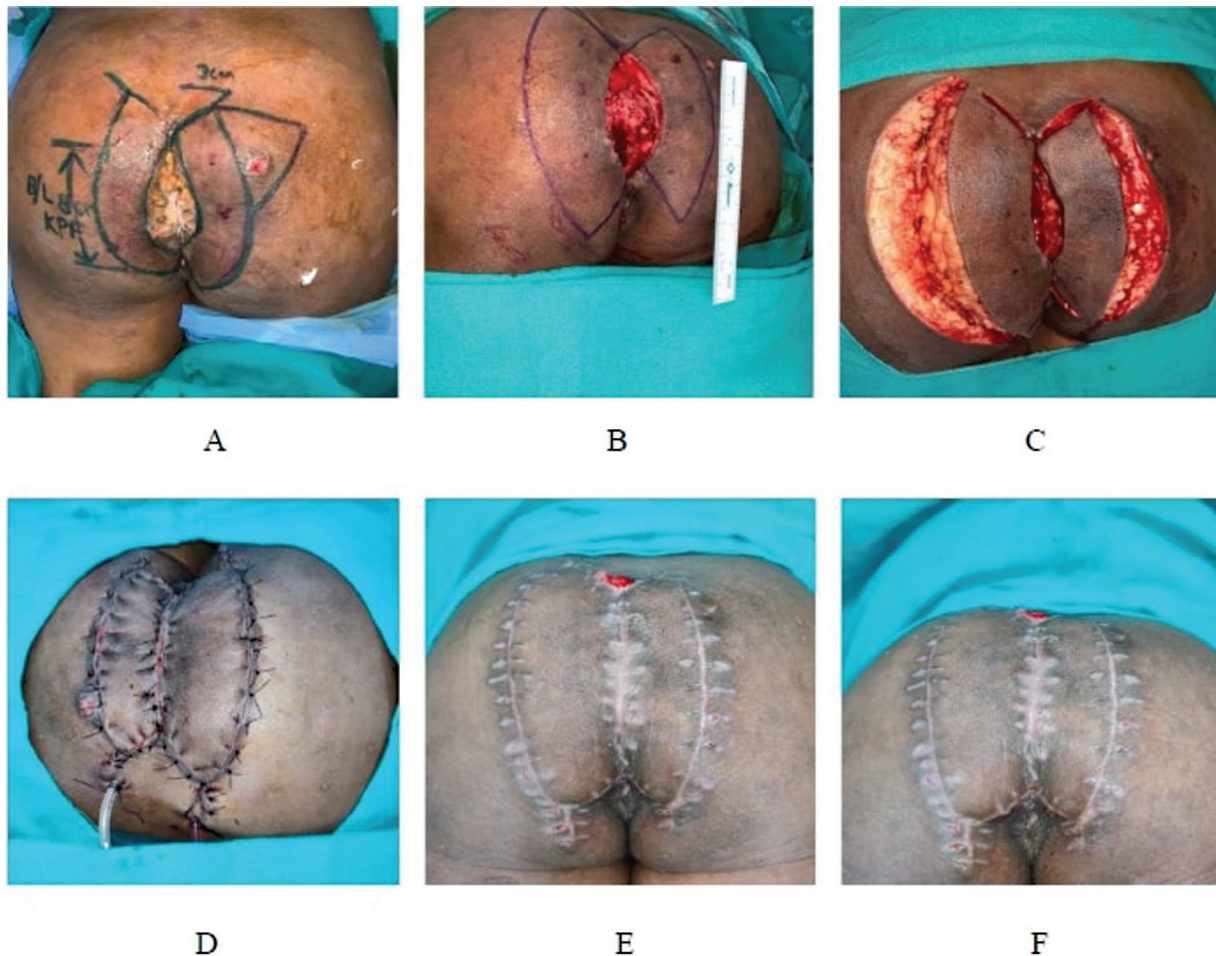


Fig. 4 A 53-year-old female patient with defect over the sacral region near the gluteal cleft following excision of verrucous growth reconstructed with type 3 double opposing keystone flaps. (A) Preoperative planning; (B) defect after excision and flaps on either side marked; (C) flaps dissected; (D) inset and suturing done to cover the defect; and (E, F) postoperative follow-up after 3 months.

defects occurring in every region of the body. The standard design can be modified to meet the requirements of the defect and achieve closure without any complications. An understanding of the physiology behind the keystone principle helps better design and execute this flap. With advantages such as faster learning curve and predictable healing outcomes of the flap, it is of utmost utility in high patient volume centers with limited resources.

Ethical Approval

The article has been prepared in compliance with the ethical standards of our institution and has been approved by the institutional ethics committee. Informed consent was taken from all the patients for participation in the study.

Conflict of Interest

None declared.

References

- Behan FC. The keystone design perforator island flap in reconstructive surgery. *ANZ J Surg* 2003;73(03):112–120
- Yoon CS, Kong YT, Lim SY, Kim J, Shin HW, Kim KN. A comparative study for tension-reducing effect of Type I and Type II keystone perforator island flap in the human back. *Sci Rep* 2021;11(01):16699
- Mohan AT, Rammos CK, Akhavan AA, et al. Evolving concepts of keystone perforator island flaps (KPIF): principles of perforator anatomy, design modifications, and extended clinical applications. *Plast Reconstr Surg* 2016;137(06):1909–1920
- Riccio CA, Chang J, Henderson JT, et al. Keystone flaps: physiology, types, and clinical applications. *Ann Plast Surg* 2019;83(02):226–231
- Donovan LC, Douglas CD, Van Helden D. Wound tension and ‘closability’ with keystone flaps, V-Y flaps and primary closure: a study in fresh-frozen cadavers. *ANZ J Surg* 2018;88(05):486–490
- Johnson C. Measuring pain. visual analog scale versus numeric pain scale: what is the difference? *J Chiropr Med* 2005;4(01):43–44
- Joshi A, Kale S, Chandel S, Pal D. Likert scale: explored and explained. *Br J Appl Sci Technol* 2015;7(04):396–403
- Gupta S, Sharma A, Srivastava S. A keystone flap as a reconstructive option for selected areas: a prospective study. *J Aesthet Reconstr Surg* 2020;6(02):6
- Pelissier P, Santoul M, Pinsolle V, Casoli V, Behan F. The keystone design perforator island flap. Part I: anatomic study. *J Plast Reconstr Aesthet Surg* 2007;60(08):883–887
- Behan FC. The fasciocutaneous island flap: an extension of the angiotome concept. *Aust N Z J Surg* 1992;62(11):874–886
- Lo CH, Nottle T, Mills J. Keystone island flap: effects of islanding on vascularity. *Plast Reconstr Surg Glob Open* 2016;4(02):e617

- 12 Behan FC, Lo CH, Sizeland A. The interpretation of vascular changes observed in keystone island flaps: a hypothesis. *J Plast Reconstr Aesthet Surg* 2010;63(02):e215–e216
- 13 Pelissier P, Gardet H, Pinsolle V, Santoul M, Behan FC. The keystone design perforator island flap. Part II: clinical applications. *J Plast Reconstr Aesthet Surg* 2007;60(08):888–891
- 14 Yoo BW, Oh KS, Kim J, Shin HW, Kim KN. Modified keystone perforator island flap techniques for small- to moderate-sized scalp and forehead defect coverage: a retrospective observational study. *J Pers Med* 2023;13(02):329
- 15 Pripotnev S, White C. The keystone flap—a case series demonstrating practical design, use, and applications. *Plast Surg (Oakv)* 2017;25(03):184–187
- 16 Bhat SP. Keystone flaps in coloured skin: flap technology for the masses? *Indian J Plast Surg* 2013;46(01):36–47
- 17 Lanni MA, Van Kouwenberg E, Yan A, Rezak KM, Patel A. Applying the keystone design perforator island flap concept in a variety of anatomic locations a review of 60 consecutive cases by a single surgeon. *Ann Plast Surg* 2017;79(01):60–67
- 18 Gómez OJ, Barón OI, Peñarredonda ML. Keystone flap: overcoming paradigms. *Plast Reconstr Surg Glob Open* 2019;7(03):e2126
- 19 Lo Torto F, Frattaroli JM, Kaciulyte J, et al. The keystone flap: a multi-centric experience in elderly patients treatment. *J Plast Reconstr Aesthet Surg* 2022;75(01):226–239
- 20 Behan F, Findlay M, Lo CH. *The Keystone Perforator Island Flap Concept*. Australia: Churchill Livingstone; 2012