



# Training in Sylvian Arachnoid Dissection: The Art of Using Kamiyama Scissors and a Simple Novel Model for Practice Sylvian Arachnoid Dissection Using Cotton Fiber with Brain Model

Chanon Ariyaprakai<sup>1,2</sup> Muhammad Kusdiansah<sup>2,3</sup> Javier Degollado-García<sup>2,4</sup> Nakao Ota<sup>2</sup>  
Kosumo Noda<sup>2</sup> Hiroyasu Kamiyama<sup>2</sup> Rokuya Tanikawa<sup>2</sup>

<sup>1</sup>Department of Surgery, Division of Neurosurgery, Faculty of Medicine, Vajira Hospital, Navamindradhiraj University, Bangkok, Thailand

<sup>2</sup>Department of Neurosurgery, Stroke Center, Sapporo Teishinkai Hospital, Sapporo, Hokkaido, Japan

<sup>3</sup>Department of Neurosurgery National Brain Center, East Jakarta City, Indonesia

<sup>4</sup>Division of Neurovascular Surgery, Department of Neurosurgery, National Institute of Neurology and Neurosurgery Manuel Velasco Suarez Hospital, Mexico City, Mexico

Address for correspondence Rokuya Tanikawa, MD, 1-chome-3-1, Kita 33, Johigashi, Higashi Ward, Sapporo, Hokkaido, Japan 065-8612 (e-mail: superbypass@gmail.com).

Chanon Ariyaprakai, MD, Vajiraphayaban, Dusit District, Bangkok, 10300, Indonesia (e-mail: bear.ariyaprakai@gmail.com).

Asian J Neurosurg 2024;19:228–234.

## Abstract

### Keywords

- ▶ sharp dissection of arachnoid
- ▶ transsylvian approach
- ▶ Kamiyama microscissors
- ▶ practice arachnoid dissection
- ▶ cotton fiber
- ▶ brain model

**Background** Transsylvian approach is one of the main approaches for a variety of vascular, tumor, and skull-base lesions. Sylvian fissure harbors a lot of critical structures including the middle cerebral artery and many venous structures. If not done properly, the transsylvian approach could cause several complications. Up to now, there is no simple training model for practicing Sylvian fissure dissection. In this article, we describe the technique of using microscissors for the sharp dissection of arachnoid trabeculae. We also propose a new model for practicing Sylvian arachnoid dissection using a three-dimensional (3D) brain model with cotton fiber.

**Materials and Method** We inserted cotton fiber into the Sylvian fissure of the brain model (aneurysm box from UpsurgeOn) and covered the Sylvian fissure with a cotton sheet, then sprayed the water over it. We dissected this model under a microscope by using Kamiyama scissors in the right hand and suction in the left hand.

**Result** Under the microscope, our model appears comparable with the real Sylvian fissure. We can use this model for practicing arachnoid dissection with Kamiyama scissors.

**Conclusion** The arachnoid dissection model by using a 3D brain model with cotton fiber is a simplified and novel approach for practicing the Sylvian fissure dissection.

article published online  
June 3, 2024

DOI <https://doi.org/10.1055/s-0044-1787091>.  
ISSN 2248-9614.

© 2024. Asian Congress of Neurological Surgeons. All rights reserved.

This is an open access article published by Thieme under the terms of the Creative Commons Attribution-NonDerivative-NonCommercial-License, permitting copying and reproduction so long as the original work is given appropriate credit. Contents may not be used for commercial purposes, or adapted, remixed, transformed or built upon. (<https://creativecommons.org/licenses/by-nc-nd/4.0/>)

Thieme Medical and Scientific Publishers Pvt. Ltd., A-12, 2nd Floor, Sector 2, Noida-201301 UP, India

## Introduction

Sylvian fissure is one of the main gateways to a variety of neurosurgical lesions such as vascular lesions, intrinsic brain tumors, or skull base lesions. It is indisputable that Sylvian fissure arachnoid dissection is one of the most essential neurosurgical skills for neurovascular surgeons, oncologic neurosurgeons, and skull base surgeons.<sup>1-8</sup> Techniques of splitting Sylvian could be divided into two categories: sharp dissection by microscissors and blunt dissection by spreading the tip of bipolar forceps or probing with a microdissector.<sup>9,10</sup> Splitting Sylvian fissure widely has many benefits such as brain relaxation and wide surgical corridor, which lead to safer surgery, less perioperative complications, and better neurological outcomes.<sup>11-13</sup> Arachnoid dissection is vital to untangle the complex structures within the Sylvian fissure. Hence, a proper understanding of anatomy and surgical technique is paramount for a safe Sylvian dissection. However, if the arachnoid dissection was not done properly, it could lead to several complications such as arterial injury, venous injury, and brain contusion that could lead to post-operative seizure, permanent neurological deficit, and poor neurological outcomes.<sup>12,14-16</sup>

Achieving the skill of meticulous Sylvian dissection requires a lot of practice.<sup>13,17,18</sup> In the past, most of the Sylvian dissection trainings was done by practicing Sylvian dissection in actual clinical cases under the supervision of experienced attending staff.<sup>2,19</sup> However, microneurosurgical cases are decreasing due to other options for treating intracranial lesions, such as endovascular treatment or radiotherapy.<sup>20,21</sup> Also, there are medicolegal issues about training in real clinical cases.<sup>22,23</sup> These make neurosurgical residents and young neurosurgeons have fewer cases to practice microsurgical skills. Therefore, training models have a lot of benefits in neurosurgical training.<sup>24-26</sup> In neurosurgery, there are several training models for microvascular anastomosis,<sup>27,28</sup> tumor surgery,<sup>29,30</sup> or even a temporal bone drilling.<sup>31</sup> However, there are very few training models for Sylvian dissection. All of them used a placenta, a cadaver, or

animal models,<sup>32-34</sup> which is sophisticated to prepare and ineffective as an off-job training model every day after working hours. In this article, we summarized the principle of using microscissors in arachnoid dissection and also proposed a new training model for practicing Sylvian arachnoid dissection.

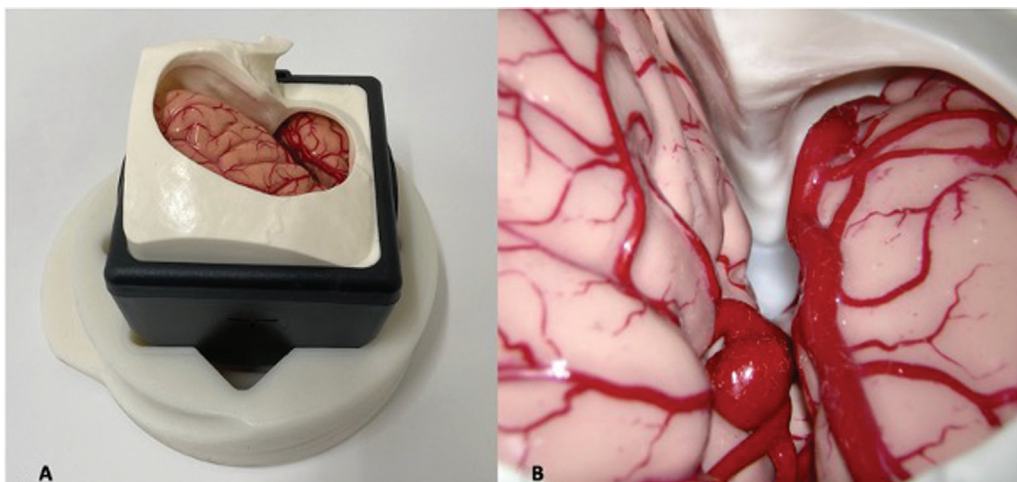
## Materials and Methods

Our training model consisted of two parts: A brain model and a cotton fiber mimicking arachnoid trabeculae. We use a brain model from UpsurgeOn (aneurysm box model), which had a Sylvian fissure and middle cerebral artery within it. The brain parenchyma of this model was made from silicon and had a soft texture mimicking the real brain (►Fig. 1). The cotton fiber (for skin care and women's makeup cleansing) was purchased from the local convenience store (►Fig. 2). Cosmetic cotton fiber is made from the natural fibers of seeds of the cotton plant. The main building block of the fiber is cellulose. The texture of cotton fiber is soft and slightly tough, making it a potential model for arachnoid surgical training. The goal of this training model is to master the sharp dissection of arachnoid fiber by using the Kamiyama scissors.

### Setup

Three young microvascular neurosurgeons (experience in vascular neurosurgery less than five years) who are also the authors of this paper performed this experiment under an operating microscope (Mitaka MM80; ►Fig. 3).


First, we teased the commercial cotton into thin sheets (►Fig. 4). We inserted the first piece of cotton in a Sylvian fissure of the brain model to mimic the arachnoid trabeculae of the intermediate Sylvian arachnoid membrane (►Fig. 5A). Then, we covered the Sylvian fissure with a second sheet of thin cotton fiber to simulate a superficial Sylvian membrane. After that, we sprayed the water on the cotton fiber to simulate the wetness of cerebrospinal fluid and to make the cotton fiber attach to the brain model (►Fig. 5B).




**Fig. 1** (A) Aneurysm box from UpsurgeOn, (B) Aneurysm box under magnification of microscope demonstrates Sylvian fissure with middle cerebral artery and middle cerebral vein.



**Fig. 2** Cotton fiber for skin cleansing (from convenience store).



**Fig. 3** : Operating microscope (Mitaka MM80).



**Fig. 4** Cotton sheet from the convenience store.

### Training Goal

Our goal in this model is to practice sharp dissection of the Sylvian arachnoid membrane using the Kamiyama microscissors in the dominant hand and suction in the nondominant hand.

### Principle and Arts of Using Kamiyama Scissors

In our practice, we always use side-curve microscissors designed by Professor Hiroyasu Kamiyama for sharply dissecting the arachnoid in the Sylvian fissure and interhemispheric fissure. We never use blunt arachnoid dissection. Sharp dissection under high magnification of a surgical microscope, in contrast to blunt dissection by spreading of the bipolar tips, allows precise cutting of arachnoid trabeculae without causing brain contusion.

Before using the scissors, we should understand the anatomy of the scissors. The Kamiyama microscissors have two side-curved blades: the lower and upper blades (►Fig. 6). These two blades are not symmetrical. The upper blade is sharper than the lower blade. The curved shape of both blades makes the tips of the blades more visual, especially when working in a deep corridor.

Due to these distinct features of these scissors, the scissors have many functions, not only simple cutting as done by the typical scissors. We can use the scissors in three ways: cut, slice, and swipe.

#### Cut

“Cut” is quite similar to simple cutting by ordinary scissors. We keep the lower blade stationary during simple cutting and move only the upper blade (as shown in ►Fig. 7A). This movement is comparable to brush movement in Japanese calligraphy called “to-me(止め)” (steady draw a straight line as shown in ►Fig. 7b). This technique makes the cutting more precise and reduces tremors compared to moving both blades. Although moving only upper blade sounds very simple, achieving this skill requires much practice. Most of people, including neurosurgeons, are accustomed to using scissors by moving both blades of scissors, which is unstable, especially in the microsurgery.

“Cut” is used when we can see the structure we want to cut clearly and there is enough space between the structure we want to cut and the vital structures (vessel or neural tissue).

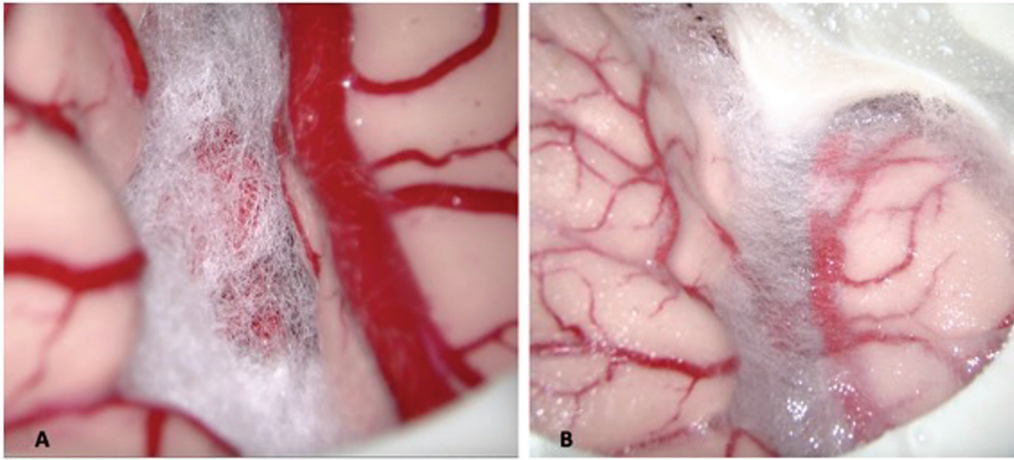
#### Slice

“Slice” is comparable to using a kitchen knife to slice vegetables or peel fruit. In doing “Slice,” we slightly open the tips of scissors and keep this gap between the tips of the scissors. Then, we move the whole scissors up parallel to the blade plane (►Fig. 8A). In doing this, the lower blade will act as a knife to cut the tissue. This movement is comparable to brush movement in Japanese calligraphy called “Ha-Ne(跳ね)” (upward brushstroke as shown in ►Fig. 8B).

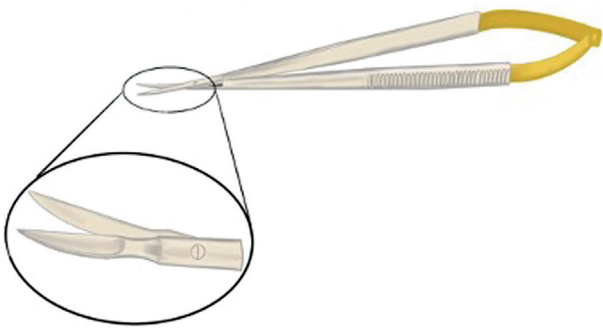
#### Swipe

“Swipe” is comparable to movement of our finger to swipe the touch screen of a smartPhone. In doing a “Swipe,” we slightly open the tips of scissors, keeping the tissue in between (not cutting it), then move both blades in the direction perpendicular to the plane of blades (►Fig. 9A). This movement is comparable to brush movement in Japanese calligraphy called “Ha-Rai(払い)” (swiping of brush stroke as shown in ►Fig. 9B). In doing this, scissors act as

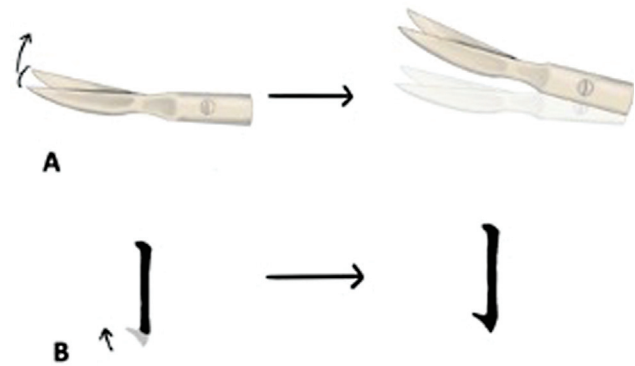




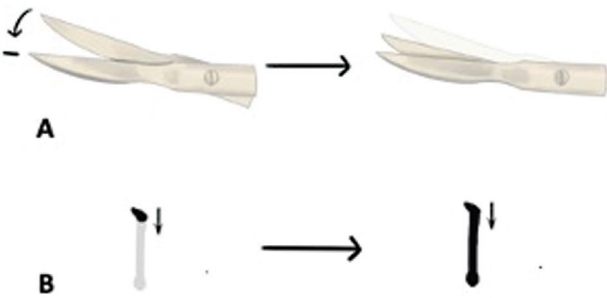
**Fig. 5** (A) Cotton fiber in the Sylvian fissure of brain model mimicking arachnoid trabeculae. (B) Cotton sheet covering the Sylvian fissure mimicking superficial Sylvian membrane.



**Fig. 6** Demonstration of Kamiyama scissors.



**Fig. 8** (A) "Slice" movement of the scissors; both blades are moving up. This movement is comparable to the "ha-ne" brushstroke in Japanese calligraphy in part (B).

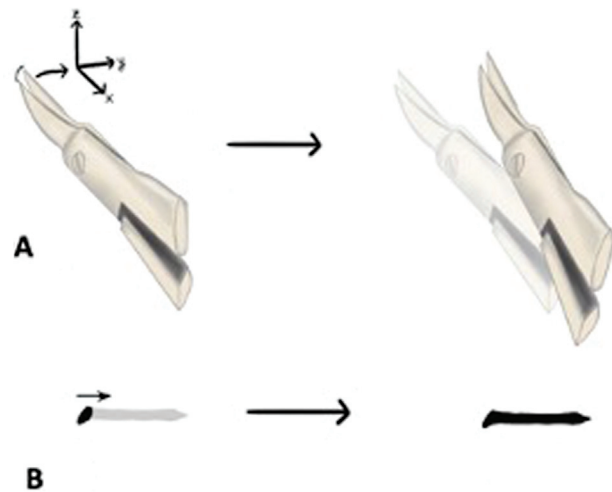


**Fig. 7** (A) "Cut" movement of the scissors, note that only upper blade moves while the lower blade is stationary. This movement is comparable to "to-me" brushstroke in Japanese calligraphy in (B).

a microforcep for microdissecting the tissue. We used this motion to separate the vital structure adhering together; then, we can use "Cut" to cut the arachnoid trabeculae between them.

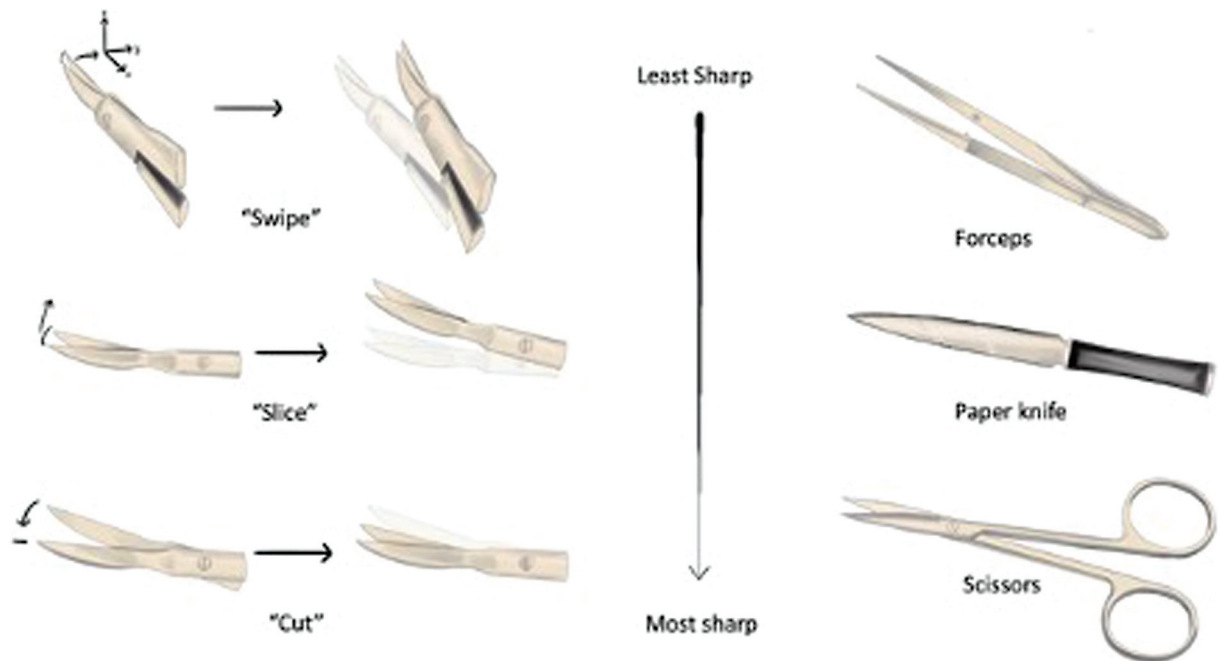
In summary, the "Cut" is the most sharpness and precise motion of the three motions.

"Swipe" is the least sharpness motion and acts like a microforcep. "Slice" is the intermediate between "Cut" and "Swipe." The three motions, "Cut", "Slice," and "Swipe" are shown in **Fig. 10**. Note that, generally, we use the Kamiyama microscissors for both laboratory practice and

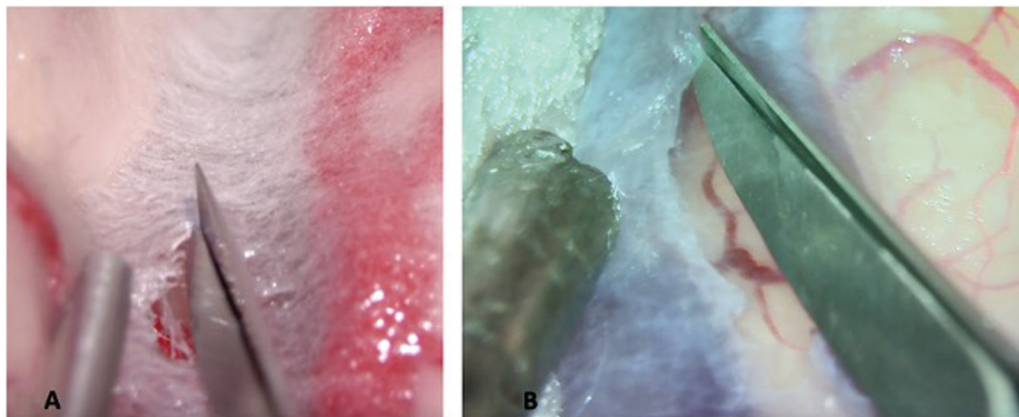


**Fig. 9** (A) "Swipe" movement of the scissors; note that both are lying in xz plane and the movement of both blade is in direction y. This movement is comparable to the "ha-rai" brushstroke in Japanese calligraphy in part (B).

in clinical cases. However, if Kamiyama microscissors are unavailable, other microscissors with curved side blades can be used effectively for arachnoid dissection.



**Fig. 10** The motions of "Cut", "Slice," and "Swipe."



**Fig. 11** (A) The superficial Sylvian membrane in our model looked very similar to the superficial Sylvian membrane in the actual case in part (B).

## Result

The cotton fiber under magnification of the microscope looks very similar to the arachnoid membrane of both superficial Sylvian membrane (► **Fig. 11**) and the arachnoid trabeculae of the intermediate membrane (► **Fig. 12**).

The fiber's texture is softer than the real arachnoid. So, it is easier to cut the cotton fiber. However, for young neurosurgeons, the texture of cotton is quite comparable to real arachnoid trabeculae.

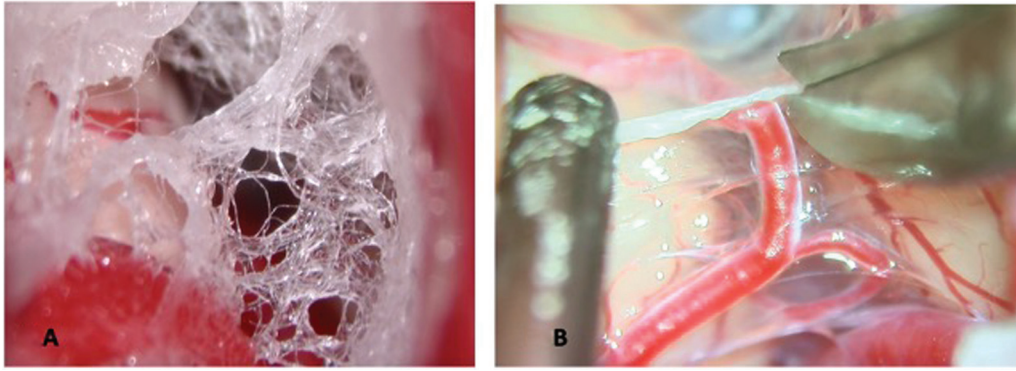
In our experience, cotton fiber is suitable for young neurosurgeons to practice arachnoid dissection with Kamiyama scissors using motion of "Cut", "Slice," and "Swipe."

For the brain model, the texture and elasticity of brain parenchyma are pretty similar to the actual brain. It can be retracted like the real one (► **Fig. 13**).

Overall, cotton fiber in brain model is a good and simple easy-to-prepare as an off-job-training tool for young neurosurgeons to master the technique of sharply dissecting the Sylvian fissure before performing surgery in the real patients.

## Discussion

This article summarized the technical notes using the Kamiyama microscissors for arachnoid dissection. Since we consider that fully knowing the instruments we use, how it is



**Fig. 12** (A) The arachnoid trabeculae in our model looked very similar to the arachnoid trabeculae of the intermediate Sylvian membrane in real case in part (B).



**Fig. 13** Brain parenchyma was retracted by suction in left hand while arachnoid was dissected by Kamiyama scissors in right hand.

made up, and their operation, we can make the most of all their advantages and be aware of their limitations.

We also proposed a new noncadaveric, nonliving animal model for practicing Sylvian arachnoid dissection using a three-dimensional (3D) brain model and cotton fiber. Under the microscope, cotton fiber looked quite similar to arachnoid trabeculae and is suitable for practicing dissection by Kamiyama microscissors, not only for the texture but also for recreating the different arachnoid compartments of the Sylvian fissure, with this, learning the cutting order by inducing tension to the arachnoid trabeculae with the dynamic movement of the suction and microscissors.

Our model is very simple to prepare by inserting cotton fiber into Sylvian of the brain model. By this simplicity, it can be used for daily training after work. By using this model, the practice could be performed everywhere without requiring access to the surgical laboratory. We can practice in operating theater after working hours, in the doctor's office or even in our room.

Despite the simplicity, this model has some limitations. First, the model has only the superficial Sylvian membrane and arachnoid trabeculae of the intermediate membrane but lacks lateral and medial Sylvian membranes as in real clinical

cases. Second, the cotton fiber texture is easier to cut than the real arachnoid trabeculae.

Sylvian fissure is quite a complex anatomical structure.<sup>1,17</sup> So, creating a model that imitates the real one is challenging. But nowadays, the 3D printing technology in medicine including neurosurgery is developing rapidly.<sup>35</sup> In the near future, this technology might be able to create a more realistic Sylvian fissure model.

## Conclusion

A model of cotton fiber with 3D brain model is a simple and effective training model for training Sylvian fissure dissection. This model has potential benefits for future training neurosurgical residents and young neurosurgeons.

## Conflict of Interest

None declared.

## Reference

- 1 Kazumata K, Yokoyama Y, Sugiyama T, et al. Anatomic consideration for transsylvian approach. *Jpn J Neurosurg* 2012;21(09):680–687
- 2 Tanikawa R, Sugimura T, Hokari M, et al. Surgery of internal carotid aneurysms in distal transsylvian approach: differences and advantages of distal transsylvian approach. *Nosotchu No Geka* 2004;32(01):19–24
- 3 Ishikawa K, Sasaki T, Yamazaki T, et al. Surgical technique of proximal control in the middle cerebral artery aneurysm clipping by distal Sylvian approach in relation to the morphological variety of M1 segment. *Nosotchu No Geka* 2022;50(01):25–30
- 4 Nathal E, Serrano-Rubio A, Monroy-Sosa A, et al. Operative considerations and surgical treatment of sylvian fissure arteriovenous malformations: a 20-year experience. *Neurosurg Focus* 2022;53(01):E10
- 5 Kawaguchi T, Fujita S, Shose Y, Hamano S, Tanimoto A. Surgical strategy for sylvian fissure arteriovenous malformations. *Nosotchu No Geka* 1993;21(06):455–459
- 6 Safae MM, Englot DJ, Han SJ, Lawton MT, Berger MS. The transsylvian approach for resection of insular gliomas: technical nuances of splitting the Sylvian fissure. *J Neurooncol* 2016;130(02):283–287
- 7 Pitshkelauri D, Bykanov A, Konovalov A, et al. Transsylvian insular glioma surgery: new classification system, clinical outcome in a consecutive series of 79 cases. *Oper Neurosurg (Hagerstown)* 2021;20(06):541–548



- 8 Tanikawa R, Wada H, Ishizaki T, et al. Anterior temporal approach for basilar bifurcation aneurysms as a modified distal transsylvian approach. *Nosotchu No Geka* 1998;26(04):259–264
- 9 Muhammad S, Tanikawa R, Lawton M, Regli L, Niemelä M, Korja M. Microsurgical dissection of Sylvian fissure-short technical videos of third generation cerebrovascular neurosurgeons. *Acta Neurochir (Wien)* 2019;161(09):1743–1746
- 10 Rodríguez RG, Agyemang K, Arias SAM, Cearns MD, Chaddad-Neto F. Importance of arachnoid dissection in arteriovenous malformation microsurgery: a technical note. *World Neurosurg* 2023;173:12
- 11 Figueiredo EG, Deshmukh P, Zabramski JM, Preul MC, Crawford NR, Spetzler RF. The pterional-transsylvian approach: an analytical study. *Neurosurgery* 2008;62(6, suppl 3):1361–1367
- 12 Maekawa H, Hadeishi H. Venous-preserving Sylvian dissection. *World Neurosurg* 2015;84(06):2043–2052
- 13 Cohen-Gadol AA. Atraumatic Sylvian fissure split: nuances and pitfalls. *Oper Neurosurg (Hagerstown)* 2020;18(02):217–224
- 14 Kageyama Y, Fukuda K, Kobayashi S, et al. Cerebral vein disorders and postoperative brain damage associated with the pterional approach in aneurysm surgery. *Neurol Med Chir (Tokyo)* 1992;32(10):733–738
- 15 Gao W, Li Z, Zhang L. Surgical techniques and prevention of complications in the treatment of basal ganglia hemorrhage through the distal transsylvian approach. *J Craniofac Surg* 2020;31(01):e27–e30
- 16 Dean BL, Wallace RC, Zabramski JM, Pitt AM, Bird CR, Spetzler RF. Incidence of superficial sylvian vein compromise and postoperative effects on CT imaging after surgical clipping of middle cerebral artery aneurysms. *AJNR Am J Neuroradiol* 2005;26(08):2019–2026
- 17 Kazumata K, Kamiyama H, Ishikawa T, et al. Operative anatomy and classification of the sylvian veins for the distal transsylvian approach. *Neurol Med Chir (Tokyo)* 2003;43(09):427–433
- 18 Rey-Dios R, Cohen-Gadol AA. Technical nuances for surgery of insular gliomas: lessons learned. *Neurosurg Focus* 2013;34(02):E6
- 19 Moroi J, Ishikawa T, Hadeishi H, Kobayashi N, Suzuki A, Yasui N. Usefulness and safety of a distal transsylvian approach for microsurgical training. *Nosotchu No Geka* 2009;37(06):429–433
- 20 Stienen MN, Freyschlag CF, Schaller K, Meling TEANS Young Neurosurgeons and EANS Training Committee. Procedures performed during neurosurgery residency in Europe. *Acta Neurochir (Wien)* 2020;162(10):2303–2311
- 21 Hopkins B, Shlobin N, Kesavabhotla K, Smith Z, Dahdaleh N. Case Volume Analysis of Neurological Surgery Training Programs in the United States: 2017–2019. *Neurosurgery Open*. 2021;2 (ahead of print). doi: 10.1093/neuopn/okaa017
- 22 Guan J, Karsy M, Brock AA, et al. Impact of a more restrictive overlapping surgery policy: an analysis of pre- and postimplentation complication rates, resident involvement, and surgical wait times at a high-volume neurosurgical department. *J Neurosurg* 2018;129(02):515–523
- 23 Woodrow SI, Bernstein M, Wallace MC. Safety of intracranial aneurysm surgery performed in a postgraduate training program: implications for training. *J Neurosurg* 2005;102(04):616–621
- 24 Nguyen AV, Coggins WS, Jain RR, et al. Effect of an additional neurosurgical resident on procedure length, operating room time, estimated blood loss, and post-operative length-of-stay. *Br J Neurosurg* 2020;34(06):611–615
- 25 Chawla S, Devi S, Calvachi P, Gormley WB, Rueda-Esteban R. Evaluation of simulation models in neurosurgical training according to face, content, and construct validity: a systematic review. *Acta Neurochir (Wien)* 2022;164(04):947–966
- 26 Harada K, Morita A, Minakawa Y, et al. Assessing microneurosurgical skill with medico-engineering technology. *World Neurosurg* 2015;84(04):964–971
- 27 Lizana J, Montemurro N, Aliaga N, Marani W, Tanikawa R. From textbook to patient: a practical guide to train the end-to-side microvascular anastomosis. *Br J Neurosurg* 2023;37(01):116–120
- 28 Byvaltsev VA, Akshulakov SK, Polkin RA, et al. Microvascular anastomosis training in neurosurgery: a review. *Minim Invasive Surg* 2018;2018:6130286
- 29 Altun A, Çokluk C. The microneurosurgical training model for intrinsic and extrinsic brain tumor surgery using polyurethane foam and fresh cadaveric cow brain: an experimental study. *World Neurosurg X* 2019;4:100039
- 30 Kamp MA, Knipps J, Steiger HJ, et al. Training for brain tumour resection: a realistic model with easy accessibility. *Acta Neurochir (Wien)* 2015;157(11):1975–1981
- 31 Frithioff A, Frendø M, Pedersen DB, Sørensen MS, Wuyts Andersen SA. 3D-printed models for temporal bone surgical training: a systematic review. *Otolaryngol Head Neck Surg* 2021;165(05):617–625
- 32 Gökyar A, Cokluk C. Using of fresh cadaveric cow brain in the microsurgical training model for sulcal-cisternal and fissural dissection. *J Neurosci Rural Pract* 2018;9(01):26–29
- 33 Tayebi Meybodi A, Borba Moreira L, Gandhi S, Preul MC, Lawton MT. Sylvian fissure splitting revisited: applied arachnoidal anatomy and proposition of a live practice model. *J Clin Neurosci* 2019;61:235–242
- 34 de Oliveira MMR, Ferrarez CE, Ramos TM, et al. Learning brain aneurysm microsurgical skills in a human placenta model: predictive validity. *J Neurosurg* 2018;128(03):846–852
- 35 Blohm JE, Salinas PA, Avila MJ, Barber SR, Weinand ME, Dumont TM. Three-dimensional printing in neurosurgery residency training: a systematic review of the literature. *World Neurosurg* 2022;161:111–122