



Intramedullary Spinal Epidermoid Cyst—A Rare Cause of Spastic Paraparesis

Debajyoti Datta¹ Debarshi Chatterjee¹ Mona Tiwari² Soutrik Das² Anindya Basu¹

¹Department of Neurosurgery, Institute of Neurosciences, Kolkata, West Bengal, India

²Department of Radiology, Institute of Neurosciences, Kolkata, West Bengal, India

³Department of Pathology, Institute of Neurosciences, Kolkata, West Bengal, India

Address for correspondence Debajyoti Datta, Department of Neurosurgery, Institute of Neurosciences, Kolkata 700017, West Bengal, India (e-mail: deb.d1988@gmail.com).

Asian J Neurosurg 2024;19:309–311.

Abstract

Spinal intramedullary epidermoids are rare intramedullary lesions of the spinal cord. They may be congenital or acquired with the congenital type often associated with spinal dysraphism and other spinal anomalies. The clinical presentation depends on the level of the involvement of the spinal cord. Management of these lesions is surgical excision. We report a case of intramedullary spinal epidermoid who presented with spastic paraparesis.

Keywords

- ▶ epidermoid cyst
- ▶ intramedullary epidermoid
- ▶ intramedullary tumors
- ▶ spastic paraparesis
- ▶ spinal tumor

Introduction

Spinal epidermoid cysts are rare intraspinal tumors with intramedullary spinal epidermoid cysts being even rarer. Spinal epidermoid cysts can be either congenital or acquired. These lesions are slow growing, and the clinical presentation of the patient depends on the level of the involvement of the spinal cord. Herein, we present a case of an intramedullary spinal epidermoid cyst in an adult who presented with spastic paraparesis.

Case Report

A 63-year-old female presented with a history of intermittent episodes of back pain for the last 3 months along with difficulty in walking and stiffness of bilateral lower limbs for

the same duration. The stiffness in the limbs has been increasing progressively since onset. There was no history suggestive of any sensory or bladder/bowel involvement. On examination, the patient had weakness of bilateral lower limbs with power being three-fifth in bilateral hip, knee, ankle, and extensor hallucis longus. Her planters were extensor bilaterally with exaggerated knee and ankle jerks bilaterally. Tone in bilateral lower limbs was also normal. There was no sensory involvement. Contrast-enhanced magnetic resonance of her spine showed a T1 heterogeneously hyperintense, T2 hypointense, contrast-enhancing space-occupying lesion at D4 vertebral level, intramedullary in location (▶ **Fig. 1**). She underwent D4–D5 laminectomy, midline myelotomy, and gross total excision of the lesion under intraoperative neuromonitoring. The lesion was grayish red in color, soft in consistency and could be well

article published online
June 4, 2024

DOI <https://doi.org/10.1055/s-0044-1787049>.
ISSN 2248-9614.

© 2024. Asian Congress of Neurological Surgeons. All rights reserved.

This is an open access article published by Thieme under the terms of the Creative Commons Attribution-NonDerivative-NonCommercial-License, permitting copying and reproduction so long as the original work is given appropriate credit. Contents may not be used for commercial purposes, or adapted, remixed, transformed or built upon. (<https://creativecommons.org/licenses/by-nc-nd/4.0/>)

Thieme Medical and Scientific Publishers Pvt. Ltd., A-12, 2nd Floor, Sector 2, Noida-201301 UP, India

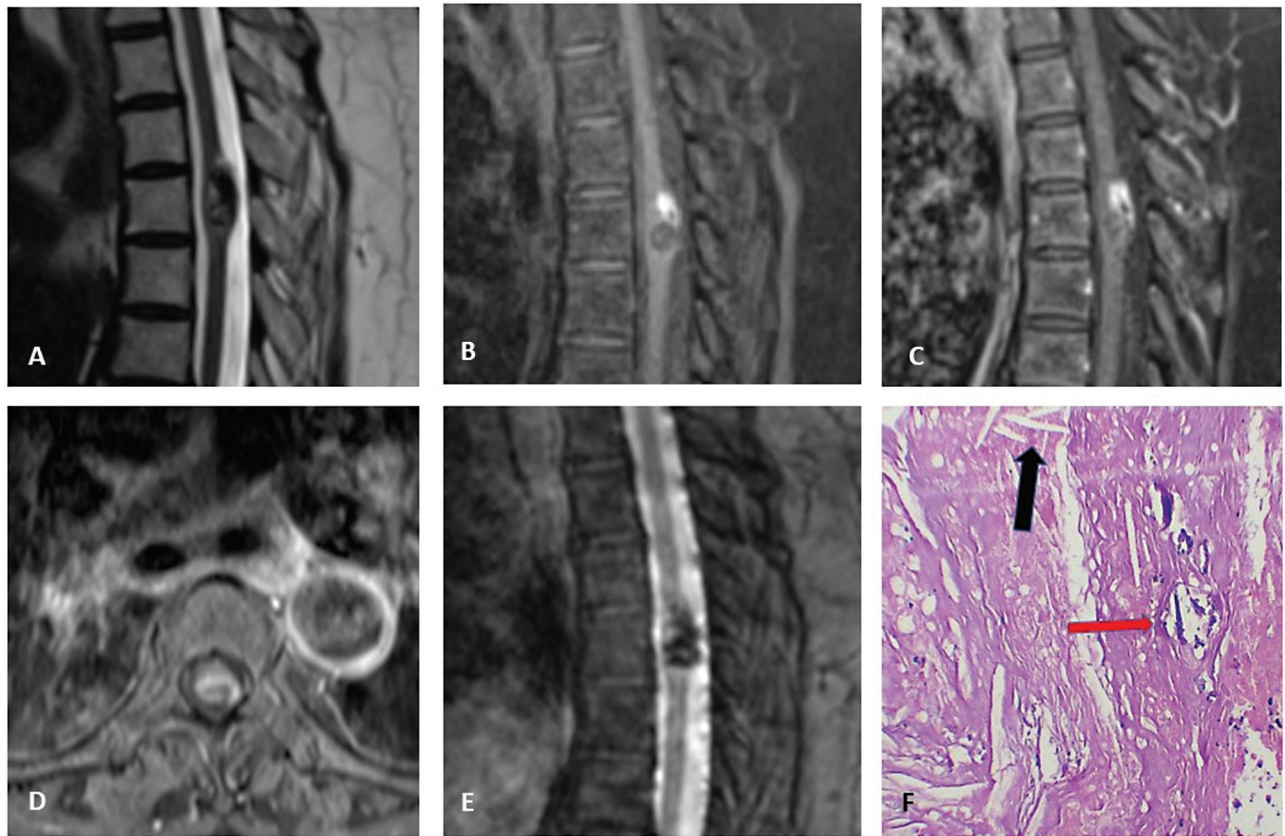


Fig. 1 (A) Sagittal T2-weighted image showing a heterogeneous, partly hypointense lesion in dorsal spinal cord posteriorly at D4 level. (B) Precontrast fat-saturated T1-weighted image showing heterogeneous, partly hyperintense D4 cord lesion. (C) Postcontrast fat-saturated T1-weighted image showing patchy contrast enhancement of D4 cord lesion. (D) Postcontrast T1-weighted axial image showing enhancing lesion at the posterior aspect of the cord at D4 level. (E) Sagittal gradient recalled echo image showing blooming in the lesion. (F) Photomicrograph depicting the cyst contents composed with areas of dystrophic calcification (red arrow) and cholesterol clefts (black arrow) (hematoxylin and eosin, x100).

separated from the cord parenchyma. Histopathologic examination of the excised lesion showed presence of acellular lamellated keratin flakes and xanthomatous reaction consisting of eosinophilic keratinous debris, cholesterol clefts, and dystrophic calcification consistent with an epidermoid cyst. Her postoperative period was uneventful and on subsequent follow-up she had decrease in spasticity of lower limbs.

Discussion

Intraspinal epidermoid cysts are benign, slow growing lesions. The incidence of spinal intramedullary epidermoid cysts was calculated by Roux et al.¹ They found the incidence to be 0.9% in two series consisting of 1479 patients. Sîrbu et al, in their literature review, found that these tumors have a bimodal age distribution, one peak occurring in 0 to 10 years age group and the second peak at around 35 years of age.² They also noted a slight female preponderance (54%) of these tumors. Although these tumors are benign in nature, one case of malignant transformation into squamous cell carcinoma has been reported.³

The pathogenesis of spinal intramedullary epidermoids can be congenital or acquired. In the congenital form, ectodermal

tissue gets entrapped during the closure of the neural tube in the 3rd to 5th week of gestational life.⁴ The congenital form is often associated with spinal dysraphism, scoliosis and cutaneous or dermal defects. The acquired form occurs when there is a displacement of the dermal elements into the spinal cord during procedures like lumbar puncture or other spinal interventions. Manno et al had found an acquired origin of spinal intramedullary epidermoids in 41% of cases.⁵

Histologically, these tumors are lined by stratified squamous epithelium supported by an outer layer of collagenous tissue. There is progressive desquamation and of keratin from the epithelial lining which gives the characteristic pearly white appearance to the contents. The onset of symptoms in these lesions is usually insidious due to their slow growing nature. Sîrbu et al in their review found pain to be the most common symptom (back pain followed by radicular pain). Motor weakness was the second most common symptom followed by sensory deficits and bladder involvement. The most common location is the lumbar region followed by upper dorsal region.

Initial diagnosis is made on the basis of magnetic resonance imaging (MRI) of the spine. These lesions are usually hypointense on T1-weighted imaging and hyperintense on T2-weighted images. However, in their review, Sîrbu et al found that 14% of

the reported lesions were not hyperintense on T2-weighted images. There is usually no contrast uptake or only a thin rim of uptake. The other differentials to be considered are spinal ependymomas and spinal astrocytomas. Surgical resection of the tumor is the standard treatment. Approach can be open laminectomy/laminoplasty with gross total resection of the tumor preserving the neural function with the help of intraoperative neuromonitoring. Minimally invasive approach to these lesions has also been described.⁶ Intraoperative ultrasound can be used to localize the lesion and plan the myelotomy.⁷ Extracapsular gross total resection of the lesion whenever feasible has been advocated to reduce the risk of recurrence and aseptic meningitis.⁸ Postoperative MRI obtained within 48 hours of surgery can show the extent of resection and exclude any hematoma within the operative cavity. A case of a recurrent spinal epidermoid cyst treated with radiotherapy has been reported but this does not constitute the standard of care. Wang et al have demonstrated an overall survival of 100% and progression-free survival of 85.96% at 5 years and 78.95% at 8 years for intradural spinal dermoid and epidermoid tumors. Functional outcome had improved in 28.07%, remained stable in 70.18%, and deteriorated in 1.75% patients as measured by McCormick grade. Tumor size more than 4cm, sphincter involvement, and subtotal resection were associated with poor outcome and recurrence on univariate analysis.⁹

Conclusion

Spinal intramedullary epidermoids are rare, benign lesions which usually present with pain and motor deficits. They are either congenital or acquired in origin and have good prognosis when gross total resection of the lesion is achievable.

Video 1

Online content including video sequences viewable at: <https://www.thieme-connect.com/products/ejournals/html/10.1055/s-0044-1787049>.

Authors' Contributions

D.D. and D.C. were involved in study conception, manuscript preparation, and clinical care of patient. M.T. and S.D. reviewed the manuscript. A.B. helped in manuscript review and clinical care of patient.

Ethical Approval

The authors declare that the procedures followed were in accordance with those of the World Medical Association and the Helsinki Declaration.

Conflict of Interest

None declared.

References

- 1 Roux A, Mercier C, Larbrisseau A, Dube LJ, Dupuis C, Del Carpio R. Intramedullary epidermoid cysts of the spinal cord. Case report. *J Neurosurg* 1992;76(03):528–533
- 2 Sîrbu OM, Chirteş AV, Mitrică M, Sîrbu CA. Spinal intramedullary epidermoid cyst: case report and updated literature review. *World Neurosurg* 2020;139:39–50
- 3 Somasundaram A, Lesser GJ, Mott RT, Hsu W. Malignant transformation of an intramedullary epidermoid cyst in the thoracic region of the spinal cord: case report. *J Neurosurg Spine* 2013;19(05):591–594
- 4 Gonzalvo A, Hall N, McMahan JH, Fabinyi GC. Intramedullary spinal epidermoid cyst of the upper thoracic region. *J Clin Neurosci* 2009;16(01):142–144
- 5 Manno NJ, Uihlein A, Kernohan JW. Intraspinous epidermoids. *J Neurosurg* 1962;19(09):754–765
- 6 Formo M, Halvorsen CM, Dahlberg D, et al. Minimally invasive microsurgical resection of primary, intradural spinal tumors is feasible and safe: a consecutive series of 83 patients. *Neurosurgery* 2018;82(03):365–371
- 7 Ivanov M, Budu A, Sims-Williams H, Poeta I. Using intraoperative ultrasonography for spinal cord tumor surgery. *World Neurosurg* 2017;97:104–111
- 8 Yin H, Zhang D, Wu Z, Zhou W, Xiao J. Surgery and outcomes of six patients with intradural epidermoid cysts in the lumbar spine. *World J Surg Oncol* 2014;12(01):50
- 9 Wang X, Gao J, Wang T, Li Z, Li Y. Intraspinous dermoid and epidermoid cysts: long-term outcome and risk factors. *J Spinal Cord Med* 2020;43(04):512–517