





# Primary Seminal Vesicle Clear Cell Adenocarcinoma: A Rare Entity

Jitin Goyal<sup>1</sup> Rupinder Singh Baweja<sup>1</sup> Nitin Agarwal<sup>1</sup> Anila Sharma<sup>2</sup> Sunil Kumar Puri<sup>1</sup>

<sup>1</sup>Department of Radiology, Rajiv Gandhi Cancer Institute and Research Centre, Delhi, India

<sup>2</sup>Department of Pathology, Rajiv Gandhi Cancer Institute and Research Centre, Delhi, India

**Address for correspondence** Rupinder Singh Baweja, MBBS, MD, DM (Neuroradiology), Department of Radiology, Rajiv Gandhi Cancer Institute and Research Centre, Rohini Sector 5, Delhi 110085, India (e-mail: rupinder.dr@gmail.com).

Ind J Med Paediatr Oncol

## Abstract

Primary seminal vesicle cancer (SVC) is an exceptionally rare occurrence and is often secondary to bladder or prostate cancers. Adenocarcinoma is being the predominant histological type, with only a few cases reported in the literature.

This case report presents a 54-year-old male diagnosed with primary seminal vesicle clear cell adenocarcinoma who underwent bilateral orchidectomy for bilateral undescended testis 25 years ago. The patient exhibited frequency of urination and imaging studies revealed a large enhancing soft tissue mass in the pelvis, involving the prostate gland, compressing the urinary bladder and left ureter. Biopsy results initially suggested poorly differentiated carcinoma of renal cell origin but subsequent histopathological and immunohistochemical analysis confirmed clear cell adenocarcinoma originating from the seminal vesicles/mesonephric remnants. The patient underwent excision of pelvic mass with sigmoidectomy bladder repair, rectosigmoid anastomosis, and bilateral double-J stenting and followed by adjuvant chemotherapy.

In conclusion, primary SVC is an extremely rare malignancy, and clear cell adenocarcinoma represents a particularly uncommon subtype. This case highlights the importance of considering primary seminal vesicle malignancies when evaluating pelvic masses and the significance of histopathological and immunohistochemical analyses in establishing an accurate diagnosis.

## Keywords

- ▶ seminal vesicle cancer
- ▶ immunohistochemistry
- ▶ CECT
- ▶ PET-CT

## Introduction

Seminal vesicle cancers (SVCs) are frequently secondary tumors to bladder or prostate cancers.<sup>1</sup> Only a few number of cases with primary SVC has been documented in the literature. Adenocarcinoma of the seminal vesicle is the most prevalent histological type.<sup>2</sup> In this case report, an elderly male had primary seminal vesicle clear cell adenocarcinoma.

## Case Report

A 54-year-old hypertensive male presented with complaints of frequent defecation and urination. He had a history of

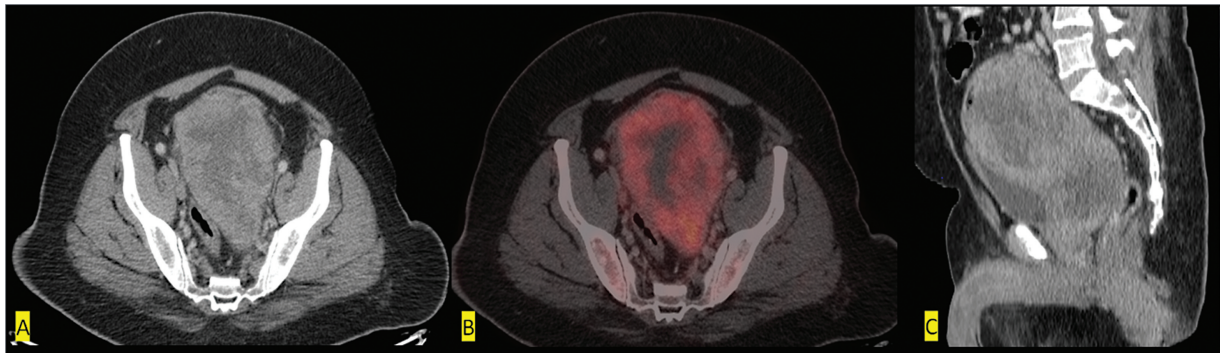
bilateral orchidectomy for bilateral undescended testes 25 years ago. Subsequently, he underwent contrast-enhanced computed tomography (CECT) of the abdomen and whole-body 18-fluorodeoxyglucose (FDG) positron emission tomography-CT scan for evaluation. The imaging (▶ **Fig. 1**) revealed an FDG-avid large heterogeneously enhancing lobulated soft tissue mass lesion (with standardized uptake value [SUV]max 11.6) in the pelvis, located in the retrovesical space, involving the prostate gland, and indenting the urinary bladder with compression of the distal left ureter and possible infiltration into the sigmoid colon. The mass did not show separate visualization of the seminal vesicles. Additionally, a few FDG-avid lymph nodes were noted in bilateral

DOI <https://doi.org/10.1055/s-0044-1786969>.  
ISSN 0971-5851.

© 2024. The Author(s).

This is an open access article published by Thieme under the terms of the Creative Commons Attribution License, permitting unrestricted use, distribution, and reproduction so long as the original work is properly cited. (<https://creativecommons.org/licenses/by/4.0/>)

Thieme Medical and Scientific Publishers Pvt. Ltd., A-12, 2nd Floor, Sector 2, Noida-201301 UP, India

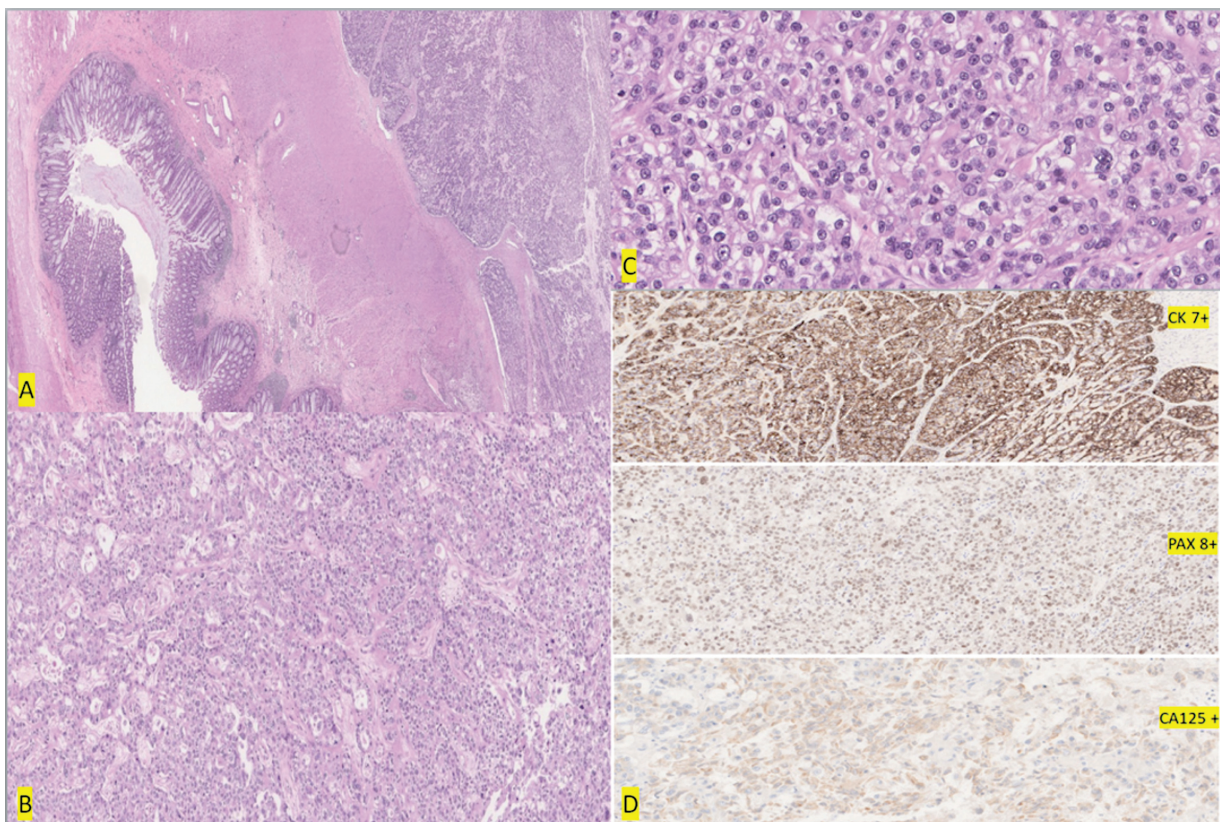


**Fig. 1** Contrast-enhanced computed tomography (CECT; A, C images) of abdomen and whole-body 18-fluorodeoxyglucose (FDG) position emission tomography-computed tomography (PET-CT; B image) scan showed FDG-avid large heterogeneously enhancing lobulated soft tissue mass lesion (with standardized uptake value [SUV]max 11.6) in pelvis in retrovesical space, involving the prostate gland and indenting the urinary bladder with seminal vesicles not seen separately from the mass.

common iliac (right: subcentimetric, SUVmax 2.9), presacral, and bilateral external iliac (right: 1.6 × 0.9 cm, SUVmax 4.1) regions. A subsequent biopsy from the mass demonstrated a poorly differentiated malignancy, characterized by sheets of neoplastic cells. Immunohistochemistry (IHC) showed that the tumor cells were positive for PAX-8, with focal CK7 and CD10 (moderate) expression. The tumor cells tested negative for CK20, TTF1, GATA3, CA-IX, P40, and NKX3.1. BAP-1 and FH expression were retained (►Fig. 2). Overall, these features were indicative of poorly differentiated carcinoma of renal cell origin-renal cell carcinoma, not otherwise specified.

Following the diagnosis, the patient underwent excision of pelvic mass with sigmoidectomy bladder repair, rectosigmoid anastomosis, and bilateral double-J stenting. Pelvic lymphadenectomy was not done.

The postoperative specimen histopathology revealed tumor cells arranged in sheets, nests, trabeculae, papillae, and glandular configuration. The papillae exhibited significant hyalinization, and the tumor cells displayed pleomorphism, distinct cell membranes, clear to eosinophilic moderate cytoplasm, irregular convoluted vesicular nuclei, prominent nucleoli, frequent mitosis, and foci of necrosis. On IHC, the



**Fig. 2** (A) Sigmoid colonic mucosa on the left side and a malignant tumor seen on the right side infiltrating its muscular wall. (B) Tumor cells are arranged in sheets, nests, and glandular pattern along with areas of hyalinization. (C) Tumor cells are pleomorphic with distinct cell membrane, clear to eosinophilic cytoplasm, irregular vesicular nucleus, and prominent nucleoli with frequent mitosis. (D) On immunohistochemistry (IHC) tumor cells are immunopositive for CK7 +, PAX8 +, and CA125 +, respectively, shown.

tumor cells were positive for CK7, PAX8, NAPSIN-A, and CA125, while negative for CK20, NKX3.1, PSA, P40, GATA3, AMACR, and SALL4 (→Fig. 2). The final diagnosis was clear cell adenocarcinoma arising from the seminal vesicles/mesonephric remnants.

The postoperative period was uneventful, and the patient received adjuvant six cycles of paclitaxel-carboplatin based chemotherapy with radiotherapy. A follow-up CT imaging after 1 year revealed no enhancing soft tissue lesion or deposit in the postop bed or anastomotic site.

## Discussion

Primary malignancy arising from the seminal vesicle is very rare. Usually, secondaries from the prostate are being the most common malignancy.<sup>1</sup> SVCs include sarcomas and uncommon tumors comprising of stroma and mixed epithelial tissue. Adenocarcinoma is the most common primary histotype in epithelial type with approximately 100 cases in literature.<sup>2</sup>

To the best of our knowledge, only Gaur et al<sup>1</sup> and Murakami et al<sup>3</sup> have reported cases of primary clear cell carcinoma of the seminal vesicle. The age of SVC diagnosis can range from 10 to 90; however, it is most frequently diagnosed after age 50.<sup>3</sup> The most common symptoms are obstructive lower urinary tract symptoms like dysuria, seen in approximately 35% of cases.<sup>3,4</sup> In our case, the patient presented with frequent urination.

Cross-sectional imaging, including CT and magnetic resonance imaging (MRI), are helpful in determining the location, local extent of tumors, and associated congenital deformities such as ectopic kidneys or ureters.<sup>3,5</sup>

Among the diagnostic criteria for seminal vesicle malignancies are the absence of prostate-related tumors, seminal vesicle-specific adenocarcinoma, and papillary adenocarcinoma that resembles the seminal vesicle mucosa.<sup>6</sup>

Dalgaard and Giertsen<sup>3,7,8</sup> established a three-point set of diagnostic criteria for primary seminal vesicle carcinoma. First, there must be a malignant seminal vesicle tumor confirmed via gross or microscopic examination. Second, there must be no other primary cancers in the body. Third, the tumor must be a papillary adenocarcinoma, showing features that resemble those of a nonneoplastic seminal vesicle. Our patient met all three requirements for primary seminal vesicle carcinoma, in consideration that clear cell carcinoma being subtype of adenocarcinoma.

The histological features reported by Gaur et al<sup>1</sup> are like clear cell ovarian carcinoma, as the papillary architecture was composed of proliferating pale cells with round nuclei

and abundant pale cytoplasm. Additionally, on IHC, our case showed reactivity for CK7, PAX8, and CA125, and nonreactivity for CK20. PAX8 is specifically expressed in the malignancies involving epithelia of Wolffian ducts, Mullerian ducts, the kidneys,<sup>8</sup> and also in ovarian clear cell carcinoma.<sup>9</sup> CK7 and CK20 are known markers for identifying the origin of malignancies.<sup>10</sup> However, clear cell carcinomas of the seminal vesicle, urinary bladder adenocarcinomas, and malignant tumors arising from the Mullerian duct are reactive for CK7 but nonreactive for CK20 on immunostaining (→Table 1).

The histogenesis of clear cell carcinoma of the seminal vesicle is controversial. In female patients clear cell carcinoma of the urinary bladder or urethra is closely related to endometriosis or ectopic Mullerian epithelia. In our case, as the patient is male, the patient's seminal vesicle clear cell carcinoma could have originated from a remnant Mullerian epithelium. Due to the rarity of primary SVC, there is no clearly defined standard of care for its treatment. However, total tumor excision is generally recommended as the primary treatment approach. This may involve surgical removal of the tumor along with any adjacent involved structures, such as the prostate or bladder, depending on the extent of the disease. In positive surgical margins, adjacent organ invasion or recurrence, adjuvant chemotherapy or radiotherapy has been found to prolong recurrence-free survival or overall survival in previous cases.<sup>11</sup> In localized margin-negative disease, no recurrence was reported during the follow-up; however, adjuvant therapy does not provide any sufficient evidence of comparative survival differences in these cases.<sup>14</sup> No established reports on hormonal therapy were reported; however, antiandrogen therapy could be effective for androgen-dependent SVC as an adjuvant therapy.<sup>12</sup>

The prognosis of primary SVC is variable and is determined by several factors, including the stage of the disease at the time of diagnosis, the extent of tumor involvement, and the efficacy of the treatment given. There is a wide range in the overall survival of individuals who undergo complete resections (from 3 months to long-term survival).<sup>13,14</sup> Some individuals with complete tumor resection experience long-term survival, while others may have a more limited overall survival. To find any recurrence or metastasis and to inform future treatment choices, it is crucial to have regular follow-up including imaging tests and periodic tumor marker monitoring.

## Conclusion

Primary seminal vesicle carcinoma is a rare occurrence. Cross-sectional imaging including CT and MRI plays an

**Table 1** Common IHC markers for cancer

|                        | CA-125 | CK7 | CK20 | PAX-8 |
|------------------------|--------|-----|------|-------|
| Seminal vesicle cancer | +      | +   | –    | +     |
| Prostate cancer        | –      | –   | –    | –     |
| Urinary bladder cancer | –      | +   | +    | –     |
| Colorectal cancer      | –      | –   | +    | –     |

Abbreviation: IHC, immunohistochemistry.

important role for location and extent of tumors. Definitive diagnosis is done by histopathology and immunohistochemical analysis. Although there is no conventional treatment technique, total tumor removal is often suggested, followed by consideration of adjuvant therapy. The varying long-term prognosis highlights the importance of continuing monitoring and follow-up.

**Informed Consent**

None.

**Patient Consent**

Not required.

**Financial Support and Sponsorship**

None.

**Conflict of Interest**

None declared.

**Acknowledgments**

We thank the patients and their families for their munificence in contributing to this study. We would also like to thank all members of the IRB committee who gave their approval for this study.

**References**

- 1 Gaur S, Kapadia A, Pillai SB, Hegde P, Chawla AK. Clear cell primary seminal vesicle carcinoma in a young male—a rare case report. *J Clin Diagn Res* 2018;12(02):406
- 2 Bhardwaj N, Rastogi P, Attri VS, Bora GS, Gorski U. Primary seminal vesicle adenocarcinoma: a case report of rare entity and discussion of its differential diagnosis using immunohistochemical approach for the core biopsy specimen. *Andrologia* 2020;52(03):e13512
- 3 Murakami H, Motoshima T, Kurahashi R, et al. Clear cell carcinoma of the seminal vesicle in a young adult. *IJU Case Rep* 2022;5(05):406–409
- 4 Ramamurthy R, Periasamy S, Mettupalayam V. Primary malignancy of seminal vesicle: a rare entity. *Indian J Urol* 2011;27(01):137–139
- 5 Warmann SW, Vogel M, Wehrmann M, et al. Giant mullerian duct cyst with malignant transformation in 15-year-old boy. *Urology* 2006;67(02):424.e3–424.e6
- 6 Eken A, Izol V, Aridogan IA, Erdogan S, Acikalin A, Tansug Z. An unusual cause of hematospermia: primary adenocarcinoma of the seminal vesicle. *Can Urol Assoc J* 2012;6(06):E259–E262
- 7 Thyavihally YB, Tongaonkar HB, Gupta S, Gujral S. Primary seminal vesicle adenocarcinoma presenting as isolated metastasis to penis responding to chemotherapy and hormonal therapy. *Urology* 2007;69(04):778.e1–778.e3
- 8 Dalgaard JB, Giertsen JC. Primary carcinoma of the seminal vesicle; case and survey. *Acta Pathol Microbiol Scand* 1956;39(04):255–267
- 9 Gaur S, Pillai SB, Hegde P, Chawla AK, Kapadia A. Clear cell primary seminal vesicle carcinoma in a young male—a rare case report. *J Clin Diagn Res* 2018;12:XD01–XD02
- 10 Nonaka D, Chiriboga L, Soslow RA. Expression of pax8 as a useful marker in distinguishing ovarian carcinomas from mammary carcinomas. *Am J Surg Pathol* 2008;32(10):1566–1571
- 11 Yao Y, Liu S, He YL, Luo L, Zhang GM. Primary seminal vesicle adenocarcinoma with a history of seminal vesicle cyst: a case report and review of literature. *World J Clin Cases* 2023;11(14):3261–3266
- 12 Yin T, Jiang Y. A 5-year follow-up of primary seminal vesicle adenocarcinoma: a case report. *Medicine (Baltimore)* 2018;97(41):e12600
- 13 Ormsby AH, Haskell R, Jones D, Goldblum JR. Primary seminal vesicle carcinoma: an immunohistochemical analysis of four cases. *Mod Pathol* 2000;13(01):46–51
- 14 Bouassida K, Hmida W, Mestiri S, Tlili G, Mokni M, Mosbah AT. Primary seminal vesicle adenocarcinoma presenting as acute urinary retention and hematuria: a case report. *World J Nephrol* 2015;4:2426