




Myiasis in Percutaneous Transhepatic Biliary Drainage Site

Tara Prasad Tripathy¹ Ranjan Patel¹ Ripan Debbarma¹ Sunita Gupta² Brahmadutta Pattanaik²

¹Department of Radiodiagnosis, All India Institute of Medical Sciences, Bhubaneswar, Orissa, India

²Department of Surgical Gastroenterology, All India Institute of Medical Sciences, Bhubaneswar, Orissa, India

Address for correspondence Tara Prasad Tripathy, MD, PDCC, Department of Radiodiagnosis, All India Institute of Medical Sciences, Bhubaneswar, Orissa 751019, India (e-mail: taraprasad.mkcg@gmail.com).

J Clin Interv Radiol ISVIR 2024;8:131–134.

Abstract

Keywords

- ▶ myiasis
- ▶ percutaneous transhepatic biliary drainage
- ▶ ivermectin

The infection of dipterous larvae causes myiasis. It is generally associated with unsanitary conditions. An interventional radiologist rarely comes across myiasis. We report a case of myiasis around a percutaneous transhepatic biliary drainage (PTBD) tube. A 31-year-old man from a rural area underwent left PTBD for cholangiocarcinoma and was discharged with an internal–external drain. Two weeks later, he presented with pain in the local site, pruritus, and bile leakage. He was found to have maggots around the PTBD tube with poor wound hygiene. Treatment included turpentine oil instillation and oral and topical ivermectin, accompanied by manual removal of the larva.

Introduction

Myiasis is derived from the Latin words *muia*, meaning fly, and *iasis*, meaning disease. The term was coined by Hope in 1849.¹ It is an ectoparasite infestation of the skin by the larvae of Diptera flies. The three parasitological categories of myiasis are obligatory, facultative, and accidental. Obligatory myiasis refers to the requirement of living tissue for larval development. Facultative myiasis refers to larval development on carrion or vegetable matter, with the possibility of sporadic development on living tissue. Clinical classifications are made depending on the body parts that have been infected, including the urogenital, ophthalmic, nasopharyngeal, intestinal, auricular, and cutaneous. The most typical form of myiasis is cutaneous involvement. Myiasis in the wound indicates poor hygiene and improper wound care.² We report a case of myiasis at a recently placed percutaneous transhepatic biliary drainage (PTBD) site.

Case Report

A 31-year-old man, a daily wage laborer from a low socio-economic background, presented with features of obstructive

jaundice, following which diagnostic imaging and biopsy were done. Investigations revealed a dual pathology: distal extrahepatic common bile duct (CBD) cholangiocarcinoma causing dilatation of the CBD and bilobar intrahepatic biliary radicles and carcinoma stomach involving the antrum (▶**Fig. 1**). Laboratory investigations revealed a total bilirubin of 22.6 g. Endoscopic retrograde cholangiopancreatography (ERCP) failed due to a deformed antrum, following which PTBD was placed through the left hepatic duct. After 1 week, after reduction in bilirubin and total leucocyte count (TLC), internalization of the biliary drain was done (8.5 Fr, Cook Medical, Bloomington), and the patient was discharged. After 2 weeks, the patient presented with intense itching and biliary leakage around the biliary drainage site, and on the removal of the bile-soaked dressing, the tissue at the PTBD site was infected. On closer inspection, multiple larvae were observed around the PTBD location, identified as *Dermatobia hominis* larvae (▶**Fig. 2A**).

Turpentine oil was applied at the PTBD site. Manual removal of the maggots was done. Ivermectin was applied topically (1% cream) and administered orally (12 mg, single dose). Maggots were eliminated in 3 days. The biliary drainage tube was exchanged, and the patient was advised for

article published online
May 13, 2024

DOI <https://doi.org/10.1055/s-0044-1786710>.
ISSN 2457-0214.

© 2024. The Author(s).

This is an open access article published by Thieme under the terms of the Creative Commons Attribution License, permitting unrestricted use, distribution, and reproduction so long as the original work is properly cited. (<https://creativecommons.org/licenses/by/4.0/>)

Thieme Medical and Scientific Publishers Pvt. Ltd., A-12, 2nd Floor, Sector 2, Noida-201301 UP, India

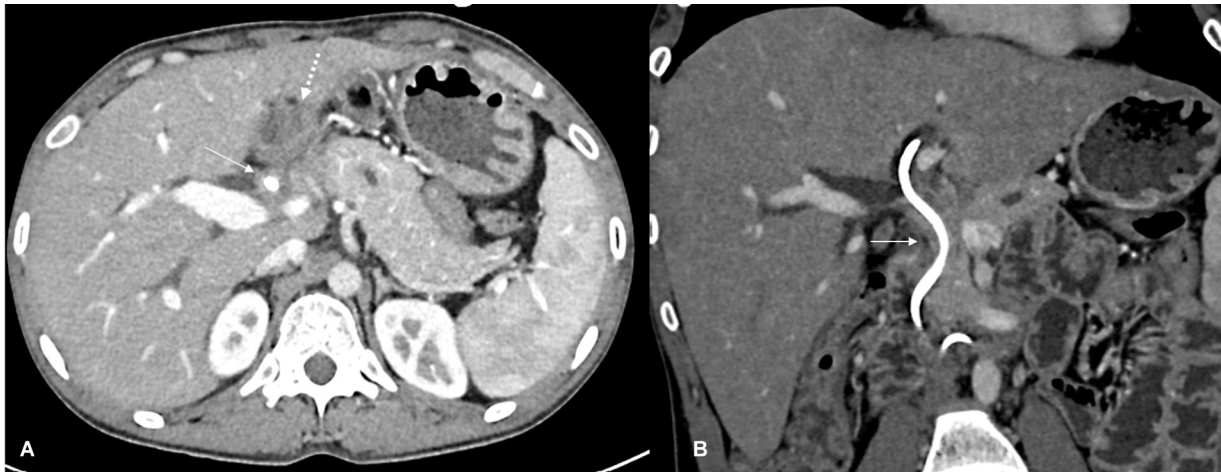


Fig. 1 (A) Axial venous phase contrast-enhanced computed tomography (CECT) section showing mid and distal common bile duct (CBD; arrow) with a drainage tube in the CBD. Gastric wall thickening (dotted arrow) also seen. Coronal CECT showing mid and distal CBD wall thickening.

adequate catheter care. Concurrent broad-spectrum antibiotics (tablet cefixime 200 mg twice daily for 5 days) were administered. After 1 week, the local site was inspected for any maggots. As serum bilirubin and TLC were within acceptable limits (►Table 1), drain was removed, and metallic biliary stenting (EPIC, 10 × 100 mm, Boston Scientific) was done (►Fig. 2B).

Discussion

Maggot infestations are commonly seen in the tropical region; however, maggot infestations in the PTBD site are rarely reported. Maggots are dipteran fly larvae that require a host to complete their life cycle. Goats and sheep are the undisputed hosts for maggots. Humans are an unintentional

host; an unhygienic surgical wound site is a risk factor. Cases of myiasis typically manifest in the spring and summer.³ Wound myiasis develops as a result of egg deposition on dead flesh or in a wound with dripping pus. ►Fig. 3 represents the life cycle of a maggot.⁴ Poor hygiene, fly population density, housing conditions, poor sanitation, and physical, mental, or immune system impairments are risk factors for myiasis. Another essential risk factor are exposed lesions.⁵ Myiasis at the PTBD site is rare.

In fear of displacing the PTBD catheter, our patient had not taken a bath. He also had close contact with domestic animals. Due to bile leakage, the wound site was soaked, which attracted the flies. A diagnosis of myiasis is made mostly clinically and laboratory and imaging studies are not necessary.

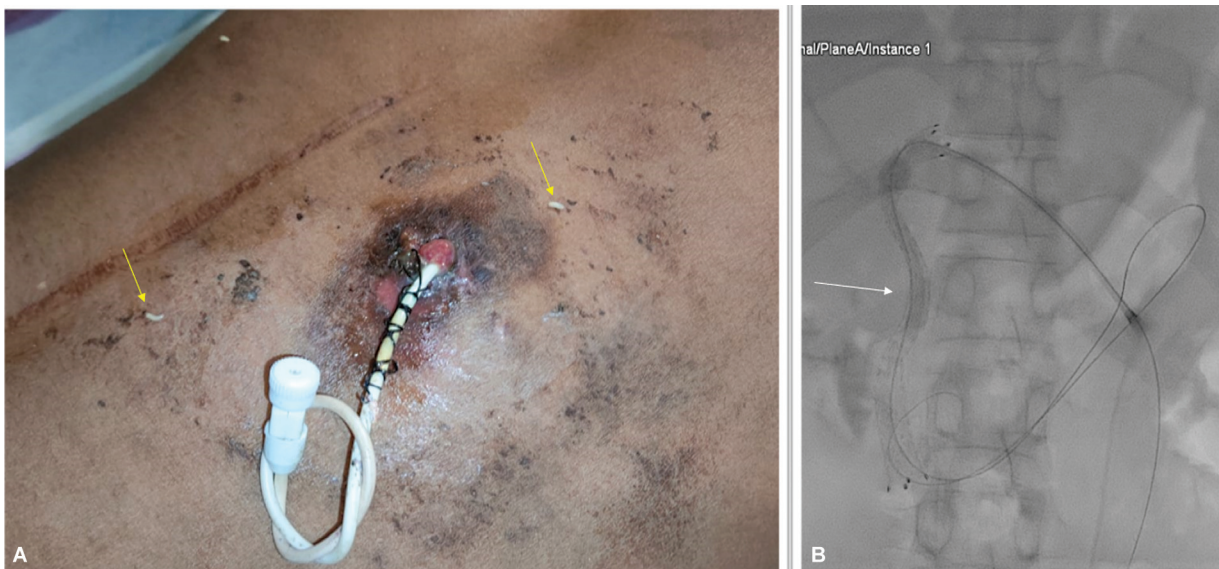

Fig. 2 (A) Skin puncture site with percutaneous biliary drainage tube (internal–external drainage tube (8.5 Fr, Cook Medical, Bloomington) after removal of the bile-soaked dressing shows multiple larvae crawling around the wound (arrows). (B) Spot radiograph showing placement of a metallic biliary stent with a check catheter in situ after treatment of myiasis.

Table 1 Laboratory parameters

	Pre-PTBD	Post-PTBD with internalization	PTBD with myiasis	Posttreatment of myiasis
Bilirubin (g/dL)	22.6	3.1	2.9	2.8
TLC (cells/mm ³)	9.8	10.1	9.7	8.1

Abbreviations: PTBD, percutaneous transhepatic biliary drainage; TLC, total leukocyte count.

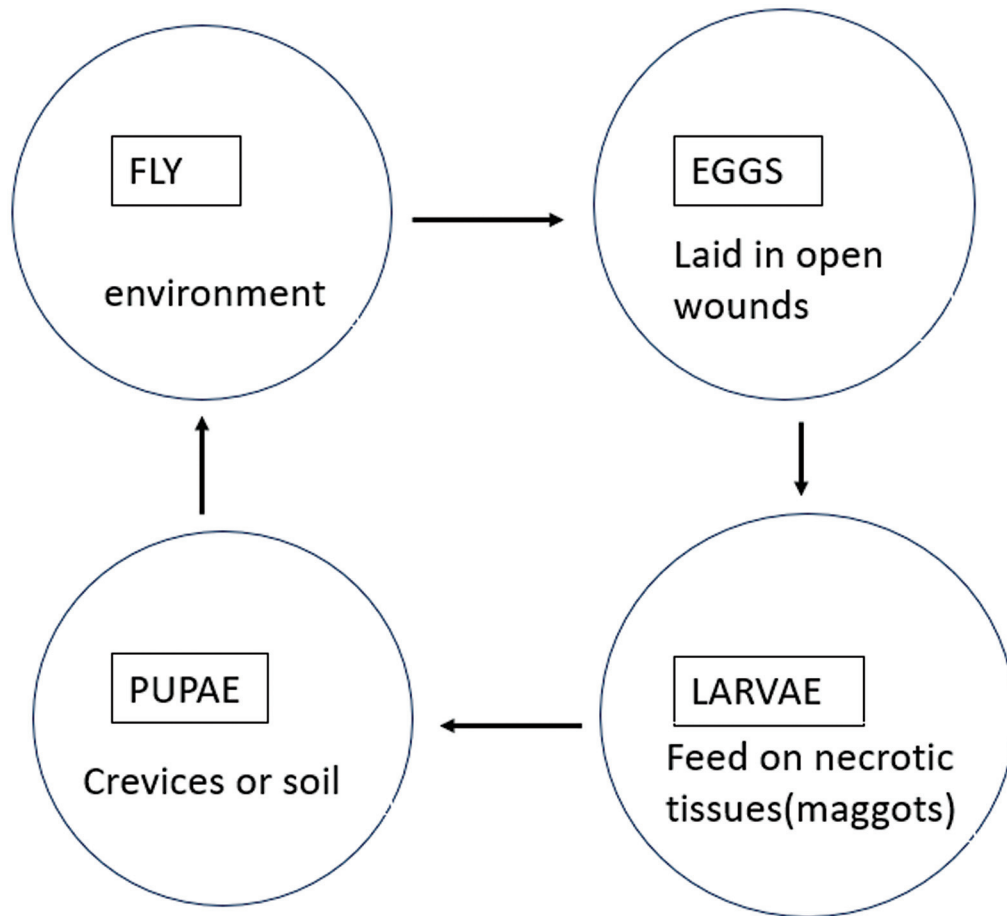


Fig. 3 Life cycle of a maggot. To eat or lay their eggs, female flies may visit the wounds. Typically, they lay 50 to 300 eggs at a time, which at skin temperature hatch 8 to 12 hours later. The eggs are around 1.7 mm long, and the hatching larvae are similar in size but harder to spot. When they first emerge, they grow quickly, reaching a maximum length of 7 to 8.5 mm in 24 hours at human skin temperature and reaching full size in just 50 to 60 hours. Upon ceasing to feed, they leave the tissue in search of a dry nook or patch of earth to pupate in (the life stage in which it attains maturation). It is uncommon to discover insects in this group debriding viable tissue; instead, they often only consume necrotic tissue and slough.

Three methods make up the general therapy concepts. The first step in killing the larvae is to apply a noxious material like turpentine oil or hypertonic saline. Usually, persistence is necessary. The larva is known to be paralyzed by lignocaine at a concentration of 1%. The second step is to cause local hypoxia by applying petroleum jelly. This closes off the airways, and maggots erupt after suffocating. The eradication of the maggots comes third. Avoid removing one by force. Maggots resist removal by digging their hook-like structures into the tissues. Forceful removal results in partial removal and can result in calcification, granulomatous inflammation, and allergy problems. In our case, the maggots disappeared after three applica-

tions of turpentine oil and oral and local application of ivermectin.⁵

Conclusion

Myiasis indicates poor hygiene and poor wound care. One of the differential diagnoses in long-term biliary drainage site infection should be myiasis.

Prevention can be achieved by eliminating the flies, proper education in catheter care, regular wound inspection, and hygienic practice. Diagnosis is entirely clinical, and management is with turpentine oil application, and oral and local ivermectin.

Funding

None.

Conflict of Interest

None declared.

References

- 1 Shukla AD, Kamath AT, Kudva A, Pai D, Patel N. Our experience in the management of traumatic wound myiasis: report of 3 cases and review of the literature. *Case Rep Dent* 2016;2016:7030925
- 2 Solomon M, Lachish T, Schwartz E. Cutaneous myiasis. *Curr Infect Dis Rep* 2016;18(09):28
- 3 Puthran N, Hegde V, Anupama B, Andrew S. Ivermectin treatment for massive orbital myiasis in an empty socket with concomitant scalp pediculosis. *Indian J Ophthalmol* 2012;60(03):225–227
- 4 Sunny B, Sulthana L, James A, Sivakumar T. Maggot infestation: various treatment modalities. *J Am Coll Clin Wound Spec* 2018;8(1–3):51–53
- 5 Mulawkar PM, Agrawal SG, Mulawkar UP, Panpaliya GS. Myiasis (maggots) around nephrostomy tube. *Urol Ann* 2021;13(04):438–441