



Comparison of Optic Nerve Sheath Diameter (ONSD) Measurements Obtained from USG Before and After Placement of Ventriculoperitoneal Shunt in Obstructive Hydrocephalus as a Surrogate Marker for Adequacy of Shunt Function: A Prospective Observational Study

M. S. Mohamed Salih¹ Adinarayanan Sethuramachandran² Prasanna Udipi Bidkar²^{ORCID} Ankita Dey³^{ORCID}
Gopikrishnan R.⁴ Adethen Gunasekaran² Vivek Chandar²

¹Department of Neuroanesthesiology, All India Institute of Medical Sciences, New Delhi, India

²Department of Anesthesiology and Critical Care, Jawaharlal Institute of Postgraduate Medical Education and Research, Puducherry, India

³Department of Anesthesiology and Critical Care, All India Institute of Medical Sciences, Bathinda, Bathinda, Punjab, India

⁴Department of Neurosurgery, Jawaharlal Institute of Postgraduate Medical Education and Research, Puducherry, India

Address for correspondence Adinarayanan Sethuramachandran, DA, DNB, Jawaharlal Institute of Postgraduate Medical Education and Research, Puducherry 605006, India (e-mail: adinarayanans@gmail.com).

Asian J Neurosurg 2024;19:242–249.

Abstract

Keywords

- ▶ computed tomography scan
- ▶ hydrocephalus
- ▶ optic nerve
- ▶ ultrasonography
- ▶ ventriculoperitoneal shunt

Introduction Optic nerve sheath diameter (ONSD) measured using ultrasonography has been widely used as a surrogate marker of elevated intracranial pressure. However, literature is sparse on the correlation between ONSD and ventriculoperitoneal (VP) shunt function, especially in adults with hydrocephalus. Our study was designed to assess the correlation between ONSD measured using ultrasonography before and 12 hours after VP shunt placement and the success of VP shunt placement assessed using computed tomography (CT) of the brain.

Materials and Methods Fifty-one patients between 16 and 60 years of age, with obstructive hydrocephalus scheduled for VP shunt surgery were included in this prospective, observational study. ONSD measurements were obtained from both eyes prior to induction of anesthesia, immediately after the surgery, and at 6, 12, and 24 hours after the surgery. An average of three readings was obtained from each eye. Cerebrospinal fluid (CSF) opening pressure was noted after entry into the lateral ventricle. Noncontrast CT (NCCT) brain was obtained 12 hours after the surgery and was interpreted by the same neurosurgeon for signs of successful VP shunt placement.

article published online
June 3, 2024

DOI <https://doi.org/10.1055/s-0044-1786701>.
ISSN 2248-9614.

© 2024. Asian Congress of Neurological Surgeons. All rights reserved.

This is an open access article published by Thieme under the terms of the Creative Commons Attribution-NonDerivative-NonCommercial-License, permitting copying and reproduction so long as the original work is given appropriate credit. Contents may not be used for commercial purposes, or adapted, remixed, transformed or built upon. (<https://creativecommons.org/licenses/by-nc-nd/4.0/>)

Thieme Medical and Scientific Publishers Pvt. Ltd., A-12, 2nd Floor, Sector 2, Noida-201301 UP, India

Results There was a significant reduction in ONSD in the postoperative period compared to ONSD measured preoperatively. The average ONSD (mean \pm standard deviation) measured prior to induction of anesthesia, immediately after the surgery, and at 6, 12, and 24 hours after the surgery was 5.71 ± 0.95 , 5.20 ± 0.84 , 5.06 ± 0.79 , 4.90 ± 0.79 , and 4.76 ± 0.75 mm, respectively. The mean CSF opening pressure was 19.6 ± 6.9 mm Hg. Postoperative NCCT brain revealed misplacement of the shunt tip in only one patient.

Conclusion ONSD measured using ultrasonography may be used as a reliable indicator of VP shunt function in adults with obstructive hydrocephalus.

Introduction

Hydrocephalus is defined as an active distension of the cerebral ventricles on account of inadequate passage of cerebrospinal fluid (CSF) from its point of production within the ventricular system of the brain to its point of absorption into the systemic circulation.¹ The prevalence of hydrocephalus is estimated at 85/100,000 worldwide.² If left untreated, hydrocephalus may result in elevated intracranial pressure (ICP), which may, in turn, result in catastrophic consequences such as cerebral ischemia and brainstem herniation.³ Therefore, early diagnosis and prompt management of elevated ICP could be potentially life-saving. CSF diversion procedures such as ventriculoperitoneal (VP) shunt surgery, endoscopic third ventriculostomy (ETV), or placement of an external ventricular drain are frequently performed to relieve raised ICP in patients with hydrocephalus.⁴ While invasive methods continue to remain the proverbial “gold standard” for monitoring ICP, they are associated with several complications such as infection, hemorrhage, and device failure or disconnection.⁵ In addition, invasive ICP monitoring is relatively contraindicated in the presence of coagulopathy, which is commonly encountered in patients with traumatic brain injury.^{6,7} Noninvasive methods of ICP monitoring may help circumvent the problems associated with invasive ICP monitoring. Among the various noninvasive modalities available for monitoring ICP, optic nerve sheath diameter (ONSD) assessment using ultrasonography (USG) has gained traction over the past decade.^{8–11} The CSF of the intracranial cavity also surrounds the optic nerve, which in turn is surrounded by a sheath of meningeal layers. An increase in ICP results in an increase in the radial pressure in the CSF surrounding the optic nerve, causing the diameter of the nerve sheath to increase. Therefore, serial measurements of ONSD may be used for detecting and monitoring raised ICP.¹²

Different modalities such as USG, computed tomography (CT), and magnetic resonance imaging (MRI) have been used for the assessment of ONSD.^{8,11,13,14} However, USG possesses certain advantages over CT and MRI, in that it is portable, can be used bedside, is relatively inexpensive, and does not incur the risk of exposure to radiation that is inherent to CT. According to studies, ONSD measured using USG is a reliable indicator of raised ICP.^{3,10,15} However, most of the studies evaluating USG ONSD in patients with hydrocephalus included

children as their study population.^{16–18} A few studies have evaluated the correlation of ONSD with ICP in adults with hydrocephalus.^{11,19,20} Nonetheless, literature is sparse on the correlation between ONSD measured using USG and the outcome of CSF diversion procedures in adults with hydrocephalus. A study conducted in a tertiary care center in the southern part of India deserves mention in this regard.²¹

Our study was designed as a prospective, observational trial in order to assess the correlation between ONSD measured using USG before and at 12 hours after the placement of a VP shunt in patients with obstructive hydrocephalus, between 16 and 60 years of age, and the success of the VP shunt placement assessed using CT scan. We also compared serial USG ONSD measurements at predetermined time points in the postoperative period in each patient, with their respective preoperative ONSD measurements.

Materials and Methods

Our study was designed as a prospective, observational trial. Fifty-one patients, between 16 and 60 years of age, who underwent VP shunt surgery for obstructive hydrocephalus, were enrolled after obtaining approval from the Institute Ethics Committee (JIP/IEC/2020/135) and registration with the Clinical Trials Registry-India (CTRI/2020/07/026895). The study was conducted at a tertiary care center in the southern part of India. Patients with ocular injuries and those who were scheduled for VP shunt surgery on account of an infectious etiology were excluded from the study. We specifically included patients with obstructive hydrocephalus because VP shunt in patients with intraparenchymal or intracerebral hemorrhage or in patients in whom CSF maybe turbid on account of a central nervous system infection, may get blocked by debris or red blood cells and platelet microthrombi, thereby resulting in an increased incidence of shunt blockage.²² Written informed consent was obtained from all the participants or their legal guardians, in patients less than 18 years of age, prior to their enrolment in the study. The sample size was calculated in accordance with a previous study.¹¹ The sample size for the study was estimated based on the sample size formula for paired *t*-test to assess the change in ONSD using USG before and after placement of a VP shunt. The sample size was estimated to be 51, considering a mean difference of 0.5 mm and a standard deviation (SD) of 1.25 mm, to be clinically significant, assuming a 5% level of

significance and 80% power. ONSD values between 4.78 and 5.3 mm were considered normal, based on published studies.^{23,24} Based on a similar study conducted by Bhandari et al, we expected the mean ONSD to reduce by 15 to 20% within 12 hours of the placement of a VP shunt.¹¹

During the preoperative visit, patients were evaluated for clinical features suggestive of raised ICP—headache, nausea, vomiting, altered sensorium, and blurring of vision—using a binary question and answer format (presence of symptom was recorded as “yes” and absence of symptom was recorded as “no”). After shifting the patient to the operation theatre, standard American Society of Anesthesiologists (ASA) monitors such as electrocardiogram, pulse oximeter, and noninvasive blood pressure were attached, and baseline parameters were noted. ONSD measurements from both eyes were obtained using an 8 to 12 MHz linear USG probe, before induction of anesthesia. The USG probe was generously lubricated and placed on the superolateral aspect of the closed eyelid. The optic nerve sheath was seen as a hypoechoic band dorsal to the globe. ONSD was measured at a depth of 3 mm behind the posterior sclera, with the cursor placed from the outer edge to the outer edge of the hypoechoic band, following the methodology described in a previous study.²⁵ The measurements were taken cautiously, avoiding any undue compression over the eyes. An average of three measurements was obtained from each side.²⁶ All the measurements were performed by an anesthesiologist with a minimum of 3 years of experience with the use of ultrasound. A standard induction protocol using injection fentanyl 1 to 2 mcg/kg, propofol 1 to 2 mg/kg, and vecuronium 0.1 mg/kg was followed. Anesthesia was maintained with 1 MAC of isoflurane in a mixture of oxygen and air.

The occipital approach was used for insertion of VP shunt in all the patients. A styleted catheter was introduced into the lateral ventricle. The stylet was then removed and the catheter was attached to a water column-based pressure transducer, which was zeroed at the level of the patient’s tragus, corresponding to the foramen of Monro. Strict aseptic precautions were adopted to ensure sterility while obtaining the measurements. The ICP value thus obtained was documented.

Using the methodology described earlier, ONSD measurements were obtained immediately after the surgery and at 6, 12, and 24 hours after the surgery. Noncontrast CT (NCCT) brain obtained 12 hours after the surgery was interpreted by a single neurosurgeon, who did not perform the surgery, for the following parameters indicative of successful shunt placement—location of shunt tip in the frontal horn of lateral ventricle, shrinkage of the ventricles, and resolution of periventricular haze. These findings were documented in the data collection pro forma. The patients were also assessed for resolution of clinical symptoms 12 hours after shunt insertion.

Statistical Analysis

All the statistical tests were performed using SPSS (version 18.0, IBM, United States). The categorical variables like presence of headache, vomiting, nausea, visual disturbances, and altered sensorium were expressed as frequency and percentage, whereas all the continuous variables like USG

ONSD and CSF opening pressure were expressed as mean and SD. The change in USG ONSD before and after the placement of the VP shunt was assessed using repeated measures of analysis of variance and post hoc Bonferroni paired comparisons. The change in the proportion of subjects in the study experiencing headache, vomiting, visual disturbance, and altered sensorium during the preoperative and postoperative period was assessed using McNemar’s test. All the tests were conducted at a 5% significance level, and a *p*-value of less than 0.05 was considered to be statistically significant.

Results

After obtaining informed written consent from patients or their legal guardians, 51 patients, between 16 and 60 years of age, belonging to the ASA Physical Status class 1, 2, and 3 were recruited in our prospective, observational study. The demographic characteristics of the study population are outlined in ►Table 1. The mean CSF opening pressure was 19.6 ± 6.9 mm Hg. Obstructive hydrocephalus developed secondary to brain tumors in all the patients in our study. Most of these tumors were situated in the posterior fossa.

We observed a significant reduction in ONSD measurements in the postoperative period compared to ONSD measured prior to induction of anesthesia. The average ONSD was 5.71 ± 0.95 mm in the preoperative period and 5.20 ± 0.84, 5.06 ± 0.79, 4.90 ± 0.79, and 4.76 ± 0.75 mm measured in the immediate postoperative period and at 6, 12, and 24 hours after the surgery, respectively. A reduction of ONSD of 8.9% from the average preoperative ONSD was observed in the immediate postoperative period. Subsequently, we noted a reduction of 11.4, 14.2, and 16.6% in ONSD at 6, 12, and 24 hours after the surgery, respectively (►Tables 2 and 3 and ►Fig. 1).

Table 1 Demographic variables

Variable	Mean ± SD/percentage/n
Age (y)	42.3 ± 13.9
Weight (kg)	57.9 ± 8.1
Gender (M:F) (n)	22:29
ASA-PS (1/2/3) (percentage)	19.6/58.8/21.6
Clinical features (n/percentage)	
Headache	45 (88)
Vomiting	23 (45)
Nausea	22 (43)
Blurring of vision	20 (39)
Altered sensorium	16 (31)
CSF opening pressure (mm Hg)	19.6 ± 6.9

Abbreviations: ASA-PS, American Society of Anesthesiologists Physical Status; CSF, cerebrospinal fluid; M:F, male:female; SD, standard deviation.

Table 2 ONSD values measured at different time points

Time	ONSD right eye (mm) Mean ± SD	ONSD left eye (mm) Mean ± SD	ONSD average of both eyes (mm) Mean ± SD
Before induction	5.7 ± 0.9	5.7 ± 1	5.71 ± 0.95
Immediate postoperative	5.2 ± 0.8	5.2 ± 0.8	5.2 ± 0.84
6 hours after the surgery	5.1 ± 0.8	5.1 ± 0.8	5.06 ± 0.79
12 hours after the surgery	4.9 ± 0.8	4.9 ± 0.8	4.90 ± 0.79
24 hours after the surgery	4.8 ± 0.8	4.8 ± 0.7	4.76 ± 0.75
Repeated measures ANOVA	$p < 0.001$		

Abbreviations: ANOVA, analysis of variance; ONSD, optic nerve sheath diameter; SD, standard deviation.
Note: Repeated measures ANOVA was the statistical test used.

Table 3 Post hoc Bonferroni correction for paired comparisons of average ONSD

Time points at which ONSD was measured	Post hoc Bonferroni correction
Preoperative vs. Immediate postoperative	< 0.001
Preoperative vs. 6 hours postoperative	< 0.001
Preoperative vs. 12 hours postoperative	< 0.001
Preoperative vs. 24 hours postoperative	< 0.001

Abbreviation: ONSD, optic nerve sheath diameter.

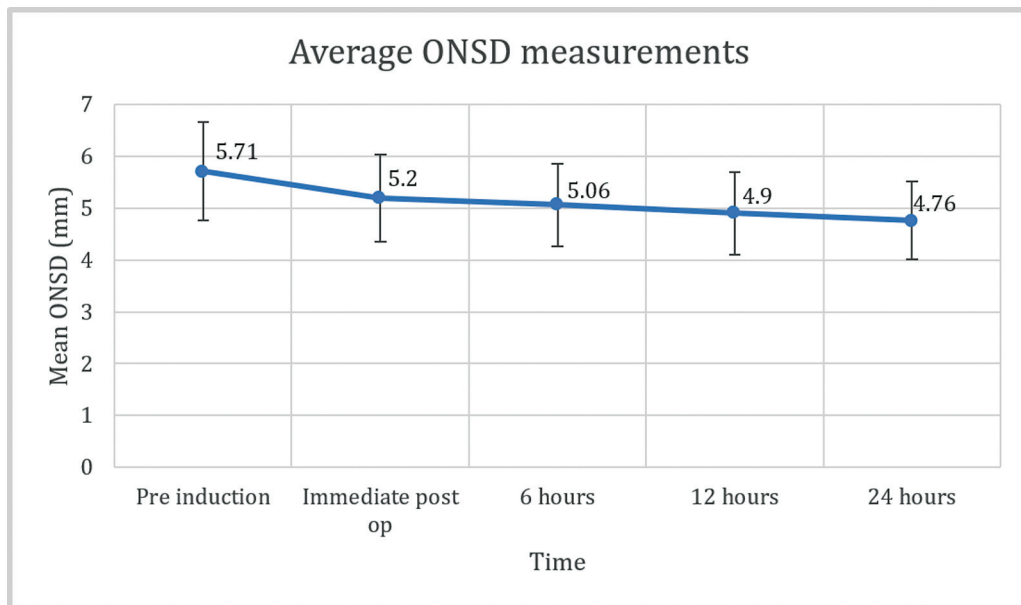


Fig. 1 Average ONSD of both eyes at predetermined time points. ONSD, optic nerve sheath diameter; mm, millimeters.

All the patients were also assessed for clinical improvement of symptoms 12 hours after completion of the surgery. Among the 45 patients who presented with headache, 39 of them reported resolution of symptoms 12 hours following the surgery. Twenty-three patients presented with vomiting and 22 patients presented with nausea. All of them had complete resolution of symptoms 12 hours after the surgery. Sixteen out of the 20 patients who had preoperative visual problems had complete resolution of symptoms when they were assessed 12 hours after the surgery. Eleven out of the 16

patients who presented with altered sensorium recovered completely 12 hours after the surgery (►Table 4).

NCCT brain was done for all the patients 12 hours after the surgery. Among the 51 patients recruited in the study, accurate placement of the tip of the VP shunt in the frontal horn of the lateral ventricle was confirmed on imaging in all but one patient. Shrinkage of ventricles was observed in 49 patients and resolution of periventricular haze was observed in 28 patients (►Fig. 2). The shunt tip was misplaced in only one patient. Prior to surgery, this patient’s average ONSD was

Table 4 Clinical features in the preoperative period and 12 hours postoperatively

Clinical features	Preoperative (n = 51)		12 hours postoperative (n = 51)		McNemar test p-value
	Present	Absent	Present	Absent	
Headache	45 (88.2%)	6 (11.8%)	6 (11.8%)	45 (88.2%)	< 0.001
Vomiting	23 (45%)	28 (54.9%)	0 (0%)	51 (100%)	N/A
Nausea	22 (43.1%)	29 (56.8%)	0 (0%)	51 (100%)	N/A
Blurring of vision	20 (39.2%)	31 (60.7%)	4 (7.8%)	47 (92.1%)	< 0.001
Altered sensorium	16 (31.3%)	35 (68.6%)	5 (9.8%)	46 (90.1%)	0.001

Abbreviation: N/A, not applicable.

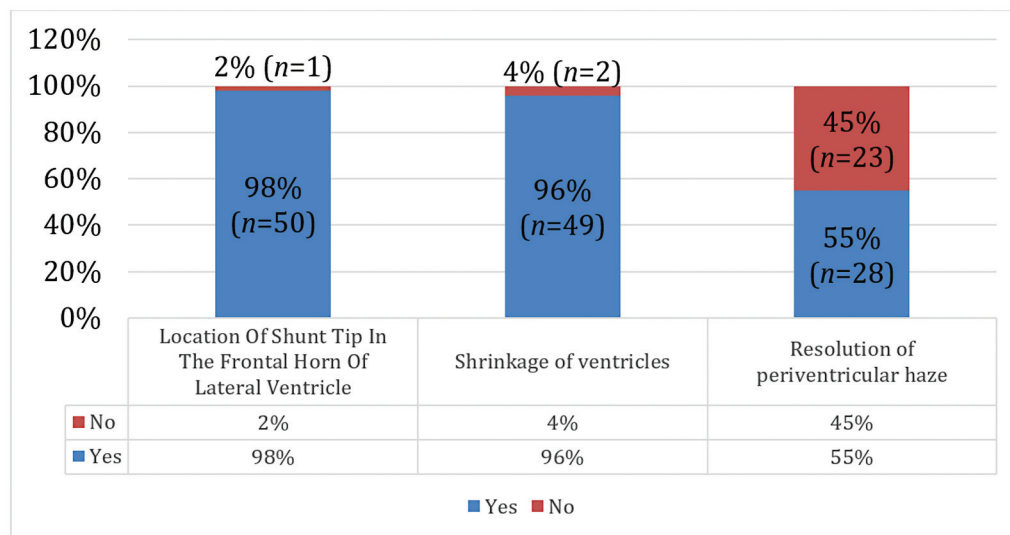


Fig. 2 Bar diagram depicting the NCCT brain findings after VP shunt placement. n, number of patients; NCCT, noncontrast computed tomography; VP shunt, ventriculoperitoneal shunt.

6.13 mm. Average ONSD measured immediately after the surgery and at 6, 12, and 24 hours after the surgery was 6.20, 6.30, 6.27, and 5.98 mm, respectively. Also, he had presented with headache, which did not resolve after the surgery. This patient was one of the two patients whose postoperative NCCT brain did not show shrinkage of ventricles. He underwent shunt revision surgery following which symptomatic improvement was observed. The other patient's symptoms resolved after the surgical procedure and he continued to remain asymptomatic until his discharge from the hospital. NCCT brain performed on his follow-up visit demonstrated complete resolution of hydrocephalus.

Discussion

Our results demonstrate that ONSD derived from USG may be used as a reliable surrogate marker for the adequacy of VP shunt function as assessed by NCCT brain, in patients with obstructive hydrocephalus. We observed a significant reduction in ONSD values in the postoperative period ($p < 0.001$). Bonferroni correction performed for paired comparisons of average ONSD (preoperative vs. immediate postoperative, 6,

12, and 24 hours postoperative) was also statistically significant (\rightarrow Tables 2 and 3).

ONSD Measurements

Sonographic assessment of the optic nerve for the detection of intracranial hypertension has been in use in clinical practice since as early as the 1980s.²⁷ Ultrasonographic assessment of ONSD is a noninvasive, reliable, and reproducible technique that can be performed quickly at the bedside for the detection of elevated ICP.^{17,28,29} Several studies have demonstrated that an increase in ONSD correlates well with intracranial hypertension.^{10,15,29,30} However, there is a wide variation in the reported values of ONSD cutoffs in the literature for the detection of raised ICP. In a prospective, observational study on 41 adult neurosurgical patients, with invasive ICP monitoring in place, admitted in the neurosurgical intensive care unit, by Raffiz et al, the authors found that ONSD value of 5.20 mm was found to have a sensitivity of 95.8% and specificity of 80.4% for the detection of elevated ICP. In addition, the authors also found a significant correlation between ONSD and invasively measured ICP, with a correlation coefficient of 0.82.³¹ In another prospective,

observational study conducted on 51 patients scheduled for VP shunt surgery or ETV for hydrocephalus, Subramanian et al found that the sensitivity and the specificity of ONSD cutoff value of 5.5 mm to detect ICP \geq 20 mm Hg was 94.9 and 66.7%, respectively. The sensitivity of ONSD cutoff value of 5.5 mm to detect ICP > 22 mm Hg and ICP > 25 mm Hg were 91.4 and 88.4%, respectively. However, the specificity of the aforementioned ONSD cutoff decreased to less than 50% for the detection of ICP \geq 22 mm Hg. The authors observed a strong correlation between ONSD \geq 5.5 mm and clinical and radiological features of elevated ICP. Furthermore, the authors also observed a progressive decrease in ONSD following the CSF diversion procedure, with the lowest ONSD recorded on the 7th postoperative day.²¹ In accordance with the findings of the study conducted by Subramanian et al, we also observed a significant decrease in ONSD measurements following the insertion of a VP shunt. However, unlike Subramanian et al who included children older than 10 years of age as well as adults with hydrocephalus regardless of the etiology in their study, we included patients between 16 and 60 years of age with obstructive hydrocephalus only. Our findings are also in agreement with a prospective, observational study conducted by Chopra et al, on 40 adults scheduled for CSF diversion procedures, where the authors observed a significant decrease in ONSD following CSF diversion procedure. The authors also found that an ONSD cutoff value of 5.85 mm was able to predict ICP > 20 mm Hg with a sensitivity of 92.3% and a specificity of 85.7%.⁴ In a recently published prospective study conducted by Sahu et al on 30 adults scheduled for surgical procedures for the management of intracranial hypertension, the authors observed that an ONSD cutoff value > 5.5 mm predicted ICP > 20 mm Hg with a sensitivity of 100% and a specificity of 75%. The authors also identified ONSD cutoffs of 6.3, 6.5, and 6.7 mm for predicting ICP greater than 25, 30, and 35 mm Hg, respectively.³² Regardless of the ONSD cutoff for detection of intracranial hypertension, it can be agreed upon that ONSD correlates well with invasively measured ICP in patients with varied neurological and neurosurgical pathologies, especially when the ICP is between 20 and 25 mm Hg. A reduction in ICP results in a progressive reduction in ONSD as well.

Preoperative and Postoperative ONSD Values

We found a significant reduction in serial USG ONSD after VP shunt insertion (► **Table 2**, ► **Fig. 1**). The mean preoperative and 12 hours postoperative ONSD of both eyes were 5.71 ± 0.95 and 4.90 ± 0.79 mm ($p < 0.001$), respectively. Our findings are in agreement with those of Bhandari et al, who measured ONSD using both USG and CT before and after 12 hours of placement of VP shunt, in 69 patients between 2 and 60 years of age.¹¹ In their prospective, observational study, the mean preoperative and postoperative (12 hours after shunt placement) ONSD measurements by USG were 5.80 ± 0.63 and 4.52 ± 0.72 , respectively, among adults, and 4.76 ± 1.14 and 3.90 ± 1.08 mm before and 12 hours after VP shunt placement, respectively, in the pediatric population. The authors also observed a good correlation between ONSD measurements obtained from USG and ONSD measurements

obtained from CT (interclass correlation coefficient = 0.97; $p < 0.001$). Their findings further emphasize the reliability of ONSD measured using USG as a surrogate marker for the efficacy of VP shunt. Our findings are concordant with those of Choi et al who compared the ONSD measured with USG before and within 30 minutes of VP shunt placement on 34 children, undergoing VP shunt surgery for the treatment of hydrocephalus. ONSD values, after induction of anesthesia, before shunt placement were 5.4 ± 0.6 and 5.3 ± 0.7 mm in the right and left eye, respectively. The authors observed a significant reduction in ONSD values to 4.4 ± 0.5 and 4.5 ± 0.7 mm in the right and left eye, respectively, within 30 minutes of the completion of the surgery.³³ However, we included patients over 16 years of age in our study.

Subramanian et al obtained serial ONSD measurements using USG in 51 patients undergoing CSF diversion procedures. ONSD was measured before surgery, on postoperative days 1, 3, and 7 on all 51 patients and on 31 patients at follow-up at a median duration of 12 months. The authors observed a significant reduction in ONSD on day 3 and day 7 after the CSF diversion procedure compared with the preoperative measurements in patients with successful CSF diversion. The maximum reduction in ONSD was observed on the 7th postoperative day, when 95% of the patients had ONSD < 5.5 mm. Further reduction in ONSD was observed in 78.6% of the patients during follow-up.²¹ We performed serial ONSD measurements till 24 hours after the placement of VP shunt. We observed a maximum reduction in ONSD of 16.6% measured 24 hours after the surgery, compared to ONSD measured preoperatively.

ONSD and VP Shunt Misplacement

The overall incidence of complications following VP shunt surgery is 23.8%.³⁴ Shunt migration or misplacement is observed in approximately 1 in 1,000 patients following VP shunt surgery.³⁵ In their retrospective analysis of data obtained from 227 adults who had undergone VP shunt surgery between 2001 and 2011, Khan et al noted that the overall incidence of shunt malfunction was 15.4%, of which shunt migration accounted for 0.9%. The median time for shunt malfunction from the day of shunt placement was 120 days. Furthermore, the authors also observed a significant association between the etiology of hydrocephalus and shunt malfunction ($p = 0.03$).²² Only one patient (2%) in our study developed shunt misplacement, accounting for shunt failure. Among the various factors that significantly affect the shunt function, an important factor is the presence of blood. In patients with intracerebral or intraparenchymal hemorrhage, the shunt may get clogged, thereby affecting the drainage of CSF.²² Also, shunt misplacement is comparatively higher among children, compared to adults. In a comprehensive review of the literature on shunt migrations performed by Harischandra et al, a total of 396 shunt migrations were noted, 71.2% of which were noted in the pediatric age group.³⁵ The low rate of shunt malfunction in our study may be attributed to the fact that we only enrolled patients between 16 and 60 years of age with obstructive hydrocephalus in our study. In addition, our follow-up period was

restricted to 24 hours postoperatively. This is one of the limitations of our study. We also observed that there was no reduction in ONSD in the postoperative period in the patient who developed shunt malfunction in our study. Our findings are in agreement with the findings of Subramanian et al.²¹ In their study, 3 out of the 31 patients who presented for long-term follow-up had shunt dysfunction. In all these 3 patients, ONSD at follow-up was significantly higher than ONSD measured on the 7th postoperative day, implying a correlation between ONSD and shunt failure. Similarly, Padayachy et al, in their retrospective analysis of preoperative and postoperative MRI scans of 24 children who had undergone ETV, found that in patients with successful ETV ($n = 19$), the mean change in ONSD was 0.73 mm and in patients with a failed ETV ($n = 5$), the mean change in ONSD was 0.18 mm ($p = 0.0007$). In addition, a change in MRI ONSD of 7.5% from the initial measurement was found to have a sensitivity of 92.9% and a specificity of 85.7% for the outcome of ETV.¹⁶ These findings suggest that ONSD may be used as a marker for the efficacy of CSF diversion procedures.

ONSD and Resolution of Clinical Features

We assessed all the patients for clinical improvement 12 hours after VP shunt surgery, along with ONSD measurements. We observed that 86.7% of the patients who presented with headache and all patients with preoperative nausea and vomiting recovered completely. Eighty-five percent of the patients with preoperative visual problems recovered. Note that 68.8% of the patients who presented with altered sensorium experienced complete resolution of their symptoms (► **Table 4**). Our findings are concordant with those of Subramanian et al, who observed that reduction in ONSD values correlated well with resolution of symptoms such as visual disturbances and headache.²¹ A correlation between ONSD measured by MRI and resolution of clinical features of hydrocephalus was also observed by Singhal et al in 16 children who underwent either ETV or tumor resection for the management of hydrocephalus.¹⁸

Our findings suggest that ONSD measurements obtained using USG may be used as a reliable indicator of VP shunt function in adult patients with obstructive hydrocephalus. Our study has few limitations. The incidence of shunt failure in our study was only 2%, which is significantly lower than the numbers reported in literature.^{22,35} Therefore, we could not perform a correlation analysis between ONSD measurements and CT findings suggestive of successful or unsuccessful VP shunt placement. Also, the duration of follow-up in our study was limited to 24 hours, which may not be sufficient for the development of shunt malfunction.

Conclusion

ONSD measured using USG may be used as a reliable indicator of VP shunt function in adult patients with obstructive hydrocephalus. However, larger studies are warranted to extrapolate our findings to patients with hydrocephalus attributable to different etiologies.

Authors' Contributions

The concept and design of the review article were developed by P.U.B., A.D., A.S., and S.M. Data acquisition, analysis, and manuscript preparation were carried out by P.U.B., A.G., V.C., and S.M. Critical revision and finalization of the manuscript were conducted by P.U.B., A.D., and A.S.. All authors contributed to the conceptualization and design of the review article. Additionally, all authors have thoroughly reviewed and approved the manuscript, attesting to its integrity and authenticity.

Conflict of Interest

None declared.

References

- 1 ReKate HL. A contemporary definition and classification of hydrocephalus. *Semin Pediatr Neurol* 2009;16(01):9-15
- 2 Isaacs AM, Riva-Cambrin J, Yavin D, et al. Age-specific global epidemiology of hydrocephalus: systematic review, meta-analysis and global birth surveillance. *PLoS One* 2018;13(10):e0204926
- 3 Dubourg J, Javouhey E, Geeraerts T, Messerer M, Kassai B. Ultrasonography of optic nerve sheath diameter for detection of raised intracranial pressure: a systematic review and meta-analysis. *Intensive Care Med* 2011;37(07):1059-1068
- 4 Chopra A, Das PK, Parashar S, et al. Clinical Relevance of Transorbital Ultrasonographic Measurement of Optic Nerve Sheath Diameter (ONSD) for Estimation of Intracranial Pressure Following Cerebrospinal Fluid Diversion Surgery. *Cureus*. Accessed July 18, 2022 at: <https://www.cureus.com/articles/67294-clinical-relevance-of-transorbital-ultrasonographic-measurement-of-optic-nerve-sheath-diameter-onsd-for-estimation-of-intracranial-pressure-following-cerebrospinal-fluid-diversion-surgery>
- 5 Zhang X, Medow JE, Iskandar BJ, et al. Invasive and noninvasive means of measuring intracranial pressure: a review. *Physiol Meas* 2017;38(08):R143-R182
- 6 Böhm JK, Güting H, Thorn S, et al. Global characterisation of coagulopathy in isolated traumatic brain injury (iTBI): a center-TBI analysis. *Neurocrit Care* 2021;35(01):184-196
- 7 Zhang J, Zhang F, Dong JF. Coagulopathy induced by traumatic brain injury: systemic manifestation of a localized injury. *Blood* 2018;131(18):2001-2006
- 8 Kalantari H, Jaiswal R, Bruck I, et al. Correlation of optic nerve sheath diameter measurements by computed tomography and magnetic resonance imaging. *Am J Emerg Med* 2013;31(11):1595-1597
- 9 Hall MK, Spiro DM, Sabbaj A, Moore CL, Hopkins KL, Meckler GD. Bedside optic nerve sheath diameter ultrasound for the evaluation of suspected pediatric ventriculoperitoneal shunt failure in the emergency department. *Childs Nerv Syst* 2013;29(12):2275-2280
- 10 Goeres P, Zeiler FA, Unger B, Karakitsos D, Gillman LM. Ultrasound assessment of optic nerve sheath diameter in healthy volunteers. *J Crit Care* 2016;31(01):168-171
- 11 Bhandari D, Dupui Bidkar P, Adinarayanan S, Narmadhalakshmi K, Srinivasan S. Measurement of changes in optic nerve sheath diameter using ultrasound and computed tomography scan before and after the ventriculoperitoneal shunt surgery in patients with hydrocephalus - a prospective observational trial. *Br J Neurosurg* 2019;33(02):125-130
- 12 Evensen KB, Eide PK. Measuring intracranial pressure by invasive, less invasive or non-invasive means: limitations and avenues for improvement. *Fluids Barriers CNS* 2020;17(01):34
- 13 Bäuerle J, Schuchardt F, Schroeder L, Egger K, Weigel M, Harloff A. Reproducibility and accuracy of optic nerve sheath diameter

- assessment using ultrasound compared to magnetic resonance imaging. *BMC Neurol* 2013;13:187
- 14 Geeraerts T, Newcombe VF, Coles JP, et al. Use of T2-weighted magnetic resonance imaging of the optic nerve sheath to detect raised intracranial pressure. *Crit Care* 2008;12(05):R114
 - 15 Ballantyne J, Hollman AS, Hamilton R, et al. Transorbital optic nerve sheath ultrasonography in normal children. *Clin Radiol* 1999;54(11):740–742
 - 16 Padayachy LC, Kilborn T, Carrara H, Figaji AA, Fieggen GA. Change in optic nerve sheath diameter as a radiological marker of outcome from endoscopic third ventriculostomy in children. *Childs Nerv Syst* 2015;31(05):721–728
 - 17 Padayachy LC, Padayachy V, Galal U, Gray R, Fieggen AG. The relationship between transorbital ultrasound measurement of the optic nerve sheath diameter (ONSD) and invasively measured ICP in children : part I: repeatability, observer variability and general analysis. *Childs Nerv Syst* 2016;32(10):1769–1778
 - 18 Singhal A, Yang MMH, Sargent MA, Cochrane DD. Does optic nerve sheath diameter on MRI decrease with clinically improved pediatric hydrocephalus? *Childs Nerv Syst* 2013;29(02):269–274
 - 19 Lee HC, Lee WJ, Dho YS, Cho WS, Kim YH, Park HP. Optic nerve sheath diameter based on preoperative brain computed tomography and intracranial pressure are positively correlated in adults with hydrocephalus. *Clin Neurol Neurosurg* 2018;167:31–35
 - 20 Wang J, Li K, Li H, et al. Ultrasonographic optic nerve sheath diameter correlation with ICP and accuracy as a tool for noninvasive surrogate ICP measurement in patients with decompressive craniotomy. *J Neurosurg.* 2019;133(02):514–520
 - 21 Subramanian S, Nair S, Moorthy RK, et al. Utility of serial optic nerve sheath diameter measurements in patients undergoing cerebral spinal fluid diversion procedures for hydrocephalus. *World Neurosurg* 2021;154:e168–e175
 - 22 Khan F, Rehman A, Shamim MS, Bari ME. Factors affecting ventriculoperitoneal shunt survival in adult patients. *Surg Neurol Int* 2015;6(01):25
 - 23 Ertl M, Knüppel C, Veitweber M, et al. Normal age- and sex-related values of the optic nerve sheath diameter and its dependency on position and positive end-expiratory pressure. *Ultrasound Med Biol* 2020;46(12):3279–3285
 - 24 Schroeder C, Katsanos AH, Richter D, Tsvigoulis G, Gold R, Krogias C. Quantification of optic nerve and sheath diameter by transorbital sonography: a systematic review and metanalysis. *J Neuroimaging* 2020;30(02):165–174
 - 25 Ohle R, Mclsaac SM, Woo MY, Perry JJ. Sonography of the optic nerve sheath diameter for detection of raised intracranial pressure compared to computed tomography: a systematic review and meta-analysis. *J Ultrasound Med* 2015;34(07):1285–1294
 - 26 Shirodkar CG, Rao SM, Mutkule DP, Harde YR, Venkatesowda PM, Mahesh MU. Optic nerve sheath diameter as a marker for evaluation and prognostication of intracranial pressure in Indian patients: an observational study. *Indian J Crit Care Med* 2014;18(11):728–734
 - 27 Gangemi M, Cennamo G, Maiuri F, D'Andrea F. Echographic measurement of the optic nerve in patients with intracranial hypertension. *Neurochirurgia (Stuttg)* 1987;30(02):53–55
 - 28 Rajajee V, Vanaman M, Fletcher JJ, Jacobs TL. Optic nerve ultrasound for the detection of raised intracranial pressure. *Neurocrit Care* 2011;15(03):506–515
 - 29 Thotakura AK, Marabathina NR, Danaboyina AR, Mareddy RR. Role of serial ultrasonic optic nerve sheath diameter monitoring in head injury. *Neurochirurgie* 2017;63(06):444–448
 - 30 Kavi T, Gupta A, Hunter K, Schreiber C, Shaikh H, Turtz AR. Optic Nerve Sheath Diameter Assessment in Patients with Intracranial Pressure Monitoring. *Cureus*. Accessed June 28, 2022 at: <https://www.cureus.com/articles/15434-optic-nerve-sheath-diameter-assessment-in-patients-with-intracranial-pressure-monitoring>
 - 31 Raffiz M, Abdullah JM. Optic nerve sheath diameter measurement: a means of detecting raised ICP in adult traumatic and non-traumatic neurosurgical patients. *Am J Emerg Med* 2017;35(01):150–153
 - 32 Sahu S, Panda N, Swain A, et al. Optic Nerve Sheath Diameter: Correlation With Intra-Ventricular Intracranial Measurements in Predicting Dysfunctional Intracranial Compliance. *Cureus*. Accessed July 20, 2022 at: <https://www.cureus.com/articles/50019-optic-nerve-sheath-diameter-correlation-with-intra-ventricular-intracranial-measurements-in-predicting-dysfunctional-intracranial-compliance>
 - 33 Choi SH, Min KT, Park EK, Kim MS, Jung JH, Kim H. Ultrasonography of the optic nerve sheath to assess intracranial pressure changes after ventriculo-peritoneal shunt surgery in children with hydrocephalus: a prospective observational study. *Anaesthesia* 2015;70(11):1268–1273
 - 34 Merkle AE, Ch'ang J, Parker WE, Murthy SB, Kamel H. The rate of complications after ventriculoperitoneal shunt surgery. *World Neurosurg* 2017;98:654–658
 - 35 Harischandra LS, Sharma A, Chatterjee S. Shunt migration in ventriculoperitoneal shunting: a comprehensive review of literature. *Neurol India* 2019;67(01):85–99