





A Computerized Tomography-Based Analysis of Spinal Canal Diameter to Study Its Implication on Cervical Spine Stenosis in Western Indian Population: A Retrospective Study

Isha Purohit¹ Sitaram Barath² Anjana Verma³ Kanishk Modi¹ Chelsi Purohit¹

¹ Geetanjali Medical College and Hospital, Udaipur, Rajasthan, India

² Department of Radiology, Geetanjali Medical College and Hospital, Udaipur, Rajasthan, India

³ Department of Community Medicine, Geetanjali Medical College and Hospital, Udaipur, Rajasthan, India

Address for correspondence Isha Purohit, MBBS student, 13 Prem Nagar, A-block, Chandanwadi, Udaipur 313001, Rajasthan, India (e-mail: ishapurohit01@gmail.com).

Indian J Neurosurg

Abstract

Background The cervical spine is prone to various conditions necessitating early detection. Morphometric analysis through computed tomography (CT) scans plays a pivotal role in diagnosing and preventing severe diseases. This study focuses on understanding the morphometric details of the cervical canal in the West Indian population, addressing a geographical gap in existing literature. The primary objective of this study was to perform a morphometric analysis of the cervical spine to study the implications it can have on cervical canal stenosis in the West Indian population.

Materials and Methods This study utilizes imaging data from the CT database of 100 individuals (73 men and 27 women). Measurements such as transverse canal diameter, sagittal canal diameter, cross-sectional canal surface area (CSA), and vertebral body diameter (VBD) were collected and the Pavlov-Torg ratio (PTR) was calculated from C2 to C7.

Results Notable findings include significant differences in CSA and VBD between genders, while PTR indicated cervical damage in 40% of participants. Multinomial regression was applied which signified an association between weakness and PTR.

Conclusion This study can be used to highlight the CT scan's importance in studying bony structures and the call for more region-specific morphometric studies. The variations in morphometric parameters could provide insights into understanding the vulnerabilities of a population belonging to a particular geographic area, in our case, the West Indian population.

Keywords

- ▶ cervical stenosis
- ▶ CT
- ▶ functional imaging
- ▶ spinal cord

Introduction

The cervical spine plays an important role in maintaining neurological well-being by protecting the spinal cord from various illnesses and traumas. It is, however, susceptible to several ailments that can inflict a considerable burden on the nervous system leading from disability to death. The course

followed by these diseases may range from manifesting with mild symptoms, like neck pain or radiating discomfort throughout the upper body, to being completely asymptomatic. An example of such disease is cervical spine stenosis which is known to have an insidious onset.¹ Symptoms develop over time and worsen as the condition declines. In a morphometric study by Lee et al, it was found

DOI <https://doi.org/10.1055/s-0044-1786173>.
ISSN 2277-954X.

© 2024. The Author(s).

This is an open access article published by Thieme under the terms of the Creative Commons Attribution License, permitting unrestricted use, distribution, and reproduction so long as the original work is properly cited. (<https://creativecommons.org/licenses/by/4.0/>)

Thieme Medical and Scientific Publishers Pvt. Ltd., A-12, 2nd Floor, Sector 2, Noida-201301 UP, India

that cervical spine stenosis has a prevalence of 4.9% in the adult population.² The risk only increases with the patient's age.³ Plain radiographs such as X-rays and other modalities such as computed tomography (CT) scans and magnetic resonance imaging (MRI) have proven useful in the diagnosis of degenerative spinal diseases which are often associated with variations in the spine morphometry and can be caught early through these diagnostic measures. Examples would be the sagittal canal diameter (SCD), transverse canal diameter (TCD), and Pavlov-Torg ratio (PTR) all of which can be measured on lateral radiographs. Individuals with narrow cervical canal tend to go unnoticed unless the condition is superimposed by a cervical injury, in such cases, morphometric analysis has proven to be an early indicator as well as a diagnostic tool.⁴⁻⁶ The PTR is one such ratio that can be applied to radiographs such as CT scans, MRI, and X-rays which serve as an indicator for cervical spine stenosis.⁷⁻⁹ A ratio less than 0.7 to 0.8 is an indicator of severe neurological damage. Though the PTR lacks specificity, it is sensitive to cervical stenosis and can be used as a screening tool for degenerative diseases. Many studies have been conducted on long-term degenerative diseases which compare the preoperative and postoperative morphometric outcomes using the modified Japanese Orthopaedic Association scores which have yielded adequate results.¹⁰ Studies have also revealed that variations in the cervical spine are influenced by factors such as ethnicity, geography, and gender which provides the need to collect data from different geographical locations to assess regional morphometric analysis. Through this study, we aimed to understand the morphometric analysis of the cervical spine in the West Indian population. The data obtained from our study could be important in understanding the details of the cervical spine, enhancing our understanding of the prevalence of cervical spine stenosis in the western Indian population.

Materials and Methods

The research was conducted at a tertiary hospital in western Rajasthan in the department of radiology from June 2023 to

December 2023. The objective of this study was to perform a morphometric analysis of the cervical spine to understand its implications on cervical stenosis. The study included 100 adults who visited the department for CT, contrast-enhanced CT, and noncontrast CT scans of the cervical spine, peripheral nervous system, neck and thorax, chest, and full-body scans. Phone numbers of participants were obtained from their files while maintaining strict confidentiality to safeguard patient information. All individuals above the age of 18 during the study period were eligible and selected using a random sampling technique. Individuals whose PTR was below 0.8 and 0.7 were contacted, and verbal consent was obtained through phone communication. The patient's history, including their name, age, sex, height, weight, indication for the scan, and neurological problems they faced, was obtained. Patients whose primary indication for the scan was severe debilitating neck pain, spinal trauma, congenital malformation of the cervical spine, malignant cancer of the neck presenting with more than one neurological symptom, and those suffering from any other pathology affecting the cervical spine were excluded. Additionally, patients under the age of 18 were excluded from the study. The spinal canal dimensions including TCD, cross-sectional canal surface area (CSA), vertebral body diameter (VBD), and SCD were calculated from C2 to C7. The PTR was computed for each vertebra following the procedure abstracted by Pavlov et al.⁷ Before commencing the study, ethical clearance was obtained from the Ethical Committee of Geetanjali Medical College and Hospital, Udaipur, Rajasthan, India. The data were compiled in Microsoft Excel 2019, and statistical analysis was performed using IBM SPSS software. Significance was described to be $p < 0.05$ (→ Fig. 1).

Result

The data from 100 patients was chosen for this study from the CT database of a tertiary hospital in western Rajasthan. The TCD, SCD, CSA, VBD, and PTR were measured from the C2

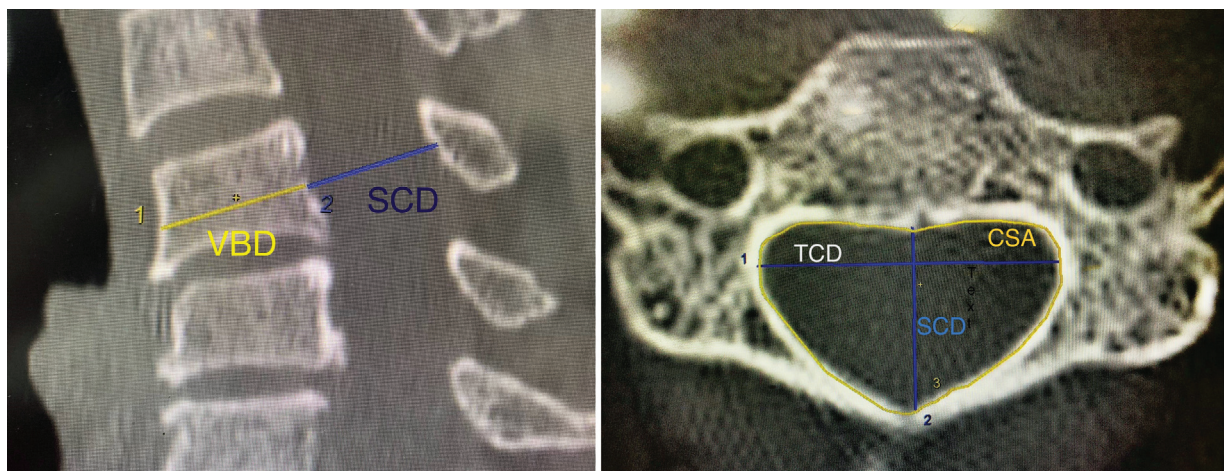


Fig. 1 Computed tomography (CT) image of cervical sign showing mid-sagittal anteroposterior diameter, vertebral body diameter, and canal surface area.

Table 1 Analysis of the characteristics of subjects with PTR < 0.8 (N = 40)

Variable	Percentage (%) / Mean ± SD
Gender	
1. Male	31 (77.5)
2. Female	9 (22.5)
Age (y)	50.42 ± 14.42
Weight	
1. 40–49	3 (7.5)
2. 50–59	25 (62.5)
3. 60–69	5 (12.5)
4. 70–79	3 (7.5)
5. > 80	4 (10)
Height	
1. 141–150	1 (2.5)
2. 151–160	26 (65)
3. 161–170	11 (27.5)
4. 171–180	2 (5)
Indication for scan	
1. Neck pain	
Mild	0
Moderate	4 (10)
Severe	0
2. Other	
Benign tumor	
Neck	8 (22)
Nose	3 (8)
Oral cavity cancer	15 (41.6)
Postoperative scan	10 (27.7)
Neurological sign	
1. Neck pain	1 (2.5)
2. Numbness	3 (7.5)
3. Weakness	5 (12.5)
4. All of the above	8 (20)
5. None	23 (57.5)

Abbreviations: PTR, Pavlov-Torg ratio; SD, standard deviation.

to C7 level. The mean age of the study population was 50.24 ± 1.488 (→ **Table 1**). A total of 73% of the participants were men and 27% were women. The values for both subjects were calculated individually and together using one-way analysis of variance (→ **Tables 2** and **3**). Individuals whose PTR was below 0.8 and 0.7 were contacted, and their

indication for scan, neurological signs and symptoms, weight, height, and age were calculated (→ **Table 1**). Multinomial logistic analysis of PTR value at every cervical level and the neurological symptom was carried out in IMB SPSS 16.0 (→ **Tables 3** and **5**).

Transverse Canal Diameter

The highest and narrowest TCD was measured in both men and women at the level of C6 and C3 vertebrae, respectively (C6 = 25.349 ± 1.627 vs. 25.014 ± 1.806; C3 = 23.265 ± 1.453 vs. 22.648 ± 1.295). No significance was reported (*p* < 0.29).

Sagittal Canal Diameter

The highest SCD was measured at the level of C2 vertebrae (men = 17.32 ± 2.388 vs. women = 16.570 ± 1.39) and narrowest at C6 in women (13.244 ± 1.753) and C4 in men (13.16 ± 1.654). The *p*-value was reported as 0.52, hence no significance was found.

Canal Surface Area

The CSA held the most significant differences between men and women with *p*-value of < 0.04. In men, the highest area was 74.867 ± 5.415 at C2, and the narrowest was 67.460 ± 6.213 at C7. In women, the height was 70.551 ± 4.300 at C2, and the narrowest 62.048 ± 5.071 at C7. In both, the highest and narrowest were at the same level.

Vertebral Body Diameter

The highest VBD was measured at C2 in both men and women (16.728 ± 1.952 vs. 15.555 ± 1.741) while the narrowest was at C7 in men (16.493 ± 1.987) and C4 in women (14.855 ± 2.069). The significance was found to be 0.00.

Pavlov-Torg Ratio

The PTR was calculated by dividing the mid-sagittal diameter of the cervical spine by the sagittal diameter of the vertebral body.⁷ No significance was found between men and women at any level except at C3 (men = 0.842 ± 0.157; women = 0.918 ± 0.167) and C5 (men = 0.842 ± 0.157; women = 0.843 ± 0.176). The *p*-value was reported to be 0.33.

Of the 100 participants, 40% had PTR < 0.8 and < 0.7 which signifies cervical damage.⁷⁻⁹ Further information

Table 2 The mean ± SD of the cervical spine in all women (N = 27)

Level	TCD (mean ± SD)	SCD (mean ± SD)	CSA (mean ± SD)	VBD (mean ± SD)	PTR (mean ± SD)
C2	22.796 ± 1.496	16.570 ± 1.39	70.551 ± 4.300	15.555 ± 1.741	1.081 ± 0.170
C3	22.648 ± 1.295	13.725 ± 1.395	64.663 ± 3.200	15.200 ± 1.653	0.918 ± 0.167
C4	23.996 ± 1.257	13.455 ± 1.257	65.814 ± 2.561	15.522 ± 1.672	0.879 ± 0.145
C5	24.540 ± 2.924	13.759 ± 2.344	67.003 ± 4.607	14.855 ± 2.069	0.941 ± 0.189
C6	25.014 ± 1.806	13.244 ± 1.753	67.163 ± 4.865	15.533 ± 1.702	0.867 ± 0.177
C7	23.696 ± 1.952	13.600 ± 1.745	62.048 ± 5.071	15.548 ± 1.883	0.892 ± 0.190

Abbreviations: CSA, canal surface area; PTR, Pavlov-Torg ratio; SCD, sagittal canal diameter; SD, standard deviation; TCD, transverse canal diameter; VBD, vertebral body diameter.

Table 3 The mean \pm SD of the cervical spine in men ($N=73$)

Level	TCD (mean \pm SD)	SCD (mean \pm SD)	CSA (mean \pm SD)	VBD (mean \pm SD)	PTR (mean \pm SD)
C2	23.690 \pm 1.540	17.32 \pm 2.388	74.867 \pm 5.415	16.728 \pm 1.952	1.046 \pm 0.194
C3	23.265 \pm 1.453	13.72 \pm 1.562	67.375 \pm 4.717	16.528 \pm 1.851	0.842 \pm 0.157
C4	24.534 \pm 1.468	13.16 \pm 1.654	68.711 \pm 4.197	16.602 \pm 1.793	0.804 \pm 0.155
C5	25.135 \pm 2.112	13.83 \pm 2.063	70.775 \pm 4.384	16.678 \pm 2.236	0.843 \pm 0.176
C6	25.349 \pm 1.627	14.19 \pm 1.833	70.297 \pm 4.805	16.597 \pm 2.229	0.868 \pm 0.165
C7	24.163 \pm 2.175	14.87 \pm 2.452	67.460 \pm 6.213	16.493 \pm 1.987	0.913 \pm 0.191

Abbreviations: CSA, canal surface area; PTR, Pavlov-Torg ratio; SCD, sagittal canal diameter; SD, standard deviation; TCD, transverse canal diameter; VBD, vertebral body diameter.

Table 4 The mean \pm SD of the cervical spine in all subjects ($N=100$)

Level	TCD (mean \pm SD)	SCD (mean \pm SD)	CSA (mean \pm SD)	VBD (mean \pm SD)	PTR (mean \pm SD)
C2	23.478 \pm 1.573	17.080 \pm 2.196	73.760 \pm 5.483	16.423 \pm 1.976	1.056 \pm 0.190
C3	23.122 \pm 1.438	13.688 \pm 1.517	66.721 \pm 4.520	16.210 \pm 1.886	0.860 \pm 0.163
C4	24.398 \pm 1.420	13.195 \pm 1.569	67.974 \pm 4.046	16.340 \pm 1.823	0.822 \pm 0.156
C5	24.957 \pm 2.372	13.798 \pm 2.372	69.772 \pm 4.757	16.221 \pm 2.339	0.870 \pm 0.186
C6	25.056 \pm 1.653	13.931 \pm 1.860	69.452 \pm 4.969	16.340 \pm 2.156	0.869 \pm 0.170
C7	24.014 \pm 2.119	14.527 \pm 2.341	66.043 \pm 6.394	16.255 \pm 2.011	0.909 \pm 0.192

Abbreviations: CSA, canal surface area; PTR, Pavlov-Torg ratio; SCD, sagittal canal diameter; SD, standard deviation; TCD, transverse canal diameter; VBD, vertebral body diameter.

was collected including their age, height, weight, indication for scan, and neurological signs experienced by the patient (\rightarrow **Table 4**). Multinomial regression was applied to check for a correlation between the neurological signs experienced by the patient and the Pavlov-Torg which was calculated from C2 to C7. "NONE" was used as a reference category and neck pain, numbness, and weakness were used as variables. No significance was found between the signs and the level of the vertebrae except at C7 vertebrae with "weakness" where the p -value was found to be < 0.04 . The significance value at each vertebral level and odds ratio are mentioned in \rightarrow **Tables 1** and **3**.

Discussion

PTR is a method that can be used for CT-based morphometric analysis to determine cervical canal stenosis. Though the ratio can give inconclusive results in people with larger (e.g., athletes) and smaller (e.g., women) vertebral bodies, it has great predictability and can be used as a screening tool for degenerative diseases of the spine.¹¹ It is calculated by dividing the mid-vertebral sagittal diameter of the cervical canal by the sagittal diameter of the vertebral body with a ratio < 0.8 or < 0.7 exhibiting severe canal stenosis with neurological injury.⁷⁻⁹ According to several studies conducted, the ratio has proven to be a useful tool in detecting stenosis associated with neurological injuries.^{4,12-15}

Transverse Canal Diameter

In this study, the mean TCD was 24.35 ± 0.81 in men and 23.77 ± 0.94 in women, indicating gender-specific variations. This data aligns with the findings from a related investigation by Toki et al which centered on the morphometric analysis of the subaxial cervical spine with myelopathy and included a comparative analysis with the normal population.¹⁶

Sagittal Canal Diameter

A significant difference was noted in SCD between levels C2 and C3 (17.080 ± 2.196 and 13.688 ± 1.517) in both genders, respectively. Furthermore, SCD exhibited the narrowest diameters at level C4, confirming observations made in various CT-based studies.^{1,2,12,17} Additionally, an MRI-based investigation conducted by Morishita et al to find the correlation between cervical spinal canal diameter and pathological changes, revealed a mean SCD of 13.73 ± 1.37 mm which correlates with our findings.¹³

Canal Surface Area

The average cross-sectional CSA in this study was determined to be 68.05 ± 3.31 , with the smallest CSA observed at C3 in men and C7 in women. Significantly notable variations between men and women, particularly at C7, were identified with a p -value of less than 0.04. However, in a separate study comparing individuals with an injured spinal canal to a control group, no significant

Table 5 Multinomial logistic regression of the variable (neurological signs) with PTR at the individual level from C2 to C7

Neurological sign	PTR2		PTR3		PTR4		PTR5		PTR6		PTR7	
	p-Value	OR (95% CI)	p-Value	OR (95% CI)	p-Value	OR (95% CI)	p-Value	OR (95% CI)	p-Value	OR (95% CI)	p-Value	OR (95% CI)
Neck pain	0.98	0.0	0.99	7.2	0.99	7.8	0.99	0.0	0.99	0.0	0.99	7.56
Numbness	0.70	0.05	187	5.9	0.170	0.9	0.05	2.73	0.33	2.82	0.92	0.39
Weakness	0.74	13	0.90	0.29	0.11	1.28	0.20	91	0.11	2.99	0.04^a	1.61
All	0.92	1.62	0.98	0.89	0.08	4.61	0.74	3.04	0.27	0.006	0.51	11

Abbreviations: CI, confidence interval; OR, odds ratio; PTR, Pavlov-Torg ratio.

^aSignificance was found at PTR at C7 in association with weakness with p-value < 0.04.

differences were observed. This implies that there may be no correlation between CSA and spinal canal injuries.¹⁴

Vertebral Body Diameter

The mean VBD observed in the male participants was 16.61 ± 0.11 , while in the female population it was noted as 15.31 ± 0.27 . The statistical analysis revealed a significance level of 0.0, indicating a notable difference between the two groups. Importantly, these findings align with existing research by Toki et al.¹⁶

Pavlov-Torg Ratio

No statistically significant associations were identified at various PTR levels with age, correlating with the study conducted by Moon et al on comparative analysis of age in patients with minor trauma devoid of neurological symptoms.¹⁵ Although anatomical investigations on human cadavers by Lee et al indicated larger measurements in males, our study revealed only marginal significance in CSA and VBD.² For individuals with a PTR less than < 0.8, our findings showed no gender differences or their indication for the scan. Only at the level of C7, the neurological sign *weakness* was associated with PTR < 0.8 (p-value 0.04).

In the study by Evangelopoulos et al, cervical spine measurements were conducted up to C6. However, based on the findings presented in this article, we propose extending CT-based morphometric analysis to include measurements up to C7. This suggestion is informed by the observed significance related to weakness and the PTR at the level of C7.

PTR is a comparatively better tool for predicting cervical canal stability; however, it is associated with disadvantages due to its poor predictability value due to its dependence on VBD. The outcome of CT scans in providing measurements of bony structures is better than MRI in which measurements may show some variations owing to soft tissue structures.¹³ The anatomy of the cervical spine differs according to the geographical locations, hence a morphometric study must be done according to the geography to understand the prevalence of cervical stenosis and other development disorders.¹⁸

Geographical Variations in Spinal Canal Morphometry in India

While there are several CT- and MRI-based studies done in the world with different ethnic and geographical variations in the cervical spine, there is, however, a lack of such studies done in different geographical locations in India.^{2,4,12-16,18,19}

In an MRI-based study done by Kar et al from C3 to C7 on sub-Himalayan and north Bengal populations, the average SCD in males was 11.99 ± 1.34 mm and that in females was 12.15 ± 1.24 mm (mean = 12.07 ± 0.11) which was smaller than our 13.82 ± 0.47 . The VBD was 14.60 ± 1.38 mm in males and 13.04 ± 1.13 mm in females which were also smaller than ours.²⁰

In another CT-based morphometric analysis by Kumar et al from C2 to C7 in the Central Indian population, the average SCD was 13.11 ± 0.59 , smaller than ours

Table 6 Comparison with other radiographic studies done in specific geographical regions in India

Author	Radiograph used	Cervical level measured	Geographical area of India	SCD (mean ± SD)	Pavlov–Torg ratio
Kar et al ²⁰	MRI	C3 to C7	Sub-Himalayan and North Bengal	12.07 ± 0.11	0.86 ± 0.07
Kumar et al ¹	CT	C2 to C7	Central	13.11 ± 0.59	0.86 ± 0.05
Singh et al ²¹	X-ray	C2–C6	Northern	G1-17.04 ± 1.56 G2-17.17 ± 1.82 G3-17.18 ± 1.67	G1-0.96 ± 0.13 G2-0.98 ± 0.14 G3-0.97 ± 0.13
Pawar et al ²²	X-ray	C1 to C7	Southwest	12.9	Not available
Our study	CT	C2 to C7	Western	14.36 ± 1.39	0.89 ± 0.08

Abbreviations: CT, computed tomography; MRI, magnetic resonance imaging; SCD, sagittal canal diameter; SD, standard deviation.

14.36 ± 1.39. The same variations were noticed with TCD. However, the average CSA was much smaller in our study in comparison (68.93 ± 2.76 mm² vs. 136.07 ± 9.14 mm²).¹

In other such studies, conducted in northern, southwestern, and western regions, dissimilarities were found in the SCD and PTR, respectively, citing our need for more such CT-based geographical studies^{21,22} (► **Table 6**).

Limitations

In this study, the first limitation was the need to maintain homogeneity in sample collection. There were significant differences observed between men and women in the study.

The second was that the research was confined to a certain geographical area. To get a broader idea of the accurate morphometric analysis, future studies need to aim for increased sample sizes, broader geographical coverage, and randomization in participant selection.

Conclusion

In conclusion, this study provides insights into the morphometric characteristics of the cervical spine in the western Indian population. The uniformity observed in certain measurements correlates with other studies done by authors from Asia. There were significant findings in CSA and VBD that contributed to our understanding of cervical anatomy. The association between weakness and PTR at the C7 level also highlights the clinical implications and the need for such studies to be conducted till the C7 vertebrae. These CT-based studies can prove to be useful in understanding the region-specific reference values, as a screening method for other spinal pathologies, preoperative and postoperative surgical evaluation, and understanding congenital anomalies. Further research and exploration of these findings may enhance diagnostic and treatment approaches for cervical spine conditions.

Conflict of Interest

None declared.

References

- Kumar A, Sahu S, Sethi S, et al. Computerized tomography-based morphometric analysis of cervical spinal canal in Central Indian population. *J Neurosci Rural Pract* 2020;11(02):274–277
- Lee MJ, Cassinelli EH, Riew KD. Prevalence of cervical spine stenosis. Anatomic study in cadavers. *J Bone Joint Surg Am* 2007;89(02):376–380
- Fakhoury J, Dowling TJ. Cervical degenerative disc disease.
- Zhang L, Chen HB, Wang Y, Zhang LY, Liu JC, Wang ZG. Cervical spinal canal narrowing and cervical neurological injuries. *Chin J Traumatol* 2012;15(01):36–41
- Hinck VC, Sachdev NS. Developmental stenosis of the cervical spinal canal. *Brain* 1966;89(01):27–36
- Payne EE, Spillane JD. The cervical spine; an anatomicopathological study of 70 specimens (using a special technique) with particular reference to the problem of cervical spondylosis. *Brain* 1957;80(04):571–596
- Pavlov H, Torg JS, Robie B, Jahre C. Cervical spinal stenosis: determination with vertebral body ratio method. *Radiology* 1987;164(03):771–775
- Torg JS, Pavlov H, Genuario SE, et al. Neurapraxia of the cervical spinal cord with transient quadriplegia. *J Bone Joint Surg Am* 1986;68(09):1354–1370
- Torg JS. Pavlov's ratio: determining cervical spinal stenosis on routine lateral roentgenograms. *Contemp Orthop* 1989;18:153–160
- Chang PY, Chang HK, Wu JC, et al. Is cervical disc arthroplasty good for congenital cervical stenosis? *J Neurosurg Spine* 2017;26(05):577–585
- Herzog RJ, Wiens JJ, Dillingham MF, Sontag MJ. Normal cervical spine morphometry and cervical spinal stenosis in asymptomatic professional football players. Plain film radiography, multiplanar computed tomography, and magnetic resonance imaging. *Spine* 1991;16(6, Suppl):S178–S186
- Song KJ, Choi BW, Kim SJ, Kim GH, Kim YS, Song JH. The relationship between spinal stenosis and neurological outcome in traumatic cervical spine injury: an analysis using Pavlov's ratio, spinal cord area, and spinal canal area. *Clin Orthop Surg* 2009;1(01):11–18
- Morishita Y, Naito M, Hymanson H, Miyazaki M, Wu G, Wang JC. The relationship between the cervical spinal canal diameter and the pathological changes in the cervical spine. *Eur Spine J* 2009;18(06):877–883
- Matsuura P, Waters RL, Adkins RH, Rothman S, Gurbani N, Sie I. Comparison of computerized tomography parameters of the cervical spine in normal control subjects and spinal cord-injured patients. *J Bone Joint Surg Am* 1989;71(02):183–188
- Moon MS, Choi WR, Lim HG, Lee SY, Wi SM. Pavlov's ratio of the cervical spine in a Korean population: a comparative

- study by age in patients with minor trauma without neurologic symptoms. *Clin Orthop Surg* 2021;13(01):71–75
- 16 Toki S, Higashino K, Manabe H, et al. Morphometric analysis of subaxial cervical spine with myelopathy: a comparison with the normal population. *Spine Surg Relat Res* 2020;5(01):34–40
 - 17 Chaurasiya AK, Dawar A, Gour R, Vaidya K. Morphological study of cervical spinal body and vertebral body anatomy: CT scan based. *Int Surg J* 2021;8(05):1540–1544
 - 18 Chazono M, Tanaka T, Kumagai Y, Sai T, Marumo K. Ethnic differences in pedicle and bony spinal canal dimensions calculated from computed tomography of the cervical spine: a review of the English-language literature. *Eur Spine J* 2012;21(08):1451–1458
 - 19 Evangelopoulos D, Kontovazenitis P, Kouris S, et al. Computerized tomographic morphometric analysis of the cervical spine. *Open Orthop J* 2012;6:250–254
 - 20 Kar M, Bhaumik D, Ishore K, Saha PK. MRI study on spinal canal morphometry: an Indian study. *J Clin Diagn Res* 2017;11(05):AC08–AC11
 - 21 Singh S, Kumar D, Kumar S. Risk factors in cervical spondylosis. *J Clin Orthop Trauma* 2014;5(04):221–226
 - 22 Pawar KA, Mishra AS, Bandagi G, Srivastava SK. Roentgenographic and computerized tomography based morphometric analysis of cervical spinal canal diameters to establish normative measurements in an Indian population. *J Clin Orthop Trauma* 2017;8(02):185–190