



Middle meningeal artery embolization contraindication when it originates from the ophthalmic artery

Contraindicação de embolização da artéria meníngea média quando ela se origina da artéria oftálmica

Lívio Pereira de Macêdo^{1,2,3} Mayle Gomes Ferreira de Araújo¹ Pedro Lucas Negromonte Guerra⁴
Marcos Alcino Soares Siqueira Marques Júnior^{1,2} José Laércio Júnior Silva^{1,2,3}

¹ Hospital da Restauração, Departamento de Neurocirurgia, Recife PE, Brazil.

² Hospital da Restauração, Departamento de Neurorradiologia Intervencionista, Recife PE, Brazil.

³ ANGIORAD, Departamento de Radiologia Neurointervencionista, Recife PE, Brazil.

⁴ Universidade Federal de Pernambuco, Recife PE, Brazil.

Address for correspondence Lívio Pereira de Macêdo (e-mail: livio21@gmail.com).

Arq. Neuro-Psiquiatr. 2024;82(4):s00441786023.

It aims to highlight the importance of anatomical variations of the (MMA) middle meningeal artery's origin in practice for neurointerventionalist. Before proceeding with embolization of the MMA in some pathologies, a critical analysis of the anatomy of these vessels should be done. When MMA originates from the ophthalmic artery, it is a formal contraindication to proceed with the embolization.^{1,2} Otherwise, major complications is embolization of the central retinal artery results in blindness.³

A patient with recurrent chronic subdural hematoma and thrombocytopenia was referred to embolization of the MMA. Angiogram shows MMA originates in the OA, and the procedure was inadvisable (→ **Figures 1 and 2**).

Authors' Contributions

LPM: conceptualization, supervision, validation, visualization, writing – original draft, writing – review & editing; MGFA: data curation, writing – original draft; PLNG:

writing – original draft, writing – review & editing; MASMJ: conceptualization, writing – original draft, writing – review & editing; JLJS: conceptualization, supervision, writing – review & editing.

Conflict of Interest

There is no conflict of interest to declare.

References

- 1 Bonasia S, Smajda S, Ciccio G, Robert T. Middle Meningeal Artery: Anatomy and Variations. *AJNR Am J Neuroradiol* 2020;41(10):1777–1785. Doi: 10.3174/ajnr.A6739
- 2 Liu Q, Rhoton AL Jr. Middle meningeal origin of the ophthalmic artery. *Neurosurgery* 2001;49(02):401–406, discussion 406–407. Doi: 10.1097/00006123-200108000-00025
- 3 Fantoni M, Eliezer M, Serrano F, et al. High frequency of ophthalmic origin of the middle meningeal artery in chronic subdural hematoma. *Neuroradiology* 2020;62(05):639–644. Doi: 10.1007/s00234-020-02363-6

received
January 27, 2024
received in its final form
February 16, 2024
accepted
February 22, 2024

DOI <https://doi.org/10.1055/s-0044-1786023>.
ISSN 0004-282X

Editor-in-Chief: Hélio A. G. Teive
Associate Editor: Carolina de Medeiros Rimkus.

© 2024. The Author(s).

This is an open access article published by Thieme under the terms of the Creative Commons Attribution 4.0 International License, permitting copying and reproduction so long as the original work is given appropriate credit (<https://creativecommons.org/licenses/by/4.0/>).

Thieme Revinter Publicações Ltda., Rua do Matoso 170, Rio de Janeiro, RJ, CEP 20270-135, Brazil

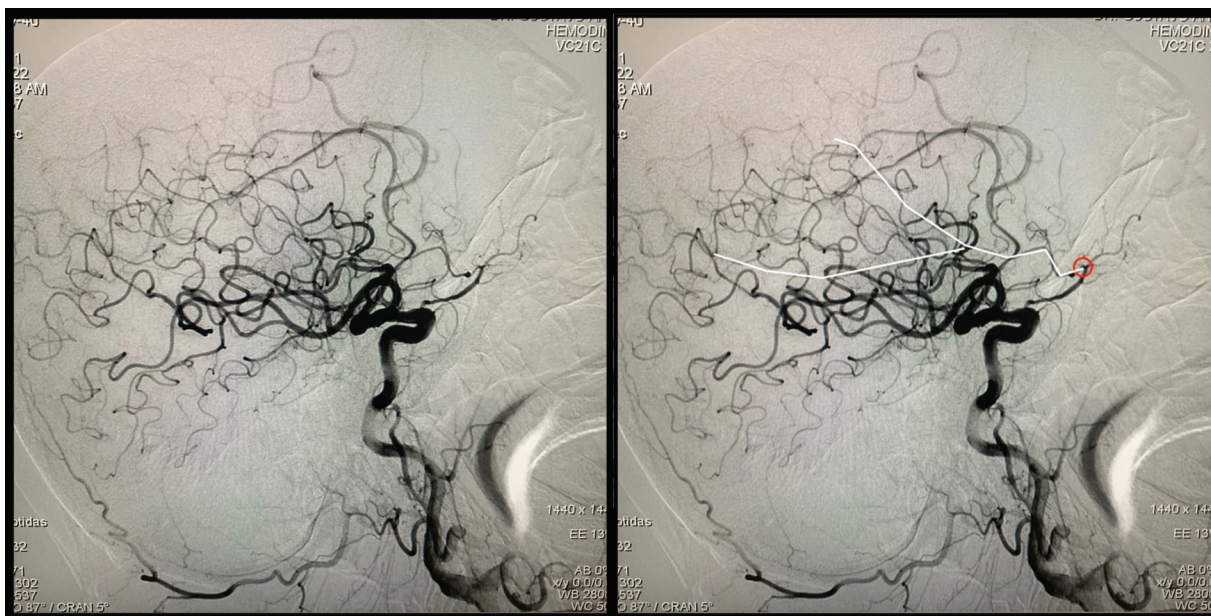


Figure 1 Lateral view of a cerebral angiogram showing a right subdural hematoma and the right middle meningeal artery originates from the ophthalmic artery.

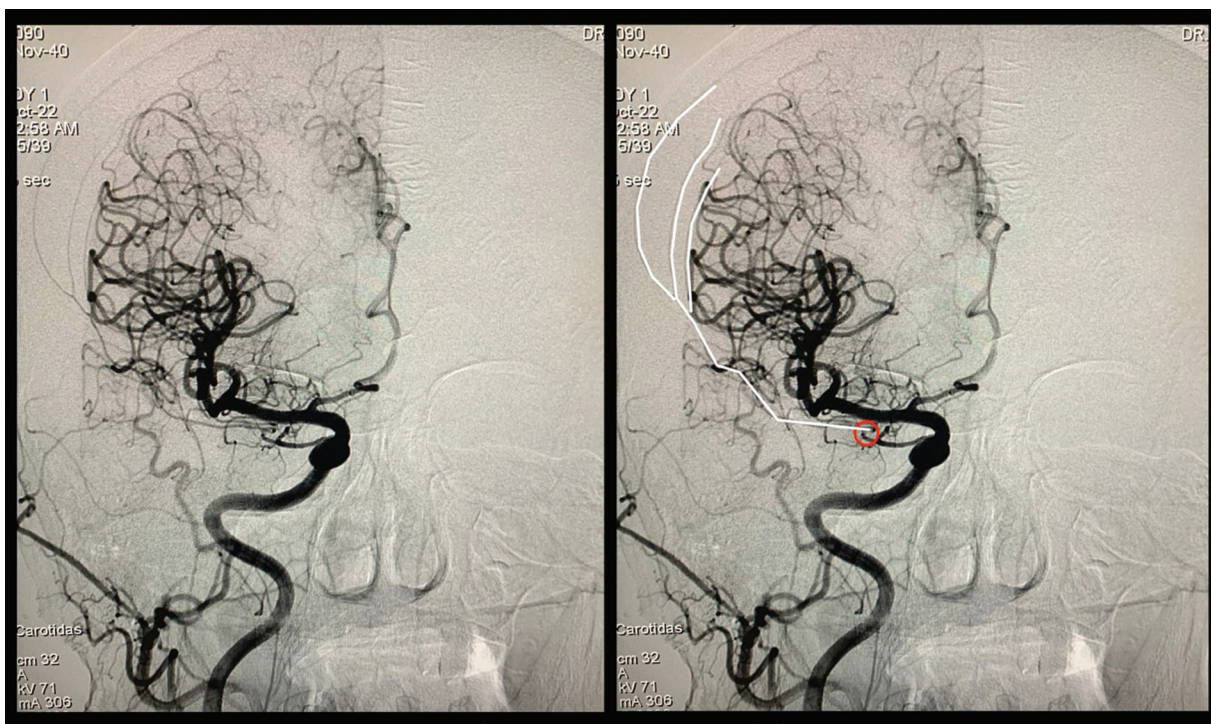


Figure 2 Anteroposterior view of a cerebral angiogram showing a right subdural hematoma and the right middle meningeal artery originates from the ophthalmic artery.