




Unilateral Vision Loss after Posterior Fixation for Traumatic Atlantoaxial Dislocation: A Case Report with Literature Review

Guramritpal Singh¹ Ved Prakash Maurya¹  Kamlesh Singh Bhaisor¹ Arun Kumar Srivastava¹
Sanjay Behari² Raj Kumar¹

¹ Department of Neurosurgery, Sanjay Gandhi Postgraduate Institute of Medical Sciences, Lucknow, Uttar Pradesh, India

² Department of Neurosurgery, Sree Chitra Tirunal Institute for Medical Sciences and Technology, Trivandrum, Kerala, India

Address for correspondence Ved Prakash Maurya, MCh, Department of Neurosurgery, Sanjay Gandhi Postgraduate Institute of Medical Sciences, Lucknow 226014, Uttar Pradesh, India (e-mail: vpmsurgery@gmail.com).

Indian J Neurotrauma

Abstract

Postoperative vision loss following spine surgery is a rare and devastating complication with variable incidence. Various risk factors have been identified in the literature. A 16-year-old male presented with neck pain, spastic quadriparesis, and tingling paraesthesia in the left upper limb for the past 3 years. Radiological workup was suggestive of atlantoaxial dislocation with occipitalization of the posterior arch of the atlas (C1). The patient was prone to a horseshoe headrest and underwent occipito-C2-C3 fixation by removing the posterior rim of foramen magnum. Postoperatively, the patient complained of loss of vision in the right eye. Ophthalmology evaluation revealed a loss of perception of light in the right eye due to central retinal artery occlusion. An injectable steroid was started, but there was no improvement in vision in the involved eye. Proper head positioning and avoidance of intraoperative hypotension are modifiable factors to avoid such devastating complications.

Keywords

- ▶ prone position
- ▶ ischemia
- ▶ vision loss
- ▶ atlantoaxial dislocation

Introduction

Vision loss after spine surgery is a rare but devastating complication, with incidence for spinal and cardiac surgery as high as 0.2 and 4.5%.¹ Ischemic optic neuropathy, central retinal artery thrombosis, and cortical blindness are the three recognized causes of blindness.^{2,3} Multiple risk factors have been identified in the literature.²⁻⁵ We report a rare case of unilateral vision loss following surgery for craniovertebral junction anomaly in the prone position.

Case History

A 16-year-old boy presented with chief complaints of neck pain, progressive spastic quadriparesis, and tingling

paraesthesia in the left upper limb for the past 3 years. Vision and extraocular movements were regular. Tone was modified ashworth scale (MAS) grade 2 and power was 4/5 in all four limbs. Deep tendon reflexes were exaggerated. Abdominal reflex was absent in all quadrants. Plantars were bilateral extensors. Sensory system was normal. Radiological investigations were suggestive of atlantoaxial dislocation with occipitalization of atlas (▶ **Fig. 1**). The patient underwent occipito-C2-C3 fixation with foramen magnum decompression in a prone position with the head resting on a horseshoe headrest (▶ **Fig. 2**). Surgery lasted 6 hours. Postoperatively, the patient had improvement in power and tingling paraesthesia. On postoperative day 1, the patient complained of loss of vision from the right eye with orbital swelling. Patient was given injectable methylprednisolone

DOI <https://doi.org/10.1055/s-0044-1782610>.
ISSN 0973-0508.

© 2024. The Author(s).

This is an open access article published by Thieme under the terms of the Creative Commons Attribution License, permitting unrestricted use, distribution, and reproduction so long as the original work is properly cited. (<https://creativecommons.org/licenses/by/4.0/>)
Thieme Medical and Scientific Publishers Pvt. Ltd., A-12, 2nd Floor, Sector 2, Noida-201301 UP, India

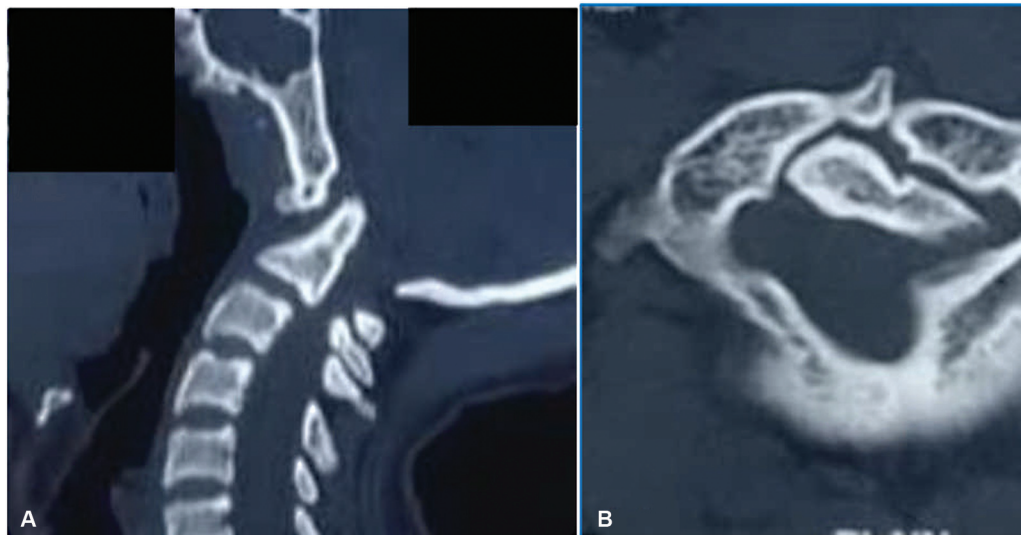


Fig. 1 Preoperative computed tomography scan of craniocervical junction with upper cervical spine, (A) sagittal and (B) axial section, showing atlantoaxial dislocation with rotation of the occipitoatlantal joint having a bifid anterior and posterior arch of atlas (C1).

(30 mg/kg) followed by continuous infusion (5.4 mg/kg/h) for the next 23 hours. Ophthalmology evaluation revealed a loss of perception of light in the right eye. Fundus examination showed a cherry red spot with macular ischemia with

arteriole attenuation, which was suggestive of central retinal artery occlusion. Orbital swelling subsided over the next 1 to 2 days. Extraocular movements were regular. However, there was no improvement in vision in the right eye.

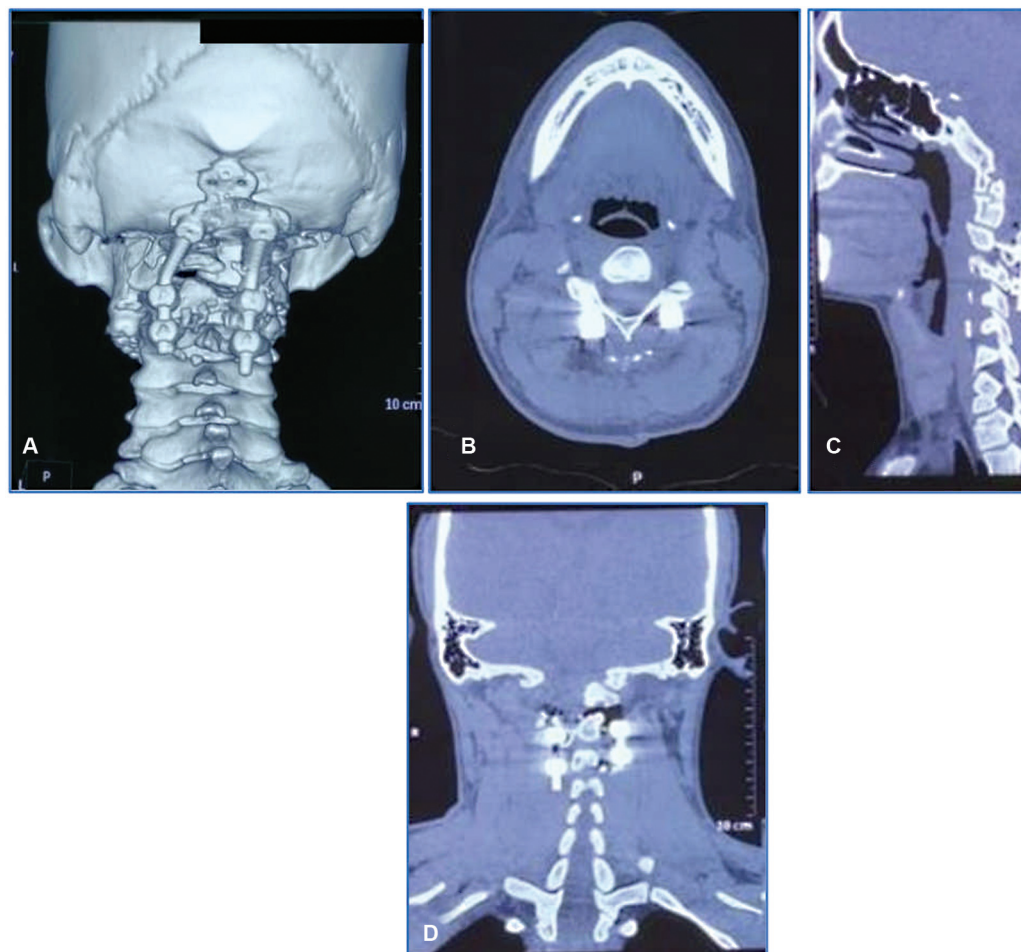


Fig. 2 Postoperative images of computed tomography scan of craniocervical junction demonstrating (A) three-dimensional reconstruction: (B) axial, (C) sagittal, and (D) coronal section showing occipito-C2-C3 fixation with reduction in the atlantoaxial dislocation.

Table 1 The published cases with possible reasons of visual impairment following surgery in prone position

Sl. no.	Study	Number of patients	Possible diagnosis of vision loss	Preoperative risk factors	Intraoperative and postoperative risk factors
1.	Stevens et al ¹ 1997	3,450	Posterior optic nerve ischemia, occipital lobe infarcts, central retinal vein thrombosis	Paroxysmal atrial fibrillation, hypertension	Air embolism, deep venous thrombosis
2.	Myers et al ² 1997	37	Ischemic optic neuropathy, retinal artery occlusion, cerebral ischemia	Hypertension, diabetes mellitus, smoking, vascular disorders leading to increased viscosity	Hypotension, anemia
3.	Kamming and Clarke ³ 2005	1	Ischemic optic neuropathy	Medullary carcinoma of thyroid	Pressure over the eyeball due to headrest, hypotension, anemia
4.	Warner ⁴ 2006	–	Ischemic optic neuropathy, central retinal artery occlusion	Hypertension, diabetes mellitus, smoking, polycythemia, renal failure, narrow-angle glaucoma and atherosclerosis	Hypotension, anemia
5.	Hunt et al ⁵ 2004	20	–	–	Prone position leads to increase in intraocular pressure
6.	Abraham et al ⁶ 2003	1	Ischemic optic neuropathy	–	Malposition horseshoe headrest, prone position
7.	Ozcan et al ⁷ 2004	10	–	–	Ten degrees of reverse Trendelenburg position also helped decrease the pressure to normal in the prone position
8.	Hoski et al ⁸ 1993	1	Central retinal artery occlusion	–	Prone position
9.	Merle et al ⁹ 1994	1	Central retinal artery occlusion	–	Prone position
10.	Hayreh ¹⁰ 1974	25	Anterior ischemic optic neuropathy	–	–

Discussion

Multiple case reports in the literature have reported ischemic optic neuropathy after spinal surgery in the prone position (► **Table 1**). Multiple causative factors include:

- (a) Preoperative—Hypertension, diabetes mellitus, smoking, polycythemia, renal failure, narrow-angle glaucoma, and atherosclerosis.
- (b) Intraoperative—Hypotension and anemia.⁶
- (c) Postoperative factor—Raised intraocular pressure.

The reasons of 'raised intra ocular pressure' include:

1. Due to increased pressure over globe: Inappropriate pressure from padding while lying on the horseshoe headrest leads to extrinsic pressure over the eyeball, causing raised intraocular pressure.
2. Raised central venous pressure: Decreased venous return due to low position of the head, obstruction to venous

outflow if head is turned to one side, pressure over the abdomen along with absence of valves result in central venous pressure changes causing associated changes in ocular venous pressure.

3. Prone position: Intraocular pressure increases in prone position.⁵ Ten degrees of reverse Trendelenburg position also helped decrease the pressure to normal in prone position.⁷
4. Intraoperative change in the patient's position: Operating team, including an anesthetist, preoperatively confirmed the position of the head and eye. Change in this position during surgery could have led to external pressure over the eyeball.

The blindness mechanism is retinal ischemia due to increased intraocular pressure caused by venous congestion or arterial occlusion. Venous collapse leads to decreased blood flow when venous pressure is exceeded by intraocular pressure.⁸ Dual arterial supply is present in

retina—inner layer supplied by central retinal artery. Retina's outer layer gets its supply due to diffusion from the choroidal plexus. Hence, in the event of any obstruction to central retina, blindness may result. Arterial or venous occlusion changes the blood circulation in retina and produces hypoxia in the affected area. In case of arterial occlusion, severe hypoxia rapidly (in less than 45 minutes) produces irreversible cell damage in inner layers of the retina.⁹ Time duration that the human retina can resist is not precise. Retina of rhesus monkeys can remain unaffected by ischemia for 95 minutes. Anaerobic glycolysis starts in vitreous humor after 20 minutes of ischemia. The glucose stored in vitreous humor is the only source of nutrition to the retina between 40 and 70 minutes of ischemia. This reserve is the sole determining factor of the time duration of retinal ischemia, which can be safely tolerated.¹⁰

We believe that the head position of our patient might have changed during surgery, leading to the patient's face being trapped inside the horseshoe headrest, resulting in extrinsic compression over the right eyeball, which developed orbital swelling and blindness.

Conclusion

Postoperative vision loss after spinal surgery in prone positioning is a rare and irreversible complication. Proper positioning of the head should be done so that ocular compression does not happen. Any change in the patient's position intraoperatively and intraoperative hypotension resulting from excessive blood loss should be avoided.

Authors' Contributions

V.P.M. conceptualized and designed the study. R.K. and S.B. provided administrative support. K.S.B. helped in provision of study materials or patients. G.S. contributed to collection and assembly of data. V.P.M.

and A.K.S. helped in data analysis and interpretation. All the authors helped in manuscript writing and provided final approval for the manuscript.

Funding

None.

Conflict of Interest

None declared.

References

- 1 Stevens WR, Glazer PA, Kelley SD, Lietman TM, Bradford DS. Ophthalmic complications after spinal surgery. *Spine* 1997;22(12):1319–1324
- 2 Myers MA, Hamilton SR, Bogosian AJ, Smith CH, Wagner TA. Visual loss as a complication of spine surgery. A review of 37 cases. *Spine* 1997;22(12):1325–1329
- 3 Kamming D, Clarke S. Postoperative visual loss following prone spinal surgery. *Br J Anaesth* 2005;95(02):257–260
- 4 Warner MA. Postoperative visual loss: experts, data, and practice. *Anesthesiology* 2006;105(04):641–642
- 5 Hunt K, Bajekal R, Calder I, Meacher R, Eliahoo J, Acheson JF. Changes in intraocular pressure in anesthetized prone patients. *J Neurosurg Anesthesiol* 2004;16(04):287–290
- 6 Abraham M, Sakhuja N, Sinha S, Rastogi S. Unilateral visual loss after cervical spine surgery. *J Neurosurg Anesthesiol* 2003;15(04):319–322
- 7 Ozcan MS, Praetel C, Bhatti MT, Gravenstein N, Mahla ME, Seubert CN. The effect of body inclination during prone positioning on intraocular pressure in awake volunteers: a comparison of two operating tables. *Anesth Analg* 2004;99(04):1152–1158
- 8 Hoski JJ, Eismont FJ, Green BA. Blindness as a complication of intraoperative positioning. A case report. *J Bone Joint Surg Am* 1993;75(08):1231–1232
- 9 Merle H, Delattre O, Trode M, Catonne Y. [Central retinal artery occlusion in surgery of the cervical vertebrae]. *J Fr Ophtalmol* 1994;17(10):603–607
- 10 Hayreh SS. Anterior ischaemic optic neuropathy. III. Treatment, prophylaxis, and differential diagnosis. *Br J Ophthalmol* 1974;58(12):981–989