



Upfront Low-Dose Cytarabine with Prednisolone for Langerhans Cell Histiocytosis with Liver Dysfunction: A Ray of Hope

Niranjan Gurunath Hegde¹ Meena S. Sivasankaran¹ Vimal Kumar G.² Deenadayalan Munirathnam²

¹Department of Pediatric Hemato-Oncology and BMT, Kanchi Kamakoti CHILDS Trust Hospital, Chennai, Tamil Nadu, India

²Department of Pediatric Hemato-Oncology, Immunology and Stem cell transplantation, Dr Rela Institute and Medical Centre, Chennai, Tamil Nadu, India

Address for correspondence Niranjan Gurunath Hegde, FIAP (PHO), DNB (Pediatrics), Department of Pediatric Hematology Oncology and BMT, Kanchi Kamakoti CHILDS Trust Hospital, Chennai, Tamil Nadu, India (e-mail: gh.niranjana@gmail.com).

Ind J Med Paediatr Oncol

Abstract

The management of Langerhans cell histiocytosis (LCH) with accompanying liver dysfunction poses significant challenges, and this prompted the development of a modified low-dose cytarabine and prednisolone regimen. In this prospective observational study on children with LCH and liver dysfunction, four patients underwent induction and maintenance chemotherapy. The induction phase included 5 days of 100 mg/m² cytarabine and 4 weeks of 40 mg/m² daily prednisolone, with subsequent tapering. Maintenance included a regimen of 5 days of 100 mg/m² cytarabine, along with oral prednisolone, repeated every 3 weeks. Complete disease resolution occurred after varying chemotherapy cycles. Three patients had liver transplants, and the chemotherapy resumed for 52 weeks after the transplant. In one child, chemotherapy was continued after reaching remission. In conclusion, a modified, less toxic low-dose cytarabine-based chemotherapy effectively managed LCH with liver dysfunction, with liver transplantation as a postremission treatment option.

Keywords

- ▶ decompensated liver
- ▶ PET-CT
- ▶ sclerosing cholangitis
- ▶ liver transplantation

Introduction

Langerhans cell histiocytosis (LCH) is characterized by aggressive proliferation of histiocytes causing tissue destruction at the involved sites. The liver is affected in 20 to 60% of patients with LCH and is more common when there is multiorgan involvement.¹ A prototype hepatic LCH is secondary sclerosing cholangitis (SSC), which is caused by progressive destruction of the biliary tree by malignant histiocytes.¹ It is one of the “risk organs,” apart from the spleen and bone marrow, as this can adversely affect long-term survival. Liver involvement is divided into two stages: the infiltrative phase (early) and the sclerosis phase (late). In the early infiltrative phase, inflammatory mediators/cells infiltrate the periportal area in response to malignant

histiocytes. Nodular lesions were observed during this phase. In the late sclerosing phase, the liver develops scarring and cirrhosis, leading to portal hypertension.^{2,3}

Chemotherapy remains the mainstay of treatment.⁴ Vinblastine plus prednisone has been the standard of care for children with multisystem disease. Although overall survival has steadily improved, outcomes for patients with LCH with liver dysfunction remain suboptimal.⁵ It is advisable to refrain from administering vinblastine in the presence of liver dysfunction to mitigate the risk of toxicity.^{6,7} Therefore, there is a pressing need for an alternative treatment regimen. Limited research exists on the use of cytarabine as an initial therapy and as an alternative regimen in children with liver dysfunction. In the present study, we evaluated the

DOI <https://doi.org/10.1055/s-0044-1782234>.
ISSN 0971-5851.

© 2024. The Author(s).

This is an open access article published by Thieme under the terms of the Creative Commons Attribution License, permitting unrestricted use, distribution, and reproduction so long as the original work is properly cited. (<https://creativecommons.org/licenses/by/4.0/>)

Thieme Medical and Scientific Publishers Pvt. Ltd., A-12, 2nd Floor, Sector 2, Noida-201301 UP, India

effectiveness of a low-dose cytarabine/prednisolone-based therapy in terms of treatment response and associated toxicity.

Definitions

Liver involvement in LCH was defined as per the European Consortium for Histiocytosis as palpable liver 3 cm below the costal margin along the mid-clavicular line, and liver dysfunction defined by hyperbilirubinemia (at least three times the upper limit of normal), hypoalbuminemia (<3.0 g/dL), elevated alanine transaminase (ALT), and/or aspartate transaminase (AST; more than three times the upper limit of normal), elevated gamma glutamyl transpeptidase (GGT; more than twice the upper limit of normal), ascites, and/or intrahepatic nodular mass.⁸ Decompensated liver disease is defined as ascites, variceal bleed or Hepatic Encephalopathy (HE), and bilirubin >3 mg/dL, and/or acute on chronic liver failure (acute on chronic liver failure is bilirubin more than 5 mg/dL with international normalized ratio [INR] above 1.5 along with onset of ascites and/or HE within 4 weeks of onset of jaundice).^{4,9} Sclerosing cholangitis in LCH is defined as involvement of extrahepatic or intrahepatic biliary tree with strictures, dilatation, abnormal branching detected on imaging (computed tomography or magnetic resonance imaging), and/or on liver biopsy with or without elevated GGT.¹⁰ The treatment response is defined as per the LCH-IV study, namely, no active disease (NAD), active disease (AD) better, intermediate, and worse.¹¹

Materials and Methods

Chemotherapy Protocol

Children in our study received modified low-dose cytarabine-based chemotherapy.¹²⁻¹⁴ The induction regimen included cytarabine administered at a dosage of 100 mg/m² per day. The administration was carried out either through intravenous infusion over 1 hour or via subcutaneous delivery. The treatment spanned 5 consecutive days every 3 weeks. This was combined with daily prednisolone at a dose of 40 mg/m² for 4 weeks, followed by gradual tapering over the subsequent 2 weeks. Subsequently, the treatment response was assessed at 6 and 12 weeks. Induction chemotherapy was continued until complete remission or 12 weeks, whichever was earlier, as long as there was no progression of the disease. After induction, maintenance chemotherapy commenced. It involved three weekly doses of cytarabine at a dose of 100 mg/m² for 5 days, along with prednisolone at 40 mg/m²/d for 5 days. Likewise, the total duration of treatment spanned 52 weeks (► Fig. 1).

This was a prospective observational study conducted in a tertiary care hospital in Chennai. The study was conducted over 5 years (2018–2022). Children with biopsy-proven LCH and decompensated liver disease were included in this study. Children who had received chemotherapy prior to the study were excluded. We had four children in the cohort. Demographic data, growth parameters, and essential blood investigations (i.e., complete blood count and liver function test, and positron emission tomography and computed tomography [PET-CT] at diagnosis and subsequently during response

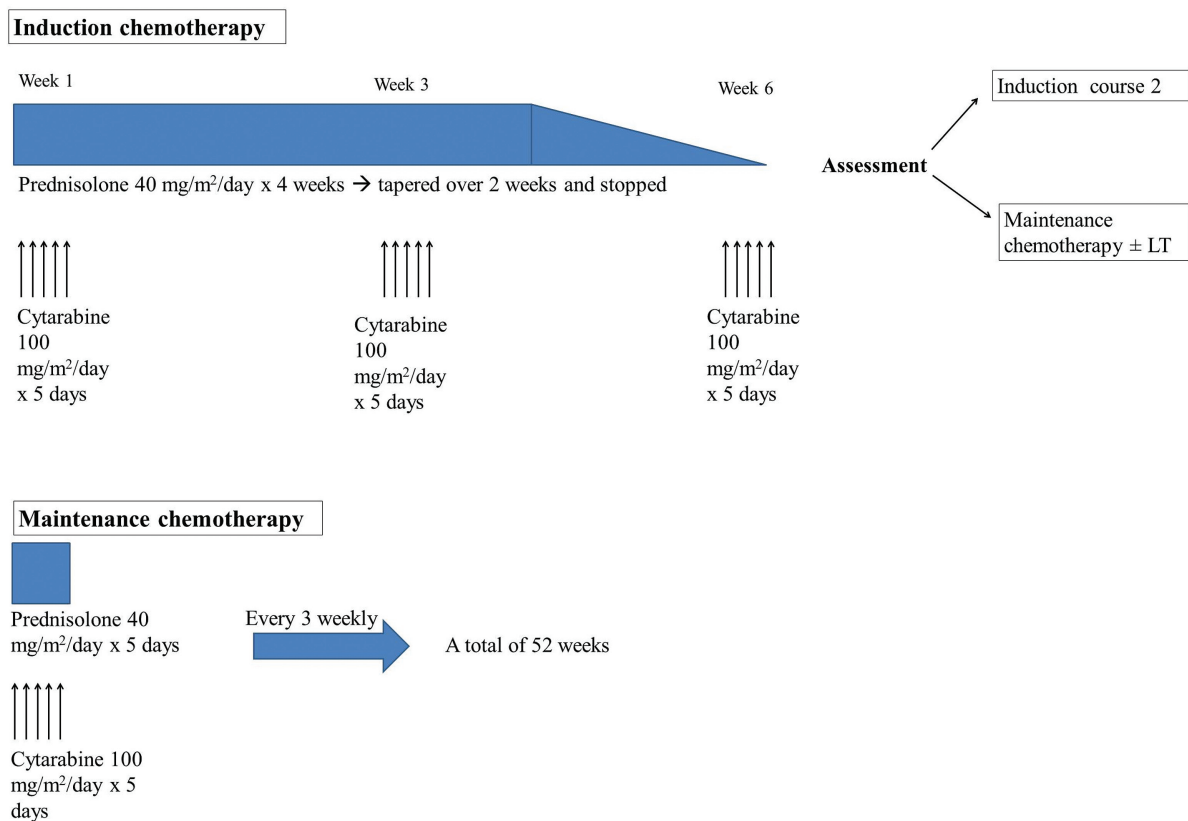


Fig. 1 Chemotherapy protocol: modified low-dose cytarabine-prednisolone-based chemotherapy.

assessment) were tabulated. Chemotherapy was administered as described above. If the disease showed complete remission at the end of 6 weeks, either the child was taken up for liver transplantation or continued on further maintenance chemotherapy to complete 52 weeks. If there was an intermediate or better response at the end of 6 weeks, chemotherapy was administered for 6 more weeks. Response was reassessed using PET-CT at the end of 12 weeks of chemotherapy. Children were continued on induction chemotherapy until complete remission or 12 weeks, whichever was earlier. If disease progression occurred at any point during induction, a salvage chemotherapy regimen was initiated.

Liver transplantation was performed in patients with acute decompensation or in children with compensated cirrhosis and sclerosing cholangitis with portal hypertension, intractable pruritus, and growth retardation.

Results

All four patients showed favorable response (NAD, AD better, or AD intermediate) to chemotherapy. Complete resolution (NAD) of the disease was attained at the end of two cycles in patients 1 and 4, whereas patients 2 and 3 attained complete resolution at the end of 13 and 5 cycles, respectively. Three patients with persistent liver dysfunction underwent liver

Table 1 Patient characteristics, evaluation, treatment received, and outcomes

	Patient 1	Patient 2	Patient 3	Patient 4
Gender	Female	Male	Male	Male
Age at symptom onset (mo)	36	6	20	8
Age at diagnosis (mo)	48	11	23	12
Hb (g/dL)	8.9	8.5	9.4	6
TLC (cells/mm ³)	18,220	15,240	19,800	23,900
Platelets (lakhs/mm ³)	5.2	4.1	6.21	11.47
PET-CT	Metabolically active liver, periportal and thoracic lymph nodes	Metabolically active middle ear cavity, mastoid air cells, bilateral level II, III, IV cervical lymph nodes, bilateral lungs, liver, spleen, and left femur	Metabolically active left temporal, petrous, orbit, sphenoid, liver, and bone marrow	Metabolically active liver, lungs, mediastinum, LNs, and bone marrow
Chemotherapeutic agents	Prednisolone, cytarabine	Prednisolone, cytarabine	Prednisolone, cytarabine	Prednisolone, cytarabine, trametinib
Post-chemo PET-CT (2 cycles/6 wk)	NAD	Intermediate response overall	AD better	Intermediate response in mediastinum; NAD elsewhere
Post-chemo PET-CT (4 cycles/12 weeks; if relevant)		Intermediate response in the lungs; AD better in liver, LNs; NAD in femur	NAD	
Total bilirubin (mg/dL)	19	16	4.4	5.5
ALP (IU/L)			2211	1099
GGT (IU/L)	163	105	555	316
Albumin (g/dL)	2.1	2.4	2.9	2.7
PELD score	22	31.4	32	22
Underwent LT?	Yes	Yes	Yes	No
Age at LT (mo)	50	33	28	–
Indication for LT	DCLD, PHTN	DCLD, PHTN	DCLD, PHTN	–
Latest PET-CT	–	NAD	–	Intermediate response in mediastinum; NAD elsewhere
Follow-up (mo)	20	38	3	12
Status	On follow-up	On follow-up	On follow-up	On follow-up

Abbreviations: AD, active disease; ALP, alkaline phosphatase; DCLD, decompensated chronic liver disease; GGT, gamma glutamyl transferase; LCH, Langerhans cell histiocytosis; LN, lymph node; LT, liver transplantation; NAD, no active disease; PELD, pediatric end stage liver disease; PET-CT, positron emission tomography and computed tomography; PHTN, portal hypertension.

transplantation at remission. Chemotherapy was resumed after transplantation to complete 52 weeks of treatment. Patient 4 had a complete resolution of active disease in the risk organs; however, he remained stable in mediastinal disease. He was positive for the BRAF-V600E mutation. Hence, trametinib was added at a dose of 0.025 mg/kg/d to the maintenance therapy.¹⁵ His liver function stabilized after induction chemotherapy and hence he was continued with maintenance chemotherapy. His periodic monitoring schedule involved checking liver function every 3 months, cardiac function every 6 to 23 months, and assessing for other potential side effects, such as colitis, hemorrhagic events, skin rashes, and pulmonary signs and symptoms, during each visit. We plan to continue trametinib for 2 years (►Table 1 and ►Fig. 2).

Discussion

In this cohort, low-dose cytarabine-based chemotherapy was administered to the children with LCH and progressive liver dysfunction. All four children successfully tolerated chemotherapy and attained remission. After achieving complete remission, three patients underwent liver transplantation. One child had stable disease in the mediastinum but

had achieved complete resolution of the disease elsewhere. Following a multidisciplinary meeting, the treatment regimen was updated to include trametinib. This medication halts the MAPK pathway by inhibiting the activity of MEK1 and MEK2, thereby disrupting intracellular cell signaling that fosters tumor growth.¹⁶ A correspondence published in the *British Journal of Haematology* in 2014 highlighted the remarkable outcome of low-dose cytarabine-based treatment, which is comparable to the results of the present study.¹³ In a study conducted by Menon et al, low-dose cytarabine-based chemotherapy was employed in children with progressive liver dysfunction, demonstrating excellent results with this regimen.⁵

Conclusion

We propose that low-dose cytarabine/prednisolone-based regimen could serve as an appealing and less toxic alternative for children with active LCH and decompensated liver diseases. The low-dose cytarabine/prednisolone regimen is a well-tolerated chemotherapy regimen, with excellent outcomes. However, a large-scale prospective study is required to underpin this modified regimen and propagate its utility. If liver dysfunction persists, liver transplantation should be

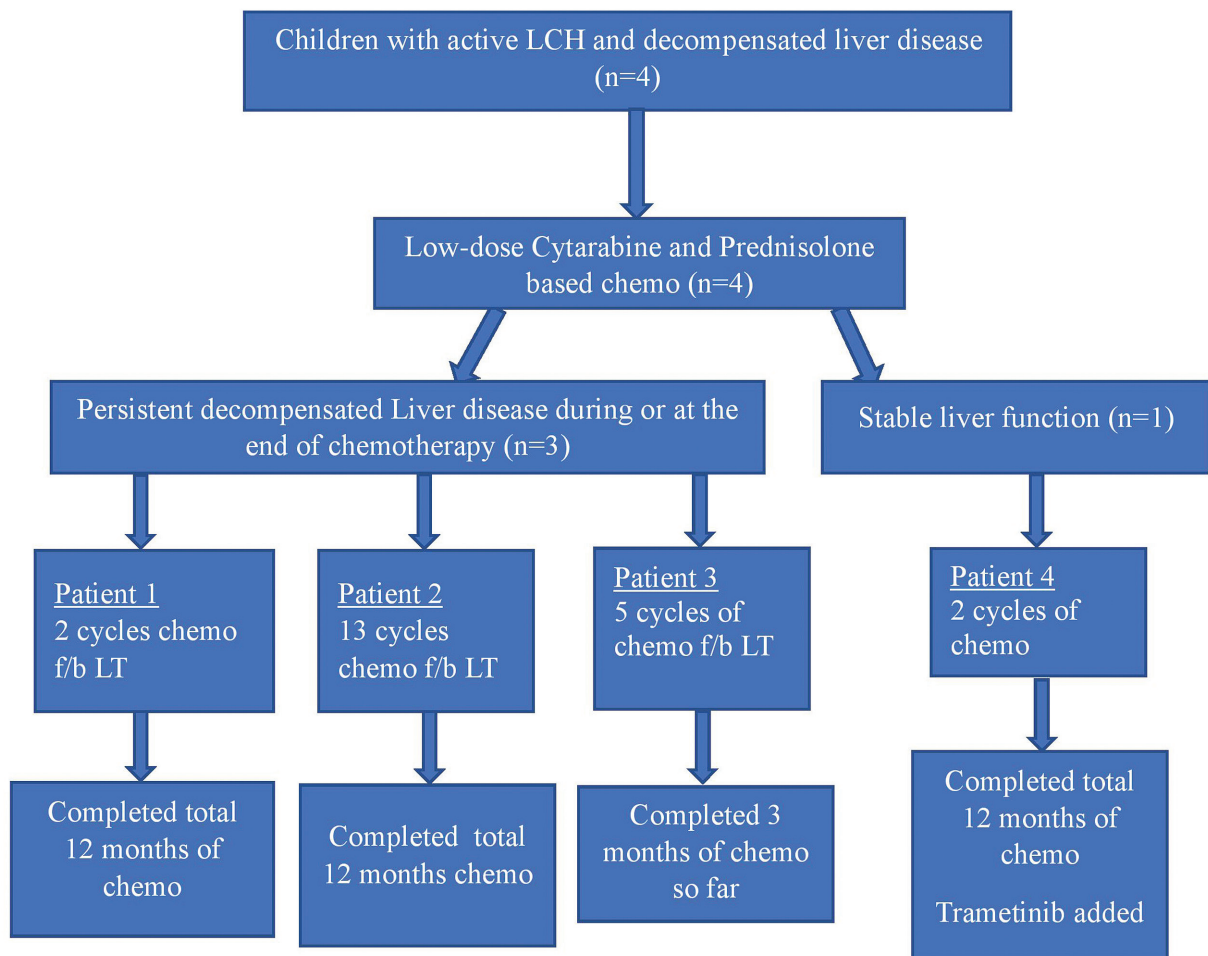


Fig. 2 Flowchart depicting the status of the liver disease and treatment received by the children. f/b = followed by; LT = liver transplantation; chemo = chemotherapy.

offered at complete remission to improve survival in these children.

Author Contributions

We state that all authors have contributed to the manuscript in significant ways, have reviewed and agreed upon the manuscript content.

N.G.H. contributed to the design of the study, literature studies, clinical studies, data acquisition, data analysis, statistical analysis, manuscript preparation, and manuscript editing. M.S.S. contributed to the concept and design of the study, definition of intellectual content, literature studies, manuscript preparation, manuscript editing, and manuscript reviewing. V.K.G. contributed to the concept of the study, definition of intellectual content, manuscript editing, and manuscript reviewing. D.M. contributed to the concept of the study, definition of intellectual content, manuscript editing, and manuscript reviewing.

Patient Consent

Patient consent was obtained.

Funding

None.

Conflict of Interest

None declared.

Acknowledgments

We acknowledge all the participants of the study. We extend our gratitude toward the faculty of the pediatric subspecialties—consultant pathologists, consultant radiologists, consultant biochemists, and many others. We are grateful for the contribution of the paramedical and nursing staff to patient management.

References

- 1 Yi X, Han T, Zai H, Long X, Wang X, Li W. Liver involvement of Langerhans' cell histiocytosis in children. *Int J Clin Exp Med* 2015; 8(05):7098–7106
- 2 Jaffe R. Liver involvement in the histiocytic disorders of childhood. *Pediatr Dev Pathol* 2004;7(03):214–225
- 3 Braier J, Ciocca M, Latella A, de Davila MG, Drajer M, Imventarza O. Cholestasis, sclerosing cholangitis, and liver transplantation in Langerhans cell histiocytosis. *Med Pediatr Oncol* 2002;38(03): 178–182
- 4 Haupt R, Minkov M, Astigarraga I, et al; Euro Histo Network. Langerhans cell histiocytosis (LCH): guidelines for diagnosis, clinical work-up, and treatment for patients till the age of 18 years. *Pediatr Blood Cancer* 2013;60(02):175–184
- 5 Menon J, Shanmugam N, Valampampil J, et al. Outcomes of liver transplantation in children with Langerhans cell histiocytosis: experience from a quaternary care center. *Pediatr Blood Cancer* 2023;70(01):e30024
- 6 Vinblastine: pediatric drug information. In: Post T, ed. UpToDate. Waltham, MA: UpToDate; 2023 Accessed August 13, 2023 at: www.uptodate.com
- 7 Anton W, Giuseppe G, Atkins MB. Goodman & Gilman's The Pharmacological Basis of Therapeutics. New York, NY: McGraw-Hill Education; 2018
- 8 Kaplan KJ, Goodman ZD, Ishak KG. Liver involvement in Langerhans' cell histiocytosis: a study of nine cases. *Mod Pathol* 1999;12(04):370–378
- 9 Sarin SK, Choudhury A, Sharma MK, et al; APASL ACLF Research Consortium (AARC) for APASL ACLF working Party. Acute-on-chronic liver failure: consensus recommendations of the Asian Pacific association for the study of the liver (APASL): an update. *Hepatol Int* 2019;13(04):353–390
- 10 Menon J, Rammohan A, Vij M, Shanmugam N, Rela M. Current perspectives on the role of liver transplantation for Langerhans cell histiocytosis: a narrative review. *World J Gastroenterol* 2022; 28(30):4044–4052
- 11 Donadieu J, Pigué C, Bernard F, et al. A new clinical score for disease activity in Langerhans cell histiocytosis. *Pediatr Blood Cancer* 2004;43(07):770–776
- 12 Minkov M, Rodriguez-Galindo C. Treatment of Langerhans cell histiocytosis: it is time to learn from the past. *Br J Haematol* 2015; 171(01):148–149
- 13 Simko SJ, McClain KL, Allen CE. Up-front therapy for LCH: is it time to test an alternative to vinblastine/prednisone? *Br J Haematol* 2015;169(02):299–301
- 14 Clinicaltrials.gov. Vinblastine/Prednisone versus Single Therapy with Cytarabine for Langerhans Cell Histiocytosis (LCH). Clinicaltrials.gov. Accessed September 13, 2023 at: <https://classic.clinicaltrials.gov/ct2/show/NCT02670707>
- 15 Cournoyer E, Ferrell J, Sharp S, et al. Dabrafenib and trametinib in Langerhans cell histiocytosis and other histiocytic disorders. *Haematologica* 2024 Apr 4;109(04):1137
- 16 Khunger A, Khunger M, Velcheti V. Dabrafenib in combination with trametinib in the treatment of patients with BRAF V600-positive advanced or metastatic non-small cell lung cancer: clinical evidence and experience. *Ther Adv Respir Dis* 2018; 12:1753466618767611