




# Perianal Paget's Disease Metachronically Associated with Adenocarcinoma

Camila Vieira Chiquetti<sup>1</sup>  Victor Hugo de Araújo Gonçalves<sup>2</sup> Leonardo Carnielli Uliana<sup>2</sup>  
Carlos Otávio da Silva Ribeiro<sup>3</sup> Odnilson Almeida Fonseca<sup>3</sup> Carlos Henrique Marques dos Santos<sup>3</sup>  
Luiz Carlos Takita<sup>4</sup>

<sup>1</sup>Hospital Regional do Mato Grosso do Sul (HRMS), MS, Brazil

<sup>2</sup>Medical Student, Universidade Estadual do Mato Grosso do Sul (UEMS), MS, Brazil

<sup>3</sup>Member of the Society Brazilian Journal of Coloproctology

<sup>4</sup>Faculdade de Medicina (FAMED), Universidade Federal do Mato Grosso do Sul (UFMS), MS, Brazil

Address for correspondence Camila Vieira Chiquetti, Street Petrópolis, 1220, Block 5, Apartment 103, Campo Grande – MS, Brazil (e-mail: milachiquetti5@hotmail.com).

J Coloproctol 2024;44(2):e141–e144.

## Abstract

**Introduction** This article describes an unusual case of perianal Paget's Disease in a 42-year-old man, highlighting distinct characteristics about more typical cases.

**Case report** 42-year-old male patient with persistent perianal lesion, recurrent abscesses, and discomfort. Magnetic resonance imaging indicated a possible fistulous path. Biopsy revealed secondary anal Paget's disease and adenocarcinoma. Chemotherapy and radiotherapy treatment demonstrated a positive response.

**Discussion** Perianal Paget's Disease is a rare condition of the anal canal that is part of the Extramammary Paget's Disease (EMPD) group. Symptoms include itching, pain, perianal bleeding, and skin lesions. Diagnosis can be challenging and usually involves performing a histopathological biopsy associated with an immunohistochemical study. Treatment varies and may involve surgery, radiotherapy, and chemotherapy. Due to the rarity of the disease, the best therapeutic approach is not yet well defined, and follow-up is essential due to the risk of recurrence.

**Conclusion** Perianal Paget's Disease is rare and requires differentiation from other conditions. Early detection is essential to prevent malignancy.

## Keywords

- ▶ Extramammary Paget's Disease
- ▶ rectal fistula
- ▶ Diseases of the Anus
- ▶ anal channel

## Introduction

Perianal Paget's Disease (PD) is a rare skin neoplasm that presents distinct clinical and histopathological characteristics. This scientific article explores an atypical case of perianal PD in a 42-year-old male patient, which differs from the prevalence characteristics observed in the literature.

## Case Report

A male patient, 42 years old, was referred from primary care, complaining of a hyperemic perianal lesion for a year, with a progressive increase in extension and recurrent episodes of local abscesses with spontaneous drainage. On physical examination, he showed perianal hyperemia associated with bilateral leukoplasic lesions accompanied by a right

received  
October 25, 2023  
accepted  
February 7, 2024

DOI <https://doi.org/10.1055/s-0044-1782156>.  
ISSN 2237-9363.

© 2024. The Author(s).

This is an open access article published by Thieme under the terms of the Creative Commons Attribution 4.0 International License, permitting copying and reproduction so long as the original work is given appropriate credit (<https://creativecommons.org/licenses/by/4.0/>).

Thieme Revinter Publicações Ltda., Rua do Matoso 170, Rio de Janeiro, RJ, CEP 20270-135, Brazil

lateral ulcerated lesion, with pain when pulling the buttocks apart, not tolerating rectal examination. An MRI of the pelvis was requested, showing a slight increase, in contrast, uptake in the right posterior perianal region, with a band-like appearance extending to posterior and inferior planes to consider the possibility of a small perianal fistulous path. A biopsy of the perianal lesion was chosen, the pathology of which suggested adenocarcinoma. Complemented study with immunohistochemistry that showed secondary anal Paget's disease, metachronically associated with infiltrative adenocarcinoma of the anal glands. The patient started treatment with clinical oncology showing response and lesion reduction after the third session of chemotherapy and radiotherapy.

## Discussion

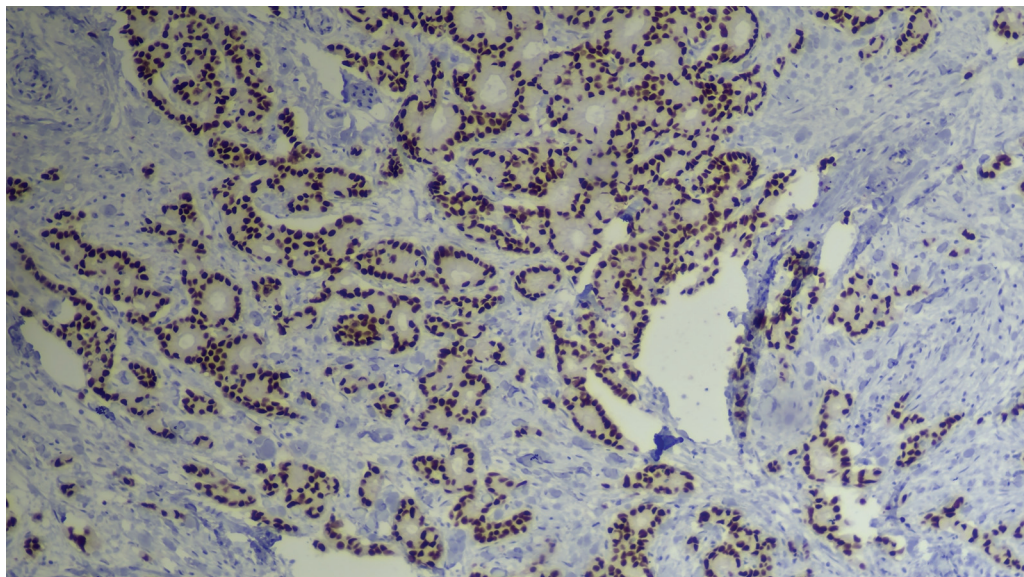
Perianal Paget's Disease is a very rare condition, accounting for less than 1% of anal canal pathologies.<sup>1</sup> This disease is included in a group of pathologies called Extramammary Paget's Disease (EMPD), which is a more frequent condition in the vulvar region, but can affect other regions such as the perianal region, perineum, scrotum, and armpit, as it affects the apocrine glands of the epidermis.<sup>2</sup> This disease is one of the four named by the British pathologist and surgeon, James Paget (1814- 1889), among which: Extramammary Paget's disease, Paget's disease, breast Paget's disease, and Paget's abscess, with DPEM being considered a pre-existing lesion. -malignant because it is characterized by high-grade intraepithelial dysplasia that can degenerate into adenocarcinoma.<sup>2</sup> The work of Rudnicki et al,<sup>3</sup> as an example, demonstrated that within a universe of 30 patients with this pathology, around 40% had invasive adenocarcinoma, as in the case of the patient in this study, with an estimated average survival of 16 years.<sup>3</sup>

In the current epidemiological scenario, it is clear in the literature that the predominance of this type of skin neoplasm

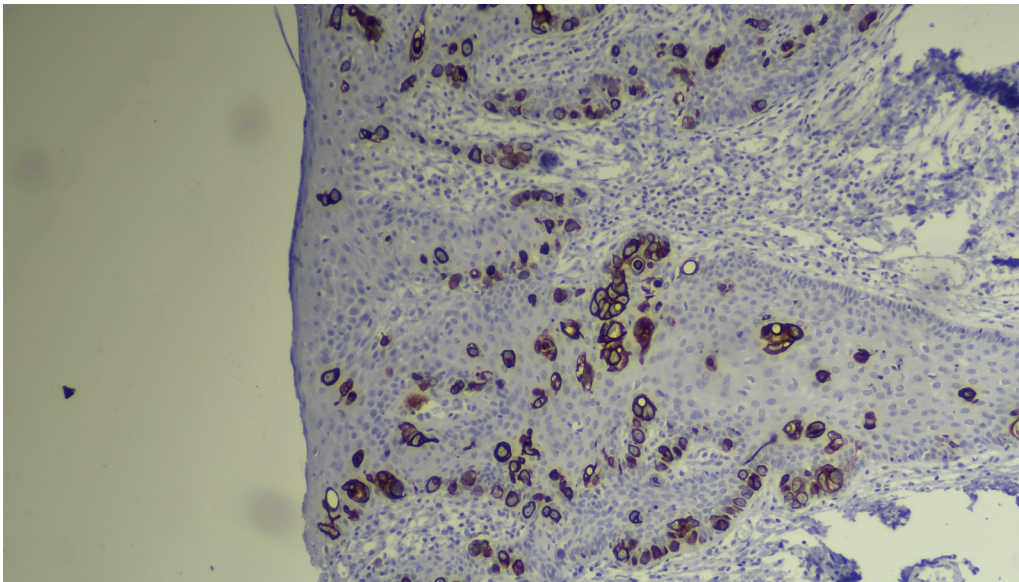
is more prevalent in Caucasian women aged 60-80 years,<sup>3</sup> but the incidence and prevalence vary according to the region, with some studies highlighting the predominance in men Asians.<sup>4</sup> In the case presented here, the patient was 42 years old and male, in disagreement with some literature.

Symptoms may vary from patient to patient, but the clinical picture commonly presents with perianal itching, which may have pain or bleeding with defecation, generally presenting as an erythematous lesion with defined borders, which may have scaling and associated lymphadenopathy.<sup>5</sup> However, the patient of the aforementioned case presented a picture for more than a year of bilateral leukoplactic lesions in the perianal region, painful to the touch, with ulcerated regions, in which these characteristics already demonstrate a more advanced process of the disease, which was later confirmed to be an adenocarcinoma secondary to perianal Paget's disease. Furthermore, the present case endorses the characteristics of delayed diagnosis of DPEM, which is mostly carried out 7 to 10 years after the appearance of the initial lesions.<sup>6,7</sup> Therefore, to investigate this pathology, biopsy is of great importance. histopathological analysis associated with an immunohistochemical study. On biopsy, the most common characteristics of DPEM are intraepithelial infiltration by large atypical neoplastic cells and a hypochromic halo.<sup>6</sup> In immunohistochemical investigation, some studies indicate variable positivity for CK7 and positivity for CK20 and CDX2. The patient's immunohistochemistry report in this case was positive for CDX2 (→ Fig. 1) and CK20 (→ Fig. 2), but negative for CK7.<sup>8</sup>

Due to the rarity of this disease and the few studies presented in the literature, the best therapeutic approach is not yet well defined, making it necessary to individualize each case and establish whether it will be surgical, clinical treatment, or both. Wide local resection of the lesion is usually the first approach to be established, but achieving adequate surgical margins is a challenge in perianal Paget's disease as it is difficult to detect macroscopically, in



**Fig. 1** CDX2-100x (Nuclear positivity).



**Fig. 2** CK20–100x (Cytoplasmic Positivity).

**Table 1** Classification and treatment of extramammary Paget's disease

Stage	Description	Treatment
I	Epidermal/intradermal Paget's cells found in perineal, scrotal, or vulvar area	WLE/MMS/TSE; if not amenable to resection or patient refusal of surgical treatment, consider 5% imiquimod
II A	Epidermal/intradermal Paget's disease with involvement anal canal	WLE plus transanal resection
II B	Epidermal/intradermal Paget's with synchronous malignancies	Treat the malignancy accordingly (e.g., abdominoperineal resection for rectal malignancy)
III	Epidermal/intradermal Paget's with node involvement (inguinal, iliac)	Chemotherapy
IV	Paget's disease with distant metastases of associated carcinoma	Chemotherapy, radiotherapy, local palliative treatment

Abbreviations: MMS, Mohs micrographic surgery; TSE traditional surgical excision; WLE, wide local excision.

addition to the technical difficulty due to the anatomical restriction of the anal canal. Histologically, the disease may be present in normal-appearing surrounding tissue due to the multifocal or projection growth pattern. One of the options, in addition to wide local excision, would be Mohs micrographic surgery,<sup>2,5</sup> widely used in skin cancer resections, which consists of repeated analyses of frozen sections intra-operatively until free margins are obtained. However, this technique may have limited use due to the challenging exposure and time required to perform the surgery in the prone or lithotomy position.<sup>9</sup> In some cases, if negative margins cannot be obtained with preservation of sphincter integrity or if there is associated malignancy in the anus or rectum, an abdominoperineal resection may be necessary. However, due to the morbidity associated with these surgical treatment strategies and case series demonstrating high recurrence rates,<sup>10</sup> other options have been used in combination or alone, with variable success, such as the topical use of imiquimod<sup>11,12</sup> and radiotherapy.<sup>13–15</sup> Moller et al.<sup>16</sup> proposed a classification and treatment scheme based on the stage of the disease (► **Table 1**).<sup>16</sup>

In the case of the patient reported here, in addition to Paget's disease, metachronous infiltrative adenocarcinoma of the anal glands was found, which would correspond to stage II B of this classification presented here. Therefore, it was decided to treat the malignancy, which in this case consists of neoadjuvant radiotherapy and chemotherapy before surgical resection. After treatment, some authors advocate strict monitoring due to the high risk of recurrence, carrying out a physical examination at least annually, with biopsy and colonoscopy at intervals of two to three years.<sup>5</sup>

## Conclusion

Paget's disease is rare in the perianal region and needs to be differentiated from other pathologies such as benign perianal fistulas. It is important to check the chronicity of the lesion to have an early clinical suspicion to avoid malignant transformation as occurred in this case.

**Conflict of Interest**  
None.

## References

- 1 Navajas Hernández P, Valdés Delgado T, Machuca Aguado J, González-Cámpora R, Argüelles Arias F. Perianal Paget's disease. *Rev Esp Enferm Dig* 2022;•••: Epub ahead of print. Doi: 10.17235/reed.2022.9304/2022 PubMed
- 2 Merichal Resina M, Cerdan Santacruz C, Sierra Grañón E, Tarragona Foradada JA, Olsina Kissler JJ. Enfermedad de Paget perianal. *Cir Esp* 2018. Doi: 10.1016/j.ciresp.2018.08.00
- 3 Rudnicki Y, Stapleton SM, Batra R, Gan T, Mathis KL, Kelley SR. Perianal Paget's-an aggressive disease. *Colorectal Dis* 2023;25:1213–1221 Epub ahead of print. Doi: 10.1111/codi.16549 PubMed
- 4 Simonds RM, Segal RJ, Sharma A. Extramammary Paget's disease: a review of the literature. *Int J Dermatol* 2019;58(08):871–879. Doi: 10.1111/ijd.14328
- 5 Thompson HM, Kim JK. Perianal Paget's Disease. *Dis Colon Rectum* 2021;64(05):511–515. Doi: 10.1097/DCR.0000000000002000
- 6 St Claire K, Hoover A, Ashack K, Khachemoune A. Extramammary Paget disease. *Dermatol Online J* 2019;25(04):13030/qt7qg8g292
- 7 Ventura S, Carvalho A, Rodrigues C, Domingues Â, Cancela E, Silva A. Perianal Paget's disease - A diagnosis to consider. *Rev Esp Enferm Dig* 2022;•••: Epub ahead of print. Doi: 10.17235/reed.2022.9224/2022 PubMed
- 8 Hutchings D, Winton A, Assarzadegan N, Salimian KJ, Voltaggio L, Montgomery EA. Perianal Paget's disease as spread from non-invasive colorectal adenomas. *Histopathology* 2021;78(02): 276–280. Doi: 10.1111/his.14218
- 9 Kim BJ, Park SK, Chang H. The effectiveness of mapping biopsy in patients with extramammary Paget's disease. *Arch Plast Surg* 2014;41(06):753–758
- 10 Perez DR, Trakarnsanga A, Shia J, et al. Management and outcome of perianal Paget's disease: a 6-decade institutional experience. *Dis Colon Rectum* 2014;57(06):747–751
- 11 Vereecken P, Awada A, Ghanem G, et al. A therapeutic approach to perianal extramammary Paget's disease: topical imiquimod can be useful to prevent or defer surgery. *Med Sci Monit* 2007;13(06): CS75–CS77
- 12 Ho SA, Aw DC. Extramammary Paget's disease treated with topical imiquimod 5% cream. *Dermatol Ther* 2010;23(04): 423–427
- 13 Mann J, Lavaf A, Tejwani A, Ross P, Ashamalla H. Perianal Paget disease treated definitively with radiotherapy. *Curr Oncol* 2012; 19(06):e496–e500. Doi: 10.3747/co.19.1144
- 14 Brown RS, Lankester KJ, McCormack M, Power DA, Spittle MF. Radiotherapy for perianal Paget's disease. *Clin Oncol (R Coll Radiol)* 2002;14(04):272–284
- 15 Besa P, Rich TA, Delclos L, Edwards CL, Ota DM, Wharton JT. Extramammary Paget's disease of the perineal skin: role of radiotherapy. *Int J Radiat Oncol Biol Phys* 1992;24(01):73–78
- 16 Möller MG, Lugo-Baruqui JA, Milikowski C, Salgado CJ. Staged marginal contoured and central excision technique in the surgical management of perianal Paget's disease. *Am J Surg* 2014;207(04): 485–492