



# Prenatal Diagnosis of Renal Rhabdoid Tumor: A Rare Malignant Neoplasm

Vidhika Berwal<sup>1</sup> Vivek Krishnan<sup>1</sup> Malini Eapen<sup>2</sup> Vidya Chandrababha<sup>2</sup> Rinshi Abid Elayedatt<sup>1</sup>

<sup>1</sup>Division of Fetal Medicine & Perinatology, Amrita Institute of Medical Sciences & Research Centre, Kochi, Kerala, India

<sup>2</sup>Department of Pathology, Amrita Institute of Medical Sciences & Research Centre, Kochi, Kerala, India

**Address for correspondence** Rinshi Abid Elayedatt, MS, DGO DNB PDF (FETAL MEDICINE), Division of Fetal Medicine & Perinatology, Amrita Institute of Medical Sciences & Research Centre, Kochi, Kerala 682041, India (e-mail: rinshielayedatt81@gmail.com).

J Fetal Med

## Abstract

### Keywords

- ▶ rhabdoid tumor
- ▶ rare renal neoplasm
- ▶ malignant renal tumor
- ▶ prenatal diagnosis
- ▶ prenatal ultrasound

Rhabdoid tumors of the kidney are highly lethal malignancies of infancy. We report the prenatal detection of this renal tumor in a fetus in the third trimester of pregnancy. Ultrasonologically, the tumor appeared as a large mass in the left renal area associated with severe polyhydramnios. Though the sonographic features alone did not allow distinction from a benign lesion, tumor extension into the subcutaneous plane favored the possibility of a malignant renal tumor and this was confirmed postnatally on histopathology.

## Introduction

Around 5% of perinatal tumors arise from the kidneys. However, their detection in the prenatal period is rare.<sup>1</sup> Differentiating between benign and malignant tumors is the prime concern with such tumors. However, in most cases, this cannot be achieved prenatally or even postnatally with sophisticated imaging techniques, and, therefore, histopathological examination plays a crucial role.<sup>2</sup> A rapid increase in size and rarely features of metastases may help in making the diagnosis of a malignant tumor.<sup>3,4</sup> We describe here a case of a unilateral renal tumor with subcutaneous extension and concomitant polyhydramnios at 33 weeks, 5 days of gestation. Postnatally, it proved to be a highly malignant rare renal neoplasm, a rhabdoid tumor with malignant components.

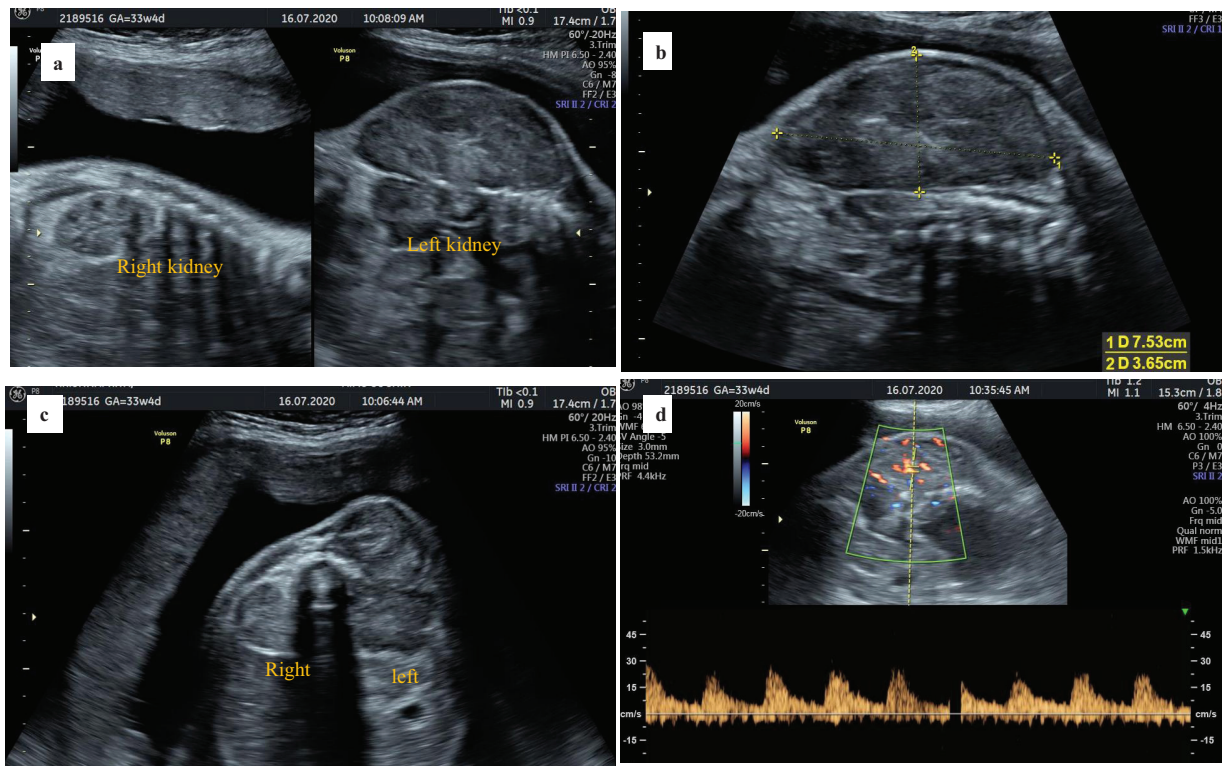
## Case Report

A 32-year-old second gravida with one living child was referred to us at 33 weeks, 5 days of gestation with unilateral

renal mass. The pregnancy till then had been uneventful with a normal first-trimester and second-trimester morphological scan at 22 weeks of gestation. An ultrasound examination in her revealed a fetus with normal growth parameters corresponding to 33 to 34 weeks of gestation with (▶**Fig. 1**) a well-defined heterogenous mass, arising from the upper pole of the left kidney with intra-abdominal and subcutaneous extension measuring 7.5 × 3.6 cm and increased vascularity with severe polyhydramnios, an amniotic fluid index of 37 cm), and left-sided pleural effusion with a mediastinal shift. The contralateral kidney, the liver, and the rest of the anatomy appeared normal. Considering the fast growth of the mass that was not visualized in the earlier anomaly scan and the cutaneous extension, the possibility of a malignant renal tumor was considered. Due to the non-visualization of the adrenal glands separately on the same side, the possibility of neuroblastoma was also considered a differential diagnosis. A thoracocentesis was planned which the couple decided to do the next day due to financial constraints.

DOI <https://doi.org/10.1055/s-0044-1780492>.  
ISSN 2348-1153.

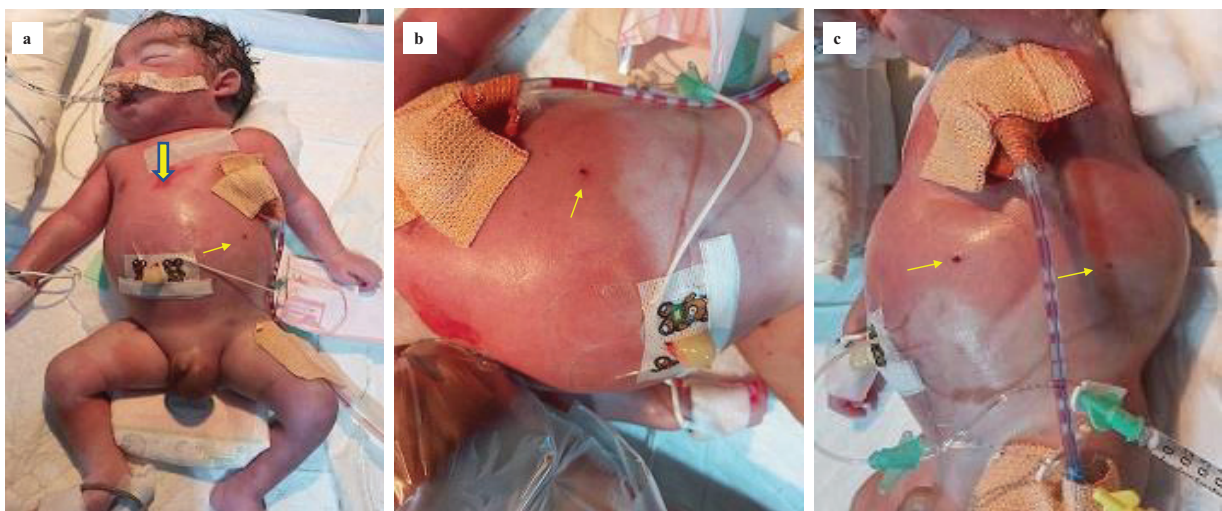
© 2024. Society of Fetal Medicine. All rights reserved.  
This is an open access article published by Thieme under the terms of the Creative Commons Attribution-NonDerivative-NonCommercial-License, permitting copying and reproduction so long as the original work is given appropriate credit. Contents may not be used for commercial purposes, or adapted, remixed, transformed or built upon. (<https://creativecommons.org/licenses/by-nc-nd/4.0/>)  
Thieme Medical and Scientific Publishers Pvt. Ltd., A-12, 2nd Floor, Sector 2, Noida-201301 UP, India



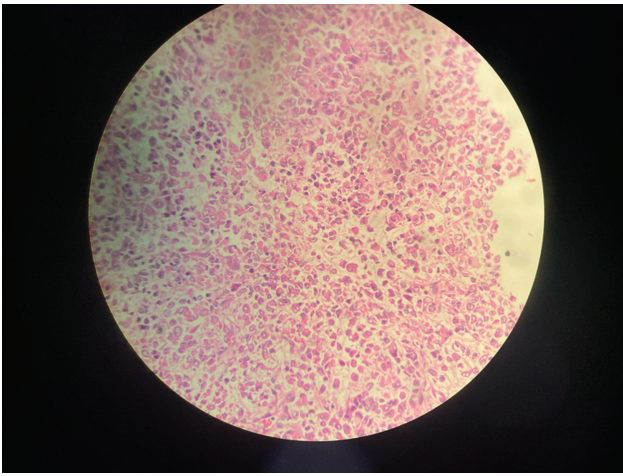
**Fig. 1** Parasagittal view of the fetal spine with (A) normal appearing right kidney and a well-defined, heterogeneous mass, seen arising from the upper pole of the left kidney extending both intra-abdominally and into subcutaneous plane (the renal parenchyma could not be separately demarcated from the mass). (B) Subcutaneous mass measuring 7.5 × 3.7 cm seen posteriorly. (C) Axial view of the fetal spine with kidneys bilaterally; the posterior subcutaneous extension of the renal mass seen as a bulge on the right side. (D) Color Doppler showing arterial pulsations suggesting tumor vascularity.

The next day, at 33 weeks, 6 days patient developed a preterm premature rupture of membrane and reported to the emergency and delivered a 3.5 kg male baby. The Apgar score at 1 and 5 minutes was 2. An immediate intercostal drainage was done that drained a bloodstained fluid, and a chest X-ray showed severe pulmonary hypoplasia and no free air. Blood gases revealed metabolic acidosis with raised

lactate. There was no pericardial effusion on postnatal echo, and as the baby developed hypotension, it was started on dopamine. Postnatal examination (–Fig. 2) showed blueberry muffins and hemorrhagic rashes over the body of the newborn and per abdominal examination showed a large hard mass occupying the left half of the abdomen. Further investigations were done in the postnatal period



**Fig. 2** (A, B) Postnatal photographs of the baby with solid arrow showing blueberry muffin rash and single arrow showing scattered hemorrhagic rashes all over the body (C) and the intercostal draining of blood-stained fluid and subcutaneous extension of renal mass seen as fullness of the left lumbar region.



**Fig. 3** Sections from the tumor showing areas of necrosis with few rhabdoid cells—hematoxylin and eosin stained 400x magnification.

including an ultrasound of the abdomen that revealed a large heteroechoic mass in relation to the posterolateral aspect of the left kidney, measuring  $7.5 \times 4$  cm. The biopsy from the skin lesion showed poorly differentiated neoplasm with few rhabdoid cells (—Fig. 3). Immunohistochemistry favored malignant rhabdoid tumors. Whole exome sequencing was done which did not reveal any pathogenic variant. Subsequently, medical exome sequencing done on the stored DNA of the baby reported mutations on SMARCB1 and SMAR 4 gene that are concomitant with the diagnosis of malignant rhabdoid tumor reported in the child. Despite all the resuscitative measures, the baby deteriorated and succumbed to death, secondary to deranged coagulopathy, pulmonary hypoplasia, and hypoxic ischemic encephalopathy. The parents declined a further perinatal autopsy.

## Discussion

Rhabdoid tumors of the kidney are one of the highly lethal malignancies in childhood.<sup>5</sup> The tumor was first identified in 1978 by the pathologists of the National Wilms' Tumor Study.<sup>6</sup> There is a paucity of data on rhabdoid tumors of the kidney in prenatal literature.

The prenatal ultrasound evaluation of the urinary tract is earliest possible from 9 to 12 weeks of gestation, when the fetal kidneys and adrenal gland are visible on either side of the lumbar spine due to their relative hyperechogenicity in the early trimester and additionally by the use of color Doppler to visualize the renal arteries. Cortico-medullary differentiation can be appreciated on ultrasound from 15 weeks onward. By 20 weeks of gestation, the kidneys appear as hyperechoic renal cortex with hypoechoic medulla due to the renal pyramids. The fetal urine production begins at 9 weeks of gestation, the fetal bladder should be seen from 13 weeks onward. By 20 weeks, approximately 90% of liquor is formed by the fetal urine.

The various renal pathologies detectable on prenatal ultrasound include renal agenesis in which the kidney is absent with empty lumbar fossa and the adrenal gland appears elongated, which is called the “lying down adrenal

sign.” When bilateral, it presents as early anhydramnios from 16 weeks, with absent bladder filling, and is a lethal condition. These can be confirmed by visualization of the renal artery on color Doppler and magnetic resonance imaging. Ectopic kidney is the presence of usually smaller or malrotated kidneys at ectopic sites, with the pelvic location being the commonest. Horseshoe kidneys, crossed (fused) ectopia, and even intrathoracic kidneys are other variants. Another entity called hyperechoic kidneys is when the kidneys appear brighter than the liver and spleen after 17 weeks of gestation. Kidneys appear hyperechoic in obstructive dysplasia, multicystic dysplastic kidney disease, nephroblastomatosis, renal vein thrombosis, ischemia, infection and metabolic diseases, nephrotic syndrome, aneuploidy, and polycystic kidney disease. Autosomal recessive polycystic kidney disease is characterized by cystic dilatation of the medulla with spared outer cortex on ultrasound after 20 weeks of gestation with decreased liquor. Autosomal dominant polycystic kidney disease on prenatal ultrasound shows moderately enlarged kidneys with both hyperechoic cortex and medulla filled by cysts. These cysts may be visible in the third trimester and the amniotic fluid volume is normal.

Multicystic kidney disease is a condition characterized by the replacement of entire normal renal parenchyma by multiple, noncommunicating cysts of varying size with an echogenic stroma secondary to embryologic maldevelopment. Obstructive cystic dysplasia is a progressive condition affecting the kidneys unilaterally, bilaterally or segmentally resulting in impaired renal function. This can present with variable liquor quantity. The dysplastic changes are usually seen confined to the upper pole of a normal kidney.<sup>7</sup>

Renal tumors are extremely rare in prenatal life. The most common fetal renal tumor is the mesoblastic nephroma, which is a benign mesenchymal tumor that appears as a solid or partially cystic tumor, with ill-defined margins due to the absence of capsule, associated with polyhydramnios on ultrasound examination and generally has a good prognosis.<sup>8</sup> The second most common is Wilms' tumor, a malignant tumor in which the kidney may be partly or totally replaced by a mass with increased vascularity on color Doppler. Nephroblastomas are capsulated tumors, characterized by multiple benign nodular lesions and bilateral involvement.<sup>9</sup>

Prenatal differentiation between benign and malignant nature of the lesions is difficult. Both benign and malignant lesions have comparable sonographic features including the appearance of the lesion, its vascularity, and the presence of associated polyhydramnios.<sup>10,11</sup> However, the only sonographic evidence of malignancy seems to be a sudden increase in the size of the lesion.<sup>3,10</sup>

Literature quotes several hypotheses regarding the appearance of polyhydramnios in fetal tumors. This has been attributed to increased urine production due to renal hyperperfusion,<sup>12</sup> in addition to decreased gastrointestinal fluid uptake due to bowel compression<sup>13</sup> or due to associated hypercalcemia-induced polyuria.<sup>14</sup> The most probable cause in this case would be a renal hyperperfusion as there was no sign of bowel obstruction in the neonate.



**Table 1** Literature review of prenatally diagnosed malignant rhabdoid tumors

Author	USG findings	GA at diagnosis	GA at delivery	Genetics	Postnatal exam	Child survival
White et al (1999) <sup>16</sup>	NS	33 wk	NS	Abnormality of chr 22q11	Face and neck, anterior cranial fossa, metastasis	Few minutes
Ohyama et al (2000) <sup>17</sup>	NS	33 wk	33 wk	NS	Liver and skin metastasis	4 d
Stahelin et al (2000) <sup>18</sup>	Cystic and solid involving right shoulder and sacrum polyhydramnios	31 wk	32 wk	46 XX, inv(11), (p13p15)	Rt shoulder and sacral tumor along with generalized multiple skin metastases	6 d
Höslı et al (2001) <sup>19</sup>	Right shoulder solid cystic tumor	31 wk	31 wk, 6 d	inv (11) (p13p15) (8)/46,XX	Generalized multiple skin metastases were present on the left hand, forehead, right foot, labia majora, left eye and one on the sacrum	6 d
Leader et al(2002) <sup>20</sup>	Vascularized tumor involving neck and left arm polyhydramnios	29 wk	30 wk	47,7[9]/47,ıdem,inc [2]/48,XX[9]	Neck, chest and left arm along with generalized multiple skin metastases	5 d
Fuchs et al (2004) <sup>21</sup>	Homogenous vascularized mass of left kidney polyhydramnios	26 wk	29 wk	Refused	NS	4 h (after surgery)
Kwon et al (2009) <sup>22</sup>	Solid tumor involving right upper arm polyhydramnios	35 wk	35 wk	Not done	Tumor involved whole right arm with overlying skin ruptured and active bleeding	11 d
Joueidi et al (2018) <sup>23</sup>	Vascularized heterogenous tumor in left arm pit, intra-abdominal organs, and subcutaneous space polyhydramnios	32 wk	32 wk	Mutation SMARCB1 (homozygous deletion of the 9 exons in tumor DNA)	NS	5 d
Schenone et al (2021) <sup>4</sup>	Mass in the left axilla, polyhydramnios and placental metastasis	36 wk	36 wk, 2 d	Not done	Mass over scapula, Bilateral thigh and right buttock	NS
Berwal et al (2024)	Vascular, homogenous tumor arising from upper pole of left kidney with subcutaneous extension	33 wk, 5 d	34 wk	Mutation SMARCB1 SMARCA4	Muffin like rash and hemorrhagic rashes over the body	10 h

Abbreviations: GA, gestational age; NS, not specified; USG, ultrasonography.

The prognosis of children with renal rhabdoid tumors is extremely poor<sup>15</sup> as the majority of affected children were known to have metastases to lymph nodes, brain, lungs, or liver.<sup>16</sup> Literature quotes several cases of extrarenal malignant rhabdoid tumor with renal metastasis<sup>4,16–23</sup> (► **Table 1**). However, no cases of prenatally diagnosed malignant renal rhabdoid tumors with subcutaneous extension have been reported in the literature thus far, to the best of our knowledge. Nevertheless, Trabelsi et al. have reported a case of malignant renal rhabdoid tumor with hepatic and skin metastasis in a neonate.<sup>24</sup>

The majority of malignant renal rhabdoid tumors were reported to involve single-gene mutations involving SMARCB1 and rarely SMARCA4 gene,<sup>25</sup> both of which were identified in the stored DNA sample of the neonate in our case. There are no reports of fetomaternal transmission of the malignancy so far; the mother is under follow-up for the same.

There are limited treatment options in such children due to the high lethality of this tumor. The proposed management of such cases includes postnatal surgery followed by postop chemotherapy.<sup>5</sup> The only prenatal intervention

proposed for these tumors is amnioreduction for polyhydramnios to prevent preterm labor, which could not be done in our case, due to the immediate delivery following the diagnosis of the lesion.

In conclusion, though rhabdoid tumors of the kidney are rare they should be included in the differential diagnosis of fetal renal masses especially when it presents as a rapidly growing renal mass or shows any other signs suggestive of tumor metastasis. The ability of the ultrasound to distinguish malignant from benign renal tumors is limited. A three-dimensional technology may not be useful for the investigator to delineate the extent of the lesion as the lesion may exceed the region of interest. However, the use of surface rendering mode may assist in screening for metastatic cutaneous nodules in utero that may be a pointer to a poor prognostic factor.<sup>23</sup> Even though there are no intrauterine treatments described for this condition, an accurate prenatal diagnosis can allow early delivery after offering a course of steroids for lung maturity and offer postnatal treatment soon after and thus prevent the development complications such as fetal hydrops.

**Informed Consent**

Written informed consent was obtained from the patients for participation and publication of this study.

**Ethical Approval**

This was in accordance with the ethical standards of the institutional and national research committee and with the 1964 Helsinki Declaration and its later amendments or comparable ethical standards.

**Authors' Contributions**

All authors contributed to the study's conception and design. All authors have read and approved the final manuscript.

**Conflict of Interest**

None declared.

**Acknowledgment**

We acknowledge the support from the Obstetrics and Gynecology, Department of Neonatology, Department of Pathology, Department of Pediatric Genetics and the Fetal Medicine team involved. We also thank the institute Amrita Institute of Medical Sciences for allowing us publish the data.

**References**

- Chen WY, Lin CN, Chao CS, et al. Prenatal diagnosis of congenital mesoblastic nephroma in mid-second trimester by sonography and magnetic resonance imaging. *Prenat Diagn* 2003;23(11):927–931
- Chung CJ, Lorenzo R, Rayder S, et al. Rhabdoid tumors of the kidney in children: CT findings. *AJR Am J Roentgenol* 1995;164(03):697–700
- Chung CJ, Cammoun D, Munden M. Rhabdoid tumor of the kidney presenting as an abdominal mass in a newborn. *Pediatr Radiol* 1990;20(07):562–563
- Schenone CV, King A, Castro E, Ketwaroo P, Donepudi R, Sanz-Cortes M. Prenatal detection of disseminated extrarenal malignant rhabdoid tumor with placental metastases. *Ultrasound Obstet Gynecol* 2021;57(06):1008–1010
- Wagner L, Hill DA, Fuller C, et al. Treatment of metastatic rhabdoid tumor of the kidney. *J Pediatr Hematol Oncol* 2002;24(05):385–388
- Beckwith JB, Palmer NF. Histopathology and prognosis of Wilms tumor results from the first national Wilms' tumor study. *Cancer* 1978;41(05):1937–1948
- Hindryckx A, De Catte L. Prenatal diagnosis of congenital renal and urinary tract malformations. *Facts Views Vis ObGyn* 2011;3(03):165–174
- Mata RP, Alves T, Figueiredo A, Santos A. Prenatal diagnosis of congenital mesoblastic nephroma: a case with poor prognosis. *BMJ Case Rep* 2019;12(08):e230297
- Sarin YK, Rahul SK, Sinha S, Khurana N, Ramji S. Antenatally diagnosed Wilms' tumour. *J Neonatal Surg* 2014;3(01):8
- Vadegar S, Ramsay M, James D, O'Neill D. Prenatal diagnosis of congenital Wilms' tumor (nephroblastoma) presenting as fetal hydrops. *Ultrasound Obstet Gynecol* 2000;16(01):80–83
- Goldstein I, Shoshani G, Ben-Harus E, Sujov P. Prenatal diagnosis of congenital mesoblastic nephroma. *Ultrasound Obstet Gynecol* 2002;19(02):209–211
- Geirsson RT, Ricketts NE, Taylor DJ, Coghill S. Prenatal appearance of a mesoblastic nephroma associated with polyhydramnios. *J Clin Ultrasound* 1985;13(07):488–490
- Howey DD, Farrell EE, Sholl J, Goldschmidt R, Sherman J, Hageman JR. Congenital mesoblastic nephroma: prenatal ultrasonic findings and surgical excision in a very-low-birth-weight infant. *J Clin Ultrasound* 1985;13(07):506–508
- Fung TY, Fung YM, Ng PC, Yeung CK, Chang MZ. Polyhydramnios and hypercalcemia associated with congenital mesoblastic nephroma: case report and a new appraisal. *Obstet Gynecol* 1995;85(5 Pt 2):815–817
- Vujančić GM, Sandstedt B, Harms D, Boccon-Gibod L, Delemarre JF. Rhabdoid tumour of the kidney: a clinicopathological study of 22 patients from the International Society of Paediatric Oncology (SIOP) nephroblastoma file. *Histopathology* 1996;28(04):333–340
- White FV, Dehner LP, Belchis DA, et al. Congenital disseminated malignant rhabdoid tumor: a distinct clinicopathologic entity demonstrating abnormalities of chromosome 22q11. *Am J Surg Pathol* 1999;23(03):249–256
- Ohyama M, Ijiri R, Tanaka Y, et al. Congenital primitive epithelial tumor of the liver showing focal rhabdoid features, placental involvement, and clinical features mimicking multifocal hemangioma or stage 4S neuroblastoma. *Hum Pathol* 2000;31(02):259–263
- Stahelin F, Bissig H, Hösli I, et al. Inv(11)(p13p15) and myf-3 (MyoD1) in a malignant extrarenal rhabdoid tumor of a premature newborn. *Pediatr Res* 2000;48(04):463–467
- Hösli I, Holzgreve W, Danzer E, Tercanli S. Two case reports of rare fetal tumors: an indication for surface rendering? *Ultrasound Obstet Gynecol* 2001;17(06):522–526
- Leader J, Carlan SJ, Blum J. Congenital malignant extrarenal rhabdoid tumor: prenatal ultrasound findings. *Obstet Gynecol* 2002;99(5 Pt 2):949–951
- Fuchs IB, Henrich W, Kalache KD, Lippek F, Dudenhausen JW. Prenatal sonographic features of a rhabdoid tumor of the kidney. *Ultrasound Obstet Gynecol* 2004;23(04):407–410
- Kwon JY, Park KI, Lee KS, Yang WI, Kim YH. Prenatal detection of congenital malignant extrarenal rhabdoid tumor primarily involving the right upper extremity that ruptured in utero. *Prenat Diagn* 2009;29(08):819–821
- Joueidi Y, Rousselin A, Rozel C, et al. Ultrasound presentation of a disseminated fetal and neonatal rhabdoid tumor. *Case Rep Obstet Gynecol* 2018;6073204
- Trabelsi F, Bouthour H, Bustame S. Rhabdoid tumor of the kidney: a new case of prenatal diagnosis with metastases immediately. *Med Sur Urol.* 2016;5(167):2
- Finetti MA, Grabovska Y, Bailey S, Williamson D. Translational genomics of malignant rhabdoid tumours: current impact and future possibilities. *Semin Cancer Biol* 2020;61:30–41