Article published online: 2024-02-09

Conversion to Autologous Breast Reconstruction with Latissimus Dorsi and Immediate Fat Grafting in Patients with Previous Implant Failure: An Efficient, Reproducible, and Safe Technique

Ivan Couto-González[1] Beatriz Brea-García[1] Adrián Ángel Fernández-Marcos[2] Antonio Taboada-Suárez[1]

[1] Department of Plastic and Reconstructive Surgery, Complexo Hospitalario Universitario de Santiago de Compostela, Santiago de Compostela, Spain
[2] Department of Plastic and Reconstructive Surgery, Centro Médico Povisa, Vigo, Spain

Indian J Plast Surg 2024;57:16–23.

Address for correspondence Ivan Couto-González, MD, MSc, Department of Plastic and Reconstructive Surgery, Servicio de Cirugía Plástica y Reparadora, Complexo Hospitalario Universitario de Santiago de Compostela, Rúa Ramón Baltar S/N, Zip Code: 15706, Santiago de Compostela, Spain (e-mails: ivan_couto@hotmail.com; ivan.couto.gonzalez@sergas.es).

Abstract

Introduction Implant-based breast reconstructions (IBBRs) increased last years despite the growing indications for radiotherapy in the treatment of breast cancer. As a result, complications and reconstructive failures associated to IBBR have increased. Autologous breast reconstruction (ABR) using fat-augmented latissimus dorsi (FALD) has become popular in recent years.

Methods We aimed to evaluate conversion to ABR using latissimus dorsi and immediate fat grafting in 61 cases with IBBR failure.

Results Immediate reconstruction was found significatively related with an increased number of surgeries resulting from IBBR complications ($p < 0.001$). Note that 41% of the cases presented a grade III/IV Baker and Palmer capsular contracture, 29% implant extrusion, and 21% implant infection. Mean survival of the first implant was 16.95 months. ABR process was completed in 47% of cases with a single surgery. Statistically significant differences were observed between this fact and previous IBBR failure due to infection ($p = 0.03$) or extrusion ($p = 0.01$). Mean volume of fat graft was 429.61 mL, mean length of the surgical procedure was 3.17 hours, and the average length of hospital stay after surgery was 2.67 days. Only 3.3% of the cases developed some major complication. None of the cases presented reconstructive failure.

Conclusion FALD is a very safe total ABR technique, an important fact in patients with previous reconstructive failures. The large volume of fat that can be grafted in a single surgery allows the reconstruction of breast in a reasonable size. The reduced length of surgery and hospital stay make the FALD technique an option to consider when an autologous but efficient and safe reconstruction is desired.

Keywords
- breast reconstruction
- latissimus dorsi
- fat-grafting
- implant failure
- postoperative complication
- lipofilling

article published online
February 9, 2024

DOI https://doi.org/10.1055/s-0044-1779479.
ISSN 0970-0358.

© 2024. Association of Plastic Surgeons of India. All rights reserved.
This is an open access article published by Thieme under the terms of the Creative Commons Attribution-NonDerivative-NonCommercial-License, permitting copying and reproduction so long as the original work is given appropriate credit. Contents may not be used for commercial purposes, or adapted, remixed, transformed or built upon. (https://creativecommons.org/licenses/by-nc-nd/4.0/)
Thieme Medical and Scientific Publishers Pvt. Ltd., A-12, 2nd Floor, Sector 2, Noida-201301 UP, India

Introduction

Since the early 2000s, breast reconstruction with implants has prevailed over autologous breast reconstruction (ABR).[1] Today, 80% of breast reconstructions are implant-based breast reconstructions (IBBRs).[2] This increase in IBBR has been associated with a number of factors, including indications for contralateral mastectomy, a better surgical performance, and less demanding surgical skills.[1] Nevertheless, indications for radiotherapy in breast cancer are growing.[3,4] The side effects of radiotherapy in IBBR are widely associated with a higher rate of reconstructive failure,[5,6] being significantly higher than in those who have undergone ABR.[7] This scenario has resulted in an increased number of patients who have initially undergone IBBR before experiencing serious complications. Sometimes, these implant complications occur repeatedly after successive prosthetic replacements until the patient rejects further implant surgery or decides to convert to ABR.

ABR using fat-augmented latissimus dorsi (FALD), originally described by Santanelli di Pompeo et al[8] in 2014, has become popular in recent years.[9–11] It is a totally autologous reconstructive procedure which presents few complications and is based on well-known techniques: harvesting a latissimus dorsi (LD) flap and fat-grafting procedures.

The aim of this study was to evaluate the safety, rates of complications, and reconstructive failure using the FALD technique in patients with prior failure of IBBR, in an attempt to offer them a safer reconstructive procedure.

Materials and Methods

A prospective *case series* study was performed from May 2014 to December 2020. The inclusion criteria were women with a failed IBBR and a subsequent conversion to ABR using FALD. A minimum 1-year follow-up period after ABR was considered. A magnetic resonance imaging (MRI) or ultrasound (US) was performed at least 6 months after the end of the ABR in all of the patients. Patients who were not in compliance with the above criteria were not eligible for inclusion in the study. Patients who underwent hybrid reconstruction were excluded from the study. A study protocol was applied on every patient, focusing on their previous reconstructive history, the characteristics of conversion to ABR, and the development of potential complications. Major complications were defined as being when the patient required surgery or hospital admission for their treatment. Minor complications were considered when only outpatient and conservative treatment was necessary. Reconstructive failure was defined as when a new surgical procedure was required, including implant removal, implant exchange, or ABR conversion.

Surgical Technique (►Video 1)

Video 1

Key steps of the fat-augmented latissimus dorsi (FALD) technique. From the extraction of adipose tissue by liposuction to the grafting of the processed tissue in breast reconstruction, including LD flap harvesting and adipose tissue centrifugation. Online content including video sequences viewable at: https://www.thieme-connect.com/products/ejournals/html/10.1055/s-0044-1779479.

The first part of the intervention should be performed with the patient in a decubitus supine position and consists of obtaining the fat graft by liposuction and the preparation of the mastectomy area. Previous scar tissue is removed. Implants removal and capsulectomy are realized if any implant problem is present. Subsequently, the patient is placed in the lateral decubitus position for the harvest of LD flap while the liposuctioned fat is processed. Finally, the patient is returned to the decubitus supine position for fat grafting and the insetting of the flap.

We prefer the abdominal region as the fat graft donor site. Liposuction is performed, after infiltration with 1:1,000,000 epinephrine saline solution, with a Mercedes-type cannula (3 mm; 32 cm). The lipoaspirate is centrifugated for 3 minutes using a fixed-rotor centrifuge (Thermo Scientific MediLite, Austin, Texas, United States; 3,100 revolutions per minute; 1,228 *g*) and serum and supernatant are disposed of. The syringes employed in the centrifugation process (10-mL Luer-lock syringes, B-Braun, Melsungen, Germany) are directly employed in the subsequent fat grafting (►**Video 1**).

The decision to make a LD flap with an external skin island depends on the amount of skin on the breast to be reconstructed. If there is good quality skin, we prefer to deep-ithelialize the skin island of the flap to avoid different aesthetic units in the breast. We rarely use a pure muscle flap and prefer to deepithelialize the island of the myocutaneous flap providing extra volume. We always draw the skin island approximately 3 to 4 cm wider than the mastectomy scar to improve the natural, curved shape of the breast. We do not perform denervation or detachment from the humeral insertion of the muscle. When harvesting the flap, we seek to recruit as much subcutaneous fat as possible, especially, from the lumbar area.[12] Once the flap has been harvested and transferred, the donor site of the flap is sutured in layers, a Blake drain is placed, and the patient is returned to the decubitus supine position.

The fat grafting is performed before the flap is anchored to the recipient area. We use 16-gauge cannulas (Coleman Infiltration cannula, Style I for body-16 ga. Mentor), to make a homogeneous "drop-by-drop" or "spaghetti-like" three-dimensional infiltration along the LD flap, the pectoralis major

 © 2024. Association of Plastic Surgeons of India. All rights reserved.

muscle, and the skin flaps of the mastectomy. Although most of the fat graft is placed in the muscular portion of the LD muscle, sufficient grafting in the pectoralis major muscle is also important if the aim is to achieve adequate shape and volume of the upper pole of the breast in a single operation. Mastectomy flaps usually admit small amounts of fat graft, but makes it possible to correct small volumetric defects.

Once the fat grafting has been completed, the flap will be adapted to the recipient area. The lower part of the cutaneous island is always anchored along the inframammary fold. The muscular portion of the LD flap usually overlaps the pectoralis major muscle. If extra volume is required in the lower pole of the breast, this muscular portion can be folded in on itself under the cutaneous island of the LD and anchored to the thoracic wall. The recipient site is sutured in layers after careful hemostasia and the placing of a Blake drain.

The patient should wear a specific bra and thoracoabdominal compression garments for a month after surgery.

Statistical Analysis

Data concerning patient records were analyzed using IBM SPSS Statistics 22.0 (IBM Corp., Armonk, New York, United States). The Kolmogorov–Smirnov goodness-of-fit test was used to verify the normality of the distributions. The Mann–Whitney *U* test was employed to study correlations between nonparametric distributions. The Student's *t*-test was used to study parametric distributions. Pearson's chi-square test was employed to study the relationship between qualitative variables. Statistical significance was considered when $p < 0.05$.

Results

A total of 316 ABRs using the FALD technique were operated during the study period, with a history of IBBR failure in 61 (19%) of the cases. Fifty-six patients were finally included in the study (5 with bilateral IBBR failure). Of the 61 reconstructions, 52% (32) were in the right breast and 48% (29) in the left. The mean age when undergoing ABR conversion was 50.85 years (range 36–73). Mean body mass index (BMI) when ABR conversion occurred was 28.70 kg/m^2 (range 21.63–41.78), with 34% (21) of patients living with obesity.

IBBR was performed immediately after mastectomy in 67% (41) of the cases. Reconstructive timing (immediate/delayed) was not found to be statistically related with the number of autologous surgeries required ($p = 0.92$) or with the volume of fat grafted ($p = 0.40$).

Radiotherapy had been administered in 74% (61) of the cases. Of the 61 cases, 51% (31) still had the breast implant when ABR was performed (►**Fig. 1**), while in 49% (30) of the cases the breast implant had been previously explanted (►**Fig. 2**). All cases had experienced at least one IBBR failure

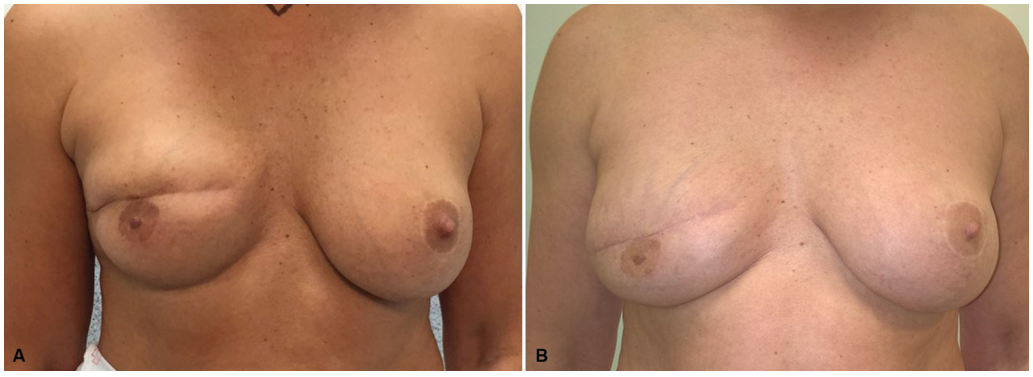

Fig. 1 (**A**) Grade IV capsular contracture in a patient who had undergone a previous surgery due to the same problem. (**B**) Postoperative view 7 months after implant removal, capsulectomy, and fat-augmented latissimus dorsi (FALD) (370 mL of fat graft).

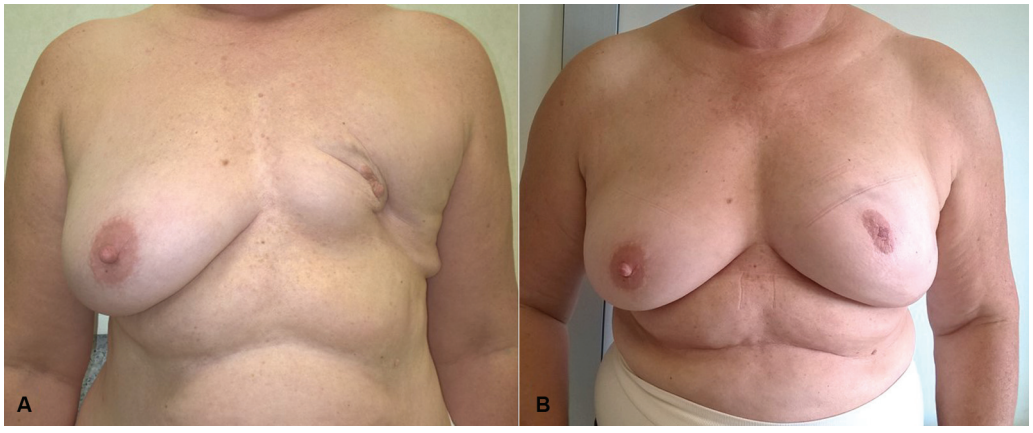

Fig. 2 (**A**) A 56-year-old patient who underwent two previous implant-based breast reconstruction (IBBR) failures due to infection in both cases. (**B**) Appearance of the reconstruction 14 months after fat-augmented latissimus dorsi (FALD) reconstruction with 415 mL of fat graft.

 © 2024. Association of Plastic Surgeons of India. All rights reserved.

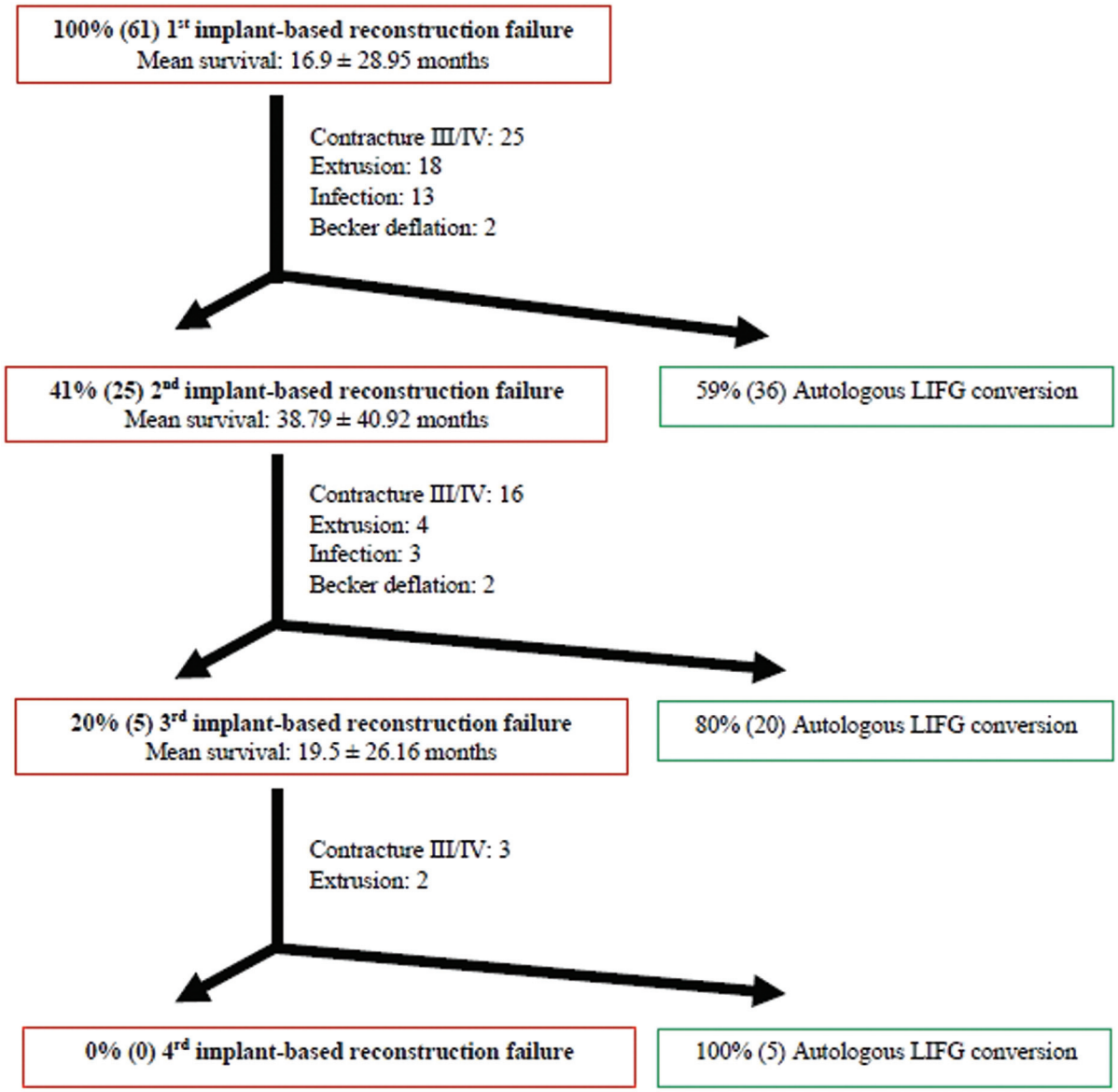

Fig. 3 Reconstructive course of the patients included in the study. The majority underwent conversion to autologous breast reconstruction (ABR) after failure of the first implant-based breast reconstruction (IBBR). In no cases were more than three implant-based reconstructions attempted.

(►**Figs. 3** and **4**). In 5% (3) of the cases the aesthetic result was unacceptable for the patient, despite not presenting any of the aforementioned complications.

A statistically significant relationship was found between cases of implant infection and the total number of autologous surgeries needed ($p = 0.02$), the number of fat-grafting sessions required after FALD ($p = 0.02$), and the volume of fat graft employed ($p = 0.01$) (►**Fig. 5**). In cases with a previous implant extrusion, statistically significant differences were found with the total number of autologous surgeries ($p < 0.001$) and the number of fat-grafting sessions needed after FALD surgery to achieve a satisfactory ABR ($p < 0.001$) (►**Table 1**).

A single autologous surgery was sufficient for the completion of the ABR conversion in 45% (27) of the patients. No statistically significant differences were found between patients maintaining the implant or not at the time of FALD surgery and completing the process with a single procedure ($p = 0.90$). Statistically significant differences were observed between completion of the autologous conversion in a single surgery and a previous history of breast reconstruction failure due to implant infection ($p = 0.03$) or implant extrusion ($p = 0.01$) (►**Fig. 6**) (►**Table 2**).

The mean volume of fat graft used to complete the ABR was 429.61 mL (range 100–755). The mean volume employed in the FALD procedure was 310.57 mL (range 100–510). If required, additional fat-grafting surgeries were performed an average of 8.3 (range 6–14) after FALD. No second fat-grafting sessions were necessary in any case.

The mean length of the surgical procedure in cases of unilateral conversion was 3.17 hours (range 2.15–4.72) and 4.63 hours (3.60–5.10) in bilateral cases.

 © 2024. Association of Plastic Surgeons of India. All rights reserved.

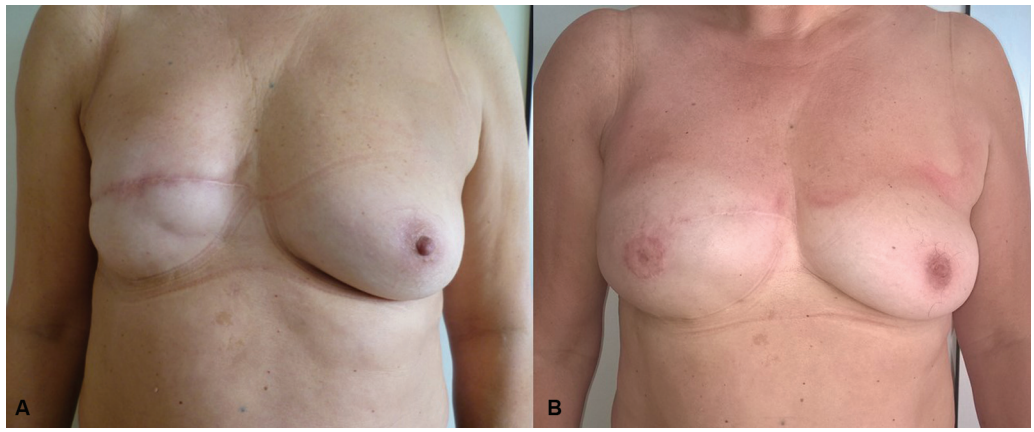

Fig. 4 (**A**) Patient who underwent implant-based breast reconstruction (IBBR) and postoperative radiotherapy developing an early grade IV capsular contracture. (**B**) Postoperative view 7 months after conversion to autologous breast reconstruction (ABR) using the fat-augmented latissimus dorsi (FALD) technique (280 mL of fat graft).

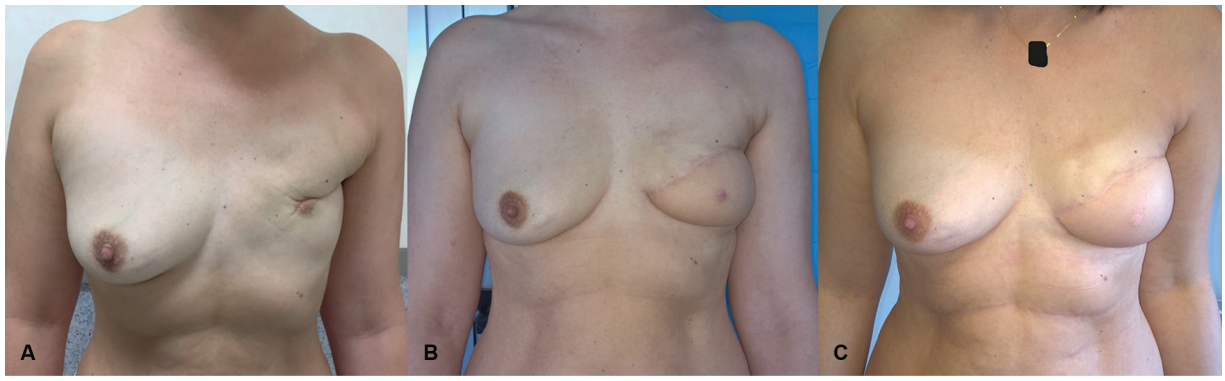

Fig. 5 (**A**) Radiated patient with two previous implant-based breast reconstruction (IBBR). (**B**) Postoperative view 7 months after fat-augmented latissimus dorsi (FALD) surgery with 260 mL of fat graft. (**C**) Postoperative appearance 9 months after complementary lipofilling (220 mL) prior to nipple-areolar complex (NAC) reconstruction.

Table 1 Previous implant complications and their relationship with total autologous surgeries, additional AFG sessions, and AFG total volume

	History of Baker grade III/IV capsular contracture	History of implant infection	History of implant extrusion
Total autologous surgeries	No: 1.56 ± 305 Yes: 1.52 ± 0.5 $p = 0.72$	No: 1.46 ± 0.5 Yes: 1.80 ± 0.41 $p = 0.02$[a]	No: 1.26 ± 0.45 Yes: 1.67 ± 0.48 $p < 0.001$[a]
Additional AFG sessions	No: 0.56 ± 0.5 Yes: 0.52 ± 0.5 $p = 0.72$	No: 0.46 ± 0.5 Yes: 0.8 ± 0.41 $p = 0.02$[a]	No: 0.26 ± 0.45 Yes: 0.67 ± 0.48 $p < 0.001$[a]
AFG total volume	No: 433.31 ± 166.98 mL Yes: 425.52 ± 155.68 mL $p = 0.69$	No: 401.65 ± 152.71 mL Yes: 515.33 ± 157.52 mL $p = 0.01$[a]	No: 374.79 ± 153 mL Yes: 454.4 ± 158 mL $p = 0.09$

Abbreviation: AFG, autologous fat grafting.
[a]Statistical significance.

Only 3.3% (2) of the cases developed a major complication. Minor complications arose in 26% (16) of the cases (►**Table 3**). Statistical significance was found in relation to obesity at the time of FALD surgery and the development of major complications ($p = 0.05$), minor complications ($p = 0.01$), and with all of the individual complications studied (partial necrosis of the flap $p = 0.05$; seroma in the donor site area $p < 0.001$; dehiscence of surgical wound $p < 0.001$; detection of nodes of fat necrosis or oil cyst upon physical examination $p = 0.03$; detection of nodes of fat necrosis or oil cyst when performing imaging techniques $p = 0.05$).

A history of previous radiotherapy was not found to be significantly related with the presence of major complications ($p = 0.40$) or minor complications ($p = 0.23$).

 © 2024. Association of Plastic Surgeons of India. All rights reserved.

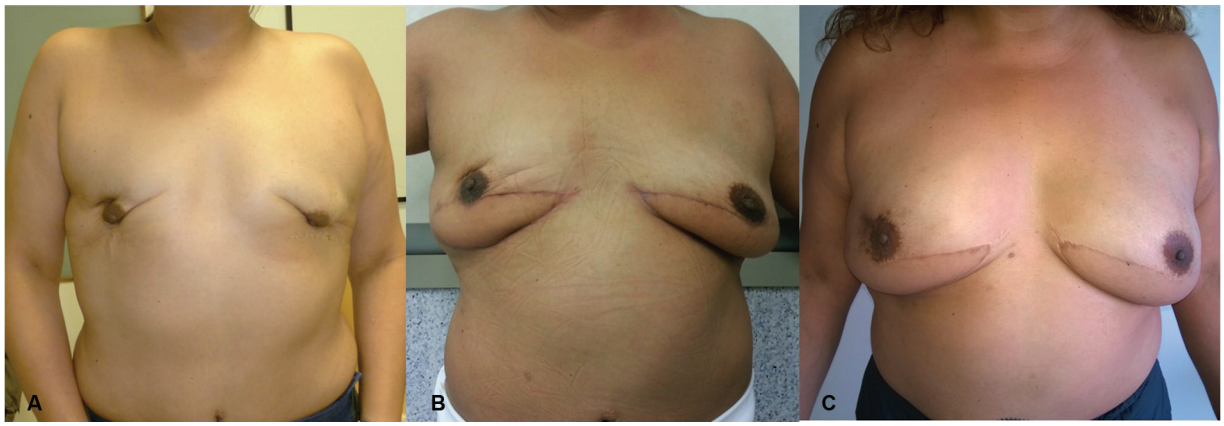

Fig. 6 (**A**) Patient with three bilateral implant-based breast reconstruction (IBBR) failures due to infection/extrusion. (**B**) Postoperative view 6 months after bilateral fat-augmented latissimus dorsi (FALD) (330 mL right, 335 mL left). (**C**) Postoperative view 13 months after lipofilling (280 mL right breast, 290 mL left).

Table 2 Studied factors and their influence on ABR in a single procedure

		Autologous conversion in a single procedure (LIFG)		*p*-Value
		No	Yes	
Presence of implant at LIFG surgery	No	17	17	0.90
	Yes	13	14	
Initial immediate breast reconstruction	No	23	11	0.93
	Yes	18	9	
Obesity	No	24	10	0.35
	Yes	16	11	
History of radiotherapy	No	11	23	0.22
	Yes	5	22	
History of Baker grade III/IV capsular contracture	No	19	15	0.54
	Yes	13	14	
History of implant infection	No	22	12	0.03[a]
	Yes	24	3	
History of implant extrusion	No	28	6	0.01[a]
	Yes	14	13	

Abbreviations: ABR, autologous breast reconstruction; LIFG, latissimus dorsi and immediate fat grafting.
[a]Statistical signification.

Table 3 Complications after ABR

Complication	% (*n*)
Partial skin island flap necrosis	3.3 (2)
Flap donor site seroma	14.8 (9)
Wound dehiscence	11.5 (7)
Fat necrosis nodule/oil cyst[a]	11.5 (7)
Fat necrosis nodule/oil cyst[b]	19.7 (12)

Abbreviation: ABR, autologous breast reconstruction.
[a]At physical examination.
[b]Ultrasound/magnetic resonance exploration.

The average length of hospital stay following FALD surgery was 2.67 days (1–7) and the mean follow-up after the last surgery was 27.25 months (range 12–59).

Discussion

The analysis of IBBR failures has a limited timeline in many of the published studies. Follow-up periods are, in many cases, lamentably short.[13–15] However, data regarding rates of failure in IBBR, especially in radiated patients, are remarkable. With a follow-up of only 12 months, Cordeiro et al show a reconstructive failure rate of 11% in the group of radiated

 © 2024. Association of Plastic Surgeons of India. All rights reserved.

patients. Pathological capsular contracture was not considered as a reconstructive failure in this study, but in the group of radiated patients, it reached striking values of 34% in grade III and 6% in grade IV.[13] Other recent series, such as the MROC multicenter study, show a reconstructive failure rate between 10 and 20% when radiotherapy is administered on the definitive implant or expander. In this study, with a follow-up period of 24 months, capsular contracture was not studied.[15] Therefore, it can be seen that in some studies in which IBBR is analyzed, there is a tendency to minimize complications arising in the form of capsular contracture. Not considering pathological capsular contracture as a true reconstructive failure[13–17] may be due to its occurrence beyond the immediate postoperative period but does not exclude the fact that it is a cause of discomfort, pain, or unsatisfactory aesthetic result. In these situations, a new surgical procedure is unavoidable. In our series, Baker grade III/IV capsular contracture was studied in depth, and the conclusion was drawn that it is fair to consider it as a completely justified cause of reconstructive failure taking into account the fact that 41% of the cases had to undergo surgery again for this reason after their reconstruction had supposedly ended. Attempting to exclude this complication as a cause of reconstructive failure when it is the most frequent cause of reoperation in patients undergoing IBBR[18] seems unacceptable if what is sought is an objective assessment of the quality of the reconstructive procedure.

It seems paradoxical that with IBBR being the most frequent method of breast reconstruction, even more so in the context of the increasing indication of radiation therapy, there is little published evidence on this aspect of breast reconstruction.[19]

Based on our own data and other published studies, it can be observed that, even today, there are patients who undergo a mastectomy without being fully informed of the pros and cons of the different reconstructive methods, especially in the cases with radiotherapy. The association between IBBR and radiotherapy has shown failure rates of close to 50%.[14] We believe that, beyond short-term economic criteria and surgical skills, ABR presents fewer complications, lower rates of reconstructive failure, and higher quality long-term results.[20,21]

FALD reconstruction is a totally autologous, nonmicrosurgical procedure, which is highly efficient with an exceptional reconstructive failure rate and excellent long-term results.[8–10,22–24] The main limitation initially assigned to this type of ABR was whether the amount of fat grafted in a single surgery could provide enough volume to accomplish the reconstruction without complications. Previous studies have shown that a suitable flap adaptation to the recipient site, together with a correct fat-grafting technique,[9] allows the grafting of reasonably large volumes without increasing complications, including fat necrosis.[25,26] The oncological safety of lipofilling techniques has been demonstrated. Fat grafting in a previously treated area of carcinoma has not been associated with increased recurrence rates.[27,28] This, together with the great versatility of the technique, has led to the widespread use of lipofilling in breast surgery, been employed as a method for total breast reconstruction,[28,29] combined with implants,[30] to repair the sequelae of breast-conserving surgery[31] or combined with different flaps.[9,32]

In our study, almost half of the patients (45%) required no additional surgery to complete the reconstruction. These data show the high efficacy of the FALD technique in providing large volumes in a single surgical procedure with a low complication rate. The only factor related to a higher rate of fat necrosis nodes was obesity. However, even in patients with a high BMI, the reconstructive failure rate was null. These data support FALD as a safe technique, even in patients with obesity, in which microsurgical ABR may present slightly increased rates of flap loss.[7,33]

Intramuscular fat grafting could theoretically lead to an increased risk of fat embolism, but most of the reported cases have occurred in cases of gluteal augmentation or treatment of genital areas. In addition, it is impossible to distinguish whether a fat embolism is due to liposuction or the subsequent fat grafting.[34] Moreover, no intramuscular calcifications due to fat grafting have been observed in the postoperative US/MRI. The fact that most of the fat graft is placed in an intramuscular plane does not appear to affect the survival of the flap. In fact, with the aforementioned fat-grafted volumes there were cases of muscle injury.

Data regarding surgical complications in our patients are similar to other FALD series in which nonextended LD flaps were employed.[35] We believe that close monitoring of drains, together with patient awareness of the importance of careful wound care are essential aspects in reducing postoperative complications.

Length of FALD surgery hospital stay and reoperation due to complications have been lower than data provided by studies evaluating microsurgical ABR.[36,37]

Conclusion

FALD is a total ABR technique with a low complication rate and very rare reconstructive failure. This is particularly important for patients who have suffered previous reconstructive failures.

The considerable volume of fat graft in a single surgery makes it possible to reconstruct breasts of a reasonable size. Additional volume or small corrections in the shape and contour of the reconstructed breast can easily be achieved with subsequent lipofilling.

Due to its efficiency, FALD technique must be considered an option to be taken into account when an autologous, but safe and efficient reconstruction, is desired.

Conflict of Interest
None declared.

Acknowledgments
The authors would like to thank Mr. Paul J. Lacey, BA, MA, DipTrans, for his kind review of the English version of the manuscript.

References

1 Panchal H, Matros E. Current trends in postmastectomy breast reconstruction. Plast Reconstr Surg 2017;140(5S Advances in Breast Reconstruction):7S–13S

 © 2024. Association of Plastic Surgeons of India. All rights reserved.

2 Coriddi M, Shenaq D, Kenworthy E, et al. Autologous breast reconstruction after failed implant-based reconstruction: evaluation of surgical and patient-reported outcomes and quality of life. Plast Reconstr Surg 2019;143(02):373–379
3 Frasier LL, Holden S, Holden T, et al. Temporal trends in postmastectomy radiation therapy and breast reconstruction associated with changes in National Comprehensive Cancer Network guidelines. JAMA Oncol 2016;2(01):95–101
4 Ragaz J, Jackson SM, Le N, et al. Adjuvant radiotherapy and chemotherapy in node-positive premenopausal women with breast cancer. N Engl J Med 1997;337(14):956–962
5 Cordeiro PG, Albornoz CR, McCormick B, Hu Q, Van Zee K. The impact of postmastectomy radiotherapy on two-stage implant breast reconstruction: an analysis of long-term surgical outcomes, aesthetic results, and satisfaction over 13 years. Plast Reconstr Surg 2014;134(04):588–595
6 Taboada-Suarez A, Brea-García B, Magán-Muñoz F, Couto-González I, González-Álvarez E. Risk factors associated with complication rates of Becker-type expander implants in relation to implant survival: review of 314 implants in 237 patients. Ann Plast Surg 2015;75(06):596–602
7 Lee KT, Mun GH. Prosthetic breast reconstruction in previously irradiated breasts: a meta-analysis. J Surg Oncol 2015;112(05): 468–475
8 Santanelli di Pompeo F, Laporta R, Sorotos M, Pagnoni M, Falesiedi F, Longo B. Latissimus dorsi flap for total autologous immediate breast reconstruction without implants. Plast Reconstr Surg 2014;134(06):871e–879e
9 Zhu L, Mohan AT, Vijayasekaran A, et al. Maximizing the volume of latissimus dorsi flap in autologous breast reconstruction with simultaneous multisite fat grafting. Aesthet Surg J 2016;36(02):169–178
10 Johns N, Fairbairn N, Trail M, et al. Autologous breast reconstruction using the immediately lipofilled extended latissimus dorsi flap. J Plast Reconstr Aesthet Surg 2018;71(02):201–208
11 Taminato M, Tomita K, Nomori M, et al. Fat-augmented latissimus dorsi myocutaneous flap for total breast reconstruction: a report of 54 consecutive Asian cases. J Plast Reconstr Aesthet Surg 2021; 74(06):1213–1222
12 Hokin JA. Mastectomy reconstruction without a prosthetic implant. Plast Reconstr Surg 1983;72(06):810–818
13 Cordeiro PG, Pusic AL, Disa JJ, McCormick B, VanZee K. Irradiation after immediate tissue expander/implant breast reconstruction: outcomes, complications, aesthetic results, and satisfaction among 156 patients. Plast Reconstr Surg 2004;113(03):877–881
14 Hirsch EM, Seth AK, Dumanian GA, et al. Outcomes of immediate tissue expander breast reconstruction followed by reconstruction of choice in the setting of postmastectomy radiation therapy. Ann Plast Surg 2014;72(03):274–278
15 Yoon AP, Qi J, Kim HM, et al. Patient-reported outcomes after irradiation of tissue expander versus permanent implant in breast reconstruction: a multicenter prospective study. Plast Reconstr Surg 2020;145(05):917e–926e
16 Nava MB, Pennati AE, Lozza L, Spano A, Zambetti M, Catanuto G. Outcome of different timings of radiotherapy in implant-based breast reconstructions. Plast Reconstr Surg 2011;128(02):353–359
17 Cordeiro PG, Albornoz CR, McCormick B, et al. What is the optimum timing of postmastectomy radiotherapy in two-stage prosthetic reconstruction: radiation to the tissue expander or permanent implant? Plast Reconstr Surg 2015;135(06):1509–1517
18 Gabriel SE, Woods JE, O'Fallon WM, Beard CM, Kurland LT, Melton LJ III. Complications leading to surgery after breast implantation. N Engl J Med 1997;336(10):677–682
19 Kühn S, Georgijewitsch MA, Wehle A, et al. Implant replacement or removal: what happens after capsular contracture? A German study examining breast implant revision surgery and patient choices in 946 cases. Breast Care (Basel) 2021;16(04):350–357
20 Berry T, Brooks S, Sydow N, et al. Complication rates of radiation on tissue expander and autologous tissue breast reconstruction. Ann Surg Oncol 2010;17(Suppl 3):202–210
21 Reinders FCJ, Young-Afat DA, Batenburg MCT, et al. Higher reconstruction failure and less patient-reported satisfaction after post mastectomy radiotherapy with immediate implant-based breast reconstruction compared to immediate autologous breast reconstruction. Breast Cancer 2020;27(03):435–444
22 Niddam J, Vidal L, Hersant B, Meningaud JP. Primary fat grafting to the pectoralis muscle during latissimus dorsi breast reconstruction. Plast Reconstr Surg Glob Open 2016;4(11):e1059
23 Ahmed YS, Abd El Maksoud WM, Sultan MH, El-Bakoury EA. Latissimus dorsi flap enhancement by lipofilling as an immediate breast reconstruction technique for skin-preserving mastectomy. Breast J 2021;27(03):222–230
24 Escandón JM, Escandón L, Ahmed A, et al. Breast reconstruction using the latissimus dorsi flap and immediate fat transfer (LIFT): a systematic review and meta-analysis. J Plast Reconstr Aesthet Surg 2022;75(11):4106–4116
25 Santanelli di Pompeo F, Sorotos M, Paolini G, D'Orsi G, Firmani G. The use of fat-augmented latissimus dorsi (FALD) flap for male Poland syndrome correction: a case report. Case Reports Plast Surg Hand Surg 2022;9(01):197–202
26 Couto-González I, Vila I, Brea-García B, et al. Safety of large-volume immediate fat grafting for latissimus dorsi-only breast reconstruction: results and related complications in 95 consecutive cases. Aesthetic Plast Surg 2021;45(01):64–75
27 Sorotos M, Paolini G, D'Orsi G, Firmani G, Timmermans FW, Santanelli di Pompeo F. Oncologic outcome of 1000 postmastectomy breast reconstructions with fat transfer: a single-center, matched case-control study. Plast Reconstr Surg 2022;150:4S–12S
28 Tukiama R, Vieira RAC, Moura ECR, et al. Oncologic safety of breast reconstruction with autologous fat grafting: a systematic review and meta-analysis. Eur J Surg Oncol 2022;48(04):727–735
29 Sorotos M, Paolini G, D'Orsi G, Firmani G, Santanelli di Pompeo F. Long-term clinical and aesthetic results of a systematic fat transfer protocol for total breast reconstruction after nipple-sparing mastectomy. Plast Reconstr Surg 2022;150(01):5–15
30 Homsy P, Höckerstedt A, Hukkinen K, Kauhanen S. Total breast reconstruction with lipofilling after traditional mastectomy without the use of tissue expanders. Plast Reconstr Surg 2023; 152(03):483–491
31 Hammond DC, O'Connor EA, Scheer JR. Total envelope fat grafting: a novel approach in breast reconstruction. Plast Reconstr Surg 2015;135(03):691–694
32 Groen JW, Negenborn VL, Twisk DJWR, et al. Autologous fat grafting in onco-plastic breast reconstruction: a systematic review on oncological and radiological safety, complications, volume retention and patient/surgeon satisfaction. J Plast Reconstr Aesthet Surg 2016;69(06):742–764
33 Nelissen X, Lhoest F, Preud'Homme L. refined method of lipofilling following DIEP breast reconstruction: 3D analysis of graft survival. Plast Reconstr Surg Glob Open 2015;3(09):e526
34 Wang XL, Liu LB, Song FM, Wang QY. Meta-analysis of the safety and factors contributing to complications of MS-TRAM, DIEP, and SIEA flaps for breast reconstruction. Aesthetic Plast Surg 2014;38 (04):681–691
35 Kao YM, Chen KT, Lee KC, Hsu CC, Chien YC. Pulmonary fat embolism following liposuction and fat grafting: a review of published cases. Healthcare (Basel) 2023;11(10):1391
36 Blondeel PN. One hundred free DIEP flap breast reconstructions: a personal experience. Br J Plast Surg 1999;52(02):104–111
37 Tallroth L, Velander P, Klasson S. A short-term comparison of expander prosthesis and DIEP flap in breast reconstructions: a prospective randomized study. J Plast Reconstr Aesthet Surg 2021;74(06):1193–1202

 © 2024. Association of Plastic Surgeons of India. All rights reserved.