



# Atypical May-Thurner Syndrome Caused by Large Lumbar Osteophyte

Nicholas Schaper<sup>1</sup> Keith Pereira<sup>2</sup>

<sup>1</sup> Saint Louis University School of Medicine, St. Louis, Missouri, United States

<sup>2</sup> Division of Vascular and Interventional Radiology, Saint Louis University, St. Louis, Missouri, United States

**Address for correspondence** Keith Pereira, MD, 1008 S Spring Ave St. Louis, MO 63110, United States  
(e-mail: keith.pereira@slucare.ssmhealth.com).

J Clin Interv Radiol ISVIR

## Abstract

An 82-year-old man presented to the emergency department with intermittent left lower extremity swelling for the last 4 to 5 months that limited his daily activities. The patient had a negative lower extremity venous duplex 3 months prior and had been treating symptoms with compression stockings but experienced no improvement. Venography showed venous outflow obstruction in his left common iliac vein and the etiology was confirmed to be a lumbar vertebral osteophyte compressing the vein. The patient underwent endovascular treatment with balloon venoplasty and stent placement over the lesion with return of adequate outflow. This report describes treatment of symptomatic left common iliac venous compression with endovascular therapy alone.

## Keywords

- ▶ May-Thurner
- ▶ endovascular treatment
- ▶ osteophyte

## Introduction

Compression of the iliac vein is a well-documented finding in the general population that is often asymptomatic affecting up to 24% of the general population, but in some cases, it can manifest as acute unilateral lower extremity swelling and pain.<sup>1,2</sup> This is known as May-Thurner syndrome (MTS) and affects women more often than men and disproportionately presents on the left side.<sup>1</sup> The etiology of MTS has been pondered since its first report in 1957 classically presenting as the compression of the left common iliac vein (LCIV) between the right common iliac artery (RCIA) and the spine.<sup>1</sup> This interaction is thought to cause spurs in the vein thus predisposing a patient to the development of deep venous thrombosis (DVT).<sup>1,3</sup> Atypical presentation of MTS has also been reported as anatomical variants such as right-sided MTS, LCIV compression by the left internal iliac artery, and distal inferior vena cava (IVC) compression by the RCIA and

compose roughly 5.8% of patients with symptomatic MTS.<sup>3</sup> Another anatomical variant of MTS that is seldom reported is MTS due to degenerative vertebral osteophytes causing posterior pressure to compress the LCIV against the overlying RCIA.<sup>4,5</sup> This case report is of a patient with symptomatic LCIV compression caused by an anterior projecting lumbar osteophyte.

## Case Presentation

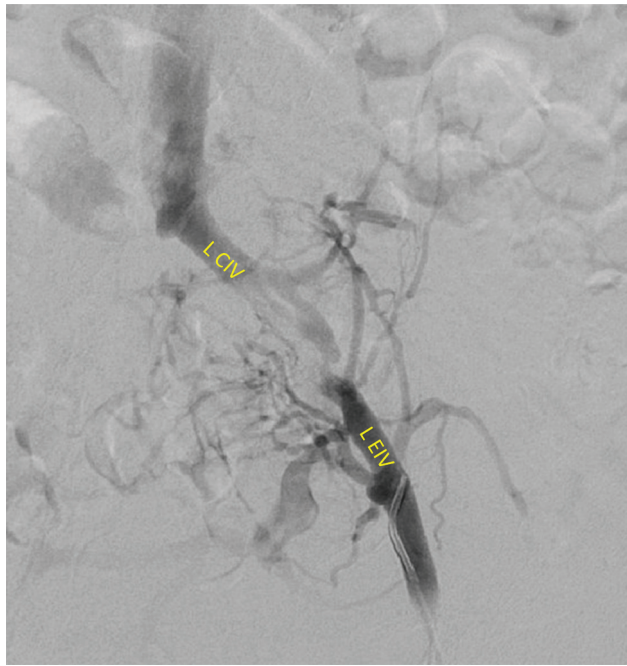
An 82-year-old male with past medical history relevant for congestive heart disease, hypertension, type 2 diabetes, and peripheral vascular disease presented to the emergency department with intermittent left lower extremity swelling for the last 4 to 5 months. Patient has been limited in daily activities and restricted from walking more than 50 feet at a time secondary to pain. Patient has isolated femur fracture 2 years prior to presentation. Patient reports treating

DOI <https://doi.org/10.1055/s-0044-1779256>.  
ISSN 2457-0214.

© 2024. Indian Society of Vascular and Interventional Radiology. All rights reserved.

This is an open access article published by Thieme under the terms of the Creative Commons Attribution-NonDerivative-NonCommercial-License, permitting copying and reproduction so long as the original work is given appropriate credit. Contents may not be used for commercial purposes, or adapted, remixed, transformed or built upon. (<https://creativecommons.org/licenses/by-nc-nd/4.0/>)

Thieme Medical and Scientific Publishers Pvt. Ltd., A-12, 2nd Floor, Sector 2, Noida-201301 UP, India



**Fig. 1** Venography from left femoral access illustrating poor venous flow through left the external iliac vein (LEIV) and significant collateral formation around the stenosis into the left common iliac vein (LCIV).

symptoms with compression stockings with minimal relief. Patient had negative left lower extremity venous duplex ultrasound 3 months prior to presentation but given clinical suspicion, underwent Interventional Radiology (IR) venography that disclosed focal stenosis of the distal LCIV from approximately 80 to 90%, likely to be chronic in nature without acute clot burden (►**Fig. 1**). Additionally, at this visit a computed tomography scan was performed that was significant for osteophyte formation distal to the bifurcation of the aorta and immediately posterior to a distal segment of the common iliac vein (►**Fig. 2**). The patient was not a candidate for surgical removal of the osteophytic lesion.

Almost 2 weeks after this evaluation, the patient underwent endovascular treatment of the stenotic portion of the common iliac vein using balloon venoplasty with a 12 mm

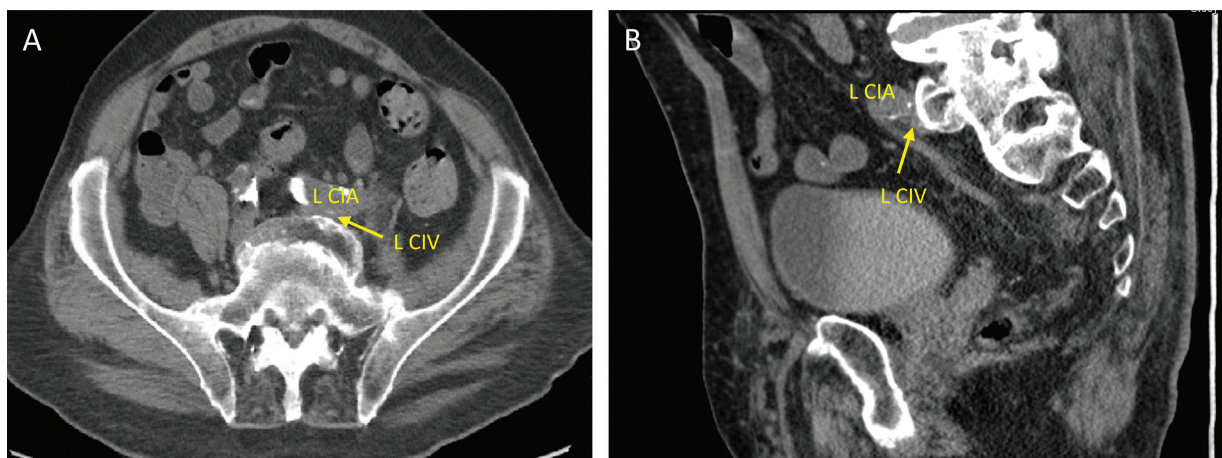
balloon followed by the placement of a 14 × 100 mm stent (Abre Stent, Medtronic Inc, Minneapolis, MN, USA) within the stenotic region. Postprocedure venography and intravascular ultrasound identified improved venous flow and no significant remaining stenosis (►**Fig. 3**). The patient was treated as an outpatient and discharged to home 4 hours following his procedure.

## Discussion

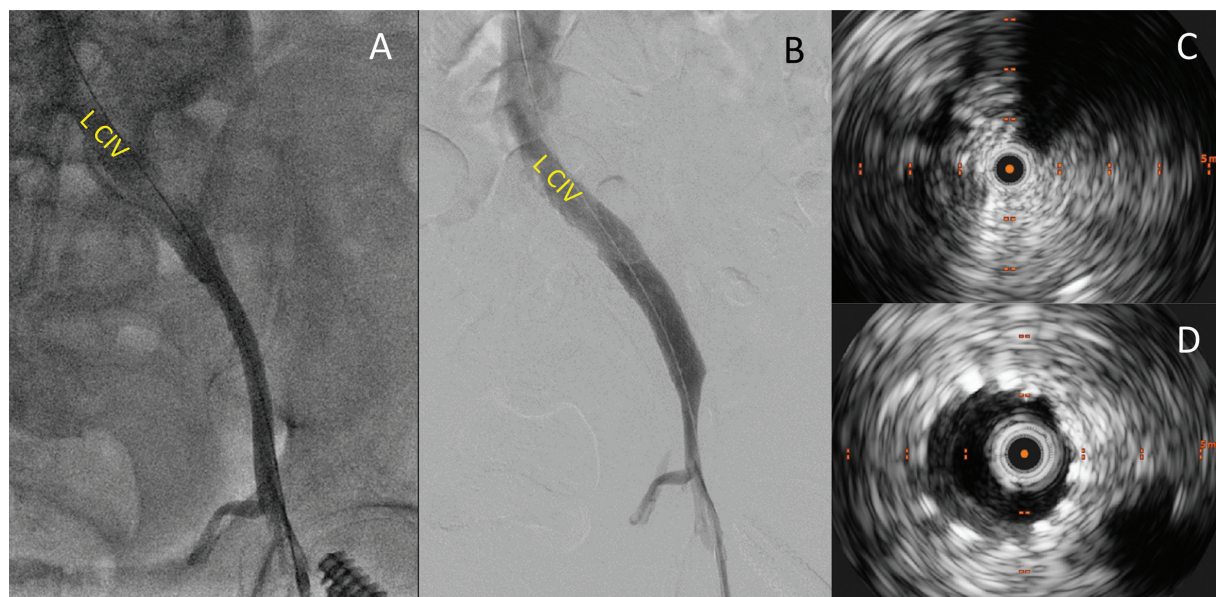
Osteophytes frequently cause radiculopathy when present in other areas of the cervical, thoracic, and lumbar spine.<sup>4</sup> The prevalence of vascular compression due to osteophytic outgrowth is commonly reported in the literature with reports of femoral and abdominal aortic compression and even aortic pseudoaneurysm due to osteophytes.<sup>6–8</sup> This presentation is more likely to occur in an older population due to the time it takes for these osteophytes to reach clinically significant size. Patients with DVT and MTS routinely require endovascular stenting as the standard of care due to the high risk of recurrence.<sup>5,9</sup>

MTS caused by bony anomalies such as osteophytes may consist of surgical removal of the underlying osteophyte, if feasible, followed by endovascular venoplasty and stenting of the vein to prevent recurrent symptomatic compression. The concern with primary endovascular treatment is that this may result in premature stent failure due to excessive extrinsic compression; hence, endovascular treatment is only reserved for patients who are not surgical candidates or surgical excision of the bony osteophyte is not possible. In these cases, endovascular treatment may require the use of stents with higher radial force.<sup>5</sup>

Our patient experienced improvement in symptoms of venous obstruction solely with endovascular treatment, in the absence of surgical options. Recent advancement in venous stent technology and availability of multiple dedicated venous stents with improved radial strength have now made it possible for endovascular options for patients like ours.<sup>10</sup> This case reminds us that MTS can result from various etiologies and vertebral osteophytes should be considered in



**Fig. 2** Transverse (A) and sagittal (B) abdominal computed tomography scan showing an osteophytic growth immediately posterior to the distal left common iliac vein (LCIV) compressing it against the left common iliac artery (LCIA).



**Fig. 3** Intraoperative venography following (A) balloon venoplasty and (B) stent placement. (C) Preprocedure intravascular ultrasound (IVUS) showing severe stenosis of left common iliac vein (LCIV). (D) Postprocedure IVUS showing appropriately sized lumen of LCIV.

patients with long-standing venous symptoms or recurrent DVTs. These should especially be considered in older populations or those with known history of osteoarthritis.

#### Conflict of Interest

None declared.

#### References

- 1 Radaideh Q, Patel NM, Shammam NW. Iliac vein compression: epidemiology, diagnosis and treatment. *Vasc Health Risk Manag* 2019;15:115–122
- 2 Kibbe MR, Ujiki M, Goodwin AL, Eskandari M, Yao J, Matsumura J. Iliac vein compression in an asymptomatic patient population. *J Vasc Surg* 2004;39(05):937–943
- 3 Park JY, Park KM, Cho SG, Hong KC, Jeon YS. Atypical iliac vein compression in patients with symptomatic May-Thurner syndrome. *Diagn Interv Radiol* 2021;27(03):372–377
- 4 Wasserburger J, Haponyuk A, Modhia UM, Langsfeld M, Paterson AJ, Rana MA. Lumbosacral exostosis as a rare cause of iliac vein compression and significant limb swelling. *J Vasc Surg Cases Innov Tech* 2019;5(04):529–531
- 5 Shin D, Mokkarala M, Allison S, Monroe E. Osteophytic iliac venous compression: technical considerations for a bony May-Thurner syndrome variant. *J Clin Interventional Radiol* 2018;2(02):95–100
- 6 Pinkerton GE. Thrombosis of the abdominal aorta apparently caused by pressure from a vertebral osteophyte. *Lancet* 1948;2(6534):811
- 7 Takasago T, Goto T, Tsutsui T, et al. A huge capital drop with compression of femoral vessels associated with hip osteoarthritis. *Case Rep Orthop* 2015;2015:709608
- 8 Dregelid E, Jenssen G, Jonung T, Braaten A. Pseudoaneurysm of the abdominal aorta due to a needle-like osteophyte on the first lumbar vertebra. *J Vasc Surg* 2007;45(05):1059–1061
- 9 Hng J, Su S, Atkinson N. May-Thurner syndrome, a diagnosis to consider in young males with no risk factors: a case report and review of the literature. *J Med Case Rep* 2021;15(01):141
- 10 Shamimi-Noori SM, Clark TWI. Venous stents: current status and future directions. *Tech Vasc Interv Radiol* 2018;21(02):113–116