



# The T1 Ratio of Marrow (TROM) as a Novel Tool to Identify Metastatic from Nonmalignant Marrow Lesions of the Spine: A Pilot Study

Neha Nischal<sup>1</sup> Mahtab Afzali<sup>2</sup> Parham Shojaie<sup>2</sup> Christine Azzopardi<sup>1</sup> Karthikeyan P. Iyengar<sup>3</sup> Shahnawaz Haleem<sup>4</sup> Jonathan Daniel Stevenson<sup>5</sup> Rajesh Botchu<sup>1</sup>

<sup>1</sup>Department of Musculoskeletal Radiology, Royal Orthopedic Hospital, Birmingham, United Kingdom

<sup>2</sup>Aston Medical School, Aston University, Birmingham, United Kingdom

<sup>3</sup>Department of Orthopedics, Southport and Ormskirk Hospital, Southport, United Kingdom

<sup>4</sup>Department of Spine Surgery, Royal Orthopedic Hospital, Birmingham, United Kingdom

<sup>5</sup>Department of Orthopedic Oncology, Royal Orthopedic Hospital, Birmingham, United Kingdom

Address for correspondence Neha Nischal, MBBS, MD, Royal Orthopedic Hospital, Bristol Road South, Northfield, Birmingham, United Kingdom (e-mail: neha.nischal@gmail.com).

Indian J Radiol Imaging 2023;33:450–455.

## Abstract

**Objective** The purpose of this study was to analyze quantitative values of normal and abnormal marrow on T1-weighted images of spine, to propose a ratio for T1 values of abnormal to normal vertebrae, and to assess whether this ratio could be helpful in predicting presence of neoplastic lesions in the spine.

**Materials and Methods** One-hundred randomly selected magnetic resonance imagings of lumbar spine without infection, fracture, and tumor were selected to form normal cohort. A second cohort of 100 metastasis of lumbar spine was identified. Ratio of T1 value of vertebral body to the T1 value of the inferior vertebral body was performed for normal cohort from D11 to L5. Ratio of T1 value of metastasis to adjacent normal vertebral body was done for metastatic cohort. Data was analyzed using standard *t*-test and kappa was performed for intra- and inter-observer reliability.

**Results** A decline in T1 value of abnormal to normal marrow was seen in patients with metastasis that was statistically significant. We call this the T1 ratio of marrow (TROM). The sensitivity and accuracy with the cutoff value of TROM at 0.7 (92% sensitivity, 97.1% accuracy) are better than at 0.6 (75% sensitivity, 96.2% accuracy) or 0.5 (47% sensitivity, 93.2% accuracy). A subset analysis of the other T1 hypointense benign lesions including atypical hemangiomas and focal marrow hyperplasia, however, revealed overlapping TROM values with the metastatic cohort.

**Conclusion** Using the TROM on T1-weighted images could not confidently differentiate malignant from benign T1 hypointense lesions of the spine.

## Keywords

- ▶ T1 ratio
- ▶ magnetic resonance imaging
- ▶ metastasis
- ▶ spine

article published online  
May 2, 2023

DOI <https://doi.org/10.1055/s-0043-57255>.  
ISSN 0971-3026.

© 2023. Indian Radiological Association. All rights reserved.  
This is an open access article published by Thieme under the terms of the Creative Commons Attribution-NonDerivative-NonCommercial-License, permitting copying and reproduction so long as the original work is given appropriate credit. Contents may not be used for commercial purposes, or adapted, remixed, transformed or built upon. (<https://creativecommons.org/licenses/by-nc-nd/4.0/>)  
Thieme Medical and Scientific Publishers Pvt. Ltd., A-12, 2nd Floor, Sector 2, Noida-201301 UP, India

## Introduction

Bone marrow is a large organ with a complex cellular structure. It is best analyzed by magnetic resonance imaging (MRI) using T1-weighted sequences.<sup>1-4</sup> Physiological changes of marrow with conversion of red marrow into fatty marrow occur in sequential manner with age. Normal red marrow contains about 40% fat and 60% hematopoietic marrow, whereas fatty marrow has a fatty predominance composed of 95% adipocytes and 5% nonfat cells.<sup>5-7</sup> The signal of fatty marrow is thus high on T1-weighted images in comparison to skeletal muscle. In marrow infiltrative disorder, there is replacement of fat by tumor accounting for the low signal in comparison to skeletal muscle. It is a well-recognized concept to compare the marrow or lesion with adjacent skeletal muscle or disc to help diagnose abnormalities.<sup>1,6-8</sup>

A spectrum of MR techniques has been used in analysis of indeterminate marrow lesions that include short tau inversion recovery (STIR), diffusion-weighted imaging (DWI), chemical shift imaging, contrast (static and dynamic) as well as computed tomography (CT), positron emission tomography-computed tomography, single-photon emission computed tomography-computed tomography and positron emission tomography-magnetic resonance.<sup>1-4,6,7,9-12</sup> A meta-analysis by Liu et al reiterated that MRI is the best modality for detection of vertebral metastasis.<sup>13</sup>

However, at many centers only T1- and T2- weighted images of the spine in sagittal and axial planes are obtained. This may lead to lesions being inconspicuous. Although to an experienced radiologist, lesion detection might be easier, it may get slightly tricky for the someone with less experience. Also, in equivocal cases, the patient may have to be recalled to obtain additional sequences.

We thus performed a retrospective study to quantitatively assess the T1 values in normal and abnormal (metastatic) marrow lesions of lumbar spine. Unlike CT, where the machine is calibrated resulting in standard values for various structures, MRI being uncalibrated can result in different T1 values for the same region of interest in the same patient on different machines, different magnetic strength, different Picture Archiving and Communication System (PACS) monitors, and even different episodes of imaging the same area on the same scanner. For this reason, instead of measuring absolute T1 values, we considered calculating ratios of the T1 values of adjacent vertebral bodies. Anecdotally, we found that the relative T1 values of a structure on MRI were comparable to adjacent structure. For instance, the T1 value of vertebral body of L2 is comparable to L1 and L3.

## Materials and Methods

Local ethical committee approval was obtained for the study. One-hundred randomly selected MRI of the lumbar spine without any evidence of infection, fracture, and tumor were selected from a cohort. This was done in way to have an even spread across different age ranges. These included MRI performed on both 1.5T and 3T Seimens (Skyra and Sola; Erlangen, Germany). This normal cohort included normal

marrow, focal marrow hyperplasia, and typical as well as atypical hemangiomas. A second cohort of 100 metastasis of lumbar spine was identified. Patients with a history of spinal surgery or with metallic implants were excluded from both cohorts.

On a GE PACS monitor, the T1 values of center of vertebral body from T11 to L5 were calculated for normal cohorts on mid-sagittal image by keeping similar sized circular regions of interest with average size 0.8 to 1 cm<sup>2</sup>. The ratio of T1 value of vertebral body to the T1 value of the inferior vertebral body was performed for normal cohort (700 vertebrae). Ratio of T1 value of metastasis to adjacent normal vertebral body was done for metastatic cohort. We named this ratio of T1 value as T1 ratio of Marrow (TROM).

T1 values and TROM were calculated by two readers anonymously with one reader repeating the measurements after a period of 2 weeks to assess intraobserver reliability. Demographics, that is, age, sex, and level of metastatic deposit, were recorded in excel sheet. Descriptive statistics for both cohorts were performed. Data was analyzed using standard *t*-test and the weighted Cohen's kappa was calculated for intra- and interobserver reliability.

## Results

The normal cohort had an average age of 41.8 years (range: 6–100 years) and the metastatic cohort had an average age of 61.8 years (range: 9–87 years; ► **Table 1**).

We found a statistically significant decrease in the TROM of metastasis in comparison to the normal vertebra. The mean TROM for the normal cohort (► **Fig. 1**) was found to be 0.99 (95% confidence interval [CI]: 0.9831–1.0074) and for metastasis (► **Fig. 2**) it was found to be 0.5 (95% CI: 0.4732–0.5171).

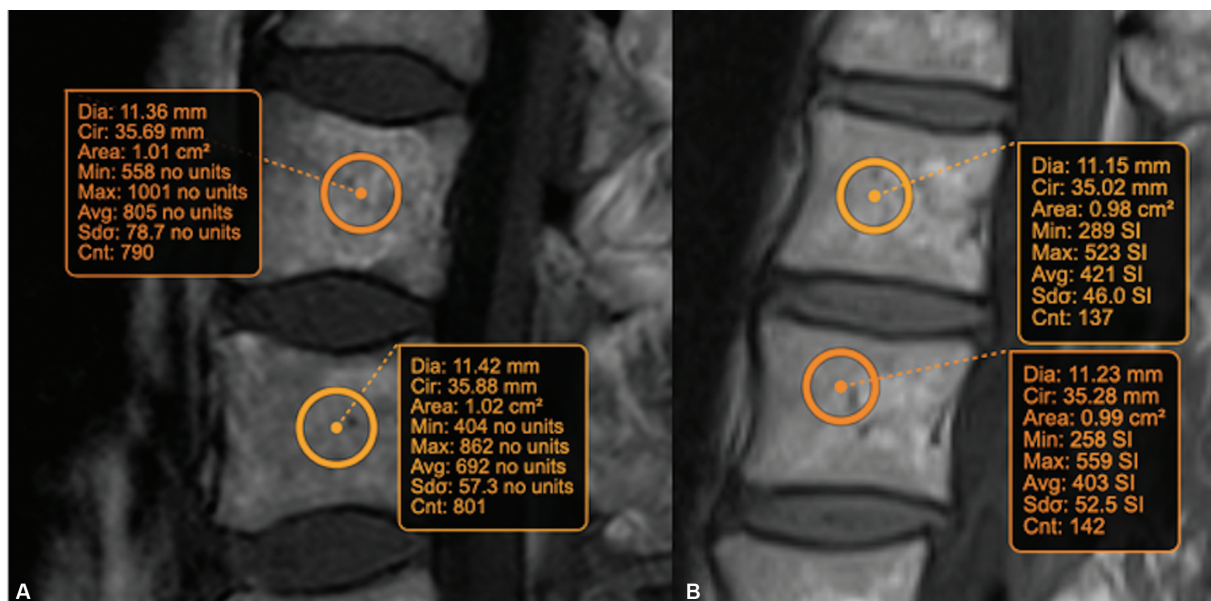
We performed a *t*-test to assess if a decline in T1 value can be used to differentiate the two cohorts. The extent of T1 value drop off was proportional to degree of confidence of identifying tumor as shown with cutoff value 0.5, 0.6, and 0.7 (*p* = 0.0001).

When 0.7 was used as the cutoff value, more metastatic lesions were identified indicating higher sensitivity. However, few normal vertebrae/ benign lesions were also classified

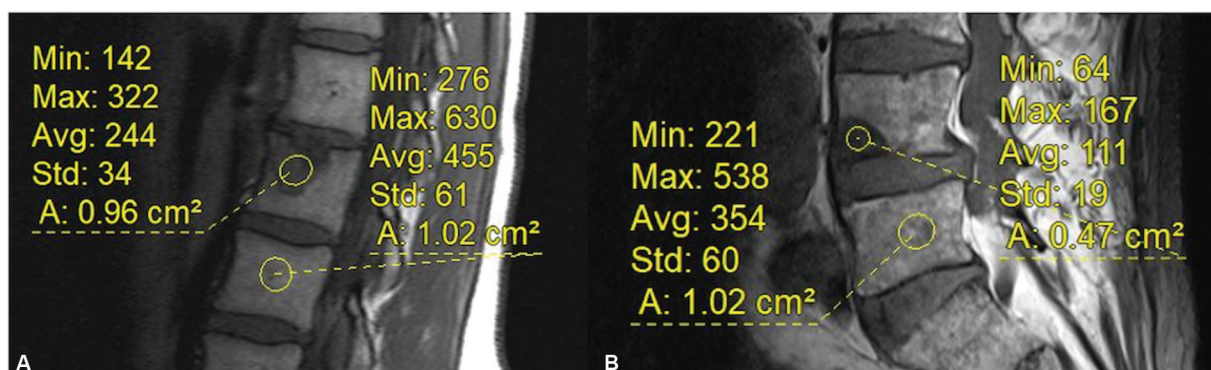
**Table 1** Demographics of normal and metastasis cohort

	Normal	Metastasis
Average age (y)	41.8	61.80
Maximum age (y)	100	87
Minimum age (y)	6	9
Male	43	39
Female	57	61
Mean TROM	0.99	0.54
SD	0.15	0.2
SEM	0.01	0.02

Abbreviations: SD, standard deviation; SEM, standard error of mean; TROM, T1 ratio of marrow.



**Fig. 1** Sagittal T1-weighted images from the normal cohort showing calculation of T1 ratio of marrow (TROM) at L2/L3 level. TROM in patient (A) is  $805/692 = 1.16$  and that in patient (B) is  $421/403 = 1.04$ .



**Fig. 2** Sagittal T1-weighted images from the metastatic cohort showing calculation of T1 ratio of marrow of the metastasis/ normal marrow in two different patients. The ratio in part (A) is 0.53 and in part (B) is 0.31.

**Table 2** Comparative statistical analysis for varying cutoffs of TROM

Statistic	0.7		0.6		0.5	
	Value	95% CI	Value	95% CI	Value	95% CI
Sensitivity	92.00%	84.84–96.48%	75.00%	65.34–83.12%	47.00%	36.94–57.24%
Specificity	97.86%	96.49–98.80%	99.29%	98.34–99.77%	99.86%	99.21–100.00%
PPV <sup>a</sup>	85.98%	78.75–91.03%	93.75%	86.14–97.31%	97.92%	86.77–99.70%
NPV <sup>a</sup>	98.85%	97.78–99.40%	96.53%	95.19–97.50%	92.95%	91.64–94.07%
Accuracy <sup>a</sup>	97.12%	95.72–98.17%	96.25%	94.69–97.46%	93.25%	91.28–94.89%

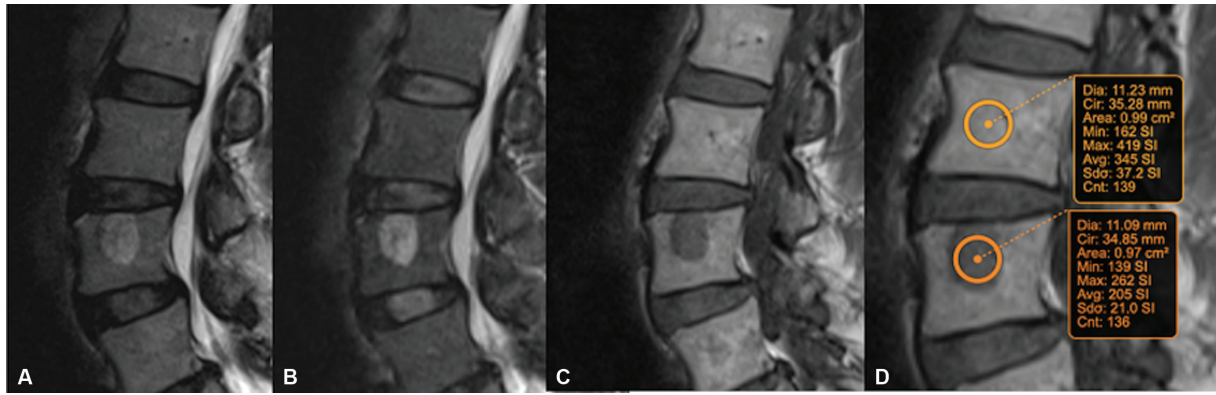
Abbreviations: CI, confidence interval; NPV, negative predictive value; PPV, positive predictive value; TROM, T1 ratio of marrow.

<sup>a</sup>These values are dependent on disease prevalence.

as metastatic (false positives). The sensitivity, specificity, and accuracy with this cutoff value were 92, 97.8, and 97.1%, respectively. With the cutoff value of 0.6, the false positives decreased along with decrease in the sensitivity of metastatic lesion detection. The sensitivity, specificity, and accuracy with this cutoff value was 75, 99.2, and 96.2%, respectively.

The sensitivity, specificity, and accuracy with cutoff value at 0.5 was 47, 99.8, and 93.2%, respectively (**►Table 2**).

The normal cohort had seven cases of atypical hemangiomas (**►Fig. 3**) and six cases of focal marrow hyperplasia. A subset analysis of these benign T1 hypointense lesions showed variable TROM values ranging from 0.8 to 0.4 that



**Fig. 3** Sagittal T2-weighted (A), short tau inversion recovery (B), and T1-weighted (C, D) images from the normal cohort with an atypical hemangioma in L3 vertebral body. The lesion is bright on the fluid-sensitive sequences (A, B) and mildly hypointense on T1-weighted imaging (C). (D) Calculation of T1 ratio of marrow of the atypical hemangioma/ normal marrow. The ratio is  $205/354 = 0.6$

significantly overlapped with the values of metastatic lesions.

This showed substantial agreement between the two readers with kappa value of 0.69. The intrarater reliability was excellent with a kappa value of 0.89.

## Discussion

There has been a lot of research on MRI of the marrow with an aim to differentiate normal or benign changes from the more sinister pathologies. This is pertinent to patient management in order to avoid unnecessary intervention and anxiety. The focus has been on identifying the morphological characteristics and using newer sequences.<sup>2-4,6,7,9,10,14,15</sup> To our knowledge, a quantitative assessment for the same using T1-weighted images has not yet been made and we proposed the TROM as a simple tool that could be applied to the basic T1-weighted sequence to increase the diagnostic confidence.

STIR sequence suppresses the signal from fat that increases sensitivity of lesion detection, but this is nonspecific and may overestimate or underestimate the extent of the lesion.<sup>2</sup> While DWI has shown to be promising in differentiating metastatic from normal or osteoporotic marrow,<sup>3,15</sup> it is not a routinely used sequence and the image quality may not be satisfactory on all scanners. DWI also has many caveats and should be never interpreted in isolation.<sup>2</sup> In fact, it may offer no added advantage to routine T1, T2-weighted sequences.<sup>9</sup>

The utility of chemical shift imaging to differentiate benign versus malignant lesions of the spine has been researched extensively and is an established problem-solving tool in majority of the cases.<sup>16-19</sup> Disler et al initially studied the relative signal intensity ratios on the in-phase and opposed phase images and proposed a cut-off value of 0.81 as being highly specific and sensitive for detecting tumors. They measured the signal intensities of lesions in the opposed as well as in-phase images and compared them with control tissues that contained little or no fat. These ratios were then divided (opposed-phase ratio divided by in-phase ratio) and the mean was found to be 1.03 versus 0.61 for neoplastic and non-neoplastic lesions, respectively. Our

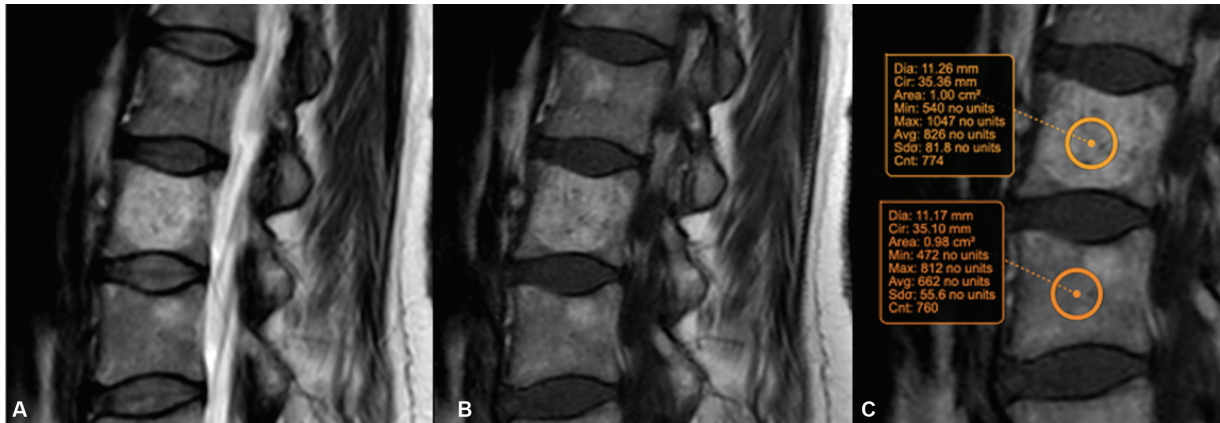
concept of TROM is similar to this except for the fact that instead of using two sets of images, we calculate the ratio on the T1-weighted sequence and use the adjacent normal appearing marrow as the reference making it simpler and less time consuming.

While some researchers have reported that CT attenuation of hyperplastic marrow is higher than normal marrow and that CT may be able to differentiate it from metastatic lesions,<sup>3</sup> it does entail exposure to radiation and repeated CT examinations are best avoided for this reason.

Despite a myriad of MRI sequences being available, a confident characterization of focal vertebral signal abnormality can be challenging. Islands or focal nodular hyperplasia of red marrow and atypical hemangiomas appear hypointense on T1-weighted imaging and hyperintense on fat suppressed T2-weighted imaging or STIR sequences. The intensity of these benign entities is, however, still usually higher than adjacent muscle.<sup>1,2,20</sup> In other words, the normal marrow of adjacent vertebral bodies showed less than 10% variation in the signal intensity on T1-weighted images. In cases of typical hemangiomas, the TROM values were as high as 2, in accordance with the high T1 signal intensity (→ Fig. 4). We had proposed that TROM could possibly correctly identify the benign lesions with low T1 signal intensity from the malignant ones. However, this did not hold true as there was an overlap of TROM values of these lesions with malignant ones.

In contrast, the metastatic lesions showed a TROM of less than 0.5 with excellent interobserver reliability. In other words, these lesions show more than 50% reduction in the T1 signal intensity. Although our cohort consisted of metastatic lesions only, we believe that similar results may apply to other marrow infiltrative disorders. As for conditions causing diffuse marrow signal alterations, such as osteoporosis, although the T1 values may be altered when compared to age-matched controls, the TROM would not vary greatly (10% variation) within the adjacent vertebral bodies. Primary marrow malignancies have not been studied at present but could be expected to show similarly reduced TROM values.

The added advantage of using this ratio is that no other special sequences, and thereby time, are added to the routine



**Fig. 4** Sagittal T2- (A) and T1-weighted (B, C) images from the normal cohort with a typical hemangioma in L3 vertebral body showing calculation of T1 ratio of marrow of the hemangioma/ normal marrow. The ratio is  $826/662 = 1.24$ .

protocol. Calculating TROM is easy, quick, and can be performed on all PACS monitors and DICOM viewing platforms. Although we found an overlap in some cases, an extrapolation to other regions of the body and further larger studies may confidently approve or refute the utility of this technique.

### Limitation

This is a single-center study that is limited by the small number of patients. The ratio could not distinguish a few atypical hemangiomas and focal marrow hyperplasia from metastasis and we suggest incorporating other sequences like in and opposed phase imaging in cases where this is a clinical and imaging concern. We have also not tried to identify the type of primary malignancy in these patients to assess if the ratios differ in different types of malignancies. Since infections were excluded from the study, we believe TROM itself cannot differentiate infection from malignancy and requires assessment of other clinicroadiological findings for this purpose. The metastatic lesions in our study were lytic in nature and did not have any case of blastic metastasis. We believe that osteoblastic metastasis does not pose a diagnostic problem owing to their characteristic imaging appearance.

### Conclusion

The TROM is derived from a simple but established concept of marrow replacement and consequent decrease in the T1 signal intensity by tumor cells.

Going further, these standardized measurements may also lead to the development of artificial intelligence tools that can red flag the suspicious vertebral bodies with reduced TROM for a second look and detailed assessment by the radiologist. Further research may also prove effectiveness of using this in treatment response assessment.

**Funding**  
None.

**Conflict of Interest**  
None declared.

### References

- Vanel D. MRI of bone metastases: the choice of the sequence. *Cancer Imaging* 2004;4(01):30–35
- Patel A, James SL, Davies AM, Botchu R. Spinal imaging update: an introduction to techniques for advanced MRI. *Bone Joint J* 2015; 97-B(12):1683–1692
- Shigematsu Y, Hirai T, Kawanaka K, et al. Distinguishing imaging features between spinal hyperplastic hematopoietic bone marrow and bone metastasis. *Am J Neuroradiol* 2014;35(10): 2013–2020
- Meyer JS, Siegel MJ, Farooqui SO, Jaramillo D, Fletcher BD, Hoffer FA. Which MRI sequence of the spine best reveals bone-marrow metastases of neuroblastoma? *Pediatr Radiol* 2005;35(08): 778–785
- Małkiewicz A, Dziedzic M. Bone marrow reconversion-imaging of physiological changes in bone marrow [Internet]. Accessed April 5, 2023 at: <http://www.polradiol.com/fulltxt.php?ICID=883628>
- Hwang S, Panicek DM. Magnetic resonance imaging of bone marrow in oncology, Part 1. *Skeletal Radiol* 2007;36(10):913–920
- Vanel D, Dromain C, Tardivon A. MRI of bone marrow disorders. *Eur Radiol* 2000;10(02):224–229
- Zhao J, Krug R, Xu D, Lu Y, Link TM. MRI of the spine: image quality and normal-neoplastic bone marrow contrast at 3 T versus 1.5 T. *AJR Am J Roentgenol* 2009;192(04):873–880
- Castillo M, Arbelaez A, Smith JK, Fisher LL. Diffusion-weighted MR imaging offers no advantage over routine noncontrast MR imaging in the detection of vertebral metastases. *Am J Neuroradiol* 2000;21(05):948–953
- Hanrahan CJ, Shah LM. MRI of spinal bone marrow: part 2, T1-weighted imaging-based differential diagnosis. *Am J Roentgenol* 2011;197(06):1309–1321
- Heusner T, Göllitz P, Hamami M, et al. “One-stop-shop” staging: should we prefer FDG-PET/CT or MRI for the detection of bone metastases? *Eur J Radiol* 2011;78(03):430–435
- Grankvist J, Fisker R, Iyer V, et al. MRI and PET/CT of patients with bone metastases from breast carcinoma. *Eur J Radiol* 2012;81(01):e13–e18
- Liu T, Wang S, Liu H, et al. Detection of vertebral metastases: a meta-analysis comparing MRI, CT, PET, BS and BS with SPECT. *J Cancer Res Clin Oncol* 2017;143(03):457–465
- Hanna SL, Fletcher BD, Fairclough DL, Jenkins JH III, Le AH. Magnetic resonance imaging of disseminated bone marrow

- disease in patients treated for malignancy. *Skeletal Radiol* 1991; 20(02):79–84
- 15 Herneth AM, Philipp MO, Naude J, et al. Vertebral metastases: assessment with apparent diffusion coefficient. *Radiology* 2002; 225(03):889–894
- 16 Disler DG, McCauley TR, Ratner LM, Kesack CD, Cooper JA. In-phase and out-of-phase MR imaging of bone marrow: prediction of neoplasia based on the detection of coexistent fat and water. *Am J Roentgenol* 1997;169(05):1439–1447
- 17 Zajick DC Jr, Morrison WB, Schweitzer ME, Parellada JA, Carrino JA. Benign and malignant processes: normal values and differentiation with chemical shift MR imaging in vertebral marrow. *Radiology* 2005;237(02):590–596
- 18 Eito K, Waka S, Naoko N, Makoto A, Atsuko H. Vertebral neoplastic compression fractures: assessment by dual-phase chemical shift imaging. *J Magn Reson Imaging* 2004;20(06): 1020–1024
- 19 Erly WK, Oh ES, Outwater EK. The utility of in-phase/opposed-phase imaging in differentiating malignancy from acute benign compression fractures of the spine. *Am J Neuroradiol* 2006;27 (06):1183–1188
- 20 Vande Berg BC, Lecouvet FE, Galant C, Maldague BE, Malghem J. Normal variants and frequent marrow alterations that simulate bone marrow lesions at MR imaging. *Radiol Clin North Am* 2005; 43(04):761–770, ix