Article published online: 2023-06-26

Hypertrophic Obstructive Cardiomyopathy Associated with Moderate Aortic Stenosis in Symptomatic 75-Year-Old Female: A Case Report

Abdulgani Abonowara[1]

[1] Department of General and Interventional Cardiology, McMaster University, Niagara Health/SCG Hospital, St. Catharines, Ontario, Canada

Libyan Int Medical Univ J 2023;8:8–11.

Address for correspondence Abdulgani Abonowara, MD, FRCPC, FACC, Department of General and Interventional Cardiology, McMaster University, Niagara Health/SCG Hospital, St. Catharines, ON L2N 6N5, Canada (e-mail: abonowaraa@gmail.com).

Abstract

A 72-year-old female was found to have symptomatic hypertrophic obstructive cardiomyopathy associated with significant aortic stenosis. She was found to have severe left ventricular outflow tract obstruction, asymmetric septal hypertrophy, significant systolic anterior motion of the anterior mitral valve leaflet, and mitral regurgitation. She was also found to have moderate aortic stenosis that made the obstruction even worse which made the patient progressively symptomatic not responding to medical therapy. She eventually underwent cardiac surgery in form of left ventricular septal myomectomy and bioprosthetic aortic valve replacement (tissue AVR) with a size 23 tissue valve, aortic root enlargement with bovine pericardial patch. She is currently stable on optimal medical therapy, feels much better and stable cardiac-wise with much better quality of life.

Keywords

- hypertrophic obstructive cardiomyopathy
- aortic stenosis
- asymmetric left ventricular hypertrophy
- septal myomectomy
- aortic valve replacement

Introduction

Hypertrophic cardiomyopathy (HCM) is a genetic disorder that is characterized by left ventricular hypertrophy (LVH) unexplained by secondary causes and a nondilated left ventricle with preserved or increased ejection fraction (EF). The basal interventricular septum is common finding, usually asymmetrical with severe septal hypertrophy.[1]

Aortic stenosis is the narrowing of the aortic valve that affects the amount of blood ejected from the left ventricle, typically gets worse over time from mild-to-moderate to severe stage.[2]

This case is unique as it is uncommon to find hypertrophic obstructive cardiomyopathy (HOCM) and aortic stenosis at the same time as this can be potentially very serious and carries high risk due the significant double obstruction that occurs at the level of left ventricular outflow tract (LVOT) and aortic valve at the same time. This also carries a therapeutic challenge due to the progressive nature of these conditions.

In addition, HCOM is typically associated with significant LVOT obstruction, asymmetric septal hypertrophy (ASH), and significant systolic anterior motion (SAM).

It is often caused by sarcomeric mutations resulting in LVH, fibrosis, hypercontractility, and reduced compliance. It is affecting approximately 0.2% of the population.[3]

As HOCM is the most common hereditary disease of the heart, genetic testing and family screening is said to be important to get more information that enables accurate assessment of disease risk in family members.[4] Here, we are reporting a rare case of symptomatic hypertrophic obstructive cardiomyopathy associated with significant aortic stenosis and its management.

Description of the Case Report

A 72-year-old female was found to have symptomatic hypertrophic obstructive cardiomyopathy (HOCM) associated with significant aortic stenosis. She was found to have severe left

article published online
June 26, 2023

DOI https://doi.org/10.1055/s-0043-57016.
ISSN 2519-139X.

ملخص المقال باللغة العربية

اعتلال عضلة القلب الضخامي الانسدادي المتزامنة مع تضيق الأبهر المعتدل لدى سيدة تبلغ من العمر 75 عاماً - تقرير حالة

المؤلف:
عبد الغني أبونواره، جامعة ماكماستر، أونتاريو – كندا ، البريد الإلكتروني- abonowaraa@gmail.com

تم تشخيص حالة مرضية لسيدة تبلغ من العمر 72 عاماً مصابة بأعراض تضخم عضلة القلب الانسدادي (HOCM) المتزامن مع تضيق الأبهر. وُجد أنها تعاني من انسداد شديد في مجرى تدفق البطين الأيسر (LVOT)، وتضخم البطين الأيسر غير المتماثل (ALVH) وحركة أمامية انقباضية كبيرة لوريقة الصمام المترالي الأمامي (SAM)، كما كانت تعاني من ارتجاع الصمام المترالي. وكانت المريضة تعاني كذلك من تضيق معتدل في الأبهر مما جعل الانسداد أسوأ وجعل المريضة تعاني تدريجياً من أعراض لا تستجيب للعلاج الطبي. خضعت المريضة في النهاية لعملية جراحية في القلب في شكل استئصال الحاجز العضلي للبطين الأيسر واستبدال الصمام الأبهري (Tissue AVR) بصمام نسيجي بحجم 23، وتكبير جذر الشريان الأبهري برقعة من التامور البقري. وتعتبر حالة المريضة الآن مستقرة مع العلاج الطبي الأمثل، وتشعر بتحسن كبير مع نوعية حياة أفضل، ومستقرة من الناحية الوظيفية القلبية.

الكلمات المفتاحية: عضلة القلب الضخامي الانسدادي، تضيق الأبهر؛ تضخم البطين الأيسر غير المتماثل، استئصال الحاجز العضلي، استبدال الصمام الأبهري.

ventricular outflow tract (LVOT) obstruction, asymmetric left ventricular hypertrophy (ALVH), significant systolic anterior motion (SAM) of the anterior mitral valve leaflet and mitral regurgitation.

Electrocardiogram (ECG) showed atrial fibrillation, left bundle branch bloc, and heart rate of 67 per minute. LVH with strain pattern. Poor R wave progression (see ►**Fig. 1**).
Fig. 1 ECG showing atrial fibrillation, LBBB and LAD.

Cardiac catheterization showed normal coronary arteries, with LV gram showing very small LV cavity during systole sings of HOCM and LVOT obstruction (see ►**Fig. 2**).

Echocardiography presurgery showed severe LVH (see ►**Fig. 3**) and normal LV systolic function with EF of 67%. The cavity size was decreased. There was HOCM, severe SAM with peak LVOT gradient of 125 mm Hg at rest, and 171 mm Hg with Valsalva. Restrictive LV filling pattern was consistent with elevated LA pressure. Moderate aortic stenosis with peak/mean pressure gradient of 51/25 mmHg, the aortic valve area (AVA) was 1.1 cm2 and there was moderate aortic valve calcification.

She became progressively worse, with more shortness of breath, New York Heart Association II-III, presyncope, chest tightness, and tiredness. She developed congestive heart failure (CHF) and paroxysmal atrial fibrillation with CHADs65 score of 2, so placed her on novel oral anticoagulation (NOAC), namely Edoxaban. She is preload-dependent due to her HOCM and she had significant heart failure; therefore, she was placed on guidelines-directed medical therapy, a small dose of diuretic and optimal medical therapy.

She was instructed to watch her fluid status closely, watch her body weight and minimize salt intake and continue with the above-mentioned medications especially β-blocker. At that point in time, she does not have palpitations or syncope. But this patient is at risk of ventricular arrhythmia, and she was made aware of that. Initially, she was referred for alcohol septal ablation procedure but she declined that and she also declined the implantation an implantable cardioverter defibrillator (ICD). Family screening was strongly recommended in her case and she was informed about that to assess her family for hypertrophic cardiomyopathy. Her mother was found to have late stage of HOCM and died of that.

She underwent cardiac surgery, LV septal myomectomy, and bioprosthetic aortic valve replacement (tissue AVR) with a size 23 tissue valve, aortic root enlargement with bovine pericardial patch. She currently feels much better and stable cardiac-wise, has much better quality of life and she is taking optimal medical therapy. Echocardiography postsurgery

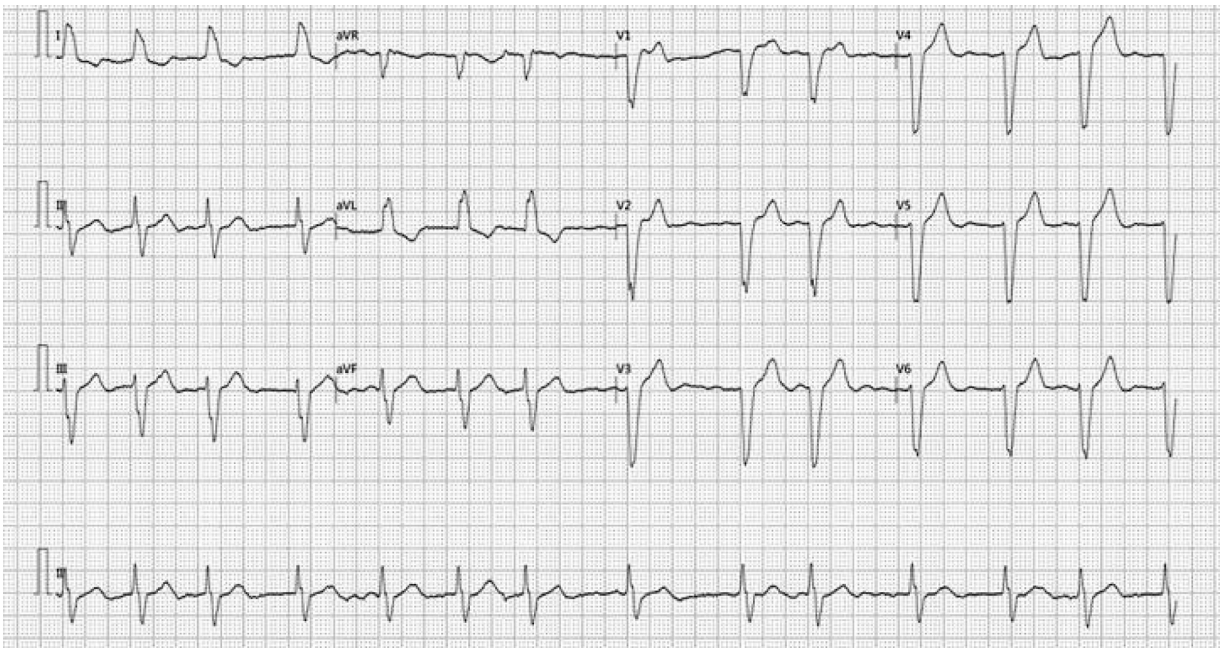

Fig. 1 ECG showing atrial fibrillation, LBBB and LAD.

showed normal biventricular size and systolic function. The left ventricular (LV) size and systolic function were normal with an ejection fraction (EF) of 60 – 65%. Status post ventricular septal myomectomy (see ►**Fig. 4**) with intact interventricular septum. The bioprosthetic aortic valve (tissue AVR) was well seated. Normally functioning bioprosthetic aortic valve with peak/Mean pressure gradients of 23/15 mm Hg, and aortic valve area (AVA) of 23 mm and there is moderate left ventricular hypertrophy (LVH) with septal myomectomy changes. There is mild pulmonary hypertension. RVSP was 40 mm Hg. Mild mitral regurgitation present. MAC. The ascending aorta is dilated measuring 39 mm.

Discussion

Hypertrophic cardiomyopathy (HOCM) is a genetic disorder that is characterized by left ventricular hypertrophy unexplained by secondary causes and a non-dilated left ventricle with preserved or increased ejection fraction. Asymmetric hypertrophic cardiomyopathy is the most common morphological variant or phenotype of HOCM.[1]

Our patient was found to have HOCM with asymmetric ALVH, and significant LVOT obstruction. She also had significant SAM of the anterior mitral valve leaflet and mitral regurgitation. Her myocardium was abnormal with cellular

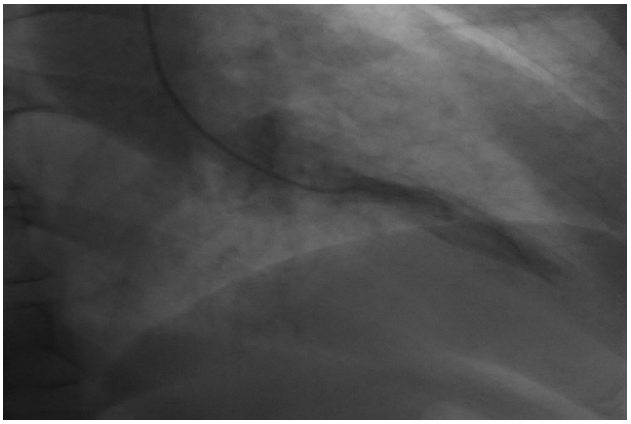

Fig. 2 LV gram showed very small LV cavity during systole sings of HOCM and LVOT.

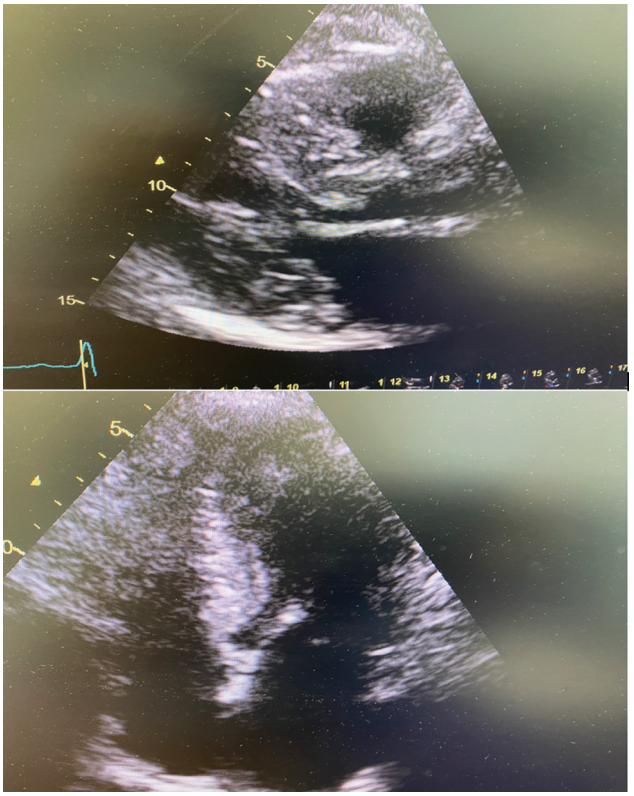

Fig. 3 Echo image showing LV septal hypotrophy with LVOT obstruction and SAM.

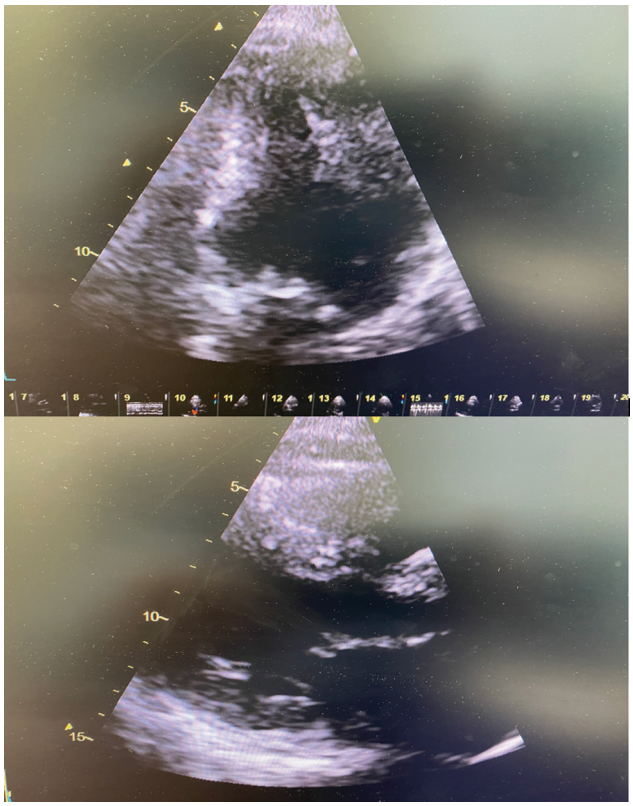

Fig. 4 Showing LV septal myomectomy.

and myofibrillar disarray, with asymmetrical septal hypertrophy. She also found to have moderate aortic stenosis that made the obstruction even worse. This made the patient progressively symptomatic despite optimal medical therapy. It has been suggested that it is difficult to diagnose and treat mixed aortic stenosis and obstructive hypertrophic cardiomyopathy.[5] After different investigational procedures, our patient underwent cardiac surgery, after which she became stable cardiac-wise. She was placed on optimal medical therapy; her symptoms improved with an improvement of her quality of life as well as reducing long-term complication. Similar results were reported in a recent study where surgical myectomy and AVR was associated with less mortality and longer-term survival.[6] Moreover, in a retrospective study conducted on 3523 patients, it was concluded that concomitant myectomy with AVR is a safe and effective procedure without additional complications and should be considered when indicated.[7] Conversely, another study showed that TAVR in patient with concomitant HCM was associated with substantially worse in-hospital outcomes, including cardiogenic shock, renal failure, and death.[8]

Overall, the presentation of severely obstructive HOCM and significant aortic stenosis is not uncommon, and that patients can undergo a combined surgical myectomy and AV replacement successfully along with optimal medical therapy as reported in our case.

Conclusion

The learning points that HOCM can occur along with significant aortic stenosis which can make the obstruction even worse. Therefore, those patients better to be referred sooner than later for cardiac surgery to get LV septal myomectomy and aortic valve replacement to minimize symptoms, to improve quality of like and reduces long term complication.

Funding
None.

Conflict of Interest
None declared.

Referrnces

1 Marian AJ, Braunwald E. Hypertrophic Cardiomyopathy: Genetics, Pathogenesis, Clinical Manifestations, Diagnosis, and Therapy. Circ Res 2017;121(07):749–770
2 Czarny MJ, Resar JR. Diagnosis and management of valvular aortic stenosis. Clin Med Insights Cardiol 2014;8(Suppl 1):15–24. Doi: 10.4137/CMC.S15716
3 Tuohy CV, Kaul S, Song HK, Nazer B, Heitner SB. Hypertrophic cardiomyopathy: the future of treatment. Eur J Heart Fail 2020;22 (02):228–240
4 Konno T, Chang S, Seidman JG, Seidman CE. Genetics of hypertrophic cardiomyopathy. Curr Opin Cardiol 2010;25 (03):205–209
5 Ramamurthi A, Aker EM, Pandian NG. A case of aortic stenosis and hypertrophic cardiomyopathy. Echocardiography 2012;29(10): 1261–1263
6 Desai MY, Alashi A, Popovic ZB, et al. Outcomes in Patients With Obstructive Hypertrophic Cardiomyopathy and Concomitant Aortic Stenosis Undergoing Surgical Myectomy and Aortic Valve Replacement. J Am Heart Assoc 2021;10(18):e018435
7 Kayalar N, Schaff HV, Daly RC, Dearani JA, Park SJ. Concomitant septal myectomy at the time of aortic valve replacement for severe aortic stenosis. Ann Thorac Surg 2010;89(02):459–464. Doi: 10.1016/j.athoracsur.2009.10.065
8 Bandyopadhyay D, Chakraborty S, Amgai B, et al. Association of Hypertrophic Obstructive Cardiomyopathy With Outcomes Following Transcatheter Aortic Valve Replacement. JAMA Netw Open 2020;3(02):e1921669