



Demystifying the Radiography of Age Estimation in Criminal Jurisprudence: A Pictorial Review

Vritika Bhardwaj^{1,*} Ishan Kumar^{1,*} Priyanka Aggarwal² Pramod Kumar Singh¹ Ram C. Shukla¹ Ashish Verma¹

¹Department of Radiodiagnosis and Imaging, Institute of Medical Sciences, Banaras Hindu University, Varanasi, Uttar Pradesh, India

²Department of Pediatrics, Institute of Medical Sciences, Banaras Hindu University, Varanasi, Uttar Pradesh, India

Address for correspondence: Ishan Kumar, Department of Radiodiagnosis and Imaging, Institute of Medical Sciences, Banaras Hindu University, Varanasi 221005, Uttar Pradesh, India (e-mail: Ishan.imsrd@bhu.ac.in).

Indian J Radiol Imaging 2024;34:496–510.

Abstract

Skeletal radiographs along with dental examination are frequently used for age estimation in medicolegal cases where documentary evidence pertaining to age is not available. Wrist and hand radiographs are the most common skeletal radiograph considered for age estimation. Other parts imaged are elbow, shoulder, knee, and hip according to suspected age categories. Age estimation by wrist radiographs is usually done by the Tanner-Whitehouse method where the maturity level of each bone is categorized into stages and a final total score is calculated that is then transformed into the bone age. Careful assessment and interpretation at multiple joints are needed to minimize the error and categorize into age-group. In this article, we aimed to summarize a suitable radiographic examination and interpretation for bone age estimation in living children, adolescents, young adults, and adults for medicolegal purposes.

Keywords

- ▶ bone age
- ▶ radiography
- ▶ skeletal
- ▶ POSCO

Introduction

Age estimation is based on the time of appearance of ossification centers of carpal bones along with the appearance and fusion of epiphyses of long and short tubular bones. In females, these changes occur earlier than males by approximately a year or 2.¹ Greulich-Pyle and Tanner-Whitehouse (TW) are the two methods for bone age estimation.^{2,3} Greulich-Pyle method advocates the comparison of the radiograph of the patient with the nearest standard radiograph corresponding to different chronological ages in males and females. Although this is a standardized and the most used method worldwide, there might be demographic and temporal differences.^{2,3} Tanner et al showed that the radio-

graphs of children in United States showed earlier maturation than the British bone age standard by approximately 3 months.⁴ Several studies have stated that differences in the rate of ossification in various demographic areas seem to be mainly the result of socioeconomic factors.^{5–7} TW method adopts a more objective approach where the maturity level of each bone is categorized into a stage from stage A to H and scored accordingly and the total score is transformed into the bone age.³ Various studies have documented the time of appearance of ossification centers of carpal bones along with the appearance and fusion of epiphyses of long and short tubular bones.^{8,9} There has been considerable variation regarding the ages at which epiphyseal union occurs with diaphysis of individual bone.¹⁰

Although a standard bone age atlas has not been developed yet for Indian population, bone age estimation by TW-3

* V.B. and I.K. are first coauthors as their contribution is equal.

method has shown to be more accurate among the available methods.¹¹ Applicability of this method is limited by its complexity, demographic and temporal differences.^{3,4} Behera et al observed that the mean bone age estimated by Greulich-Pyle method was less than the mean chronological age by 0.43 years, with a mean difference of 0.14 in males and 0.7 in females. However, a good correlation of 0.95 in males and 0.91 in females was observed upon comparison of chronological age to the estimated bone age by Greulich-Pyle standards.¹² An observational study by Shah et al has shown that the bone age estimation is underestimated at all ages irrespective of gender till the pubertal spurt. This study showed TW3 method to be most suitable among the three most commonly used methods, especially for girls and prepubertal boys. For pubertal boys, Greulich-Pyle method was more accurate. Upon assessment of bone age in children over 13 years, overestimation by 0.7 years and underestimation by 0.6 years were observed in girls and boys, respectively.¹¹

Data from multiethnic population and incorporation of strong mathematical base has been used for the development of TW-3 method, which might explain the suitability of this method over other methods of bone age assessment.¹³ Gilsanz and Ratib developed a digital atlas in 2005 by producing idealized and artificial images of hand radiographs of healthy children. Age- and sex-specific images were produced by analysis of size, shape, density, and morphology of ossification centers in hand radiographs. The quality and precision of these images were found to be better than GP atlas; however, further studies are needed for standardization and elimination of outliers.¹⁴

As per the Juvenile Justice (Care and Protection of Children) Rules 2007 of India, estimation of age can be done by (i) matriculation or equivalent certificates, (ii) the date of birth certificate from the school (other than a play school) first attended, (iii) the birth certificate given by a corporation or a municipal authority or a panchayat and only in the absence of either of above, the medical opinion is sought from a duly constituted medical board, which will declare the age of the juvenile or child. Both forensic practitioners and radiologists are often requested to assess the age of a living individual that carries an evidentiary significance in medicolegal cases. While estimating the age of an individual, multiple criteria such as physical development, dental examination and radiological examination of appearance, and fusion of epiphysis of long bones are commonly used. Radiography of wrist and hands, long bones, pelvis, and shoulder joints are commonly performed either alone or in combination with each other. The purpose of this article is to suggest the most suitable skeletal radiographs and relevant radiological clues for age estimation of living individuals to be obtained for various age groups that are relevant according to Indian jurisprudence. Overall, we have discussed the age estimation in infancy, toddlers, prepuberty, adolescent, adults, and elderly population. The age groups divisions in this article may seem arbitrary; however, we have chosen the age divisions as per various Indian laws and medicolegal situations.

Neonate, Infant, and Preschool Children

Medicolegal relevance: This age group is relevant for Hindu Minority and Guardianship Act (1956) of India. By virtue of the provisions of the Section 6(a) of the Act, the custody of a child below 5 years of age is often given to the mother of the child, for example, in a petition filed by Meenakshi versus State of UP (2020) asking the court to liberate her son, a 4-year-old minor from his father's custody, the case was ruled in favor of the mother.¹⁵ This age of the victim is important in cases of nonaccidental injury or child victims brought to emergency department often without any documents and accompanying relatives. Age estimation is also important in separated children such as victims of child trafficking. Adoption of a child without any birth certificate may require age estimation to protect the best interest of the child and to ensure that the age-appropriate vaccination and medical services can be provided to the adoptee.¹⁶

Radiological Age Estimation

Systematic age estimation from radiographs for children below 5 years is depicted as flowchart in ►**Fig. 1**. Antero-posterior (AP) wrist radiograph is done to study the number of carpal bones (►**Figs. 2, 3**). All the carpal bones, and all the epiphyses in phalanges, metacarpals, distal ulna, and radius lack ossification at birth. Capitate and hamate appear at 3 months and subsequently, radius epiphysis appears roughly at 10 months for girls and 15 months for boys. In toddlers (females: 10 months to 2 years; males: 14 months to 3 years), the ossification centers of hands appears in following order: (i) proximal phalanx, (ii) metacarpals, (iii) middle phalanx, and (iv) distal phalanx with some exceptions.¹⁴ Subsequently, other carpal bones appear in sequence and can be used to estimate the age, as explained in ►**Figs. 2 and 3**.

Children between 7 and 12 Years: Age for Consent; Committing an Offense

Medicolegal Relevance

According to section 82 of Indian Penal Code (IPC), a child under 7 years of age is incapable of committing an offense. Under section 83 IPC, a child between 7 and 12 years of age is presumed to be capable of committing an offense. As per Convention on the Rights of the Child of United Nations, all the countries have established a threshold age of criminal responsibility which varies from 6 to 18 years.^{17,18} Under section 89 IPC, a child under 12 years of age cannot give valid consent to suffer any harm that can occur from an act done in good faith and for its benefit, like consent for surgery. In international context, especially in European countries, this age group has become particularly important because of unaccompanied minors as immigrants over the last two decades and age determination is often required.

Radiological Age Estimation

Systematic age estimation from radiographs for pre-, early-, and late-puberty is depicted as flowchart in ►**Fig. 4**. At pre- or early puberty, AP view of pelvis and elbow radiograph can

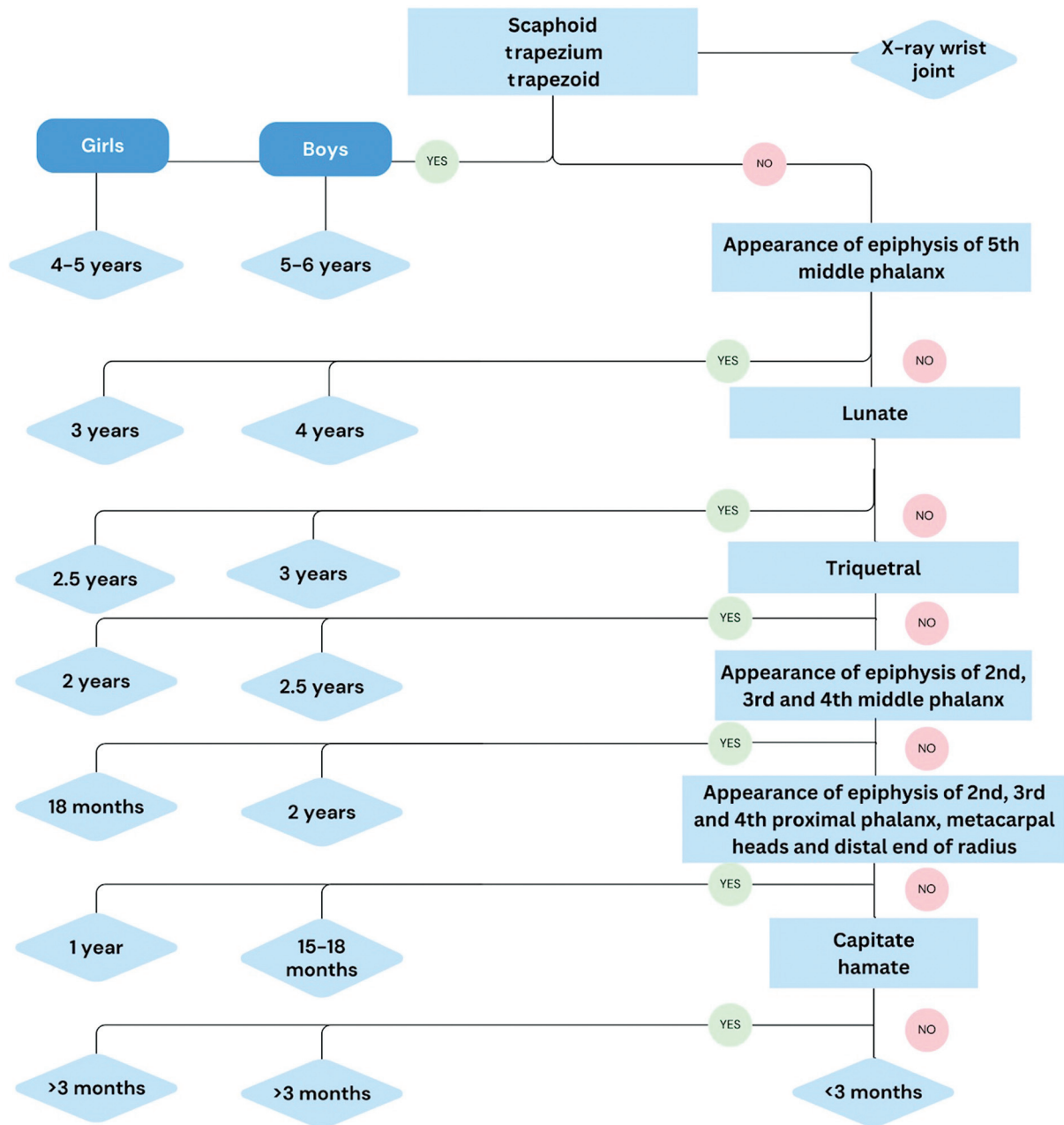


Fig. 1 Flowchart depicting systematic age estimation from radiographs for children below 5 years.

be done in addition to hand and wrist.^{8,19} If the radiograph shows unfused pubic rami and ischium, the age is likely to be less than 7 to 8 years (► **Fig. 5**). On AP view of elbow radiograph, epiphysis of medial epicondyle of humerus is looked for. If not seen, the age is estimated as less than 6 to 7 years (► **Fig. 6**). ► **Table 1** summarizes the sequence of appearance of ossification centers around elbow joint (► **Fig. 7**). This order of appearance should be remembered using the mnemonic CRITOE (capitellum, radial head, internal epicondyle, trochlea, olecranon, external epicondyle). ► **Table 2** summarizes the radiographic ossification features from birth to 10 years of chronological age. Nonvisualization of pisiform and epiphysis of lateral epicondyle of humerus indicates age below 12 years.

Late Puberty

Medicolegal Relevance

The Child Labor (Prohibition and Regulation) Act of India, 1986, prohibits employment of a child below 14 years of age in any factory, mine, or any hazardous occupation. Such cases may require radiological age estimation in case of missing certificates.²⁰

Radiological Age Estimation

To ascertain their age in cases of non-availability of documents, AP radiograph of pelvis can be done to look for the appearance of crest of ilium (iliac apophysis), which appears laterally and moves centrally. The approximate age can be

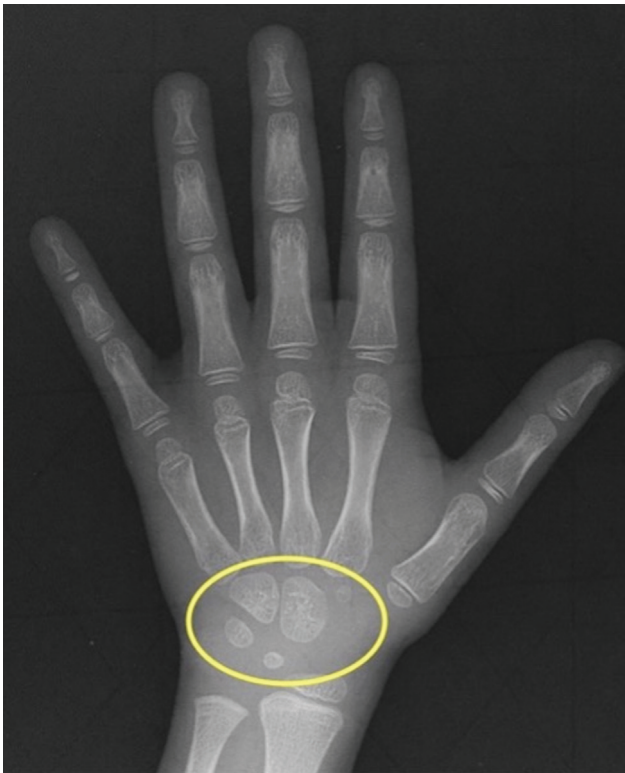

Fig. 2 Anteroposterior view of wrist radiograph showing five carpal bones (yellow circle) indicating approximate age more than 5 years.

estimated using Risser's grading based on iliac crest divided into four quadrants (► **Fig. 8**).²¹

Risser 1 to 2: < 50% ossification (14 years for girls, 15 years for boys)

Risser 3: 75% ossification (15 years for girls, 16 years for boys)

Risser 4: 100% ossification (16 years)

Risser 5: Iliac apophysis fuses to iliac crest (16 year for girls, 18 years for boys).

It should be noted that, in the hand radiograph, this age group follows a characteristic order of fusion of epiphysis starting from distal phalanx, followed by metacarpals, proximal phalanx and middle phalanx in that order.¹⁴ ► **Table 3** summarizes the radiographic features from 11 to 16 years of chronological age:

Juvenile Offenders (Boys below 16 Years and Girls below 18 Years of Age)

Medicolegal Relevance

As per section 10 of the Juvenile Justice (Care and Protection of Children) Act of India, juvenile offenders (boys below 16 years and girls below 18 years of age) who have committed an antisocial or criminal activity (Juvenile Delinquency) are tried by juvenile court and if convicted are sent either for special care under parents/ guardians or sent to correctional

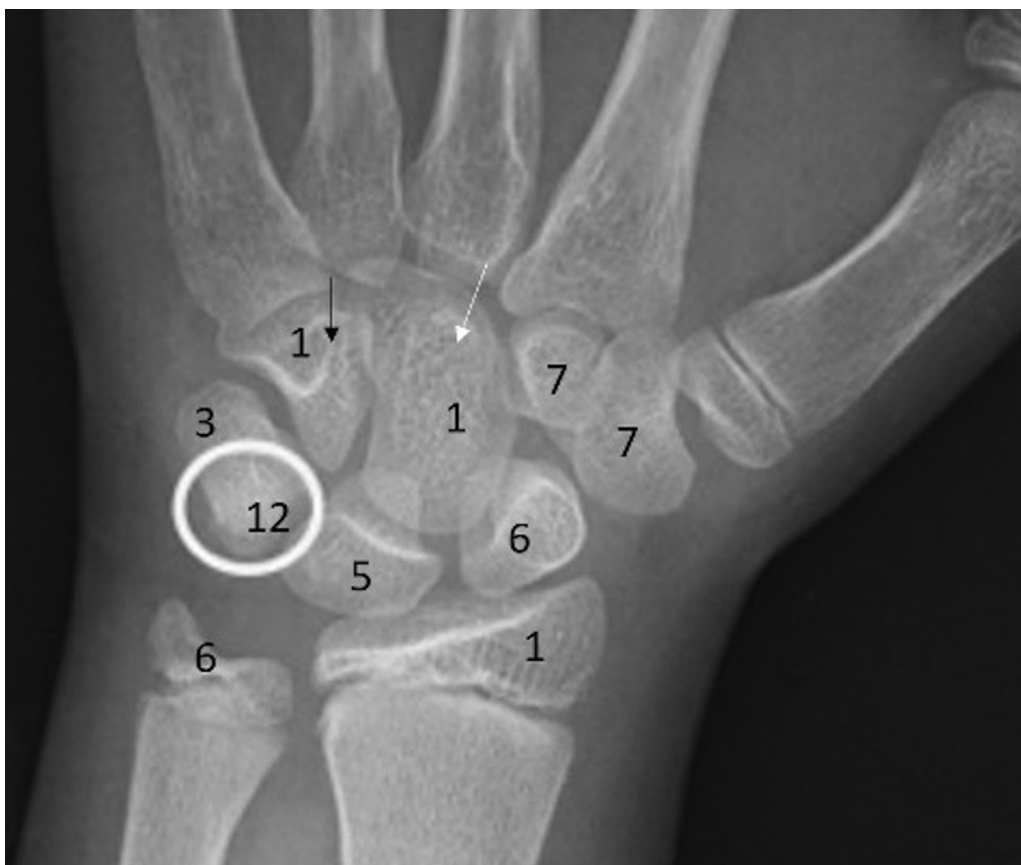

Fig. 3 Anteroposterior radiographs of wrist joint showing the ossification center of various carpal bones. The numbers indicate the upper limit of age at which these carpal bones appear on radiograph. Capitate (white arrow) and hamate (black arrow) appear at 1 year, followed by triquetrum (3 years), lunate (5 years), scaphoid (6 years), trapezium and trapezoid (7 years), and pisiform (white circle) at 12 years.

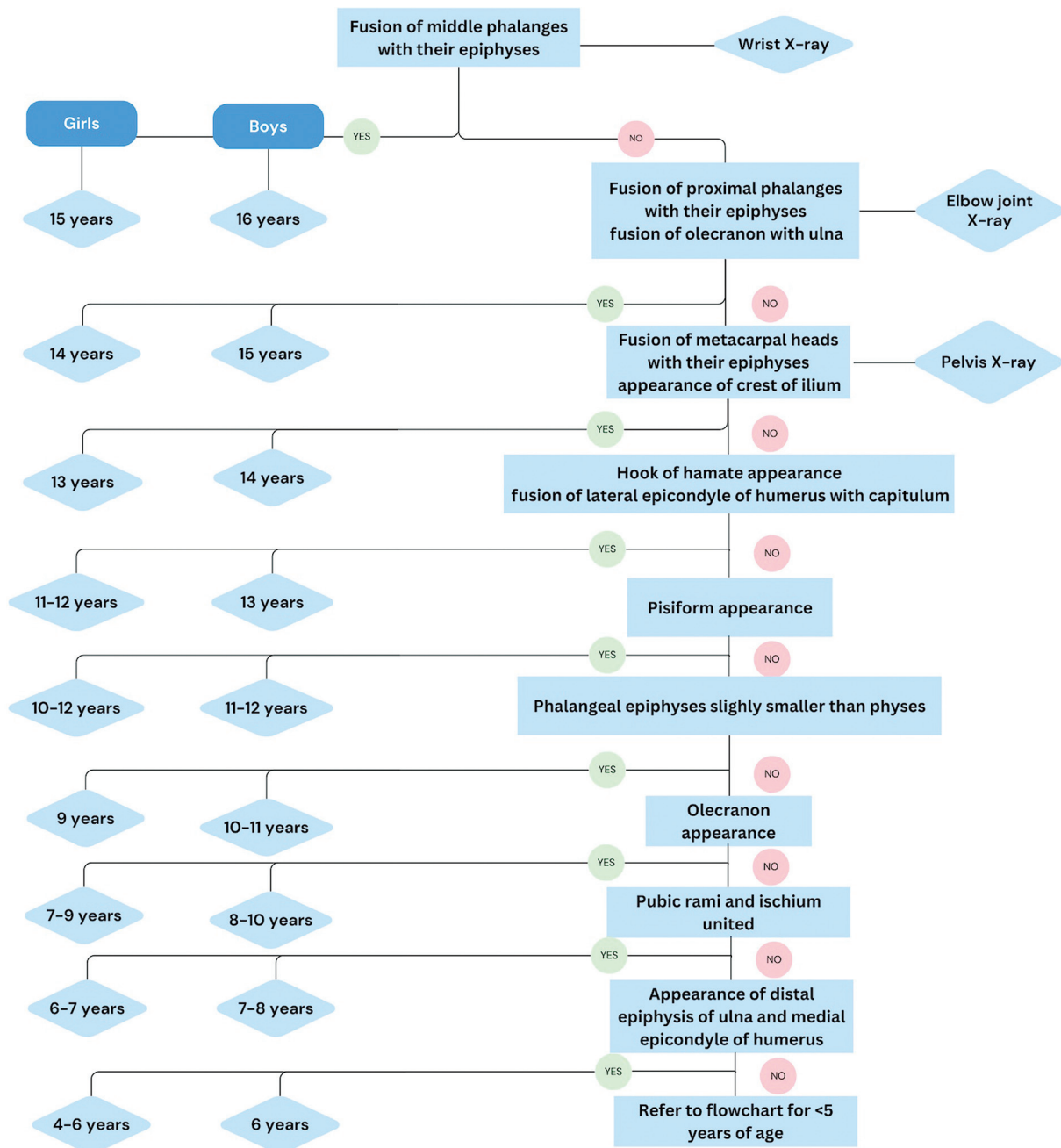


Fig. 4 Flowchart depicting systematic age estimation from radiographs for 5 to 16 years of age.

school with facilities for education, vocational training, and rehabilitation (Judicial punishment). Imprisonment for juvenile delinquency is prohibited. In a case of Kanchal Lal Juvenile versus State of UP and Another (2015), appeal was made by the revisionist for declaring the accused as juvenile. Ossification test was done in this case and the case was dismissed.²² Age fraud through document forgery in cricket and other sports is a common occurrence and regularly requires ossification test for age estimation.

Radiological Age Estimation

AP radiographs of hip joint and AP radiograph of shoulder with abducted arm should be done. In the hip, the estimated age of fusion of greater trochanter is 14 to 16 years, followed by

anterior inferior iliac spine (16 years), iliac crest (16–18 years), and anterior superior iliac spine (19–25 years).²³ Ischial tuberosity appears at 15 to 17 years and complete ossification and fusion of ischial tuberosity is seen at 18 to 20 years, although it can completely fuse as late as 25 years^{19,24} (►Fig. 9). X-ray of shoulder joint with abducted arm can be obtained to look for fusion of coracoid process with scapula. If not, age can be estimated as less than 16 years in male and 18 years in female (►Fig. 10). Also, secondary ossification centers of acromion and clavicle develop around 14 to 16 years and are completely fused at 17 years. The proximal humeral growth plate also begins to close around 14 years of age and concludes at approximately 17 years of age.²⁵ Board of Control for Cricket in India has adopted bone age tests using hand-

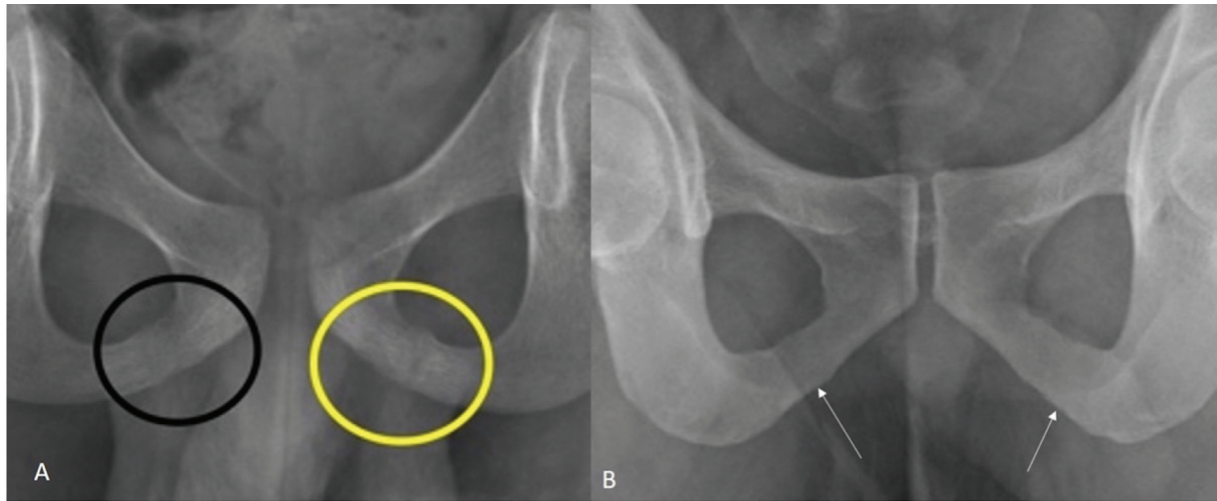


Fig. 5 Anteroposterior view of hip joint radiographs showing (A) unfused left ischiopubic joint (yellow circle) and nearly fused right ischiopubic joint (black circle) indicating approximate age of 7 to 8 years and (B) completely fused bilateral ischiopubic joints (white arrows) indicating age above 7 years.

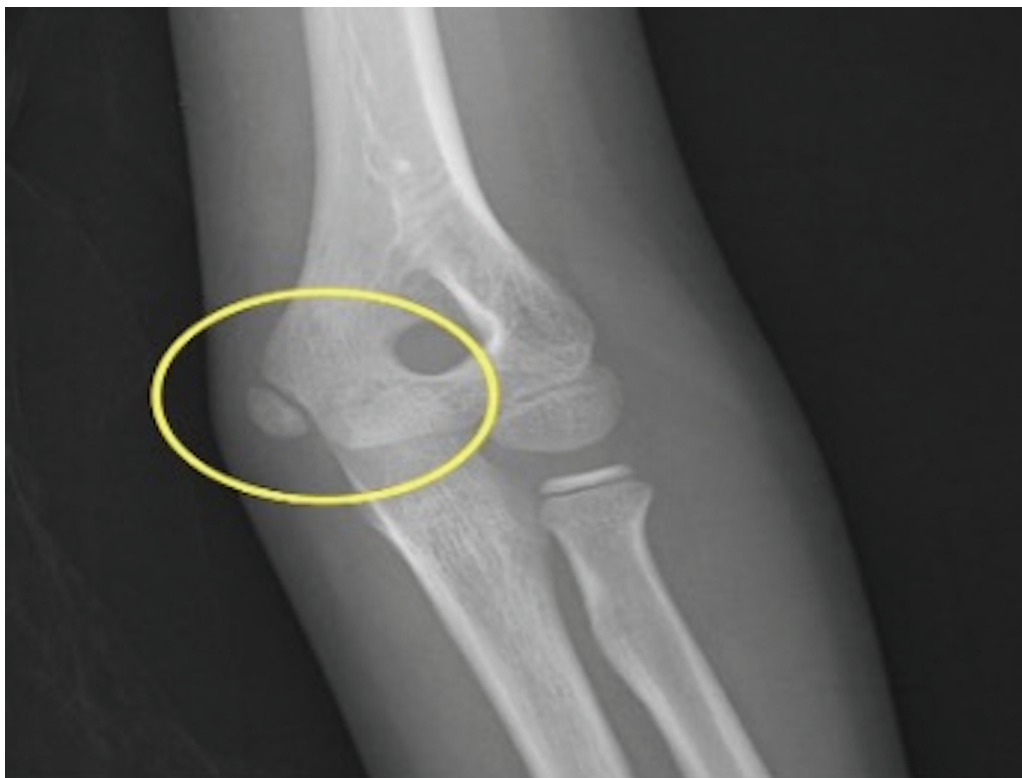

Fig. 6 Anteroposterior radiograph of elbow joint of a male child showing appearance of medial epicondyle of humerus (yellow circle) and absence of trochlea indicating age between 7 and 9 years.

wrist radiographs (TW 3 method) to estimate the age of players in the 16-year-old threshold considering the prevalent forgery in documents related to age proof.

18 Years: Attainment of Majority

Medicolegal Relevance

(i) Under section 87 IPC, a child under 18 years of age cannot give valid consent to suffer any harm that may

result from an act not intended or not known to cause death or grievous hurt. (ii) Any matrimonial alliance with a girl aged less than 18 years comes under the prohibition of Child Marriage Act of India, 2006, and is a punishable offense. (iii) The Criminal Law Amendment 2013 increased the age of consent from 16 to 18 years which implies that any sexual activity below the age of 18 years irrespective of their consent would amount to statutory rape as per section 375 of the IPC. (iv) POSCO (Protection of Children from Sexual Offenses) Act, 2012 (amended in

Table 1 Sequence of appearance of ossification centers around elbow joint¹

Ossification center	Approximate age (in years) of appearance in boys	Approximate age (in years) of appearance in girls
C: Capitellum	1	1
R: Radial head	5	4
I: Internal (medial) epicondyle	7	5
T: Trochlea	9	8
O: Olecranon	10	8
L: External (lateral) epicondyle	12	11

2019) of India protecting children from a slew of sexual offenses like sexual assault, sexual harassment, and pornography defines a child as any person below the age of

18 years. (v) In accordance with Indian majority act, 1975, every person domiciled in India shall attain the age of majority on completion of 18 years and not before for granting civil rights including voting, ID card, driving license, valid will, property maintenance & disposal.^{26–29}

Radiological Age Estimation

The ossification test involves taking AP radiographs of knee joint to look for fusion of epiphyses of lower end of femur, upper end of tibia, and fibula as well as shoulder joint for fusion of epiphysis of head of humerus with shaft. If unfused, age can be estimated as less than 18 years (► Fig. 11). Clavicle is the last bone to ossify in the entire skeleton and the assessment of medial epiphysis is done using computed tomography (CT) scan, only if rest of the skeleton is mature. Ossification of more than two-thirds of the epiphyseal plate suggests a minimum age of 19 years and complete bony fusion between epiphysis and metaphysis with an underlying epiphyseal scar suggests a minimum age of 21 years.^{30,31} As discussed earlier, fusion of ischial tuberosity also suggests

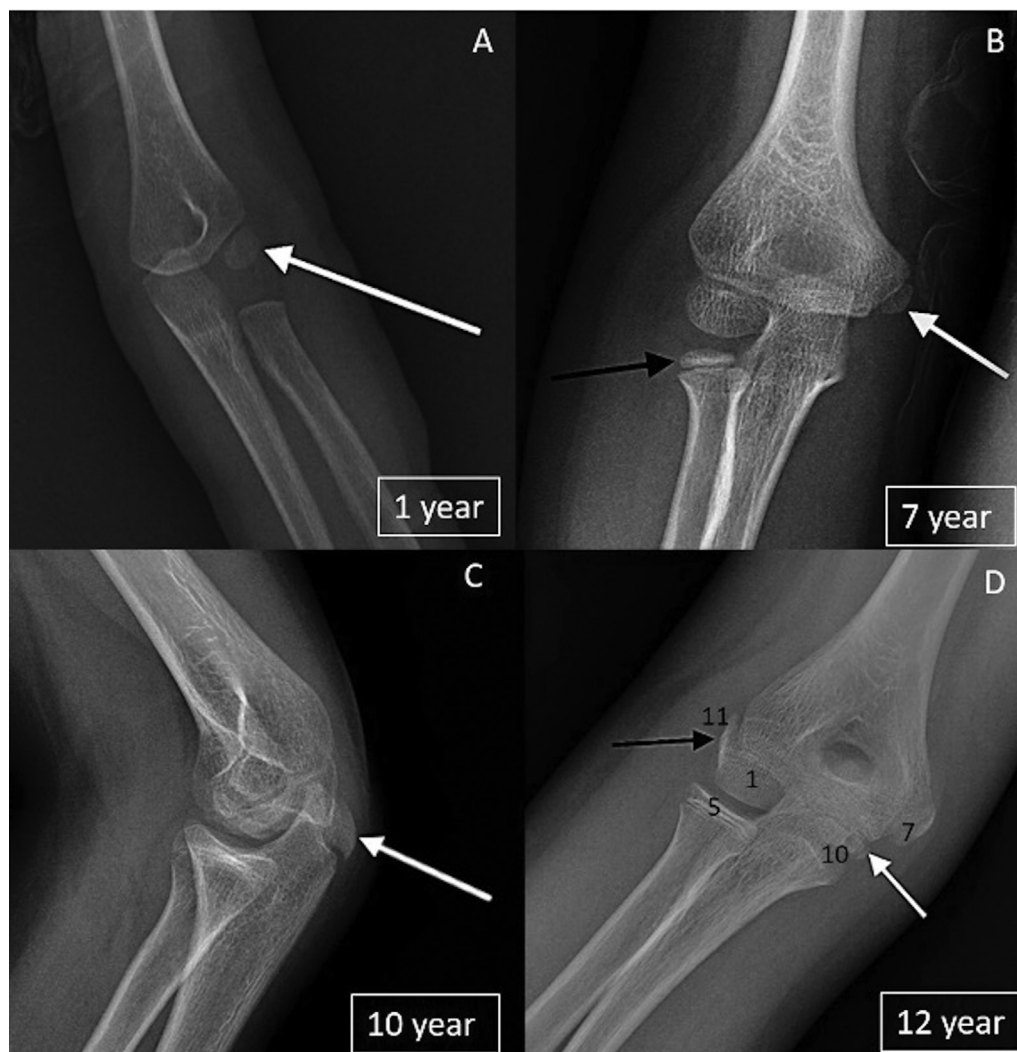


Fig. 7 Radiographs of elbow joint of four male children showing (A) capitellum (white arrow), (B) radial head (black arrow) and medial epicondyle (white arrow) (C) olecranon (white arrow) in lateral view, (D) trochlea (white arrow) and lateral epicondyle (black arrow). Appearance of various structures around elbow joint representing age in years has also been depicted in the last image (age corresponding to the X-ray images are indicated in boxes).

Table 2 Features on radiograph from birth to 10 years of chronological age^{1,8,10}

Order of appearance	Chronological age (male)	Chronological age (female)	Bones appeared in wrist radiograph	Other changes (knee, ankle, skull, elbow, pelvis)
1.	3 months	3 months	<ul style="list-style-type: none"> • Capitate • Hamate 	<ul style="list-style-type: none"> • Lower end of femur • Talus, calcaneum
1.	15–18 months	1 year	<ul style="list-style-type: none"> • Epiphysis 2nd, 3rd, and 4th proximal phalanx • Metacarpal heads • Distal end of radius 	<ul style="list-style-type: none"> • Anterior fontanelle closed • Metopic suture closed
2.	2 years	18 months	<ul style="list-style-type: none"> • Epiphysis 2nd, 3rd, and 4th middle phalanx 	<ul style="list-style-type: none"> • Condylar part of occipital bone fuses with squama
3.	2.5 years	2 years	<ul style="list-style-type: none"> • Triquetral 	<ul style="list-style-type: none"> • Number of carpal bones corresponds to age in years
4.	3 years	2.5 years	<ul style="list-style-type: none"> • Lunate 	
5.	4 years	3 years	<ul style="list-style-type: none"> • 5th middle phalanx 	
6.	5–6 years	4–5 years	<ul style="list-style-type: none"> • Scaphoid, Trapezium and trapezoid 	
7.	6 years	4–6 years	<ul style="list-style-type: none"> • Distal epiphysis of ulna 	<ul style="list-style-type: none"> • Medial epicondyle of humerus • Condylar part of occipital bone fuses with basiocciput
8.	7–8 years	6–7 years		<ul style="list-style-type: none"> • Rami of pubis and ischium unite
9.	8–10 years	7–9 years		<ul style="list-style-type: none"> • Olecranon

an age more than 18 years. ►Table 4 summarizes the radiographic ossification assessment from 17 to 25 years of age. Systematic age estimation from radiographs for 17 to 25 years is depicted as flowchart in ►Fig. 12.

Elderly

Medicolegal Relevance

Maximum age of retirement of most governmental services is 60 to 62 years. Also, age is a major aspect in deciding health insurance premium as well as other benefits. In the case of Rami Bai versus Life Insurance Corporation of India (1980), the age of the insured person was falsely claimed to be 48 years according to the appeal by the plaintiff.³² The enquiry revealed his actual age as 66 years, and thus the suit was dismissed. Many cases of disputes related to the actual age of the insured are usually solved by documents with date of birth like birth certificate, high school passing certificate, etc. However, in cases where these are not available, ossification test can be done to see the fusion of manubriosternal joint.

Radiological Age Estimation

In such cases, lateral view of chest radiograph can be taken to look for manubriosternal joint fusion. Unfused manubriosternal joint indicates the age as less than 60 to 62 years (►Fig. 13). Ossification of hyoid bone and fusion of cranial sutures, better assessed through CT scan, can serve as an indicator of age in adults and elderly. Posterior sagittal suture closes at 30 to 40 years. Complete fusion of coronal and sagittal suture occurs at 50 to 60 years, and lambdoid suture fuses by 55 years.^{33,34}

Age Estimation from Dental Examination

Dental examination and radiographs from orthopantomogram have been included in National Code against Age Fraud in Sports by Sports Association of India. The Ministry of Health and Family Welfare of Maharashtra approves age estimation using dental radiographs. Estimation of age from dental examination is possible till approximately 25 years of age where specific age categorization between 17 and 25 years cannot be done due to varying age of appearance of third molar.³⁵ Objective method of age estimation by dental radiographs is conventionally done by Demirjian's method that is based on eight developmental stages ranging from crown and root formation to apex closure of the seven left permanent mandibular teeth.³⁶ Since our review focuses on radiological skeletal examination, a detailed description is beyond the scope of this article.

Limitations and Other Modalities

One of the major flaws with the ossification test is that it only tells the "estimated" age of a person and not the exact age. It only estimates the "biological" age of a person that differs from "legal" age. The possibility of an error cannot be ruled out. Ossification test leaves much room for speculation and does not give a sure indication as to the age of a person, particularly when it is in the border region. It should be noted that as per the Supreme Court of India, when the expert opinion is given in an age range, the lower age of the range is considered as the age of the victim, so that the benefit of the doubt favors the victim.³⁷ Another

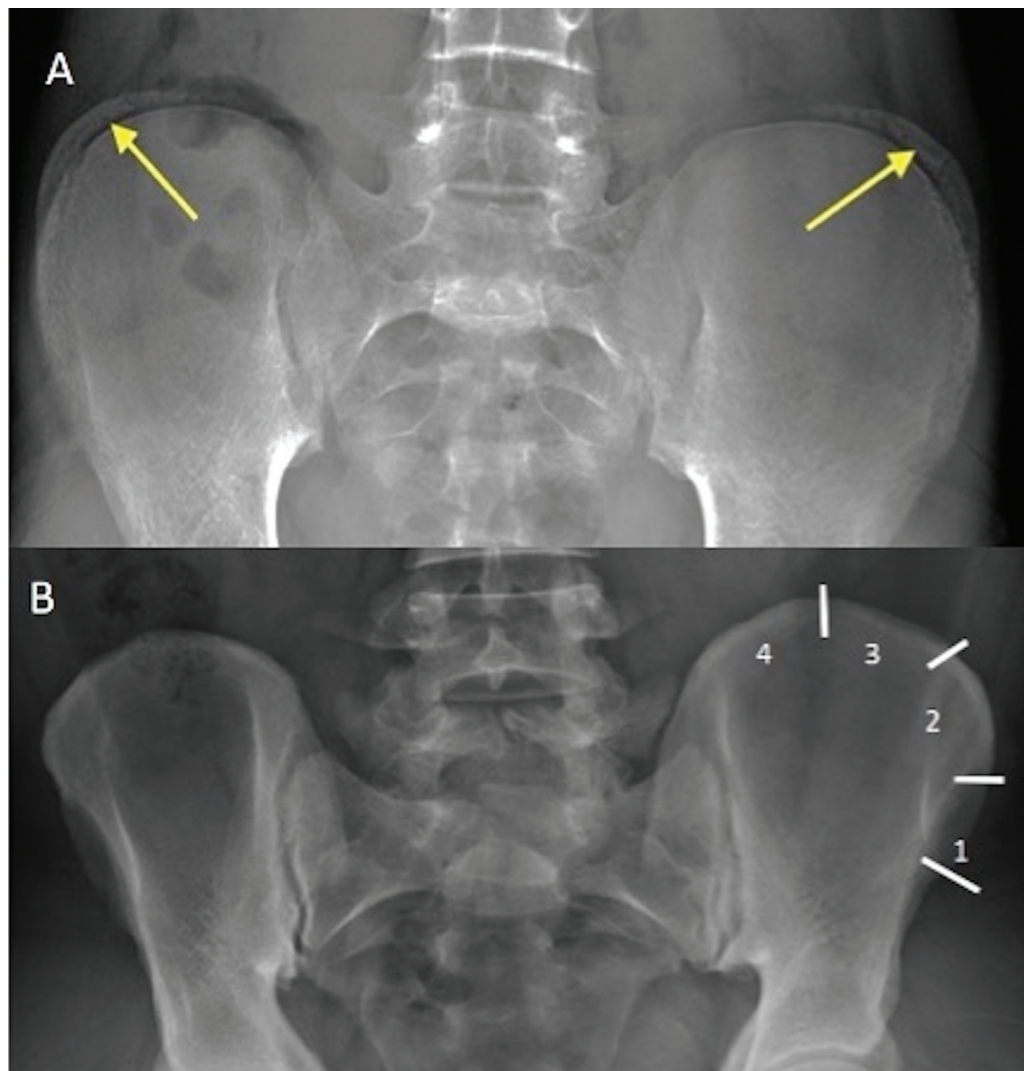


Fig. 8 Anteroposterior radiograph of pelvic bones of a 15-year-old girl showing (A) unfused bilateral crest of ilium (yellow arrows), with 75% ossification (Risser grade 3). (B) Completely fused bilateral iliac crests (Risser grade 5) of a 17-year-old girl. Numbers indicate Risser grade based on ossification of iliac crest.

Table 3 Features on radiograph from 11 to 16 years of chronological age^{1,8,10}

Order of appearance	Chronological age (male)	Chronological age (female)	Bone changes (wrist and hand)	Other changes (elbow, shoulder)
10.	Till 11 years	Till 9 years	<ul style="list-style-type: none"> Phalangeal epiphyses slightly smaller than physes 	
11.	11–12 years	10–12 years	<ul style="list-style-type: none"> Phalangeal epiphyses slightly wider than physes but not thickened Appearance of pisiform 	
12.	13 years	11–12 years	<ul style="list-style-type: none"> Hook of hamate 	<ul style="list-style-type: none"> Lateral epicondyle of humerus unites with trochlea and capitulum
13.	14 years	13 years	Metacarpal head	<ul style="list-style-type: none"> Hip (appearance of crest of ilium)
14.	15 years	14 years	Proximal phalanx	<ul style="list-style-type: none"> Coracoid process fuses with scapula Olecranon united with ulna
15.	16 years	15 years	Middle phalanx	

major limitation of the ossification test is that the test is not useful when a person has crossed 25 to 27 years of age. This is primarily because nearly all the bones are completely ossified and the skeletal growth ceases by the age of

25 years. Furthermore, all of the techniques employed to determine the age of a living individual can only provide estimates of biological age but no certainties with regard to chronological age.³⁸

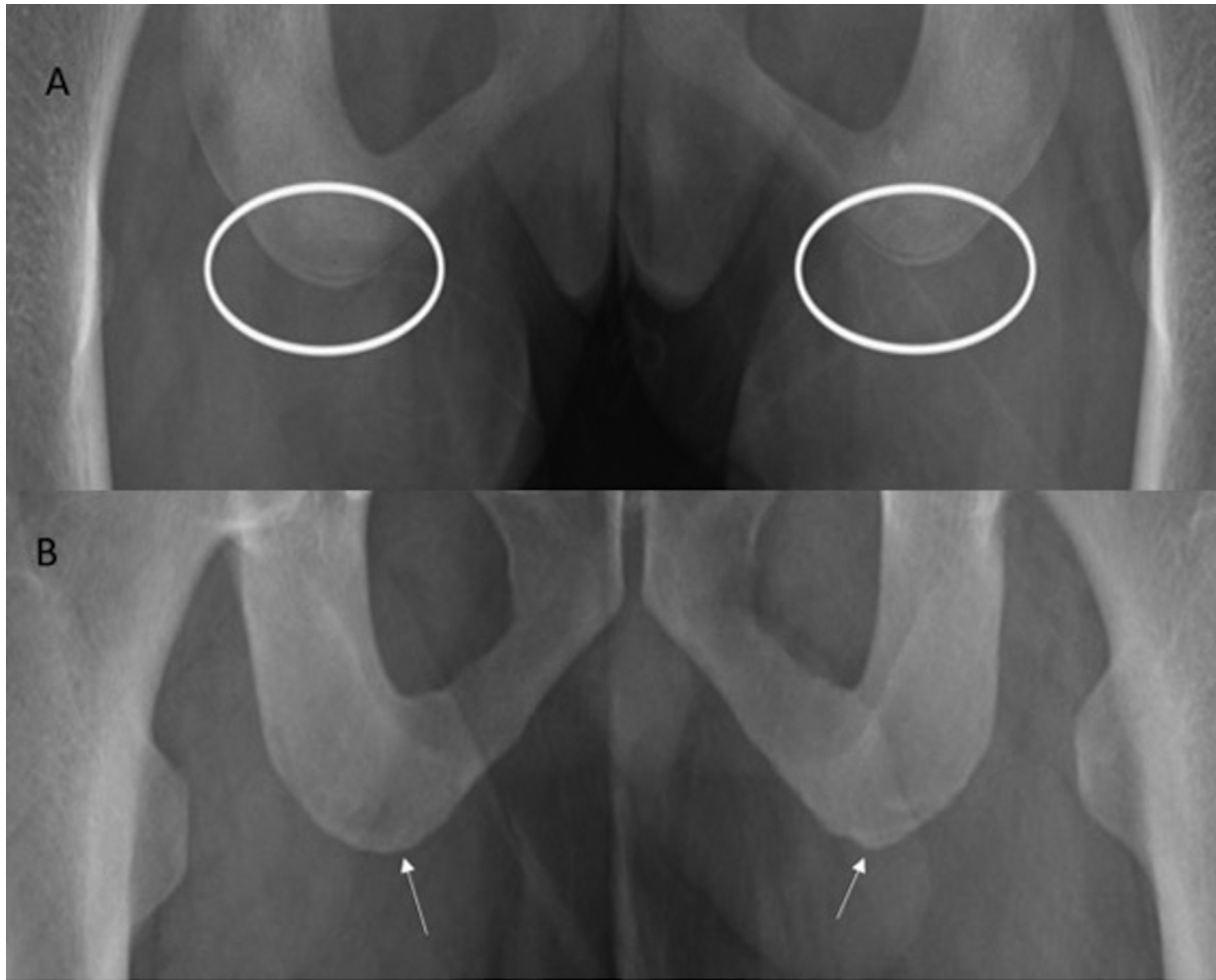


Fig. 9 Anteroposterior view of pelvic radiographs of 16-year-old male showing (A) unfused bilateral ischial tuberosities (white circles). (B) Completely fused bilateral ischial tuberosities (white arrows) in an 18-year-old boy.

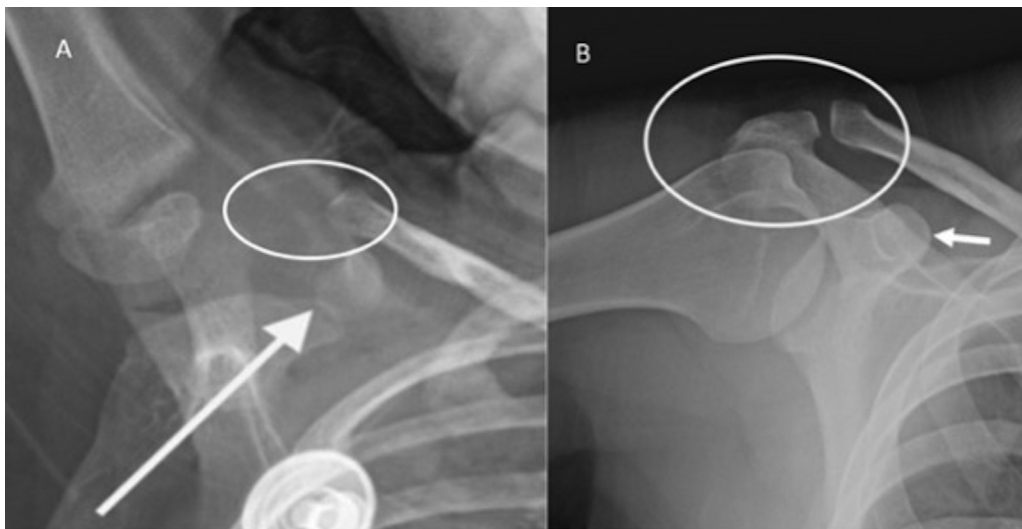


Fig. 10 Anteroposterior view of shoulder radiographs showing (A) unfused coracoid process (white arrow) and nonossified acromion. Also, proximal humeral physis is completely unfused suggesting age less than 14 years. (B) Completely fused coracoid process (arrow), ossified acromion (white circle), and fused humeral physis indicating age above 17 years.

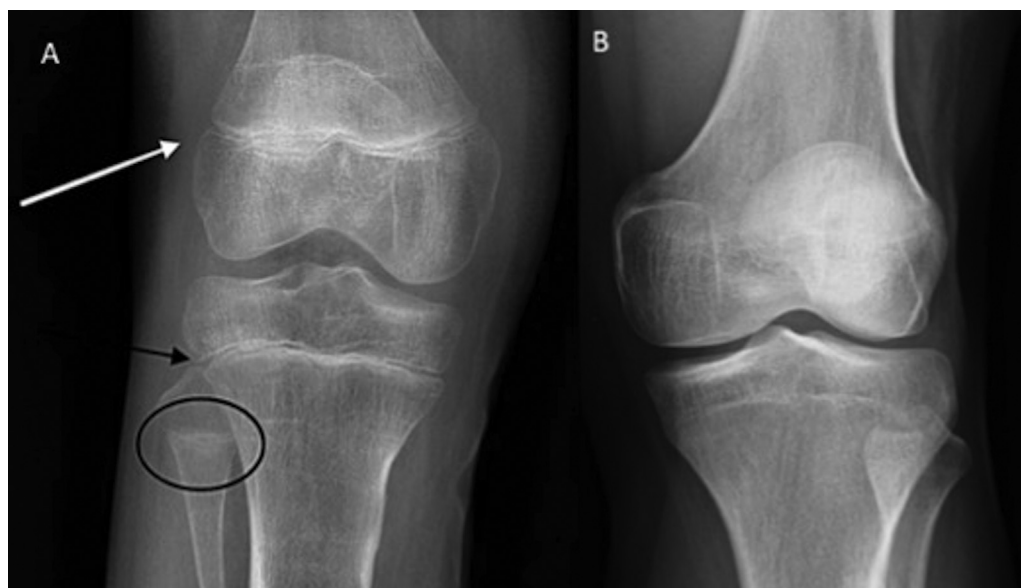


Fig. 11 Anteroposterior view of knee joint radiographs showing (A) unfused epiphyses of lower end of femur (white arrow), upper end of tibia (black arrow), and fibula (black circle) and (B) fused epiphyses in these areas in another man indicating age more than 18 years.

Table 4 Features on radiograph from 17 to 25 years of chronological age^{1,10}

Order of appearance	Chronological age (male)	Chronological age (female)	Bone changes (long bone epiphyseal fusion)	Other changes (elbow, pelvis, wrist, knee, shoulder)
16.	17–18 years	13–14 years	<ul style="list-style-type: none"> • Ulna lower end • Radius lower end (complete maturation) 	<ul style="list-style-type: none"> • Appearance of epiphysis of ischial tuberosity • All epiphyses of elbow joint join their respective shaft (except medial epicondyle) • Head of femur and lower end of tibia join shaft
17.				
18.	18–20 years	15–18 years		<ul style="list-style-type: none"> • All epiphyses of wrist, knee united • Lateral end of clavicle united • Acromion united to scapula
19.	20–22 years	19–21 years		<ul style="list-style-type: none"> • Ischial tuberosity fused
20.	23–25 years	22–24 years		<ul style="list-style-type: none"> • Four middle pieces of sacrum fuse • Fusion of all epiphyses

Recently, new methods for bone age assessment have been developed, including ultrasonographic, computerized and magnetic resonance imaging (MRI) methods.

1. Ultrasonographic method: There are several reports regarding ultrasonographic evaluation of bone age using an instrument called BonAge.^{39,40} Two transducers are utilized, one at the subject's hand and another at the wrist, while ultrasonic waves pass through distal radius and ulnar epiphysis. A software is used to calculate the bone age using an algorithm based on measurements of sound velocity and the distance between the two transducers. Although it does not involve any radiation, the operator-dependence and cumbersome technique are the disadvantages of ultrasonographic method. Further studies of bone age assessment

by ultrasonography are needed in larger populations, different ethnic groups, and children with growth disorders.

2. Computerized method: Several computerized systems for bone age assessment have been reported.^{41,42} Some of these systems were developed based on the TW method. One example is the computer-assisted skeletal age score (CASAS), in which an image is digitized and represented by several mathematical coefficients.^{43,44} These coefficients are then compared with those generated by each stage of the TW standards, and the closest match is determined. Although CASAS has been reported to be more reliable than the manual methods, a limitation of CASAS is that it can take longer to estimate bone age than the manual methods because each bone must be located manually. The usefulness of this system has been reported

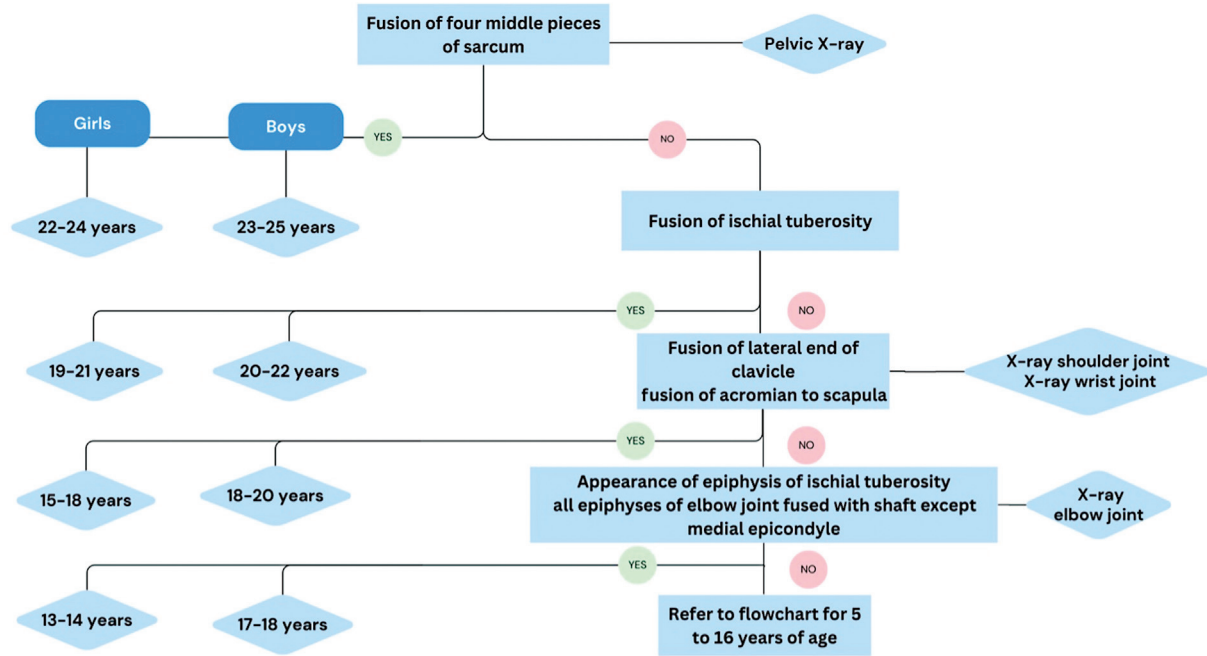


Fig. 12 Flowchart depicting systematic age estimation from radiographs for 17 to 25 years of age.

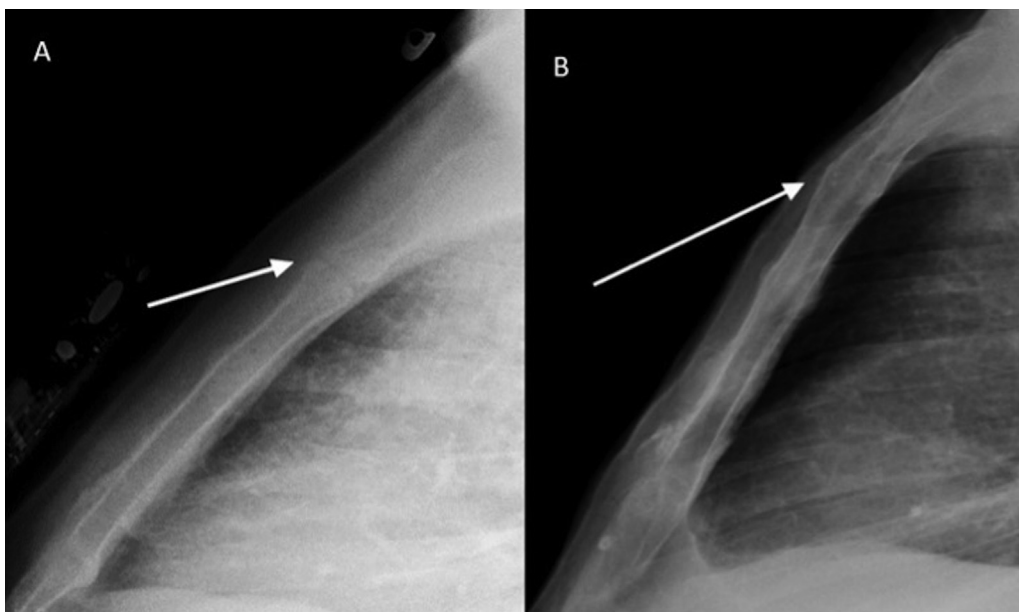


Fig. 13 Lateral view of chest radiograph showing (A) unfused and (B) fused manubriosternal joint (white arrow in A and B, respectively), the latter indicating age as more than 62 years.

for various ethnic groups especially by calibration to the standard for Japanese children.

3. MRI: MRI has been recommended by the Study Group on Forensic Age Diagnostics (AFGAD) for growth plate analysis to estimate bone age.⁴⁵ The European Commission has also prioritized the use of radiation-free methods for this purpose.⁴⁶ Terada et al reported the usefulness of bone age assessment using MRIs of the hand and wrist compared with radiographs.^{47,48} They used an open-compact

MR imager with a permanent magnet that was newly developed as a pediatric hand scanner to evaluate bone age. In another study, textural features of wrist image were studied on MRI to determine the bone age. These features were found to be highly correlated with the actual bone age.⁴⁹ Sports Authority of India has incorporated MRI for bone age estimation in select cases. This modality does not increase radiation dose in contrast to radiographs or computed tomography and can be used for

problem solving in cases with equivocal findings. Developmental stages of clavicle have been described by MRI on 1.5 Tesla and 3 Tesla.^{50,51} MRI has been used either as solitary modality or in combination with X-ray or ultrasound for estimation of bone age.^{52–54} Dedouit classification and Saint-Martin classification have been used for most of the MRI-based bone age estimation where either ossification of radial and ulnar distal epiphysis or proximal humeral epiphysis was studied to determine the age of majority.^{55,56} MRI knee joint has also been studied to evaluate the ossification center at distal femoral and proximal tibial epiphyses, either separately or in combination. These studies were based on either Dedouit or Schmeling–Kellinghaus classification systems.^{57–61} Ankle joint MRI for evaluation of distal tibial epiphysis and/or calcaneum has also been reported for age estimation.^{62–64} A comparative study by Lopatin et al showed that irrespective of demographics and imaging modality, the development rates and age of beginning and ending of ossification show certain trends.⁶⁵ Evaluation of knee MRI for age estimation can be done by area ratio index (ARI) that is the ratio between the surface of the growth plate closure and the lower part of the femur under the growth plate closure. Being an objective parameter, ARI can be an effective and efficient tool for strengthening bone age estimation by artificial intelligence (AI).⁶⁶

Role of Artificial Intelligence

AI has revolutionary potential in terms of maintaining the quality of healthcare while assisting the medical professionals with their workload. AI assistance has been observed to be more accurate with lesser interpretation time in contrast to nonassisted interpretation by radiologists.⁶⁷ BoneXpert is the most commonly used AI-based software using feature extraction techniques. The left-hand radiograph is analyzed by the software based on 13 bones. After processing, the bone age is determined by Greulich-Pyle or TW method and is transferred to PACS (Picture Archiving and Communication system). BoneXpert derived bone age has been seen to be more accurate and efficient as compared with manual derivation. However, the efficacy is reduced in cases when less than eight bones are included, poor image quality or bone morphology abnormality.⁶⁸ Consistent version upgrading needs to be done to overcome the limitations.

VUNO Med-BoneAge is another AI-based bone age tool trained on left-hand radiographs and using GP method. It is a semiautomatic system based on deep learning model where the system generates first-rank, second-rank, and third-rank estimated bone ages with increased accuracy upon combining the three bone ages. Finally, the reader has to choose among the bone-age results based on the images suggested, thus, reducing the time of interpretation as compared with manual bone age estimation.⁶⁹

Another fully automated system is HH-boneage.io based on localization of epiphysis–metaphysis growth areas of 13 bones in wrist radiograph. Regions of interest of those 13 bones are determined and maturity score is calculated. Subsequently,

the total score is calculated and bone age is predicted using a correlation matrix.⁷⁰ MediAI-BA system is another AI-based software for bone age assessment. It analyzes seven epiphysis–metaphysis growth regions in the ulna, radius, metacarpal of the first finger and metacarpal and all three phalanges of the third finger.⁷¹ Determination of bone age can also be done from pelvis, knee radiographs, or from MRI. However, more research is to be done in this field to improve accuracy and applicability in different demographics.

Since bone age varies with ethnicity and gender, large multicentric studies are needed to be done in different demographics. Besides, the current AI-based tools including BoneXpert, VUNO Med-BoneAge, HH-boneage.io solution, and MediAI-BA solution are based solely on left-hand radiographs that might increase the potential of error in specific age groups. Recently, a study showed better prediction of bone age by AI as compared with general radiologist in terms of mean absolute error, sensitivity, correlation, interpretation time, and bias.⁷² Despite the apprehension and misconception among general population, the role of AI is more of an efficient assistant rather than human replacement.

Conclusion

Radiographic ossification test forms one of the important pillar of forensic age estimation of living individuals. While wrist and hand X-rays are the most commonly performed radiographic investigation, it solely would not be adequate for all relevant categories; other parts like elbow, shoulder, knee, pelvis, and skull are also imaged as per corresponding age categories. In this article, we provide a roadmap of the most apt radiographic tests to be performed for various age categories and principles of the interpretation and age estimation using the same.

Conflict of Interest

None declared.

References

- 1 Parikh CK. Parikh's Textbook of Medical Jurisprudence, Forensic Medicine and Toxicology, for Classrooms and Courtrooms. 6th ed. C. B. S.; 2007
- 2 Greulich WW, Pyle SI. Radiographic Atlas of Skeletal Development of the Hand and Wrist. Stanford: Stanford University Press 1959: 272
- 3 Tanner JM, Whitehouse RH, Cameron N, Marshall WA, Healy MJ, Goldstein H. Assessment of Skeletal Maturity and Prediction of Adult Height (TW2 method). London: Academic Press; 1983
- 4 Tanner J, Oshman D, Bahhage F, Healy M. Tanner-Whitehouse bone age reference values for North American children. *J Pediatr* 1997;131(1 Pt 1):34–40
- 5 Schmeling A, Geserick G, Reisinger W, Olze A. Age estimation. *Forensic Sci Int* 2007;165(2-3):178–181
- 6 Schmeling A, Reisinger W, Loreck D, Vendura K, Markus W, Geserick G. Effects of ethnicity on skeletal maturation: consequences for forensic age estimations. *Int J Legal Med* 2000;113 (05):253–258
- 7 Roche AF, Roberts J, Hamill PV. Skeletal maturity of youths 12–17 years racial, geographic area, and socioeconomic differentials. United States, 1966–1970. *Vital Health Stat* 11 1978;(167):1–98

- 8 Modi R. A Textbook of Medical Jurisprudence and Toxicology. In: 6th ed. Bombay 1940:32–45
- 9 Pinchi V, De Luca F, Ricciardi F, et al. Skeletal age estimation for forensic purposes: a comparison of GP, TW2 and TW3 methods on an Italian sample. *Forensic Sci Int* 2014;238:83–90
- 10 Reddy KSN. The Essentials of Forensic Medicine and Toxicology. In: 32nd ed. Hyderabad: Om Sai Graphics 2013:61–62
- 11 Shah N, Khadilkar V, Lohiya N, et al. Comparison of bone age assessments by Gruelich-Pyle, Gilsanz-Ratib, and Tanner Whitehouse methods in healthy Indian children. *Indian J Endocrinol Metab* 2021;25(03):240–246
- 12 Behera CK, Rath R, Das SN, Sahu G, Sharma G, Bhatta A. Correlation of skeletal age by Greulich-Pyle atlas, physiological age by body development index, and dental age by London Atlas and modified Demirjian's technique in children and adolescents of an Eastern Indian population. *Egypt J Forensic Sci* 2023;13(01):40
- 13 Tanner JM, Healy MJR, Goldstein H, Cameron N. Assessment of Skeletal Maturity and Prediction of Adult Height (TW3 method). 3rd edition London, UK: Saunders; 2001
- 14 Gilsanz V, Ratib O. Hand Bone Age: A Digital Atlas of Skeletal Maturity. Springer; 2011
- 15 Smt. Meenakshi and Another vs the State of U.P. 2020
- 16 Jones VF, High PC, Donoghue E, et al; Committee On Early Childhood, Adoption, And Dependent Care. Comprehensive health evaluation of the newly adopted child. *Pediatrics* 2012; 129(01):e214–e223
- 17 Convention on the Rights of the Child. United Nations, New York 1989
- 18 Committee on the Rights of the Child. United Nations, Geneva 2007
- 19 Buckberry JL, Chamberlain AT. Age estimation from the auricular surface of the ilium: a revised method. *Am J Phys Anthropol* 2002; 119(03):231–239
- 20 Priyambhai Bipinbhai Mehta v. The State Of Gujarat. 2009.
- 21 Hacquebord JH, Leopold SS. In brief: The Risser classification: a classic tool for the clinician treating adolescent idiopathic scoliosis. *Clin Orthop Relat Res* 2012;470(08):2335–2338
- 22 Kanchal Lal Juvenile vs State of U.P. & Another. 2015
- 23 Rockwood C, Beaty J, Kasser J. Rockwood and Wilkins' Fractures in Children. 6th edition Philadelphia, PA: Lippincott Williams & Wilkins; 2005
- 24 Eich GF, Babyn P, Giedion A. Pediatric pelvis: radiographic appearance in various congenital disorders. *Radiographics* 1992;12(03):467–484
- 25 Zember JS, Rosenberg ZS, Kwong S, Kothary SP, Bedoya MA. Normal skeletal maturation and imaging pitfalls in the pediatric shoulder. *Radiographics* 2015;35(04):1108–1122
- 26 M Mohamed Abbas v. The Chief Secretary. 2015
- 27 Pradeep Kumar Bhardwaj v. The State of UP. 1998
- 28 Kishan Dashrath Tambile and Another v. The State of Maharashtra and Another. 2021
- 29 Babloo v. State. 2011.
- 30 Cunningham C, Scheuer L, Black S. Developmental Juvenile Osteology. San Diego, CA: Academic Press; 2000
- 31 Kellinghaus M, Schulz R, Vieth V, Schmidt S, Pfeiffer H, Schmeling A. Enhanced possibilities to make statements on the ossification status of the medial clavicular epiphysis using an amplified staging scheme in evaluating thin-slice CT scans. *Int J Legal Med* 2010;124(04):321–325
- 32 Rami Bai v. Life Insurance Corporation of India. 1980.
- 33 Mukherjee JB, Karmakar RNJB. Mukherjee's Forensic Medicine and Toxicology. In: 3rd ed. Kolkata: Academic Publishers; 2007: 156–157
- 34 Sahni D, Jit I, Neelam , Sanjeev. Time of closure of cranial sutures in northwest Indian adults. *Forensic Sci Int* 2005;148(2-3):199–205
- 35 Jayaraman J. Dental age estimation in India: do we have a role beyond publishing scientific evidences? *J Forensic Dent Sci* 2018; 10(01):55–57
- 36 Demirjian A, Goldstein H, Tanner JM. A new system of dental age assessment. *Hum Biol* 1973;45(02):211–227
- 37 Bajpai A. Who is a child? *Cent Commun Dev Stud.* 2007;(08):8–11
- 38 Santoro V, De Donno A, Marrone M, Campobasso CP, Introna F. Forensic age estimation of living individuals: a retrospective analysis. *Forensic Sci Int* 2009;193(1-3):129.e1–129.e4
- 39 Shimura N, Koyama S, Arisaka O, Imataka M, Sato K, Matsuura M. Assessment of measurement of children's bone age ultrasonically with sunlight bone age. *Clin Pediatr Endocrinol* 2005;14(24): 17–20
- 40 Khan KM, Miller BS, Hoggard E, Somani A, Sarafoglou K. Application of ultrasound for bone age estimation in clinical practice. *J Pediatr* 2009;154(02):243–247
- 41 Tanner JM, Gibbons RD. Automatic bone age measurement using computerized image analysis. *J Pediatr Endocrinol Metab* 1994;7(02):141–145
- 42 Drayer NM, Cox LA. Assessment of bone ages by the Tanner-Whitehouse method using a computer-aided system. *Acta Paediatr Suppl* 1994;406(s406):77–80
- 43 Tanner JM, Oshman D, Lindgren G, Grunbaum JA, Elsouki R, Labarthe D. Reliability and validity of computer-assisted estimates of Tanner-Whitehouse skeletal maturity (CASAS): comparison with the manual method. *Horm Res* 1994;42(06):288–294
- 44 Frisch H, Riedl S, Waldhör T. Computer-aided estimation of skeletal age and comparison with bone age evaluations by the method of Greulich-Pyle and Tanner-Whitehouse. *Pediatr Radiol* 1996;26(03):226–231
- 45 Schmeling A, Grundmann C, Fuhrmann A, et al. Criteria for age estimation in living individuals. *Int J Legal Med* 2008;122(06): 457–460
- 46 European Commission Joint Research Centre. Medical age assessment of juvenile migrants. [Internet]. LU: Publications Office; 2018 [cited 2023 Sep 28]. Available at: <https://data.europa.eu/doi/10.2760/47096>
- 47 Terada Y, Kono S, Tamada D, et al. Skeletal age assessment in children using an open compact MRI system. *Magn Reson Med* 2013;69(06):1697–1702
- 48 Terada Y, Kono S, Uchiumi T, et al. Improved reliability in skeletal age assessment using a pediatric hand MR scanner with a 0.3T permanent magnet. *Magn Reson Med Sci* 2014;13(03):215–219
- 49 Obuchowicz R, Nurzynska K, Pierzchala M, Piorowski A, Strzelecki M. Texture analysis for the bone age assessment from MRI images of adolescent wrists in boys. *J Clin Med* 2023;12(08):2762
- 50 Schmidt S, Mühler M, Schmeling A, Reisinger W, Schulz R. Magnetic resonance imaging of the clavicular ossification. *Int J Legal Med* 2007;121(04):321–324
- 51 Hillewig E, De Tobel J, Cuche O, Vandemaele P, Piette M, Verstraete K. Magnetic resonance imaging of the medial extremity of the clavicle in forensic bone age determination: a new four-minute approach. *Eur Radiol* 2011;21(04):757–767
- 52 De Tobel J, Bauwens J, Parmentier GIL, et al. Magnetic resonance imaging for forensic age estimation in living children and young adults: a systematic review. *Pediatr Radiol* 2020;50(12):1691–1708
- 53 Möbius D, Fitzek A, Hammer N, et al. Ultrasound in legal medicine- a missed opportunity or simply too late? A narrative review of ultrasonic applications in forensic contexts. *Int J Legal Med* 2021;135(06):2363–2383
- 54 Herrmann J, Säring D, Auf der Mauer M, Groth M, Jopp-van Well E. Forensic age assessment of the knee: proposal of a new classification system using two-dimensional ultrasound volumes and comparison to MRI. *Eur Radiol* 2021;31(05):3237–3247
- 55 Ekizoglu O, Er A, Bozdog M, Moghaddam N, Grabherr S. Forensic age estimation based on fast spin-echo proton density (FSE PD)-weighted MRI of the distal radial epiphysis. *Int J Legal Med* 2021; 135(04):1611–1616
- 56 Serin J, Rérolle C, Puchoux J, et al. Contribution of magnetic resonance imaging of the wrist and hand to forensic age assessment. *Int J Legal Med* 2016;130(04):1121–1128

- 57 Uygun B, Kaya K, Köse S, Ekizoğlu O, Hilal A. Applicability of magnetic resonance imaging of the knee in forensic age estimation. *Am J Forensic Med Pathol* 2021;42(02):147–154
- 58 Ottow C, Schulz R, Pfeiffer H, Heindel W, Schmeling A, Vieth V. Forensic age estimation by magnetic resonance imaging of the knee: the definite relevance in bony fusion of the distal femoral and the proximal tibial epiphyses using closest-to-bone T1 TSE sequence. *Eur Radiol* 2017;27(12):5041–5048
- 59 Ekizoglu O, Hocaoglu E, Inci E, Can IO, Aksoy S, Kazimoglu C. Forensic age estimation via 3-T magnetic resonance imaging of ossification of the proximal tibial and distal femoral epiphyses: use of a T2-weighted fast spin-echo technique. *Forensic Sci Int* 2016;260:102.e1–102.e7
- 60 Vieth V, Schulz R, Heindel W, et al. Forensic age assessment by 3.0T MRI of the knee: proposal of a new MRI classification of ossification stages. *Eur Radiol* 2018;28(08):3255–3262
- 61 Dedouit F, Auriol J, Rousseau H, Rougé D, Crubézy E, Telmon N. Age assessment by magnetic resonance imaging of the knee: a preliminary study. *Forensic Sci Int* 2012;217(1-3):232.e1–232.e7
- 62 Saint-Martin P, Rérolle C, Dedouit F, et al. Age estimation by magnetic resonance imaging of the distal tibial epiphysis and the calcaneum. *Int J Legal Med* 2013;127(05):1023–1030
- 63 Lu T, Shi L, Zhan MJ, et al. Age estimation based on magnetic resonance imaging of the ankle joint in a modern Chinese Han population. *Int J Legal Med* 2020;134(05):1843–1852
- 64 Ekizoglu O, Hocaoglu E, Can IO, Inci E, Aksoy S, Bilgili MG. Magnetic resonance imaging of distal tibia and calcaneus for forensic age estimation in living individuals. *Int J Legal Med* 2015;129(04):825–831
- 65 Lopatin O, Barszcz M, Bolechala F, Wozniak KJ. The fusion of ossification centers - a comparative review of radiographic and other imaging modalities of age assessment in living groups of children, adolescents, and young adults. *Leg Med (Tokyo)* 2023; 61:102185
- 66 Matijaš T, Pinjuh A, Dolić K, et al. Improving the age estimation efficiency by calculation of the area ratio index using semi-automatic segmentation of knee MRI images. *Biomedicines* 2023;11(07):2046
- 67 Lee BD, Lee MS. Automated bone age assessment using artificial intelligence: the future of bone age assessment. *Korean J Radiol* 2021;22(05):792–800
- 68 Booz C, Yel I, Wichmann JL, et al. Artificial intelligence in bone age assessment: accuracy and efficiency of a novel fully automated algorithm compared to the Greulich-Pyle method. *Eur Radiol Exp* 2020;4(01):6
- 69 Kim JR, Shim WH, Yoon HM, et al. Computerized bone age estimation using deep learning based program: evaluation of the accuracy and efficiency. *Am J Roentgenol* 2017;209(06): 1374–1380
- 70 Son SJ, Song Y, Kim N, et al. TW3-based fully automated bone age assessment system using deep neural networks. *IEEE Access* 2019;7:33346–33358
- 71 Bui TD, Lee JJ, Shin J. Incorporated region detection and classification using deep convolutional networks for bone age assessment. *Artif Intell Med* 2019;97:1–8
- 72 Nguyen T, Hermann AL, Ventre J, et al. High performance for bone age estimation with an artificial intelligence solution. *Diagn Interv Imaging* 2023;104(7-8):330–336