

Nonadherence of Polyurethane Implants: A Retrospective Cohort Study

Dmitry Batiukov¹ Vladimir Podgaiski²

¹Medical Center "Antes Med", Minsk, Belarus

²Belorussian Medical Academy for Postgraduate Education, Minsk, Belarus

Address for correspondence Dmitry Batiukov, Medical Center "Antes Med": Kozlova Lane 25-6, Minsk, 220037, Belarus (e-mail: Dmitry.batiukov@gmail.com).

Indian J Plast Surg 2024;57:24–30.

Abstract

Background Biointegration of polyurethane (PU) implants providing their stable position years after surgery ensures predictable results of breast augmentation and reconstruction almost eliminating implant factor as a cause of complications. However, in rare cases PU implants appear to be not connected to the surrounding tissues. The aim of the study was to determine the incidence of PU implant nonadherence after primary breast augmentations and augmentation mastopexies with dual plane implant position, to analyze possible causes, and to propose preventive measures and treatment possibilities of this complication.

Methods The results of primary aesthetic surgeries in 333 patients with dual plane PU implant placement were analyzed. Patients were evaluated clinically, and pictures and videos taken in different periods after the surgery were compared. Particular attention was given to the changes in implant position and the appearance of asymmetries over time.

Results PU implant nonadherence was found in seven patients. It can be divided into primary and secondary and may be complete or partial. Primary nonadherence was found in two cases (0.6%), and secondary in five (1.5%) cases. Possible influencing factors could have been traumatic surgical technique, seroma, hematoma, or physical trauma. The average follow-up was 33 months (1 month–15 years).

Conclusion Biointegration is mandatory for the long-term predictable results with PU implants. PU implant nonadherence leads to implant malposition and may cause typical complications connected to non-PU implants. Improvements in surgical maneuvers, manufacturing process, and weight reduction of the implant may be beneficial for the stability of the results.

Level of Evidence V

Keywords

- ▶ polyurethane implants
- ▶ malposition
- ▶ biointegration
- ▶ late seroma
- ▶ capsular contracture
- ▶ rotation

Introduction

Polyurethane (PU) implants represent a distinct variety of implants produced by the attachment of the PU foam on the core silicone implant. Collagen fibers growing inside the

foam encapsulate PU struts creating the three-dimensional net that firmly stabilizes the implant in its position. This process is called biointegration and lasts to 6 to 12 months.¹ After the biointegration is complete, the implant remains connected to the surrounding tissues that has a number of

article published online
January 19, 2024

DOI <https://doi.org/10.1055/s-0043-1778644>.
ISSN 0970-0358.

© 2024. Association of Plastic Surgeons of India. All rights reserved. This is an open access article published by Thieme under the terms of the Creative Commons Attribution-NonDerivative-NonCommercial-License, permitting copying and reproduction so long as the original work is given appropriate credit. Contents may not be used for commercial purposes, or adapted, remixed, transformed or built upon. (<https://creativecommons.org/licenses/by-nc-nd/4.0/>)
Thieme Medical and Scientific Publishers Pvt. Ltd., A-12, 2nd Floor, Sector 2, Noida-201301 UP, India

advantages comparing to other types of implants. First, no type of implant malposition (including rotation) is possible. Second, chaotic directions of the collagen fibers ensure very low capsular contracture rate even decades after the surgery.^{1–4} Third, complete biointegration ensures that no space exists between the implant and the surrounding tissues; therefore, shell shedding of particulates and friction that are among the possible causes of breast implant-associated anaplastic large-cell lymphoma (BIA-ALCL) are not an issue.⁵ However, in some rare cases PU implants are found not to be connected to the surrounding tissues. Nonadherence is called primary if the connection did not exist from the very beginning and secondary if it existed but was lost with time. In this article, we discuss potential causes, classification, and treatment options of this condition.

Materials and Methods

Three-hundred thirty-three patients were included in the study. All surgeries were performed by the senior author. The inclusion criteria were primary surgery, augmentation or augmentation-mastopexy, dual plane technique, no simultaneous surgeries on other parts of the body and no other concomitant procedures on the breast, which could theoretically hinder biointegration (fat grafting, liposuction, etc.), and no secondary procedures on the breast during follow-up period. The last show up of the patient when the consistent photographs for the analysis were taken was considered to be the end of the follow-up period independent of the time passed from the date of the surgery and other follow-up visits. Patients with the minimum follow-up of 1 month were included in the study not to skip a single patient with primary nonadherence. The drains were used in all cases and compression garments were applied for 1 month continuously followed by 2 months for physical activity. The patients were advised to refrain from physical activity for 1 month and for exercises involving pectoralis major muscle for another 2 months. If possible, patients

were followed up at 1, 3, 6, 12 months and annually thereafter. Patients were evaluated clinically and the pictures and videos taken in different periods after the surgery were compared.

Results

We observed nonadherence of PU implants in seven patients (► **Table 1**). Primary nonadherence was found in two cases, while secondary nonadherence in five cases. Both cases of primary nonadherence occurred after breast augmentation with transglandular periareolar approach. Both patients described that there was continuous lowering of the implant during the first few months after the surgery with the asymmetry becoming more and more pronounced. Glandular scoring was performed in one of those cases. Small hematoma that we treated conservatively occurred on the affected side in another. In five cases of secondary nonadherence, two cases were after breast augmentation, and three after augmentation and mastopexy. All the patients with secondary nonadherence distinctly remember the day when this occurred. In three cases, areolar approach with gland transection was chosen, and in two cases submammary approach was used. In two cases unfurling of the gland was performed, in one case implant nonadherence occurred after trauma, and in one case seroma appeared after 4 years that resulted in nonadherence in few weeks.

The average follow-up period was 33 months (1 month--15 years). The structure of the follow-up visits is presented in ► **Table 2**.

The probability of primary and secondary implant nonadherence in our series was 0.6 and 1.5%, respectively.

Discussion

Nonadherence of the PU implants was first mentioned in 2018 describing various patterns of PU implant removal.⁶ In this article, we define this complication in detail.

Table 1 Clinical characteristics of the patients with PU implant nonadherence

Patient	Previous interventions	Incisions	Last intervention	Type of nonadherence	Time of nonadherence	Possible factor
J	No	Infraareolar	Breast augmentation	Primary	Shortly after surgery	Small hematoma postop
K	No	Infraareolar	Breast augmentation	Primary	Shortly after surgery	Glandular scoring
P	No	Periareolar	Breast augmentation and mastopexy	Secondary	After 1 year	Unfurling of the gland
A	No	Submammary	Breast augmentation	Secondary	4 years	Seroma 4 years after
I	No	Infraareolar	Breast augmentation	Secondary	After 1 year	No
M	No	Submammary	Breast augmentation	Secondary	5 years	Trauma
Pd	No	Periareolar	Breast augmentation and mastopexy	Secondary	5 years	Unfurling of the gland

Abbreviation: PU, polyurethane.

Table 2 Structure of the followed up patients

Follow-up period	No of patients with the last documented visit	No of followed up patients	No of secondary nonadherences to this date	No of primary nonadherences
1–3 months	37	333	0	2
3–6 months	40	296	0	
6–12 months	37	256	0	
1–3 years	87	219	2	
3–5 years	50	132	1	
5–8 years	71	82	2	
8–10 years	9	11	0	
10+ years	2	2	0	

According to the pathogenesis, *nonadherence* can be divided on *primary* and *secondary* and may be *complete* (no areas of adherence remain) or *partial* (some areas of adherence are still present). In *primary nonadherence*, no sufficient biointegration occurs from the very beginning; thus, the implant behaves like any other type of implant. Typical clinical picture of this condition includes continuous infra-mammary (IMF) lowering and N-IMF lengthening. As primary nonadherence is a very rare condition, it is expected to be found unilaterally; thus, the other clinical sign is growing asymmetry between the breast where biointegration occurs properly and where it does not (►Fig. 1). The nonadhered PU implant moves freely inside the pocket and migrates laterally while supine, mimicking typical lateral implant malposition with non-PU implants (►Videos 1, 2). Some authors might

have witnessed the state of the primary nonadherence without naming it: they found PU on the implant years after implant insertion. However, they did not describe any consequences of this findings.^{3,7}

Video 1

Primary polyurethane implant nonadherence on the left side. Difference in implant position and movement. Patient is in vertical position. Online content including video sequences viewable at: <https://www.thieme-connect.com/products/ejournals/html/10.1055/s-0043-1778644>.

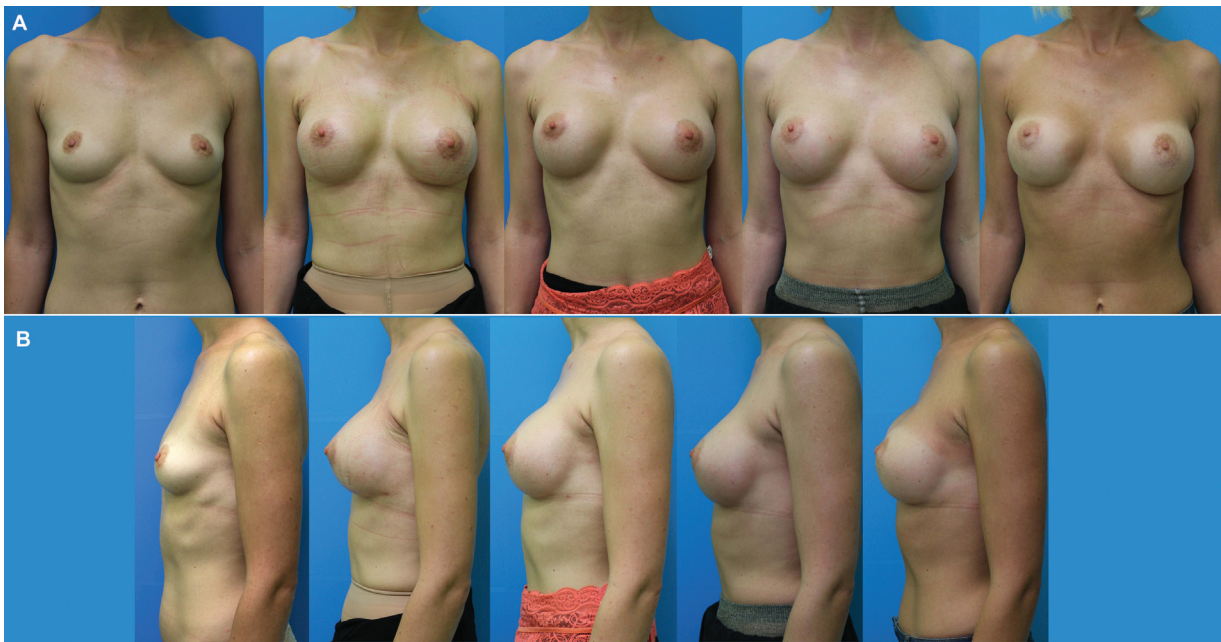

Fig. 1 (A, B) Primary nonadherence of polyurethane (PU) implants on the left side. Dynamics at 1, 3, 6, and 12 months after breast augmentation with PU implants.

Video 2

Primary implant nonadherence. Lateral implant malposition. Patient is supine. Online content including video sequences viewable at: <https://www.thieme-connect.com/products/ejournals/html/10.1055/s-0043-1778644>.

Meanwhile, complete biointegration is an ultimate goal of any PU implant surgery. Biointegration is possible if the implant is in stable and lasting connection to the surrounding tissues that have good vascularization and ability to produce collagen. The factors that interfere with it include traumatic technique, infection, fluid collection, impaired vascularization, wide pocket, early mobility and were discussed in detail in recent publications.^{8,9}

Analyzing our cases of primary nonadherence, we noticed that in one case small hematoma on the left which we decided to treat conservatively was diagnosed shortly after the surgery (►Fig. 1). The presence of blood in the pocket disconnects the implant from the surrounding tissues thus preventing biointegration. We consider it the definite factor of primary nonadherence.

In case of successful biointegration, patients do not have implant-related complications many years after surgery. In some rare cases, the connection of the implant to the capsule is completely lost and implant becomes free in its movements inside the pocket. This is called *complete secondary nonadherence*. Unattached implant loads the lower pole of the breast. Clinical picture is characterized by a sudden appearance of the previously nonexistent asymmetry with

one implant found considerably lower than the other, NAC facing higher than it was and N-IMF distance lengthened (►Figs. 2, 3).

After successful biointegration, the loss of adherence is never a one-time event. We noticed from our experience with PU implant removals that the more time has passed after primary surgery, the more likely the anterior surface of the implant was found to be detached from the capsule (*partial secondary nonadherence*). However, there were no clinical signs of it, because the posterior surface remained connected. Anterior surface was also easier than posterior detached from the capsule intraoperatively due to the implant manufacturing process.⁶ We assume that if not existent from the very beginning as an area of partial primary nonadherence, a small initial area of the *partial secondary nonadherence* usually appears somewhere on the anterior surface of the implant mainly because of the never-ending physical influence due to gravity and movements. The less is the integration, the more is the strain on the still integrated parts of the implant. Small mutual movements occur between the nonintegrated parts of the implant and the capsule that may produce some fluid (►Video 3). Also, the heavier is the implant, the more is the strain on the bio-integrated parts of the implant. These factors combined with time may gradually help disrupting remaining connections until the state of the complete secondary nonadherence occurs (►Video 4). The diagnosis of complete PU implant nonadherence in dual plane cases is based on the examination of the patient and anamnesis and is very simple. It needs no additional investigations and was proven every time intraoperatively with more than 40 patients with PU implant removals for different reasons the majority of which were operated elsewhere and did not meet the inclusion criteria.

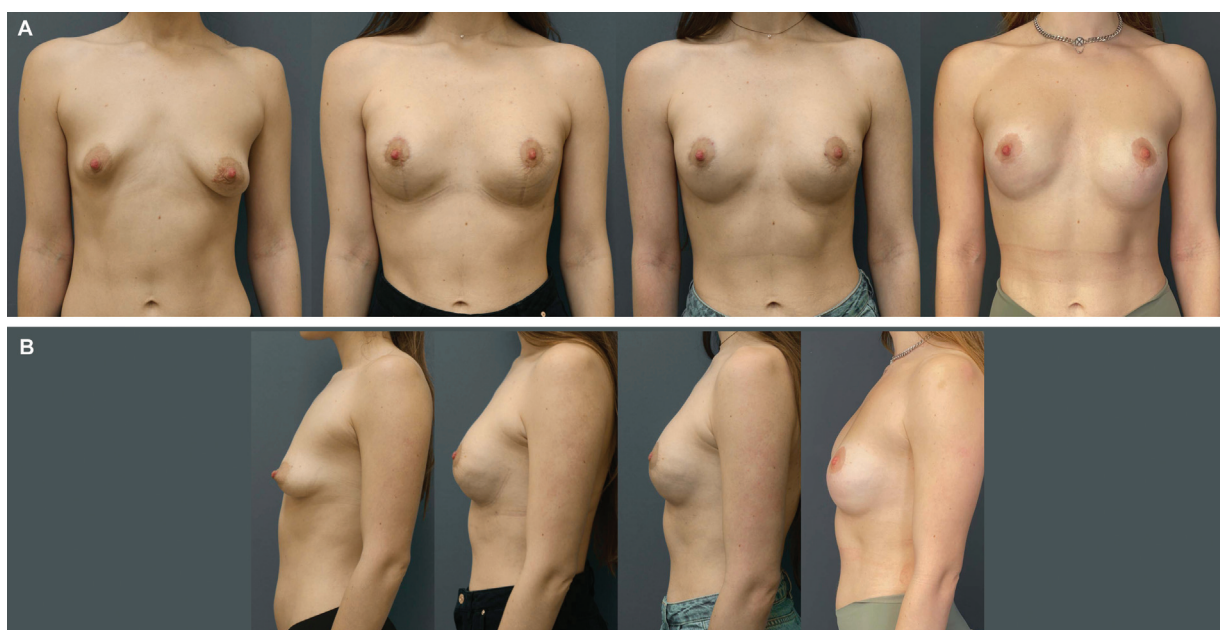


Fig. 2 (A, B) Secondary nonadherence of polyurethane (PU) implant on the left side. Dynamics at 3, 6 months, 2.5 years after breast augmentation with PU implants and mastopexy.

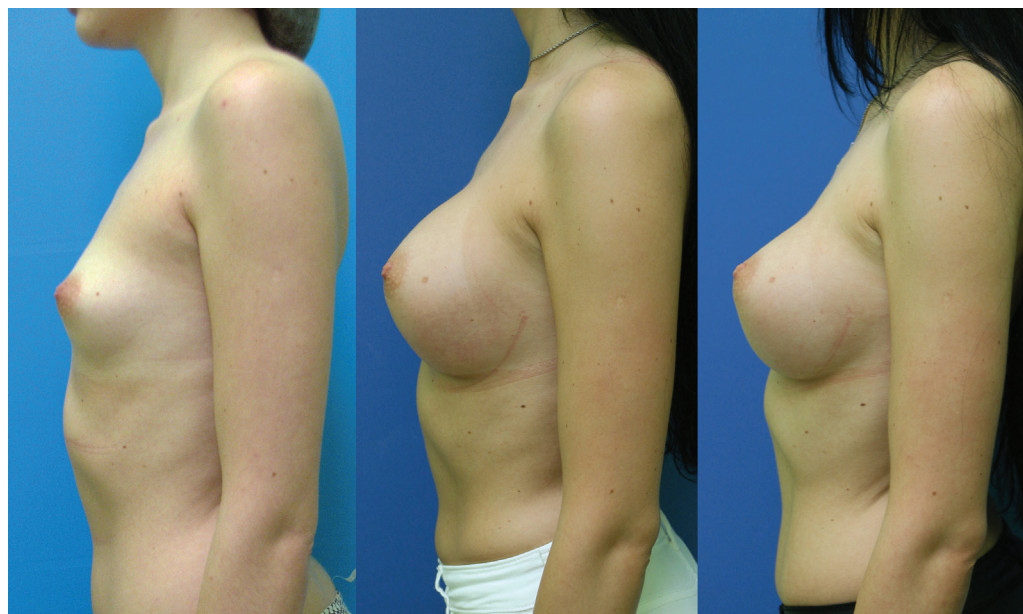

Fig. 3 Secondary nonadherence of polyurethane (PU) implant on the left side. Dynamics at 3 years, 7 months and 4 years after breast augmentation with PU implants.

Video 3

Late seroma (benign) 1.5 years after breast augmentation with polyurethane (PU) implants, partial secondary PU implant nonadherence. Online content including video sequences viewable at: <https://www.thieme-connect.com/products/ejournals/html/10.1055/s-0043-1778644>.

Video 4

Intraoperative video. Primary and secondary polyurethane implant nonadherence. Online content including video sequences viewable at: <https://www.thieme-connect.com/products/ejournals/html/10.1055/s-0043-1778644>.

At the moment complete secondary nonadherence takes place, the mobility of the implant increases tremendously and previously inexistent asymmetry and malposition of the implant appear. Our every patient diagnosed with complete secondary nonadherence recalled the exact time it happened.

In all of our five patients with secondary nonadherence, the problems began at least 1 year after the surgery. One patient directly named the reason, trauma, after which the implant lost its adherence to the capsule. One patient (→Fig. 3) came for the follow-up visit with seroma (BIA-ALCL was ruled out according to the established pro-

ocols) that resulted in nonadherence in a few months. In three patients, however, we did not find any reasonable factors.

Any factor that leads to instability of the connections between the implant and surrounding tissues may result in nonadherence. After thorough analysis of the details of the surgeries performed on the patients with PU implant nonadherence, we found that the common feature was the transection of the gland, either to form a pocket or to distribute the tissues of the lower pole (5 out of 7 patients), which corresponds to the frequency (68%) of the periareolar transglandular approach in the discussed group of patients.

In all of our cases, PU implants were put under the pectoralis major muscle. Greater degree of movements due to fixation of the implant not to the rib cage directly but to the muscle in prepectoral placement should result in more stable biointegration but produce similar although less obvious clinical picture in case of nonadherence. This is one of the reasons why nonadherence may be less common in prepectoral implant position and should be chosen if it does not compromise the aesthetic result.

The main direct consequence of PU implant nonadherence is malposition. Malposition is poorly defined in the literature. Non-PU implants do not have definite position in the body and change it considerably years after the surgery.^{10–12} These changes are not considered to be malposition until they are defined as a problem by the patient. Still malposition is one of the main indications for reoperations and its rate can reach 9 to 19% of the cases.^{13,14} This is the reason why numerous techniques to control non-PU implant position are published.^{15–18} With PU implants under the pectoralis, major muscle malposition as a consequence of complete nonadherence is a direct and very easy diagnosis. Still in our

experience, PU implant nonadherence was found in only 2.1% of cases with the average follow-up of 33 months with primary nonadherence occurring in 0.6% and secondary in 1.5% of cases that is far below any figures published in the literature about non-PU implants.

The diagnosis of PU implant nonadherence leads to several solutions. Generally, nonadhered PU implant behaves as a usual non-PU implant. Some patients may select to live with this condition accepting the asymmetry in breast appearance and mobility (all the patients included in the study refrained from surgery as opposed to the patients, not included in the study, in whom nonadherence occurred as a result of secondary surgery). However, mobility together with shell surface characteristics may be possible factors for BIA-ALCL development.⁵ Another consequence is the constant pressure which the implant exerts on the surrounding tissues because of gravity. Patients may feel pain and constant load of the lower pole of the breast that are quite disturbing, especially comparing to the contralateral side where the implant is stable.

Secondary adherence of a PU implant is not possible. In unilateral cases, nonadhered PU implant should be exchanged for a brand-new PU implant after capsulectomy. In bilateral cases or if the decision is made to exchange PU implants for non-PU, the usual tactic in secondary surgery with non-PU implants is implemented.

This study has several limitations. The average follow-up was 33 months. The longer PU implants are in the body, the more possible is the state of the nonadherence. On the other hand, taking into account the suddenness and obviousness of the clinical picture our practice showed that every patient with secondary nonadherence called the office just after nonadherence has taken place and described the typical clinical presentation. Some patients may have bilateral PU implant nonadherence (not seen by us), which may be not recognized by them as implants behave symmetrically. Our experience is based only on PU implants produced by Polytech (Germany). Silimed (Brazil) PU implants may have other particularities in biointegration and nonadherence processes due to manufacturing features.¹⁹ Only primary patients were included in the study. Previous surgeries may compromise tissues thus being a negative factor for biointegration. Despite of the large cohort of patients, we found only seven cases of PU implant nonadherence. This is a small number supporting high reliability of PU implants in the long term. From the other hand this number may be considered too small for final conclusions and recommendations. The average implant volume in patients with nonadherence was 288 mL (255–335 mL). The weight of the implant negatively correlates with the stability of biointegration. B-light implants were designed 30% lighter, so less force is applied to the surrounding tissues; thus more stable results are expected with regard to secondary malposition.²⁰

Possible future improvements in implant surface manufacturing that will help to avoid secondary nonadherence especially of the anterior surface of the implant will result in more predictable implant position.

Conclusion

The stability of the results with PU implants depends on their lasting adherence to the surrounding tissues. Absence of biointegration (primary nonadherence) or its loss (secondary nonadherence) results in uncontrolled position of the implant with possible complications due to weight, mobility, and surface characteristics of the implant.

Human and Animal Participants

This article does not contain any studies with human participants or animals performed by any of the authors.

Ethical Approval

The study was conducted according to the guiding principles of the Declaration of Helsinki.

Informed Consent

For this type of study, formal consent is not required.

Conflict of Interest

D. B. received a speaker honorarium from POLYTECH Health & Aesthetics. V. P. declares that he has no conflict of interest.

References

- 1 Fleming D, Handel M, Gutierrez J. Polyurethane foam covered breast implants. In: Peters W, Brandon H, Jerina KL, Wolf C, Young VL, eds. *Biomaterials in Plastic Surgery*. New York: Elsevier; 2012: 96–120
- 2 Vázquez G, Pellón A. Polyurethane-coated silicone gel breast implants used for 18 years. *Aesthetic Plast Surg* 2007;31(04): 330–336
- 3 Castel N, Soon-Sutton T, Deptula P, Flaherty A, Parsa FD. Polyurethane-coated breast implants revisited: a 30-year follow-up. *Arch Plast Surg* 2015;42(02):186–193
- 4 Duxbury PJ, Harvey JR. Systematic review of the effectiveness of polyurethane-coated compared with textured silicone implants in breast surgery. *J Plast Reconstr Aesthet Surg* 2016;69(04): 452–460
- 5 SCHEER (Scientific Committee on Health, Environmental and Emerging Risks), Scientific Opinion on the safety of breast implants in relation to anaplastic large cell lymphoma, 26 March 2021
- 6 Batiukov D, Podgaiski V, Ladutko D. Removal of polyurethane implants. *Aesthetic Plast Surg* 2019;43(01):70–75
- 7 Pompei S, Evangelidou D, Arelli F, Ferrante G. The modern polyurethane-coated implant in breast augmentation: long-term clinical experience. *Aesthet Surg J* 2016;36(10):1124–1129
- 8 Batiukov D, Podgaiski V, Ladutko D. Types of errors made during breast augmentation with polyurethane implants: a systematic review. *Aesthetic Plast Surg* 2020;44(01):70–79
- 9 Batiukov D, Podgaiski V, Ladutko D. Polyurethane implants in the era of BIA-ALCL: suggested improvements according to risk factors. *Aesthetic Plast Surg* 2022;46(02):995–998
- 10 Eder M, v Waldenfels F, Sichter mann M, et al. Three-dimensional evaluation of breast contour and volume changes following subpectoral augmentation mammoplasty over 6 months. *J Plast Reconstr Aesthet Surg* 2011;64(09):1152–1160
- 11 Kovacs L, Eder M, Zimmermann A, et al. Three-dimensional evaluation of breast augmentation and the influence of anatomic and round implants on operative breast shape changes. *Aesthetic Plast Surg* 2012;36(04):879–887

- 12 Lin F, Hong W, Zeng L, Kong X, Feng W, Luo S. A prospective study of breast morphological changes and the correlative factors after periareolar dual-plane augmentation mammoplasty with anatomic implant. *Aesthetic Plast Surg* 2020;44(06):1965–1976
- 13 Maxwell GP, Van Natta BW, Bengtson BP, Murphy DK. Ten-year results from the Natrelle 410 anatomical form-stable silicone breast implant core study. *Aesthet Surg J* 2015;35(02):145–155
- 14 Spear SL, Murphy DK, Slicton A, Walker PS, Inamed Silicone Breast Implant USInamed Silicone Breast Implant U.S. Study Group. Inamed silicone breast implant core study results at 6 years. *Plast Reconstr Surg* 2007;120(7, Suppl 1):8S–16S
- 15 Chopra K, Gowda AU, Kwon E, Eagan M, Grant Stevens W. Techniques to repair implant malposition after breast augmentation: a review. *Aesthet Surg J* 2016;36(06):660–671
- 16 Swanson E. Can we really control the inframammary fold (IMF) in breast augmentation? *Aesthet Surg J* 2016;36(10):NP313–NP314
- 17 Campbell CF, Small KH, Adams WP Jr. The inframammary fold (IMF) fixation suture: proactive control of the IMF in primary breast augmentation. *Aesthet Surg J* 2016;36(05):619–623
- 18 Stanizzi A, Tartaglione C. Use of Acellular Dermal Matrix (ADM) for the Correction of Breast Implant Malposition. In: Shiffman M, ed. *Breast Reconstruction*. Cham: Springer; 2016:1515–1529
- 19 Hamdi M. Association between breast implant-associated anaplastic large cell lymphoma (BIA-ALCL) risk and polyurethane breast implants: clinical evidence and european perspective. *Aesthet Surg J* 2019;39(Suppl 1):S49–S54
- 20 Govrin-Yehudain J, Dvir H, Preise D, Govrin-Yehudain O, Govreen-Segal D. Lightweight breast implants: a novel solution for breast augmentation and reconstruction mammoplasty. *Aesthet Surg J* 2015;35(08):965–971