

Original Article

Repair of distal hypospadias by the tubularised incised plate urethroplasty: A simple versatile technique

A. S. Bath, P. S. Bhandari, M. K. Mukherjee

Army Hospital (R & R), Delhi Cantt-110010.

Address for correspondence: Lt Col PS Bhandari, Plastic & Reconstructive Surgeon, Army Hospital (R & R) Delhi Cantt-110010.

ABSTRACT

Sixteen patients with distal hypospadias were treated by tubularised incised plate (TIP) repair as described by Snodgrass.¹ Coronal hypospadias constituted most of the cases (56.2%). Patient age ranged from 1.2 to 4 years. Complications occurred in two cases (12%). One patient developed urethrocutaneous fistula (6 %) and meatal stenosis (6 %) occurred in another case. Cosmetic and functional results were excellent in fourteen cases. TIP repair is the optimal technique for virgin cases of distal hypospadias.

KEY WORDS

Hypospadias, Tubularised incised plate urethroplasty.

INTRODUCTION

Hypospadias is a congenital defect resulting from incomplete tubularisation of the urethral plate. The meatus may be found any where along the penile shaft and down on to the perineum. In over 80% of cases the abnormal urethral opening is located distal to the midshaft.

The correct goal of hypospadias repair is a functional penis with a normal cosmetic appearance. Established procedures to correct the distal hypospadias are the Thiersch-Duplay, Mathieu, Mustarde, meatal advancement and glanuloplasty (MAGPI) and tubularized incised plate (TIP) urethroplasty. Of the various procedures Tip urethroplasty (Snodgrass repair) most reliably creates a normal appearing penis. At many centres it is now the preferred method of repair since it creates a vertical slit like normal appearing meatus,

unlike a horizontally oriented and rounded meatus ('Fish mouth') produced by the meatal based (Mathieu) and onlay island flap repairs. In addition this procedure allows construction of neourethra from the existing urethral plate without additional skin flaps. The technique is versatile and suitable for almost all distal lesions.

MATERIAL AND METHODS

Between Jul 1999 and Oct 2002, 16 Children with distal hypospadias underwent the TIP urethroplasty. The site of hypospadias is shown in Table 1 with coronal hypospadias being the most common (56.2%). Patient

Table 1: Sites of Hypospadias

Hypospadias Location	No of Cases	Percentage
Coronal	9	56.2%
Sub coronal	5	31.2%
Distal Shaft	2	12.5%

age ranged from 1.2 to 4 years (median 2.6 years). All reconstructions were performed under general anesthesia as per the technique described by Snodgrass^{1,2} (Figure 1). The penis was degloved with a U shaped incision extending along the edges of the urethral plate to healthy skin 2 mm proximal to the meatus. Artificial erection test was performed for chordee which if persisted after degloving, corrected by dorsal plication. In our series one patient required chordee correction by this method. The ventral glans was then infiltrated with 1:1,00000 epinephrine and the lateral borders of the distal urethral plate were separated from the glans by parallel longitudinal incisions. The glanular wings were further mobilized laterally for subsequent tension free closure. The urethral plate was then incised in midline from the hypospadiac meatus distally. Incised plate was then tubularised over a 6F stent using continuous subcuticular 6-0 chromic catgut suture. Neourethra was then covered with a vascularized dartos flap harvested from subcutaneous tissue of dorsal penile skin and preputial skin. The granular wings, mucosal collar and ventral shaft skin were closed in the midline. The stent provided urinary drainage for 10 days.

RESULTS

The cosmetic results were excellent in all patients. Follow up ranged from 3 to 24 months (mean 10 months). Each of the child voided with a well directed full stream (Figures 2 & 3).

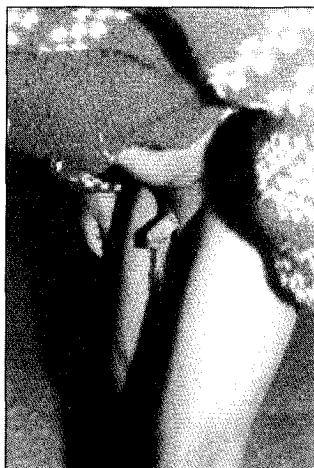

Figure 2: Preoperative photograph showing Subcornal hypospadias with chordee

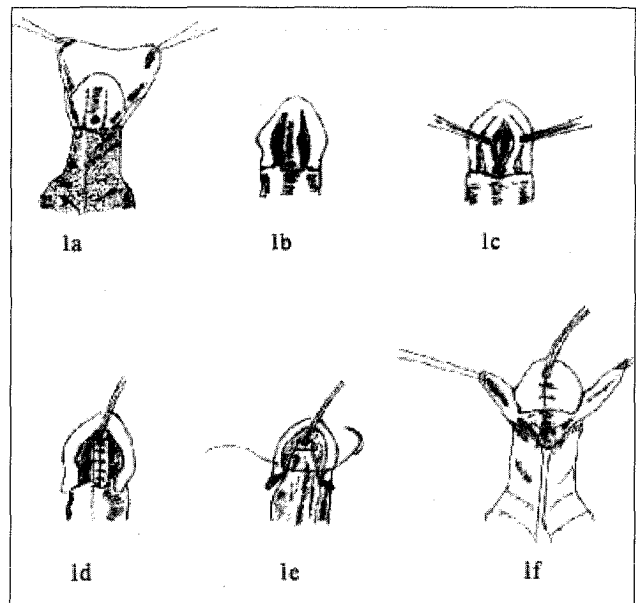


Figure 1: Tubularised Incised Plate Urethroplasty
 a) U shaped incision along the edges of the urethral plate. Penis degloved with a circumscribing incision.
 b) Urethral plate separated from the glanes.
 c) Dorsal midline relaxing incision.
 d) Incised plate tubularised over a 6 F stent.
 e) Water proofing with a dartos flap.
 f) Closure of glanular wings, mucosal collar and shaft skin.

Complications (Table 2) occurred in 2 of the 16 patients (12%). One patient developed urethrocutaneous fistula at coronal site, two weeks after the initial repair. It was subsequently closed by rotation of a local flap. Meatal stenosis occurred in one of the early cases in which incision was probably carried far distally in to the glans tissue. Snodgrass has emphasized not to incise beyond the end of urethral plate. If one incises

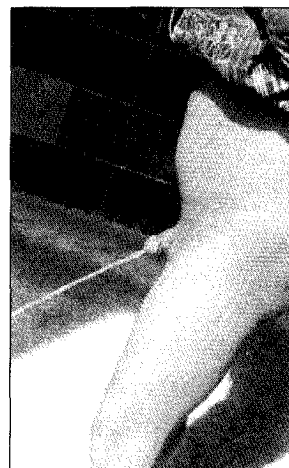


Figure 3: Postoperative photograph showing good cosmetic & functional results

Table 2: Complications of TIP plasty

Complications	No of Cases	Percentage
Urethrocutaneous fistula	1	6%
Meatal Stenosis	1	6%

in to glans beyond the plate, meatal narrowing is common because the incision in the glans tissue distal to the plate closes. Meatal stenosis was managed by urethral meatotomy. There were no cases of urethral stricture, stream abnormality or wound breakdown.

DISCUSSION

Hypospadias with an incidence of 0.8-8.2 per 1000 live male births is a common clinical problem.³ In the majority of cases abnormal meatus is situated in the glanular, coronal and subcoronal levels or in the distal part of the shaft. The goal of modern hypospadias surgery is a functionally and cosmetically normal penis. More than 200 methods have been introduced throughout the 125 years history of hypospadias repair. Many of the distal lesions were earlier repaired by meatal based flip flap procedure (the Mathieu procedure). Although this repair consistently produced a glanular meatus, the opening was often rounded, in contrast to the slit like appearance of a normal meatus. Rich et al introduced the principle of incising the urethral plate in the midline to improve the cosmesis of a hypospadias repair in 1989.⁴ In 1994 Snodgrass advanced this concept by extending the incision of the urethral plate from the meatus to the tip of the glans.¹ This maneuver allowed construction of a new urethra from the existing urethral plate. It was suggested that healing may occur through re-epithelialization of the relaxing incision without obvious scarring, allowing the incised edges to remain separated.⁵ Today TIP urethroplasty has become a preferred method for repairing distal hypospadias because of its versatility, to correct different meatal variants, the simplicity of the operative technique, low complication rate and reliable creation of a normal appearing glanular meatus.⁶ Since most of the patients with midshaft and penoscrotal defects have a supple urethral plate, a midline incision consistently widens the plate and enables tubularisation. This makes TIP plasty a versatile

technique in repairing the proximal hypospadias as well. There are two contraindications to TIP plasty - severe chordee requiring plate excision for straightening the penis and an unhealthy urethral plate that appears thin or is insufficiently widened after incision. Complications are rare. Fistula can be avoided by interposition of a vascularised dartos flap between the neourethra and overlying glans and shaft skin closures. Recently⁷ Cheng et al, have suggested a two layer closure of the neourethra to minimize the fistula rate. Closure of the first layer is done in a running subcuticular fashion with efforts made to invert the epithelium completely. The second layer incorporates the carefully preserved periurethral vascularized tissue.

Meatal stenosis is mostly the result of technical error; not confining the dorsal midline incision to the urethral plate. Other complications such as urethral stricture, diverticulum, wound breakdown are infrequent.

CONCLUSION

This study represents an experience with the tubularised incised plate urethroplasty in the management of distal hypospadias. With its simplicity, versatility, excellent cosmetic and functional results and a low complication rate, TIP urethroplasty is the procedure of choice for most of the distal defects.

REFERENCES

1. Snodgrass WT. Tubularised incised urethral plate urethroplasty for distal hypospadias. *J Urol* 1994;151:464-5.
2. Snodgrass WT. Tubularised incised plate hypospadias repair : Indications, technique and complications. *Urology* 1999;54:6-11.
3. Sweet RA, Schrott HG, Kurland R, Culp OS. Study of the incidence of hypospadias in Rochester, Minnesota 1940 - 70, and a case control comparison of possible etiologic factors. *Mayo Clin Proc* 1974;49:52-8.
4. Rich MA, Keating MA, Snyder H, Mc C III, Duckett JW. Hinging the urethral plate in hypospadias meatoplasty. *J Urol* 1989;142:1551-3.
5. Bleustein CB, Esposito MP, Soslow RA, et al. Mechanism of healing following the Snodgrass repair. *J Urol* 2001;165:277-9.
6. Snodgrass WT, Lorenzo A. Tubularised incised plate urethroplasty for proximal hypospadias. *BJU Int* 2002;89:90-3.
7. Cheng EY, Vemulapalli SN, Kropp BP, et al. Snodgrass hypospadias repair with vascularised dartos flap : The perfect repair for virgin cases of hypospadias ? *J Urol* 2002;168:1723-6.