



Mandibular Splint: Correction of Jaw Deviation following Hemimandibulectomy

Karna RK¹, Vijaykumar DK², Kanade RV³, Cherian T²

(Department of Occupational Therapy¹, Department of Surgical oncology² and Department of Physiotherapy³, Kasturba Medical College, Manipal 576 119, Karnataka, India)

Summary

Nineteen patients who underwent hemimandibulectomy with PMMC flap reconstruction as a part of the treatment for residual or recurrent oral cancer following radical radiotherapy participated in the study. Sixty eight percent of the patients were edentulous. The parameters measured during follow-up included the degree of correction of deviation, cosmetic appearance & patient satisfaction. Complete correction of jaw deviation was achieved in eight patients. In five patients, the deviation was partially corrected but the patients were not satisfied with the cosmetic appearance. In one case no change was observed. The mandibular splint was found to be a useful tool for the correction of jaw deviation following hemimandibulectomy, especially in edentulous patients.

Key words: Jaw deviation, Hemimandibulectomy, Mandibular Splint

Introduction

To rehabilitate the hemi-mandibulectomy patients, prevention and correction of mandibular deviation is essential. Several methods have been explained in this regard. Reconstructive surgery is recommended after hemimandibulectomy; but many patients are either not suitable candidates for it or not willing to subject themselves to multiple surgical procedures¹. Aramany² suggested intermaxillary fixation at the time of surgery, which may not be practical owing to the tension placed on the sutured tissues, which are used for closure of the defect and may not significantly prevent deviation after its removal. Use of guidance prosthesis or a guide flange is restricted to dentulous patients only^{3,4}. As majority of the patients are edentulous and have poor oral hygiene, this study was undertaken to evaluate the clinical

utility of the mandibular splint (an extraoral device) for the correction of jaw deviation following hemimandibulectomy.

Methods

From November 96 to May 98, nineteen patients were selected from Surgical Oncology department, who underwent wide excision with hemimandibulectomy and PMMC flap reconstruction for recurrent or residual oral cancer following radical radiotherapy and presented with facial disfigurement because of mandibular deviation towards the operated side. The patients were evaluated and followed up for at least a second visit after the first evaluation. The evaluation included physical examination of the wound, condition of the flap, jaw movement and occlusal alignment of the remaining mandible when the muscles around were relaxed.

The patient's mean age was 54 years (range 29 to 69 years). The mean post-operative time after which the splint was given to the patients was 26 days excluding the patient No 6, 13 & 17 (Table 1) for whom the period was 18, 6 & 8 months respectively. Seventy - three percent of the patients were male and sixty - eight percent of whole sample were edentulous. A summary of 19 patients evaluated is presented in table

1. All the patients were able to align the remaining mandible in correct position actively except patient No 6, 13 & 17 (Table 1) who had developed scar contracture. The extent of correction was measured as per the key described in table 1.

Splint Design

This is an extra oral splint, designed on the three-

Table 1. Summary of the 19 patients treated with the mandibular splint

Sl. No.	Age	Sex	Primary Site*	D/E*	Pre-orthotic Period (Weeks)	Degree of Correction**	Orthotic Period (weeks)	Follow up (Weeks)
1	60	M	Ca U Alv	D	4.28	3	32	24
2	58	M	Ca LAlv	E	5	2	36	20
3	64	M	Ca tongue	E	1.14	3	24	28
4	50	M	Ca tongue	E	2.14	1	32	32
5	41	M	Ca tongue	D	2.85	3	28	20
6	69	F	Ca L Alv	E	72	0	32	28
7	68	M	Ca BM	E	2.14	3	24	12
8	38	F	Ca LAlv	D	2.14	3	24	12
9	58	F	Ca BM	E	3	1	12	20
10	52	M	Ca tongue	E	3.14	3	32	16
11	66	M	Ca tongue	E	5.42	2	24	20
12	46	M	Ca tongue	D	2.57	2	16	24
13	29	M	Ca tongue	D	24	1	32	12
14	60	M	Ca BM	E	5.28	2	16	24
15	60	M	Ca tongue	E	4.28	3	32	28
16	62	M	Ca tongue	E	9.57	1	24	24
17	55	F	Ca tongue	D	30	1	16	20
18	55	M	Ca Bm	E	2.85	2	32	16
19	65	F	Ca tongue	E	2.57	3	24	16

*L=>Lower E=>Edentulous Alv=>Alveolus U=>Upper D=>Dentulous BM=>Buccal Mucosa

**Degree of correction: 0 - No correction, 1 - Partially corrected, Facial asymmetry noticeable, 2 - Partially Corrected, Facial asymmetry not noticeable and 3 - Completely corrected. No facial asymmetry; complete centric occlusion

point pressure principle. The three pressure points correspond to the stump of mandible after resection, zygomatic arch of the un-operated side and temporal bone of the operated side. The splint is made up of 1.5mm spring wire and 2mm Orthoplast (Fig 1 & 2). Orthoplast is used to make zygomatic and mandibular supports. Overhead harness is required to hold the splint on the face. This can be made with cotton straps or cotton threads of 3 mm diameter. A Velcro loop is attached to the overhead harness, which connects

to mandibular supports after donning the splint. Zygomatic and mandibular supports are padded to decrease the discomfort (Fig 3 & 4). The splint with single mandibular support (Fig 2 & 4) often slides off and it anchors well only when the mandibular stump is long (well beyond midline). In cases with mandible removed up to midline or more, the single mandibular support has poor anchorage and hence such patients had a splint with double Mandibular support (Fig 1 & 3).

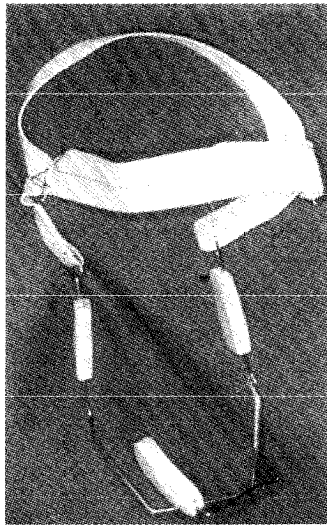


Fig 1. Mandibular splint with double maxillary support

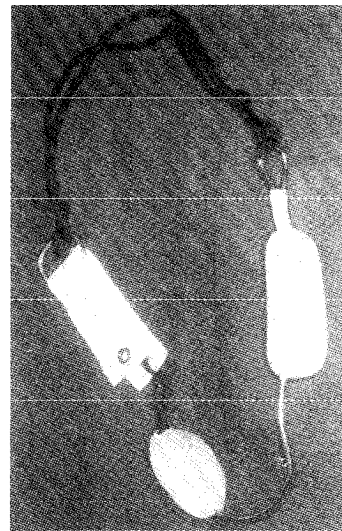


Fig 2. Mandibular splint with single maxillary support



Fig 3. Patient with the splint shown in fig 1

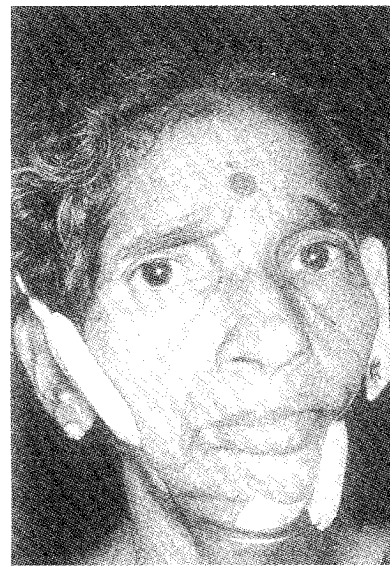

Fig 4. Patient with the splint shown in fig 2

Results

In 8 patients deviation was completely corrected. In 5 patients though the deviation was only partially corrected, they expressed subjective feeling of improved cosmesis and jaw control. In other five patients the deviation was partially corrected but the facial disfigurement was grossly noticeable. In one patient there was no change in deviation and cosmesis after treatment with the splint. Four patients (patient number 3,4,5,9 in table 1) developed pressure necrosis over the mandibular and zygomatic pressure points and had to discontinue using the splint temporarily. The splint allows movement of the jaw in the upward and downward directions without imposing any resistance, so it does not affect speech. But chewing food requires movement in the transverse plane also and the mandibular support resists the medial movement. Hence, patients were instructed to take off the splint while eating.

Compliance with the use of the splint varied: 3 patients (patient number 12, 14, 17 in table 1) stopped using the splint after the first 4 weeks with no particular reason except that one patient (patient number 17 in table 1) found the splint cosmetically embarrassing. All the remaining patients used the splint while awake during follow-up period.

Discussion

Oral and oropharyngeal cancer together form the largest group of cancer in India⁵. Treatment of oral cancer includes wide excision, which frequently requires hemimandibulectomy. Following hemimandibulectomy, the remaining mandible tends to deviate medially & superiorly towards the operated side. The mandibular deviation may lead to incapacitating impairments such as: eccentric occlusion, disoriented masticatory cycle, facial disfigurement, distorted speech & drooling⁶. The patient can maintain normal occlusion actively with the remaining mandible, as the mandibular group of muscles substitute for each other in maintaining functional equilibrium. While medial pterygoid & mylohyoid pull the remaining mandible medially, the temporalis & masseter reciprocate in superior & lateral direc-

tion^{7,8} but it is difficult to maintain the mandibular alignment actively for long due to the onset of fatigue.

Several points can be concluded from the patient's sample in this series. Contracture of the scar tissue and unopposed action of the masticatory muscles of the unoperated side primarily contribute to the mandibular deviation. However tight intraoral closure of the defect can be one of the pre-disposing factors. The corner stone of the management of mandibular deviation is the prevention of over stretching of the remaining mandibular group of muscle (of the unoperated side) and strengthening them for better jaw control. To prevent overstretching of the muscles, the remaining mandible is positioned in occlusal alignment with the help of mandibular splint.

Patients used the splint for 7 weeks with different outcomes. Eight patients achieved complete correction of the mandibular deviation while other 10 patients benefited only partially. These individual differences in outcome can be explained on the basis of extent of tissue loss, type of defect closure, early & late intervention and patients motivation towards using the splint and implementing the exercise regime.

This splint has several advantages over the other existing appliances used for the same purpose. Its fabrication is simple and can be applied on edentulous as well as dentulous patients. The guidance flange may be preferred in dentulous patients because it is intra oral and not cosmetically embarrassing. Though the complication rates are high in this series most of them were minor and manageable with discontinuation of the splint usage for short period. Some of the pain and necrosis may be because of the radical radiation that the patients had received. As majority of the patients (68% in this series) are edentulous, the mandibular splint proves to be a viable alternative to the intermaxillary fixation in edentulous patients. The splint being an extra oral splint, it doesn't complicate the oral hygiene and is easy to wear. Disadvantage of the splint includes pressure scars over the face. It can interrupt healing of wound if sufficiently long pre-splinting period is not given. In three patients (patient number:

3,7,19 in table 1) it produced pain at pressure points and in two patients (patient number 8,9 in table 1) it evoked diffuse facial pain. Pain may occur from unhealed wound and irritation of the sensitive skin. Five of those who developed pain were advised to use the splint intermittently. Many of the patients got rid of the pain in less than one week.

For the correction of the mandibular deviation and facial asymmetry, compliance with the splint is necessary. However the evidence presented in this case series clearly shows that correction of the deviation may not always be the rule.

Conclusion

The mandibular splint is a useful tool to correct the mandibular deviation and facial disfigurement following hemimandibulectomy. The splint is the only non-invasive alternative to intermaxillary fixation for edentulous patient. However it can be used in dentulous patients and its efficacy on long term follow up needs to be confirmed.

References

1. Lambert PM, Patel M. Hemimandi-bulectomy without bone grafting: Head Neck Surgery 1986; 8:375-8.
2. Aramany, Mohamed A, Myers. Intermaxillary fixation following mandibular resection; J Prosthet Dent 1977; 4:437-443.
3. Thawley, Panje. Comprehensive management of Head and Neck Tumors; p 6000. Philadelphia: W.B. Saunders Company 1987.
4. Monaghan AM, Bear AS. A simple appliance to correct mandibular deviation following Hemimandibulectomy; Brit J Oral Maxillofac Surg 1990; 28:419-420.
5. Rao DN, Ganesh B. Estimate of Cancer Incidence in India in 1991. Ind J Cancer 1998; 35:10-18.
6. Moore DS, Mitchell DL. Rehabilitating dentulous hemimandibulectomy patients. J Prosthet Dent 1976; 35: 20-26.
7. Cantor R, Curtis T A. Prosthetic management of edentulous Mandibulectomy patients Part- I anatomic physiologic and psychologic considerations. J Prosthet Dent 1954; 4:257-262.
8. Atrkison HG, shepherd RW. The masticatory movement of patients after major oral surgery. J Prosthet Dent 1969; 21:86-91.

Authors

Ratish K Karana, BOT, Occupational Therapist
DK Vijaykumar*, MS, MCh, Assistant Professor
Rajani V Kanade, MPT, Assistant Professor
Thomas Cherian, MS, MCh, Prof & Head

*At present working at Saumya Apollo Hospital,
Vijayawada

Corresponding Author

Dr. D.K. Vijaykumar
Consultant Surgical Oncologist
Saumya Apollo Hospital
Soumya Nagar, Tadepalli 522501
Vijayawada. A.P. India
Tel : (+91) (0) (866) 470577
Email : vijaykumardk@usa.net

With best compliments from :

Glaxo Wellcome India Limited

makers of

SUPACEF and FORTUM