



OUR EXPERIENCES WITH PLATYSMA MYOCUTANEOUS FLAP IN HEAD AND NECK RECONSTRUCTION

Cherian T¹, Kurien J¹, Vijaykumar DK¹, Chittoria R²

*Department of Surgical Oncology¹ and Plastic Surgery²,
Kasturba Medical College, Manipal - 576 119, Karnataka, India*

Summary

In eighty-five patients under this study ipsilateral platysma myocutaneous flaps were used. The various regions reconstructed were tongue (47%), buccal mucosa (27%), floor of mouth (14%), lower alveolus (4%), maxilla (4%), lower lip (2%) and face (2%). Partial flap necrosis was noticed in 17 cases (20%), complete flap necrosis in six cases (7%) and wound infection in three cases (3%). The platysma myocutaneous flap provides a less bulky and versatile flap for head and neck reconstruction.

Keywords: Head and neck reconstruction, Platysma, Myocutaneous flap

Introduction

Immediate reconstruction following ablative surgery is the current trend in surgical treatment of head and neck malignancies. Commonly used myocutaneous flaps in head and neck reconstruction are pectoralis major, sternocleidomastoid, trapezius and latissimus dorsi flaps¹.

In 1978, Futrell et al² reported the application of platysma myocutaneous island flap in intraoral reconstruction. The flap proved to be highly reliable and was found to have significant benefits over many other techniques commonly employed for head and neck reconstruction. Because of its thinness and pliability, the platysma myocutaneous island flap meets pre-eminently the requirements for reconstruction of defects in the oral cavity.

The purpose of this paper is to describe our experiences with the platysma myocutaneous

flap and to attempt to define its role in the reconstructive armamentarium.

Methods

Eighty-five patients under this study underwent reconstruction of the defect after ablative surgery for head and neck malignancies using ipsilateral platysma myocutaneous flap. The demographic data of patients were recorded.

Extent of the tumour resection was based on site, size, stage and nature of the lesion. Various areas reconstructed by platysma myocutaneous flaps were floor of mouth, tongue, buccal mucosa, lower alveolus, lower lip and face within reach of the flap.

Adjuvant therapy included post-operative radiotherapy, whenever indicated. Patients were evaluated for both immediate and delayed post-operative complications with follow up of 6 months to 17 years.

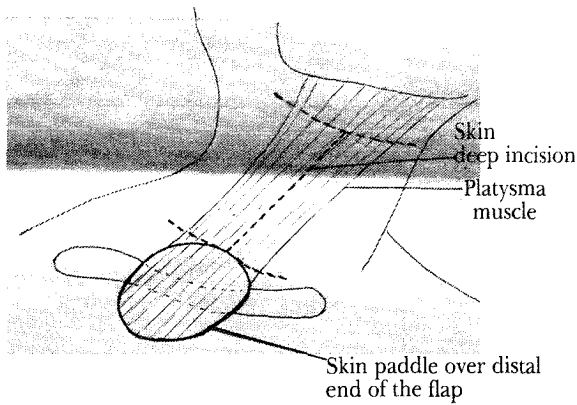


Fig 1. Line diagram of platysma myocutaneous flap

Operative Steps

Superiorly based platysma myocutaneous flap was raised in all cases after ensuring intact ipsilateral facial artery. The required size of the muscle pedicle and skin was planned over lateral side of the neck. The inferior border of the skin paddle, in any of these cases was not extended beyond 4cm in the infraclavicular area. Dissection superficial to the platysma in pedicle area was facilitated by subdermal injection of saline or 0.5% lignocaine (Fig1 & 2). While elevating the flap, the external jugular vein was ligated inferiorly and included in the flap.

In our series in none of the cases, flap was raised when neck dissection was indicated. The maximum dimension of the flap raised was 6 x 10cm and rotation of the pedicle was between 90° - 180° depending on location of the surgical defect.

Table 1. Sites of Primary Malignancies

Primary site	No. of patients	%
Tongue	40	(47%)
Buccal mucosa	23	(27%)
Floor of Mouth	12	(14%)
Lower alveolus	4	(4%)
Maxilla	4	(4%)
Lower lip	1	(2%)
Face	1	(2%)

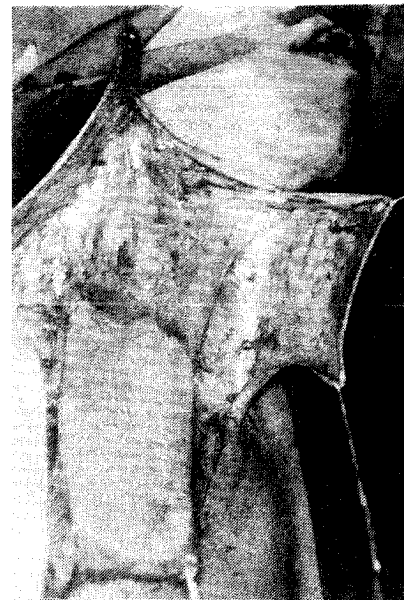

Fig 2. Photograph showing distal skin island after dissection of the flap

Table 2. Complications

Complications	No. of patients	%
Partial flap necrosis	17	(20%)
Complete flap necrosis	6	(7%)
Wound infection	3	(3%)
Total	26	(30%)

Results

The patient population consisted of 47 men and 38 women with mean age of 52 years (Fig.3-5). The commonest area reconstructed were tongue, buccal mucosa and floor of mouth (Table 1).

Flap related complications occurred in 26 patients (Table 2) including complete flap necrosis which was noticed in 6 patients. Evidences of the flap failure were notice only after 4 days. Partial necrosis occurred in 17 patients (20%), which was managed conservatively and when healthy granulation appeared, it was covered by split skin graft. All cases with flap necrosis had collection under the flap. The mean hospital stay without complications was 20 days and with complications was 30 days.

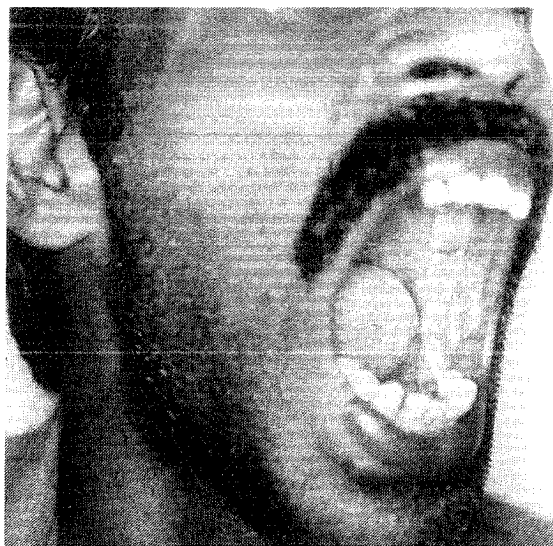

Fig 3a. Preoperative photographs showing carcinoma of buccal mucosa

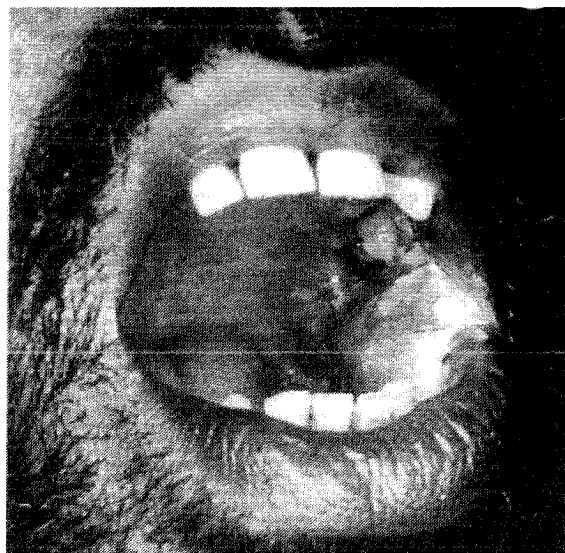

Fig 3b. Six month follow photograph after reconstruction with platysma myocutaneous flap

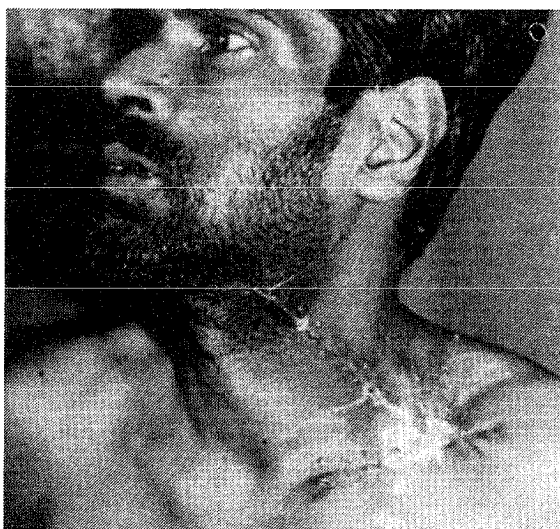

Fig 4. Photograph showing scarring in donor area after 8 weeks

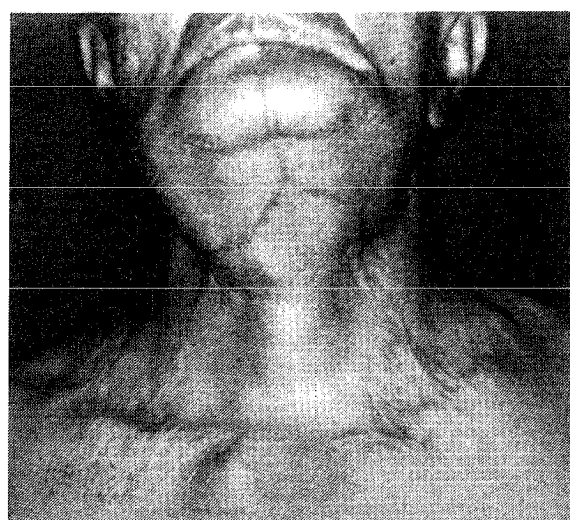


Fig 5. Photograph showing scarring in donor area after 3 years where bilateral platysma myocutaneous flap was used.

Discussion

Platysma is a type II, thin, broad, sheet like muscle extending over the entire anterior and lateral aspect of neck. Its use as musculocutaneous island flap was probably first described in 1887 by Gergusny, who employed it in reconstructing a full thickness defect of the cheek³.

In 1969, Farr et al described the application of a "cervical island skin flap" to the oral cavity⁴. Later, Futrell et al² described the tech-

nique for elevating a platysma myocutaneous flap by reflecting the cervical skin, exposing the muscle and its distal skin paddle. The various indications described for the platysma myocutaneous flap consist of reconstruction for congenital abnormalities, traumatic injuries, and most commonly, malignancies of the head and neck. Its uses range from external skin coverage in facial reconstruction to functional restoration with internal lining in upper aerodigestive tract. The majority of series including the present study indicate that the

Table 3 . Reported Series of Platysma Myocutaneous Flaps

Year	References	Reconstructed areas	No. of flaps	Complications
1978	Gersuny ³	Oral Cavity	14	2 (14%)
1982	Cannon ¹⁰	Oral Cavity	22	12 (55%)
1983	Coleman ¹²	Face, Oral cavity, oropharynx, neck	24	10 (42%)
1983	Hurwitz ⁶	Face	8	1 (13%)
1983	Persky ⁷	Oral Cavity	6	2 (33%)
1983	Neito ⁸	Posterior wall of pharynx	6	3 (50%)
1986	Manni ¹³	Oral cavity	10	4 (40%)
1986	Conley ⁹	Oropharynx, hypopharynx, supraglottic larynx	14	7 (50%)
1991	McGuirt ¹¹	Oral cavity, oropharynx, hypopharynx	41	8 (19%)
1993	Deborahis ⁵	Oral cavity, oropharynx hypopharynx	20	5 (25%)
1999	Present	Oral cavity, face .	85	26 (30%)

platysma myocutaneous flap is suitable for soft tissue replacement and lining for limited intraoral defects⁵. Demonstration of intact facial artery is important to assure flap survival. However, Hurwitz et al⁶ performed a detailed study of the blood supply of platysma muscle and found that an intact artery is not crucial to survival of the platysma myocutaneous flap. In our series, the facial artery was preserved in all the patients.

Complication rate in this study was 30% (Table 2), which is comparable with other series reported in the literature⁷⁻¹³ (Table 3).

Reported contraindications to the use of the platysma myocutaneous flap have included prior neck dissection, preoperative irradiation, ipsilateral facial nerve paralysis and ligation of the facial artery⁸⁻¹⁰. Facial artery was preserved in all the patients under the present study.

Previous irradiation to the neck appears to be a relative contraindication for using platysma flap, although conclusive evidences are lacking. In the series reported by Cannon et al¹⁰, five patients received doses of 4,300 rads or more prior to flap reconstruction and all did well, with no major complications. In our series, no patient had preoperative radiation.

Despite this information, we suggest caution when considering using the platysma flap in the setting of prior irradiation to the neck, due to potential post radiation arteritis and skin changes.

Previous surgery in the ipsilateral neck that has violated the platysma muscle may result in a precarious blood supply and therefore, should be considered a contra-indication to using the flap. However, McGuirt et al¹¹ found this concern to be debatable, particularly in patients with prior radical neck dissection. They believed that the key to success was the placement of the neck incision and two patients in their series who had undergone previous neck dissection had no postoperative complications. Although this contraindication remains debatable, we prefer to use other reconstructive methods when this situation exists.

Conclusion

The platysma myocutaneous flap was used in 85 patients for reconstruction in the head and neck area. Our results confirm the reliability and versatility of the platysma myocutaneous flap and indicate that the flap can be included in the reconstructive armamentarium for soft tissue replacement and lining for limited intraoral defects after tumor resection.

References

1. Ariyan S, Cuono B. Myocutaneous flap for head and neck reconstruction. *Head Neck Surg* 1980;2:321-345.
2. Futrell JW, Johns ME, Edgerton MT et al. Platysma myocutaneous flap for intra oral reconstruction. *Am J Surg* 1978;136:504-507.
3. Gersuny R. Plastischer Ersatz der Wangenschleimhaut Zentralblatt für Chirurgie 1887;14:504.
4. Farr HW, Gillies BJ, Die A. Cervical island skin flap repair of oral and pharyngeal defects in composite operation for cancer. *Am J Surg* 1969;118:759.
5. Deborahis, Rurark, McClairn WC et al. Head and Neck Reconstruction using the platysma myocutaneous flap. *Am J Surg* 1993; 165:713-719.
6. Hurwitz DJ, Rabson JA, Futrell JW. The anatomic basis for the platysma skin flap. *Plast Reconstr Surg* 1983; 72:302-14.
7. Persky MS, Kaufman D, Cohen NL. Platysma myocutaneous flap for intraoral defects. *Arch. Otolaryngol Head Neck Surg* 1983;109:463-464.
8. Neito CS, Gallego LL, GalenCortes JC. Reconstruction of the posterior wall of the pharynx using a myocutaneous platysma flap. *Br J Surg* 1983;36:36-39.
9. Conley JJ, Lanier DM, Tinsley P. Platysma myocutaneous flap revisited. *Arch Otolaryngol Head Neck Surg* 1986; 112:711-713.
10. Cannon CR, Johns ME, Atkins JP et al. Reconstruction of the oral cavity using the platysma myocutaneous flap. *Arch Otolaryngol* 1982;108:491-494.
11. McGuirt WF, Mathews BL, Brody JA, May JS. Platysma Myocutaneous flap : Caveats re-examined. *Laryngoscope* 1991;101:1238-1244.
12. Coleman JJ III, Jurkiewicz MJ, Nahai F, Mathes SJ. The platysma musculocutaneous flap: experience with 24 cases. *Plast Reconstr Surg* 1983; 72:315-323.
13. Manni JJ, Bruaset I. Reconstruction of the anterior oral cavity using the platysma myocutaneous island flap. *Laryngoscope* 1986; 96:564-567.

Authors

Thomas Cherian MS, MCh, Professor & Head
Jacob Kurien MS, MCh, Associate Professor
DK VijaiKumar MS, MCh. Assistant Professor
Ravi Chittoria MS, DNB, MCh. Asst.Professor

Corresponding Author

Thomas Cherian
Professor and Head,
Department of Surgical Oncology
Kasturba Medical College
Manipal - 576 119
Karnataka, India
Phone: (+91)(0)(8252)71201 Ext 2268
Fax: (+91)(0)(8252)70062
E-mail: inofo@mahe.ernet.in

With Best Compliments from:

Glaxo India Limited

makers of

SUPACEF and FORTUM