

## PROBLEM OF BURNS OF CHEST WALL IN FEMALE CHILDREN

*\*Prof. M. Mukherji, M.S., F.R.C.S., F.A.M.S.*

Female children with nylon frocks are fair preys of burns of the chest wall. This burns is likely to be deep as the frocks and under-garments cannot be opened up and removed quickly when they catch fire. The result is loss of whole skin with ulceration over the chest wall. The area may be fairly big, needing an urgent skin graft. The special point to remember is the problem of breast radicles in the chest wall of the females. Except for land marks, the breast radicles do not pose such an important problem in males. But the beauty of a lady depends considerably on the development of good looking breasts. Besides the function of the breast may also be hampered in a lady when the chest wall was burnt in childhood.

Experiences over 25 years in solving problems of burns scars in chest wall of female has shown unimaginable protection of breast radicle by nature. Creative genius of God or nature is appreciated in many parts of human body and mechanisms. This problem is another reminder of the same. The whole of the chest wall may have 3rd degree burns. The ulcers healed up with or without skin grafting forming scars in several areas. But in most children, the breast radicles are saved.

How and where they remain protected can only be recognised when the child attends puberty and the breast radicles start growing bigger. Twenty Five patients have been treated in the Plastic Unit of I.P.G.M.E. & R. for reparative surgery of the deformed breasts due to old burns in childhood from 1956-1972. Only one had complete loss of the breast radicle with complete absence of breast tissue when she attained puberty. So this paper will deal with the following three problems.

- (1) How are the breast radicles protected even when the whole of the chest wall suffers from 3rd degree burns ?
- (2) How to treat female children with 3rd degree burns of chest wall (acute burns) ?
- (3) Reconstruction of breast in girls with deformities due to burns in childhood.

(i) *How are the breast radicles protected ?*

Breast is a specialized apocrine gland developing in the front of the chest wall. The primary buds of the breast remain underneath the developing nipple and areola in the mammary line. The primary buds burrow deep through the dermis to subdermis. Actually the future buds of the breast remain

---

\*Emeritus Professor, Plastic Surgery, I.P.G.M.E. & R., Calcutta.

deep to skin. The areola and nipple are comparatively thick skin with epidermis denser than the surrounding skin of the chest wall. This portion of the skin is fairly deeply pigmented.

All these three facts help to save the breast radicle from being totally destroyed in most of the 3rd degree burns of the chest wall. In fact even when the nipple and areola have been partially or totally destroyed, the breast radicle still remains protected. These glands start growing during puberty and attain bigger size indicating the site and the deformity of the developing breast.

(ii) *How to treat female children with 3rd degree burns of chest wall?*

To-day treatment of burns has revolutionized.

In most of the deep burns, the surgeon does not delay skin grafting till all the sloughs separate and the surface of the wound shows clean and red granulations. There is no fixed time for skin grafting i.e. any time the patient is fit to stand the operation, skin grafts are placed to cover all 3rd degree burnt areas. The sloughs are separated with knife and the grafts are spread on subcutaneous fat. This modernization of treatment of burns has to be restricted in case of female children with 3rd degree burns of the chest wall.

Surgeon has to be most conservative and cautious particularly for the areas between 2nd and 6th ribs and costal cartilages. Careless excision of sloughs may remove the little remains of the breast radicles. So one is advised to wait with saline dressing till all the sloughs are separated naturally and by application of medicines. At the time of skin

grafting the whole of the red granulation should not be removed to expose the subcutaneous fat as is practised in treatment of burns ulcers in all other parts of the body. With these two precautions the skin grafts are fixed to the burns ulcer of the chest wall and the ulcers heal up. Unstable scars or keloidal burns scars are to be avoided in most patients. When the chest wall is healed up with such skin grafts, the child is advised to use some soothing ointment to soften the grafts and make them as much normal as possible. In most cases the grafted skin produces some thickening or scar formation and or pigmentation.

Once the ulcers heal up, the child is advised to attend the follow-up clinic regularly. The parents of the child are told to report to the surgeons when the child attains puberty and the breasts start growing. If the breast grows normally with nipple and areola, the 3rd problem of reconstruction does not come in the picture, but when the breast or breasts are deformed and small, the breasts are not growing properly, the nipple and areola are not demarcated well then the problem comes to the 3rd stage.

(iii) *How to reconstruct normal looking breasts in old burns of the chest wall with deformed breast or breasts?*

The first principle as in all problems of reconstructive surgery is the estimation of total skin loss. In this estimate one has to keep in mind the normal shape and size of the breast at that particular age and at that particular stage of development of the patient. If one breast has developed normally then this estimate is easy but otherwise it may be

fairly incomplete in the first operation. The nipple and areola are to be located. In many of the problems, the areola and nipple are so destroyed and deformed that exact location becomes a very difficult problem. When the little thickening of the nipple is felt than the areola can be measured around it. But when there is not even a little thickening of the nipples then particular sensation of the nipple comes to the surgeon's aid. The tentative nipple area is palpated and is pinched between the thumb and the index finger. If the patient gets sensation as is present in the normal nipple then the same area is marked. If both breasts have these problems then the patient is asked if she is feeling any different sensation in the suspected nipple area than in the other part of the surface of the breast. In fact the whole of the suspected area has to be tested by pinch sensation. If the patient feels some different and special sense of satisfaction and comfort as is the normal sensation of the nipple, then the same area is located. This point can be verified by pulling this part of the skin from the breast swelling. This breast will be found attached to this part of the skin more intimately than the rest of the skin over the developing breast.

Once the location of the nipple and areola is made then the deformity can be gauged more thoroughly. The imaginary normal breast is placed on the normal site of the chest wall i.e. between 2nd and 6th intercostal spaces. This can be built up with some stents dental composition, guttapercha or even by a suitable size moist mop. This imaginary normal breast is covered with lint and the

total skin needed is estimated. The lint piece is then placed on the deformed breast swelling and the portion of the skin cover over the upper part of the swelling is measured to find out whether that portion is sufficient to cover the upper and anterior surfaces of the released breast tissues. If the skin is not sufficient then the scared skin has to be incised and the wide gap due to the incision and internal tissue tension has to be grafted as a preliminary method. Then the breast can be covered anteriorly and superiorly by the newly made pectoral skin. Once this problem is solved an incision is made around the proposed areola.

Two transverse incisions are extended underneath the breast gradually upto the pectoral fascia and deep fascia over the rectus abdominus muscle. The nipple and the areola with the breast tissue is raised up from the deep fascia and pectoral fascia. The incision may have to be extended laterally and upwards to shape the anterior surface of the breast. Once the dissection and the cutting are completed the breast is positioned on the proper site of the chest wall. The breast tissue is fixed to the pectoral fascia by chronic catgut stitches. So the breast with its anterior skin, nipple and areola are all set. The raw surfaces to be covered are also obvious. The last problem is how to cover this raw area of the under surface and lateral surfaces of the breast. Formerly local flap were tried to make the under surface of this breast. The flap skin was taken from the contiguous abdominal wall. The whole of the raw areas of the chest wall and the abdominal wall after the flaps were rotated were covered with skin grafts. No doubt a good flap skin

for the under surface and fairly healthy skin of the pectoral region for the upper surface of the breast will make the breast having sort skin with subcutaneous tissues all round the breast. But it is not possible to design healthy skin flap in every patient. So recently medium or 3/4th thickness skin grafts are being utilized to cover the under surface of the breast from nipple and areola downwards to the chest and abdominal wall.

The fate of the grafted skin is fairly good when thick skin grafts are used. This thick skin becomes soft and healthy as flap skin in course of 6 months to a year. Sensation develops quicker on such grafts. When the wounds heal up the patient is advised to attend follow-up clinic every 2-3 months. The breast tissue getting released grow more comparable to the normal side. When the skin becomes tight again due to further development of breast, then the patient will need second sitting of skin grafting. The breast tissue grows faster once the scarbands are released and the grafted skin becomes smaller in contrast to the growth. Actually some

patients may need 2-3 operations to give a good sized and a good looking breasts.

The last problem arises when these ladies get married and have a baby. Most of the burn scar chest wall with no raised nipple have the lactiferous ducts sealed up in the so called nipple. So the breast will be very congested after child birth. This problem is solved these days by drying up the breast and soon as the baby is born. The plastic surgeons have to instruct these patients and their attending doctors so that there is no milk formation after the child birth in such reconstructed breasts from the scarred chest wall. This congestion and pooling of milk may be so great as to necessitate amputation of the same breast. But this last defect of the reconstructive surgery is not the whole of the problem. Even if the breasts are not fit to function as a feeding organ, the same should be reconstructed as best as possible when a developing female child is brought to a plastic surgeon with deformed breast as a result of old burns.

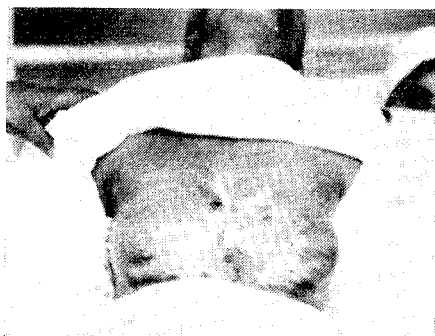

Fig. 1.

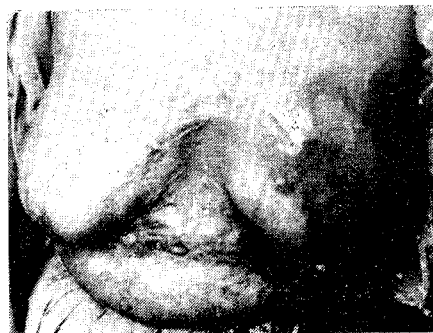

Fig. 2.

Scar chest wall deforming both breasts with stages of reconstruction.

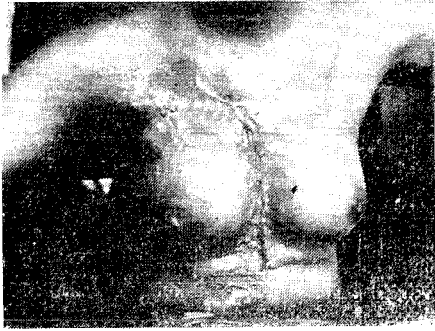


Fig. 3. 6 months after reconstruction of both breasts mainly with skin grafts.

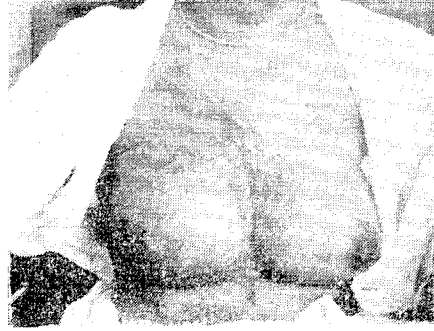


Fig. 4. 2 years later notice the matching of skin grafts.



Fig. 5. Scar chest wall embedding the breast.

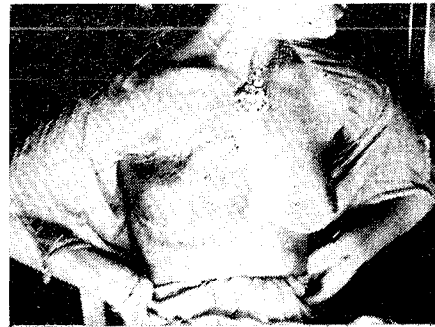

Fig. 6. Breast released and reconstructed with local flap and skin graft.

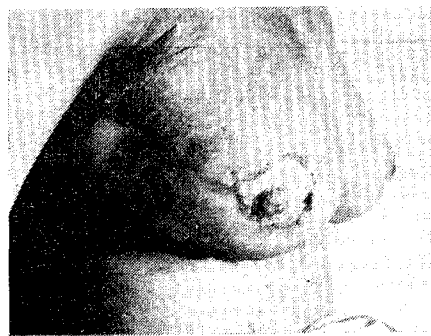

Fig. 7. An example of Nipple reconstructed from scarred skin.

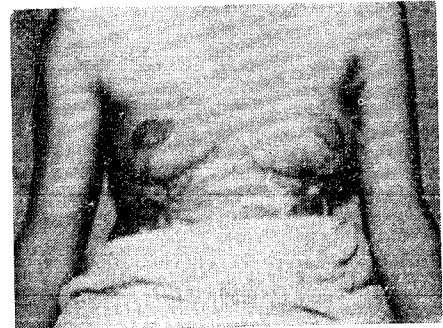
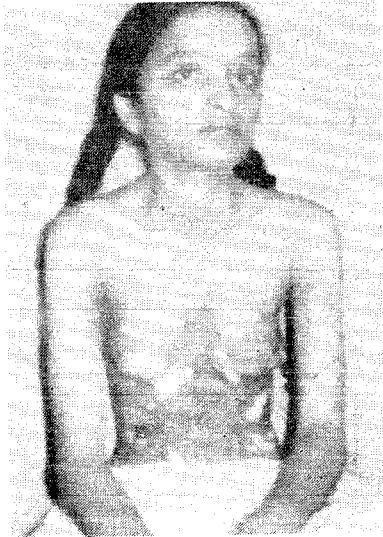

Fig. 8.  
Reconstruction of both breast by local flap and skin graft to cover the donar areas.

Fig. 9.

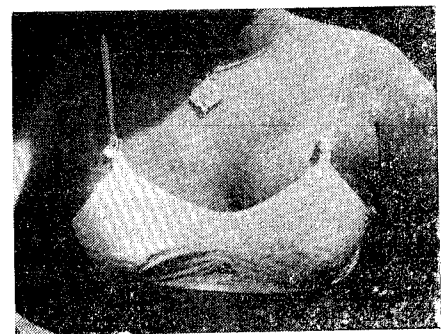
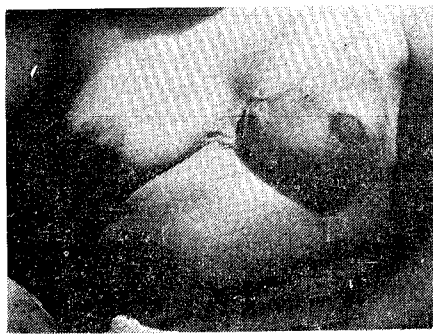

Fig. 10.  
Reconstruction of total breast by Gillie's method with inverted umbilicus as nipple.  
The girl lost the whole breast radicle due to burns.

Fig. 11.

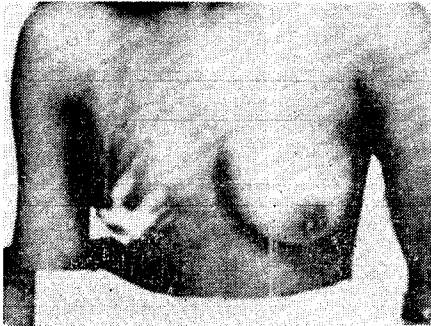


Fig. 12.

A normal looking breast comparable to the normal one can be reconstructed from this sort of scarred chest wall.

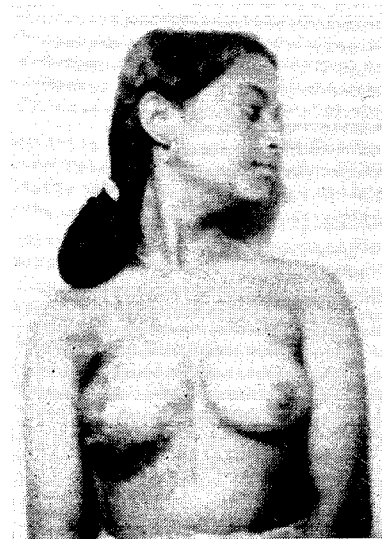


Fig. 13.

#### REFERENCES

- Henry W. Neall, Gregory L. Smith, Richard O. Gregory and Bruce G. MacMillan. "Breast reconstruction in burnt adolescent female (on eleven year study, 157 patients experience) Plastic and Reconstructive Surgery Vol. 70 No. 6, Page 718, December 1982.