

## ROLE OF TUBED PEDICLE FROM THIGH FOR RESURFACING DEFECTS OF LOWER EXTREMITY

By

*\*Lt Col Ajaipal Singh MS., MCh (Plastic)*

&

*\*\* Col P. M. L. Kathpalia MS., FRACS*

### Introduction

Lower extremity is the commonest site involved in trauma following accidental or missile wounds. Majority of the injuries involve the leg and foot, are compound in nature with skin loss and require full thickness cover for fracture union or as a prerequisite for future reconstructive surgery. There may be low grade infection with chronic osteomyelitis with or without delayed union and flap cover may be the only definitive procedure required to eradicate infection or aid and accelerate fracture union.

The aim of this paper is to present our experiences of using tubed pedicle from the ipsilateral or contralateral thigh in a series of 13 cases for extensive or difficult and unusual defects of the lower extremity. This technique with vast potentials does not appear to have been either fully exploited or documented.

### Problems

Although, the principles of reconstruction of the cutaneous defects of the lower extremity are the same as elsewhere in the body, there are a few peculiarities that make the replacement of skin little more problematical.

Most injuries of the leg are compound in nature requiring full thickness cover. There is paucity of skin below the knee and requires skin to be brought from elsewhere.

Except in the very young, it is not possible to approximate the leg to the trunk for direct flaps. Circulatory pattern of the leg and foot is not very good.

The Skin of the sole is specialised for weight bearing and is virtually irreplaceable.

### Review of Various Reconstructive Procedures

Most defects of the leg and foot requiring full-thickness cover can be treated by a cross leg or a cross thigh flap.

Dorsalis pedis based axial flap is excellent for defects around the ankle joint and distal third of the leg but split thickness cover of whole dorsum of the foot may leave a major disability especially in service personnel who have to wear boots and march long distances.

Muscle and myocutaneous flaps have the advantage of being single staged but transfer of a major muscle must leave a major motor deficit and are not recommended for our patients as this may jeopardise their chances of retention in service,

\* Classified Specialist (Surgery & Reconstructive Surgery)

\*\*Senior Adviser (Reconstructive Surgery)

Dept. of Reconstructive Surgery, Army Hospital, Delhi Cantt-10

When the defects are large and at unusual sites and a tubed pedicle from the abdomen is required, tubed groin flap appears to be a better alternative for obvious reasons. It is in these later cases where a tubed pedicle from the thigh offers a viable alternative especially in the older age group.

### Indications for a Tubed Pedicle from Thigh

Thigh is a major donor site and has the advantage of adequate muscle padding that takes split graft readily but unfortunately, it is suitable for direct flaps only to the distal part of the opposite leg or foot which involves acute flexion of the knee. The following may be considered as indications for tubed pedicle from the thigh :—

- (a) Reconstruction in an aged patient, unsuitable for a cross leg/thigh or any multi-staged procedure with rigid immobilisation.
- (b) Stiffness of knee joint following prolonged immobilisation or injury.
- (c) Defects over the upper third of leg.
- (d) Defects over the outer aspect of leg and foot.
- (e) Circumferential defects.
- (f) Defect over distal third of thigh.

A tubed pedicle from the abdomen or a tubed groin flap may be the only choice under the above unpleasant circumstances. In addition to being multistaged, these require immobilisation in a very awkward position resulting in full extension at one elbow (carrier) and varying degree of flexion at the knee (recipient limb). For such cases, we prefer raising a tubed pedicle over the ipsilateral or contralateral thigh.

4

### Technical Aspects

The antero-medial aspect of the thigh is the most suitable site for raising a tubed pedicle. The skin is relatively lax with abundance of muscle padding and the investing layer of deep fascia is thin. More over the limb can be kept in the natural position of comfort and rest. A tubed pedicle 12" x 6" can be conveniently raised and the long saphenous vein should be incorporated within the tube without damaging it if possible. There is adequate vascularity around the knee to sustain the tube even when the proximal end is detached (Fig-1).

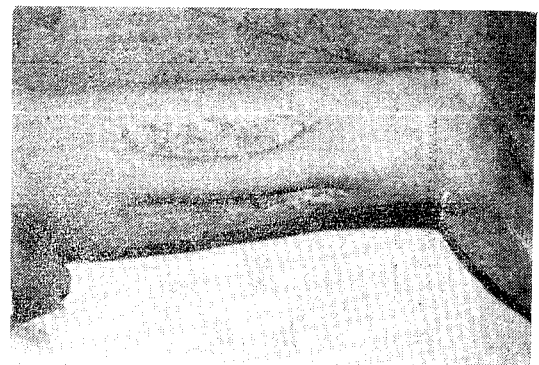


Fig. 1 Tubed Pedicle raised over the anteromedial aspect of thigh.

### Ipsilateral tubed pedicle flap

This is preferred for defects over the upper third of the leg. The proximal end is detached and inserted over the prepatellar region and subsequently brought down to cover the defect. During and in between all the stages, the patient remains ambulatory with full mobility of the knee joint. This is especially recommended for older age group (Fig-2 and 3).

### Contralateral tubed Pedicle flap

This is recommended for defects over the outer aspect of leg or circumferential defects. The proximal end is detached, tube opened and inserted on to the defect as a cross thigh

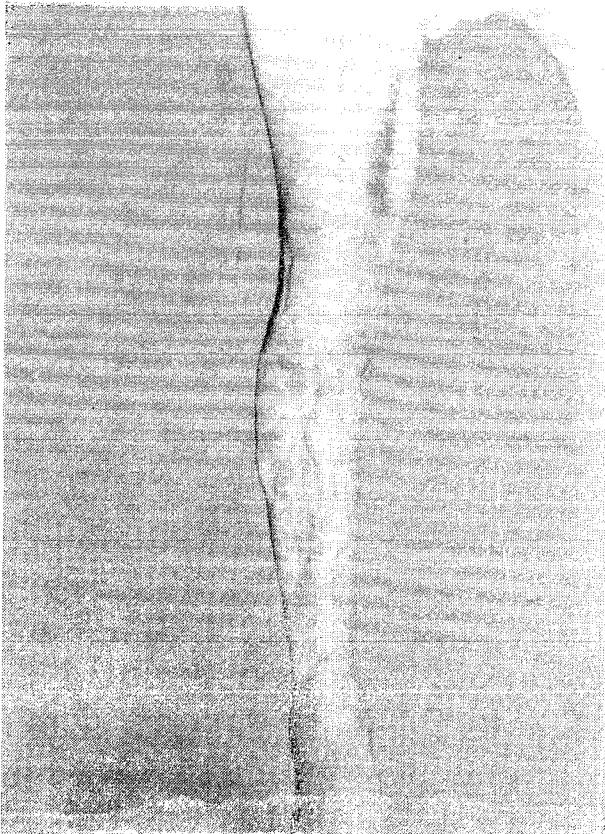


Fig. 2 Ipsilateral Tubed Pedicle from thigh for upper 2/3 defect of leg.

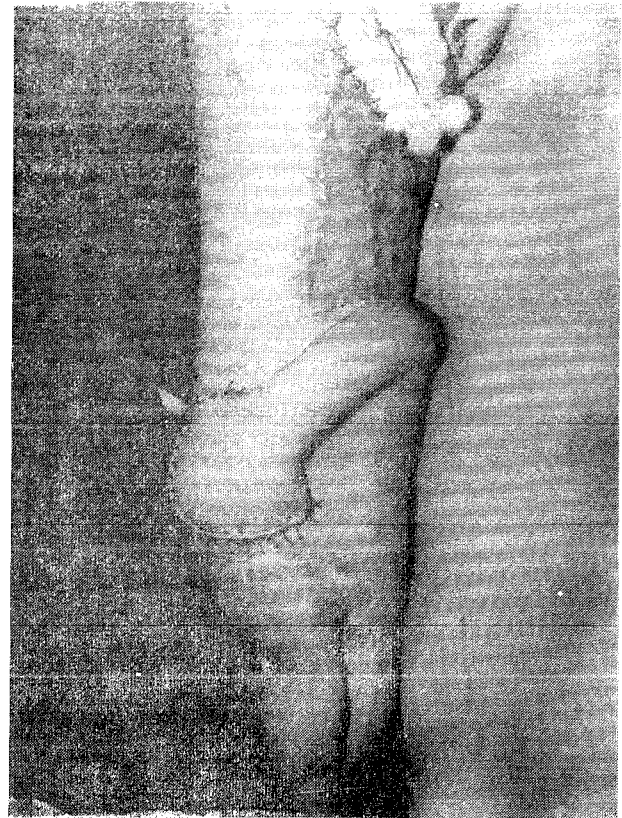


Fig. 3 Ipsilateral tube transferred to peritellar region. (II stage of case in Fig No. 2).

flap with added advantage of mobility, ease of fixation and comfort of posture. Some mobility of the knee joint is essential for its execution (Fig 4 and 5).

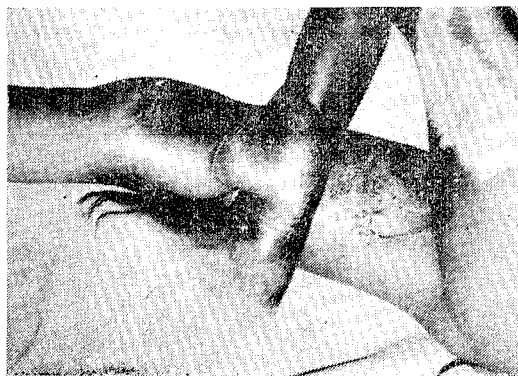


Fig. 4 Contralateral Tubed Pedicle for a circumferential defect. Note the delay procedure before separation of the flap to gain additional length.

Compound fracture of femur requiring full-thickness cover are rare. But an occasional case of this nature a contralateral tubed pedical flap is a convenient procedure in preference to an abdominal tubed pedicle or a tubed groin flap (Fig-6).

#### Results and Analysis of Cases

This table shows the nature and site of defect in the present series :—

**Table 1.**  
(Nature and Site of Defect)

Upper third of Leg	—	7
Circumferential Defects	—	5
Distal third of Thigh	—	1
Total	—	13

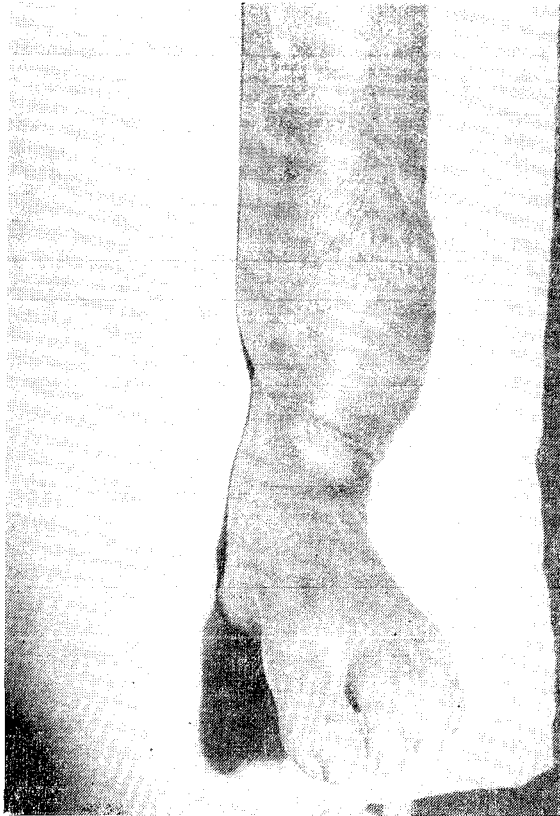


Fig. 5 Tube transfer completed. (Final stage of case in Fig No. 4).

Although, majority of the cases were young soldiers but this includes two cases who were past 50 years of age.

The ideal donor site is the antero-medial aspect of thigh but in one case it was raised over the antero-lateral aspect due to nonavailability of the usual donor site (Fig-7). This patient had chronic osteomyelitis following pott's fracture dislocation of the ankle. A cross leg flap was completely lost, a dorsalis pedis based axial flap and a tubed groin flap were partially lost due to infection.

This table shows the distribution of thigh tubes :—

**Table 2.** (Distribution of Thigh Tubes)

Ipsilateral Tubed Pedical	6
Contralateral Tubed Pedicle	7
Total	13

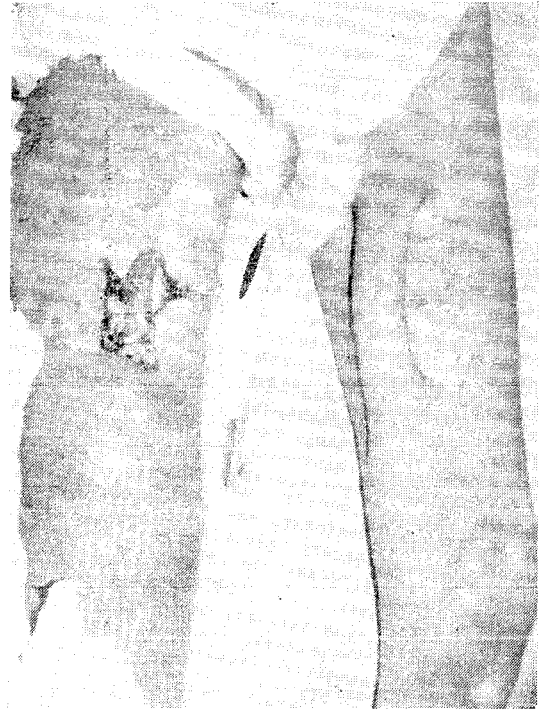


Fig. 6 Contralateral thigh tube for compound supracondylar fracture femur. (Temporary skin graft application to cover the exposed bone).

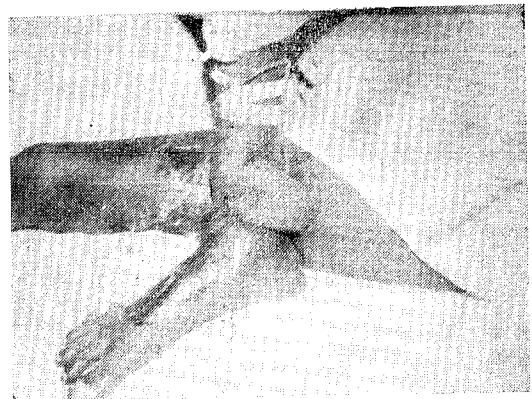


Fig. 7 Contralateral tube from antero-lateral aspect of thigh. (Employed in this difficult case see text for details).

The average number of stages in both the categories have been 3 to 4 including an occasional delay procedure thereby taking about 10 to 12 weeks for transfer of the flap.

There was no major loss but two cases had marginal necrosis during the intermediate stages which healed spontaneously.

### **Summary and Conclusion**

The utility and versatility of a tubed pedicle from the thigh hitherto unexploited for

resurfacing difficult and extensive cutaneous defects of the lower extremity have been discussed. The experiences in a series of 13 patients have been presented. We advocate this method in all major defects where indications exist for importing tissues from a distance (abdominal tubed pedicle or tubed groin flap) for reasons of convenience and ease of fixation. The donor site is well covered and leaves no residual disability.

### **Reference**

1. Jackson I. T. : Flaps, Design & Management in Plastic Surgery, Edited by James Churshill Livingstone.
  2. Stark. R. B. & Kernahan D. H. (1959) Reconstructive surgery of Leg and Foot, Surg. Clinics of North America 39,469-490.
  3. Thind R. S. & Singh A. : Direct Pedicle Skin Flap Cover for Weight Bearing Area of Foot., Ind. J. Plastic Surg. Vol 10, No. 2 , (1977).
-