

## ROLE OF COLLAGEN SHEET AS A TEMPORARY COVER FOR RAW AREA—AN EXPERIMENTAL STUDY

\*Dr. R. Krishnan \*\*Dr. T. C. Goel \*\*\*Dr. S. K. Bhatnagar and  
\*\*\*\*Dr. Mahender Kumar

### Introduction

The problems of raw areas and their healing, have involved medical men since time immemorial. Their efforts have always been to make the job easier for God.

In the present paper we have presented our experiences in the use of collagen sheets, as a biological dressing, in an experimental study on dogs.

The study was conducted with the following aims and objectives :

1. To study the efficacy of collagen sheets as a biological dressing.
2. To check the efficacy of collagen sheets in the prevention and eradication of infection.
3. To compare the pattern of wound healing in areas covered by collagen sheet, skin graft and open dressings.

### Review of Literature

The history of open wounds or raw areas, is in fact, the history of gradual understanding of the process of wound healing and the methods of treating them, evolved through the ages.

### Synthetic Skin Substitutes

In treating the severely burnt patient, the non-availability, expense and general

difficulties associated with procurement of autografts, homografts and even heterografts has encouraged scientist to make efforts to develop a wound dressing that would temporarily serve as skin substitute.

Beginning in 1961 Chardac, et al, Martin & Boyer (1963), Breitman (1964) have described the experimental and clinical utilisation of polyvinyl alcohol sponge as a temporary substitute for skin in burn wound coverage. They have reported favourable results in burned patients, though for a very short period i.e. 7 days, after which serious wound infection was seen in majority of the cases.

Harrison et al (1965) described their laboratory investigations employing a number of synthetic skin grafts including silastic, acrylic and collagen films and foams. Later on more reports, using collagen film as a temporary skin replacement in burn wounds appeared (Abbenhause et al, 1965, Lorrenmetti and Co-Workers, 1960).

The other biologic and plastic substitute which have been used as biological dressings in burn wound injuries include Methyl-2-cyano acrylate and colloidal silicate. Guldalian and Jelenko (1971) described a series of experimental studies employing a variety of synthetic and biologic materials for wound

---

\*Chief Resident, Department of Surgery, K.G's. Medical College, Lucknow.

\*\*Reader, Department of Surgery, K.G's. Medical College, Lucknow.

\*\*\*Lecturer, Postgraduate Department of Plastic Surgery, K.G's. Medical College, Lucknow.

\*\*\*\*Scientist, Central Leather Institute, Madras.

dressings, including nylon velour, polyester urethane film, foam and several collagen films.

### Collagen Products and Sheets

The use of animal tissue in surgery, particularly based on collagen has drawn the attention of medical profession and the biochemists all over the world. The most important and uninterrupted use of collagen in surgery for more than a century, has been in the form of absorbable catgut (Lister, 1969).

Brocotamp, a new assimilable material consisted of collagen which appeared perfectly non-irritating to the surrounding tissue when implanted in rabbits (Feris 1940). It was partly absorbed by phagocytosis and partly organised either by direct infiltration by the connective tissue cells or by the formation of granulation tissue.

During the past two decades, attention has been diverted to the use of such collagen products as sheets, tapes, laminates, fabrics, powders, gel, sponge etc. Grilio et al (1962), published a paper on thermal reconstitution of fresh calf skin collagen from solution and the response to its heterologous implantation and antigenicity of collagen implants. Collagen gels and sheets derived from calf dermal extracts were implanted subcutaneously in guinea pigs. Implants were accepted by the host with prompt healing of the overlying skin and deeper tissues and minimal visible local reaction. The amount of reaction depended upon the degree of local trauma during the initial implantation and super-added infection, if any. No differences of tissue response was noted in rats, guinea pigs and rabbits. 48 hours after operation, there was a zone of inflammatory cells (both polymorphs and mononuclears) around the implant.

Based upon previously described Gel-sol-Gel transformation theory, Thiele (1965) prepared synthetic skin for the treatment of experimental burns, whereas, Copanahagen (1965) used a tape of reconstituted collagen from the Tendo-Achilles of ox, as a substitute for natural fascia in the reconstructive surgery. In search of better collagen material, various tissues were explored, viz. fresh cow hides (Abbenhaus 1965), enzyme treated calf skin to obtain transparent membrane for corneal grafts (Dunn et al, 1967).

Gupta, et al, (1978) studied the fate of collagen sheet cover for artificially created raw areas and its role in burns and post-operative raw areas, as a biological cover. They used the collagen sheet developed at the Central Leather Research Institute, Madras, with encouraging results.

### Experimental Study—Technique

Three artificial raw areas of standard dimensions (2"×2") were created on the lateral surface of the chest wall in each of a group of twelve mongrel dogs. The procedure was done under general anaesthesia, achieved by intravenous injection of Nembutal.

Three raw areas were created in each of the six dogs by partial thickness excision of skin, using a Humbey's Knife. The lateral surface of the chest being usually irregular because of the underlying ribs, the difficulty in using a Humbey's Knife effectively here, was overcome by the following method. The corners of the total rectangular area of skin about (6"×10"), which had been prepared, was pulled up in opposite directions with the help of traction stitches (Subcutaneous tissue deep) passed at each corner, thereby raising the whole area of skin like a platform away from the rib cage. This

was not required in the other six dogs in whom the whole thickness skin upto the subcutaneous tissue was excised, creating similar 3 raw areas. the site being the same. The first area was covered by collagen sheet, the second by a split thickness skin graft and the third treated by conventional dressings, i.e. Furazolidone ointment, gauze, cotton and bandage (fig. 1 & 2). The skin graft was perforated and anchored in place by interrupted everting mattress sutures of thread or silk and covered by vaseline gauze and cotton (wrung dry after wetting with saline). This was secured in place by tie over sutures. The collagen sheet was not stitched to the wound as any attempt to stitch it caused a tear and besides, it adhered well to the wound by applying it only and did not need anchorage. This was covered by vaseline gauze and cotton held in place by tie-over stitches. A plaster bandage was applied over an ordinary bandage to prevent the dog from tearing the dressing and getting at the graft and collagen sheet. The dog was also muzzled for the same reason. (Fig. 2A).

Change of dressing was done under general anaesthesia. First dressing was done at 48 hours, second and subsequent at one week intervals.

Swab culture and sensitivity was done from the wound just after creation and after one week or whenever evidence of gross infection was present.

Biopsy was taken weekly :

The findings were recorded as follows :

- (i) Behaviour of collagen sheet.
- (ii) Take of graft.
- (iii) State of raw area treated by furazolidine dressings.
- (iv) Swab culture.
- (v) Biopsy from wound.

**Observations**

Twelve mongrel dogs were used. They were divided into 2 group of six each. Group I comprised of dogs with partial thickness and Group II, those with full thickness raw areas.

**Group I—Split Thickness Raw Areas**

**Table I**

Period & No. of Cases	Behaviour of Collagen Sheet
<b>2nd Day</b> 3 Cases	Greyish red in colour, adherent, no blebs no infection. (The dogs tore off the dressing and got at the sheets and skin grafts. These cases were excluded from the study).
3 Cases	
<b>7th Day</b> 1. Case	Collagen sheet cast off and wound covered with epithelium. Collagen sheet removed with dressing, wound epithelized at most places, while at other places, crusts of blood found, on removal of which, raw area present at a few points.
2 Cases (Fig. 3)	

**Take up of Graft**

Of the six dogs studied, three got at their raw areas by tearing off the dressing. These were excluded from the study.

Out of three split thickness grafts applied, none took up. On the 7th day they came off with dressing, leaving behind an epithelised surface.

**Behaviour of raw area treated by ointment dressing**

As mentioned above, only 3 cases were included in the Study. The wound in 2 cases took 10 days to epithelise completely. One case was grossly infected. Discharge of greenish pus was present. Culture was positive. It healed on the 10th day. It was sterile at time of excision, but culture swab

taken at one week was positive. Infection was the cause of retarded healing.

**Histopathological examination of wounds with collagen sheet cover**

There was no cellular invasion of the collagen sheet at one week. The wound showed epithelization under the sheet.

In raw areas with gross infection the epithelial remnants showed complete destruction. Widespread tissue necrosis was seen. Many coccal and becillary forms were seen.

**Group II—Full Thickness Skin Defects**

Two dogs were excluded from the study, as they tore off the dressings and got at the collagen sheet on the 1st and 2nd days, respectively.

**Table II**

Period & No. of Cases	Behaviour of Collagen sheet
<b>48 Hours</b>	
4 Cases	Greyish red in colour. Dry, intact, adherent, No infection, no soakage.
<b>7 Days</b>	
2 Cases	Greyish red in colour. Dry. intact, adherent No infection, no soakage.
2 Cases	Swollen, Greyish yellow, soddened, intact, not adherent, infection present, culture positive, collagen sheet replaced.
<b>14 Days (Fig. 4)</b>	
1 Case	Greyish red in colour. Dry, intact, adherent. No infection, no soakage.
1 Case	Sheet well adherent. (Sheet stripped off and autografting done. (The graft sloughed out later due to gross infection).
2 Cases	Collagen sheet sloughed out.
<b>21 Days</b>	
1 Case	Greyish red in colour. Dry, intact, adherent. No infection, no soakage. Disappearing at places. Wound size $\frac{1}{4}'' \times \frac{1}{4}''$ .
<b>28 Days (Fig. 5)</b>	
1 Case	Collagen disappeared, complete epithelization and scar tissue formation.

**Take of Graft**

In 4 of the 6 cases studied, the dogs could not get at the patches and these were observed. In 2 cases there was gross infection evident at 48 hours and the graft was non-adherent. It completely sloughed out on the 14th days. Wound was covered with pus and did not bleed on cleaning. Pus culture was positive. In 2 cases there was a 60-80% take of the graft, no infection was present and complete epithelization occurred by the 18th day in the small islands of raw areas left.

**Behaviour of wound dressed with Furacin Ointment**

Healing was complete in 35 days by formation of scar tissue and epithelization in 1 case. No gross infection was present. Even in this case though, the culture was positive. In 3 cases, the wound was infected and healing delayed upto 42 days. Ointment dressing was repeated thrice weekly in these cases. Culture was positive.

**Swab Culture**

The commonest infecting organisms in both Group I and Group II, as determined by swab culture were pseudomonas, proteus and streptococci. Staphylococci and enterococci were also found in 1 case.

Even in raw areas without evidence of gross infection (2 cases), culture was positive for some of these organisms.

**Histological changes in wound with collagen sheet cover**

The histological changes noted in the biopsy taken at weekly intervals is recorded below :—

**1st week**

Collagen sheet remained unchanged and there was no cellular invasion. Inflammatory cells, predominantly mononuclear and few polymorphs were present around the sheet. Early cellular response

**Table III**

*Bacteriology in experimental Cases with Gross Infection*

Groups & No. of Cases	Type of Bacteria on Culture				
	Pseudo- monas	Proteus	Strepto- cocci	Staphylo- cocci	Enter- cocci
<b>Group I</b>					
Ointment dressing cover (1 case)	+	+	—	+	+
<b>Group II</b>					
Collagen cover } (2 cases)	+	+	—	+	+
Autograft Cover } (2 cases)	+	+	+	—	—
Ointment Cover } (5 cases)	+	+	+	+	—
	+	—	—	+	+

to the sheets was a mixture of fibroblasts and young fibres (Von Geison Stain). These were lying roughly paralld to the sheet.

#### IIInd Week

Collagen sheet was invaded by capillaries, few fibroblasts, young fibres and mono nuclear cells. Increased number of fibroblasts and chronic inflammatory cells were present around the sheet. Few epithelial cells were also seen.

#### IIIrd Week

Diffuse invasion of collagen sheet by capillaries and fibroblasts. This was surrounded by fibroblasts, chronic inflammatory cells and a layer of epithelial cells. Sheet developed fibrillar appearance at many places.

#### IVth Week

There was nearly complete replacement of collagen sheet by fibroblasts, fibrous tissue and chronic inflammatory cells. Planty of epithelial cells seen. Chronic inflammatory cells were present.

The layer of fibrosis which separates the prosthesis from loose areolar tissue increased in depth with length of application.

*In open granulating wounds* : intense fibrosis is seen in contrast to that seen in wounds covered with collagen sheet.

*In badly infected wounds* : neutrophil response is massive, evidently due to infection and not due to the sheet. Coccal and bacillary forms were seen and tissue necrosis extended for variable distances beneath the surface, by 14 days post excision. Early response to the sheet, of a mixture of fibroblasts and young fibres was absent in infected areas.

### Discussions

#### A. *Partial thickness skin defect*

It was observed that the collagen sheet was cast off on the 7th day in 5 cases with complete epithelization of the wound in 1 case and in the other 2 cases, most of the area was epithelized, but at places crusts of serosanguinous nature were present, on removal of which, raw areas were present. In the raw areas covered with a primary split thickness skin graft, the graft did not take up and came off with the dressing on the 7th day the raw area was nearly completely epithelized in all three. The graft could not adhere to the raw area as the wound epithelized beneath it. No study involving the use of collagen sheet in partial thickness skin raw areas could be found in the literature consulted.

In the 3 raw areas treated by furazolidine ointment dressing, 2 completely epithelized by 10th day and 1 case developed gross infection and toor 20 days to heal completely. All the raw areas were sterile intra-operatively, but at one week, pus culture from this raw area showed growth of pesudomonas, proteus and streptococci.

#### B. *Full thickness skin defect*

Six mongrel dogs were used in the experimental study in Group I (full thickness skin raw areas.

In 4 of the 6 cases studied, the dogs could not get at the patches and these were observed. The sheet sloughed off due to infection in 2 cases, by the 14th day. (In 1 case the sheet which was adhrent, was stripped off and replaced by a split thickness autograft. It sloughed out due to gross infection).

Though the materials used as a cover in the experimental study by Chardack, et al.,

was different, the incidence of infection and resultant sloughing out of the sheet was 25%. Gupta, et al., (1978), though applying collagen sheets, used guinea pigs in the experimental study. They encountered infection in 4% of cases. In our study, the incidence was 28% (nil in split thickness skin raw areas and 50% in full thickness skin raw areas).

Adherence was achieved in 2 of the 4 cases (50%) studied in Group II and all 3 in group I. Chardack, et al. (1961), though using another material and because of lower infection rate, achieved adherence in 75% cases. Gupta et al. (1978), using a different experimental animal (Guinea pig) but same material (collagen sheet), showed adherence in 85% cases. This figure includes those animals also in whom the sheet was adherent and who died during the course of experimental study. The slightly higher figure of adherence can be complained because the chance that these animals (which died), stood of contracting infection had they lived, was not taken into account and is anybody's guess.

In the above cases, of the 4 raw areas which were covered with split thickness skin graft, the graft in 5 cases completely sloughed out, owing to the presence of gross infection (all the 3 areas in 3 dogs got infected, resulting in sloughing off of the collagen sheet as mentioned above and retarded healing of the area dressed conventionally, (as well). Pus culture was positive for staphylococcus, proteus and streptococci.

Our finding of the commonest infecting organism being pseudomonas, proteus and streptococci and sometimes staphylococci and enterococci, are in confirmity with the

findings of Charadack, et al (1960); Harrison; Lindberg and Mason (1965), Walkar, et al (1964); Teplits, et al (1964).

Teplits and Lindbarg (1962) and Moncrief and Teplits (1964) have demonstrated frequent overwhelming bacterial invasion of viable tissue subjacent to the burn, when conventional dressings or exposure method of treatment are used. In our study, the wounds treated by conventional. dressings showed infection most frequently, i.e. in 4 of the 7 cases.

In 2 cases, there was a 60-80% takeup of graft, no gross infection was present and the wound completely epithelized by the 18th day.

In the 4 raw areas treated with conventional ointment dressings, healing was complete in 1 case by the 35th day with complete epithelization and in the other 3 cases, because of initial infection, the healing was retarded and complete epithelization took 42-45 days.

The histological changes noted in the cases in which collagen sheet was adherent and later absorbed and epithelization of wound with the formation of supple scar occurred, are similar to the changes noted by Harrison, et al (1965) and Gupta, et al. (1978). In our study, it took 28 days for the sheet to get completely absorbed, while in the study by Gupta et al. it took 35 days. This can be explained by the different regenerating capacities of the tissues in the different experimental animals used.

### Summary and Conclusions

1. Collagen sheet is very useful in preventing exogenous infection.
2. It promotes rapid epithelization in thickness raw areas, by protecting it from infection and the sheet is ultimately cost off.

3. Split thickness skin grafts do not take up in cases of partial thickness skin loss. The wound epithelizes under the graft and it casts off.

4. Ointment dressings are prone to infection (57%) and they need frequent changes, unlike collagen sheet.

5. Small, clean, full thickness raw areas covered with collagen sheet take lesser time to heal completely (28 days), compared to those treated with conventional dressings (35-45 days).




Fig. 1. Showing 3 areas of standard dimensions marked on the lateral chest wall of a mongrel dog.




Fig. 2. *Intra Operative* : 3 raw areas, corresponding to the above marked areas, created by excising partial thickness skin. Photo shows first area covered collagen sheet, second covered with furazolidine ointment and the third by a split thickness skin graft.

6. The sheet is invaded by fibroblasts, capillaries and ultimately complete epithelialization occurs, incorporating the sheet into the raw area. Fibrosis is more marked in cases treated with ointment dressings.

The findings of the experimental study support those of the clinical study.

In the final analysis, collagen sheet is very effective in the treatment of partial thickness raw areas and in some cases of operative raw areas. It is only of limited use in deep burn and traumatic raw areas.



Fig. 2A. *Post Operative* : showing the area covered finally by a protective plaster barrel to prevent the dog from getting at the patches.




Fig. 3. *Seventh Day* : Showing non take up of graft while the collagen sheet is well adherent and dry.






Fig. 4. Showing the split thickness graft taken up and healthy, the area covered with ointment showing crusting and collagen sheet well adherant to the third area.

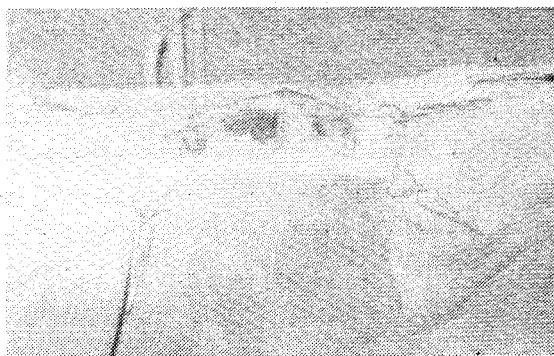

Fig. 5. Fourth Week : Showing split thickness graft very well adherant and nearly merged with the surrounding skin (extreme left). Raw area dressed with ointment (middle) has still now healed completely. Collagen sheet completely absorbed (extreme right) with epithelization.

#### Bibliography

4. Abhanhause, J. I. ; Mac Mohan R. A. ; Rosenkrants, J. G. & Paton B. C. Collagen sheet as a dressing for large excised areas. *Surg. Forum Amer College of Surgeons* Vol. XVII. (1965)
2. Breitman, R. S. The course of burns in the use of polychlorvinyl film dressings, *Klin. Med. (Moskva)* 42 : 126, 1964
3. Chardack, W. M. & Others Synthetic Skin : an experimental study, *J. Trauma* 1 : 54, 1961
4. Copenhagen, H. A new collagen tape in Reconstructive Surgery. *Brit. J. Surg.* 52 : 697, 1965
5. Dunn, M.W. ; Mishihara, T. ; Stenzel, K.H. ; Branwood, A. W. ; Rubin, A. L. Collagen—derived membranes : Corneal implantation. *science* 157 : 3794, 1967
6. Feriz, H; Experiments with Tampous & Membranes made of collagen, *Surgery* 8: 654, 1940
7. Grillo, H. C. & Cross, J. Thermal Reconstitution of Collagen from solution and the Response to its Heterologous Implantation, *J. Surg. Res.* II:1 : 69, 1962
8. Guldalian, J. & Jelenko, C. A comparative study of synthetic and biological materials for wound dressings, presented at Third Annual Meeting of the American Burn Association, San Antonio, Texas. (1971)

9. Gupta, R. L. ; Jain R. K. ; Humar, M., et al Fate of collagen sheet cover for artificially created raw areas (an experimental study) LJS, 40 : 541-645, 1978
10. Harrison, H. N. ; Lindberg, R. B. & Mason, A. D. ; Management of the burn wound : bacteriological and histological response of excised rat wounds to synthetic skin grafts. In Wallace, A. B. & Wilkinson, A. W., editors : Research in burns, Transactions of the Second International Congress on Research in Burns, Edinburgh, September, 1965, Edinburgh E. & S. Livingstone, Inc. pp 327-353. 1966
11. Lister, J. Observations on Ligature of Arteries on the Antiseptic System. The Lancet, April 3 : 451, 1869
12. Lorensetti, O. J. & Others The evaluation of micro-crystallin collagen (Vitene) in experimental burn wounds, presented at the Third Annual Meeting of the American Burn Association, San Antonio, Texas. April 16-17, 1971
13. Martin, M. M. & Boyer, B. E. The use of synthetic skin in lieu of homografts in the treatment of extensive third degree burns J. Trauma 3 : 87, 1963
14. Teplite, C. ; Davis, D. ; Mason, A. D., Jr. & Moncrief, J. A. Pseudomonas Burn Wound Sepsis : I. Pathogenesis of Experimental Pseudomonas Burn Wound Sepsis. J. Surg. Res., 4 : 217, 1964
15. Tepls, C. ; Devis D. ; Walker, H. L. ; Raulston, G. L., Mason, A. D., Jr. & Moncrief, J. A. Pseudomonas Burn Wound Sepsis ; II Haematogenous Infection at the Junction of the Burn and Unburned Hypodermis, J. Surg. Res., 4 : 217, 1964
16. Thielo, M: Synthetic Skin Ready to Try on Humans. Chem. & Eng. News. 43 : 40, (25), 1965