

## TESTIS IN POSTVASECTOMY CASE --A CLINICO-PATHOLOGICAL STUDY OF 50 CASES

*\*Prabha Bastian, M.B.B.S., \*\*Sara Varghese, M.D., \*\*\*P. A. Thomas, M.S., F.R.C.S. and \*\*\*\*Ramakrishnan Nair, K., M.S., M.Ch.*

### Introduction

Vasectomy is widely performed today as a method of male sterilisation and in India it is being advocated on a national scale as part of the population control programme. Now millions of men are undergoing vasectomy all over the world, the question of its long term effect on the structure and function of testis has attained great significance.

### Materials and methods,

Following is a study of 50 cases of vasectomy in whom recanalisation operation was done in plastic surgery department, Medical College, Hospital, Trivandrum between May 1976 to July, 1978. Testicular biopsies were fixed in Bouin's fluid. For comparison testicular biopsies from 50 postmortem cases who succumb in accidents were chosen.

Quantitative analysis of seminiferous epithelium was done in 42 cases employing Sertoli cell number as the basis for reference (Skakkeback et al., 1973)<sup>11</sup> The cells of the seminiferous epithelium were classified according to the criteria given by Clermont, Y. (1963)<sup>2</sup> (Figure 1). A total of 30 tubular cross sections were counted in each case and the mean Sertoli cell ratio was calculated.

Sertoli cell ratio is obtained by dividing the total number of germ cells counted in each of the different types by the total number of Sertoli cells in the same cross section of the tubule. The results are then compared with the control group.

Histometric assessment of testicular biopsies were carried out in 50 postvasectomy cases. 12 randomly selected fields from the Masson's trichrome stained sections were chosen in each case and the total number of fixed points falling on the tubules, Leydig cell clumps and connective tissue were noted and summated giving a total of 180 points using  $\times 12.5$  micrometer eye piece (Dykes, 1969)<sup>4</sup>. From this the ratio of the volumes of tubules to Leydig cells was calculated as follows.

$$\text{Ratio of the volumes of tubules to Leydig cells} = \frac{\text{Number of fixed points falling on the tubules}}{\text{Number of fixed points falling on Leydig cell clumps.}}$$

A follow up study was conducted. After the follow up the testicular biopsies were reviewed and findings were correlated with the results of follow up.

\*Postgraduate student in M.D. Pathology

\*\*Professor of Pathology, Medical College, Trivandrum

\*\*\*Professor of Plastic Surgery, Medical College Hospital, Trivandrum

\*\*\*\*Assistant Prof. of Plastic Surgery, Medical College Hospital, Trivandrum

### Observations and Results

The age of the patients at the time of vasovasostomy ranged from 18-41 years, with the majority belonging to 3rd and 4th decades. The interval from vasectomy to vasovasostomy was 11 months to 17 years, the most common intervals were 3 and 5 years. Table I shows the different reasons for recanalisation. The different histological changes observed is shown in Table II, (Figures 2, 3, 4, 5, 6, 7, 8, 9 and 10).

In the quantitative analysis, the only statistically significant change observed was increase in the Sertoli cell ratio for preleptotene primary spermatocytes ( $P < 0.01$ ).

Histometric assessment of testicular biopsies revealed statistically significant decrease in the ratio of the volumes of tubules to Leydig cells in the postvasectomy group ( $P < 0.01$ ) thereby indicating increase in Leydig cell volume after vasectomy.

Results of follow up is shown in Table III of the 2 cases who had azoospermia on Semen analysis, one showed Sertoli cell only pattern in histopathology (figure 10).

### Discussion

Phadke et al (1967)<sup>10</sup> stated that age of the patients at the time of vasovasostomy does not affect the result of anastomosis. In the present study age of the patient and duration after vasectomy did not affect much the outcome of Vasovasostomy. The reasons for recanalisation commonly encountered in the literature are remarriage after divorce, death of children, death of wife, improved economic situation and psychological desire to overcome the supposed ill effects of vasectomy. In this study also the reasons are similar except for vasectomy done before marriage (Table I).

Table 1.

*Distribution of Cases according to reasons for vasovasostomy*

Reasons for Vasovasostomy	Number of cases	Percentage
1. To have more children	18	36
2. Vasectomy done before marriage	17	34
3. Divorce and remarriage	8	16
4. Child died	6	12
5. Wife died	1	2
Total	50	100

Spermatogenesis continued unabated in the human testis after vasectomy and that the Sertoli cells act to phagocytose the sperm cells (Davis, 1977)<sup>3</sup>. Borbow, (1973)<sup>1</sup> found that abnormality commonly encountered after ligation of excretory ducts of testis is desquamation of germ cells into the lumen of the tubules. The most frequent histological change noted in this study was sloughing and disorganisation with active spermatogenesis. Although the testis continue to produce spermatozoa after vasectomy, its activity is depressed but is capable of complete return to normal after relieving the obstruction in the vas (Hackett, 1973)<sup>6</sup>. 5 out of 9 patients who showed hypospermatogenesis in this study reported pregnancy on follow up. Mancini et al (1976)<sup>9</sup> stated that obstruction in the efferent duct can lead to spermatozoa and consequently to extravasation of sperms into the interstitium of testis or epididymis and this leakage may be the most important factor in the formation of sperm antibodies. Extravasation of spermatozoa is seen in 2 cases in this study. Spermatogenic arrest at spermatid level was noted by Fallon et al (1978)<sup>5</sup> from their study on 41 cases. In the present study this change

was noted in one case and he had 2 children after reanastomosis thereby denoting it a reversible change.

Quantitative analysis revealed a statistically significant increase in the Sertoli cell ratio for preleptotene primary spermatocytes. The increase may be due to the action of pituitary gonadotrophins (FSH) and LH which are released due to the feedback mechanism mediated through inhibin, a hormone secreted by the testis. FSH has been shown to increase the mitotic rate of germ cells but the exact step in spermatogenesis at which it acts is not known (Johnson et al, 1977)<sup>7</sup>.

Steinach (1927)<sup>8</sup> put forward a hypothesis that vasectomy can rejuvenate the aging males by improving the endocrine function of the testis. Kothari et al (1975)<sup>8</sup> stated that vasectomy produce a modest increase in Leydig cell volume. They suggested a humoral feedback mechanism from the testis to anterior pituitary which in turn stimulates the Leydig cells. Present study also shows an increase in Leydig cells, after vasectomy.

Surgical success rate is higher than the pregnancy rate in this study and in most of the studies reported in the literature. Phadke et al (1967)<sup>10</sup> had 83% success with 55% pregnancy rate. Surgical success is 94.8% and pregnancy rate, 63.2% in this study. The duration of follow up, semen quality, fertility status of wives and immune factors are important in the evaluation of pregnancy rate after reanastomosis. A previous unsuccessful Vasovasostomy is not a contraindication to reoperation as evidenced by successful result after repeat vasovasostomy in the present study. This study also suggests the importance of taking testicular biopsy at the time of reanastomosis in order to avoid unnecessary repeat operation in irreversible conditions like sertoli cell only pattern.

### Summary

Vas deferens anastomosis was carried out in 50 cases. The different histological findings noted are normal histology, sloughing and disorganisation with active spermatogenesis, hypospermatogenesis, Leydig cell hyperplasia, focal atrophy of tubules, peritubular thickening, extravasation of spermatozoa, spermatogenic maturation arrest and sertoli cell only pattern (Table II). Surgical success was 94.8% and pregnancy rate, 63.2%. The high percentage of successful reanastomosis of vas is likely to enhance the acceptability of vasectomy as a method for family limitation and population control. However the relatively low pregnancy rate in spite of high surgical success requires further investigation.

**Table 2.**

*Testicular histology in 50 postvasectomy cases*

Histological type	Number of cases	Percentage
1. Normal histology	6	12
2. Sloughing and disorganisation with active spermatogenesis	20	40
3. Hypospermatogenesis cases	9	18
4. Leydig cell hyperplasia	6	12
5. Focal atrophy of tubules	3	6
6. Peritubular thickening	2	4
7. Extravasation of spermatozoa	2	4
8. Spermatogenic maturation arrest	1	2
9. Sertoli cell only pattern	1	2
Total	50	100

**Table 3.**

*Results of follow up 38 cases*

Results of follow up	Number	Percentage
1. Pregnancy	24	63.2
2. Semen positive only	12	31.6
3. Semen negative	2	5.2
Total	38	100

## REFERENCES

1. Bobrow, G. L. : Testicular biopsy. Recent advances in Clinical Pathology. Dyke, S.C., D.M. (Oxon.), F.R.C.P. (Lond.), (editor). Churchill Livingstone, Edinburgh and London, 1973. P. 123-132.
2. Clermont, Y. : The cycle of Seminiferous epithelium in man. *Am. J. Anat*; 112: 35-45, 1963.
3. Davis, J. E. : Status of male contraception. *Obstetrics and Gynaecology Annual*. Ralph M. Wynn. M.D. (editor), New York Volume 6, 355-369, 1977.
4. Dykes, J. R. W. : Histometric assessment of human testicular biopsies. *J. Path.* 97 : 429-439, 1969.
5. Fallon, B., Elias, J. and Raymond, G. B. : Restoration of fertility by Vasovasostomy. *J. Urol.*, 119 : 85-86, 1978.
6. Hackett, R. E. : Vasectomy. *Am. J. Obstet. Gynecol.*, 116 : 438-455, 1973.
7. Johnson, A. D. and Gomes, W. R. : *The Testis*. Academic Press, Inc. (London) Ltd., 1977, P. 189.
8. Kothari, L. K., Gupta, A. S., Dhruva, A. and Bapna, B. : Surgical sterilisation of the male and its effects on the structure and function of the testis in man. *Br. J. Surg.* 62 : 59-64, 1975.
9. Mancini, R. E. : Immunological aspects of testicular function *Monographs on Endocrinology*. Volume. 9. Edited by Gross, F., Grumbach, M. M., Lipsett. M. B., Mann. T. and Samuel L. T. Springer-Verlag. Berlin Heidelberg, New York, 1976, P. 93.
10. Phadke, G. M. and Phadke, A. G. : Experiences in reanastomosis of vas deferens. *J. Urol.* 97 : 888-890, 1967.
11. Skakkeback, N. E. and Heller, C. C. : Quantification of human seminiferous epithelium. *J. Reprod. Fertil* ; 32 : 379:389, 1973.


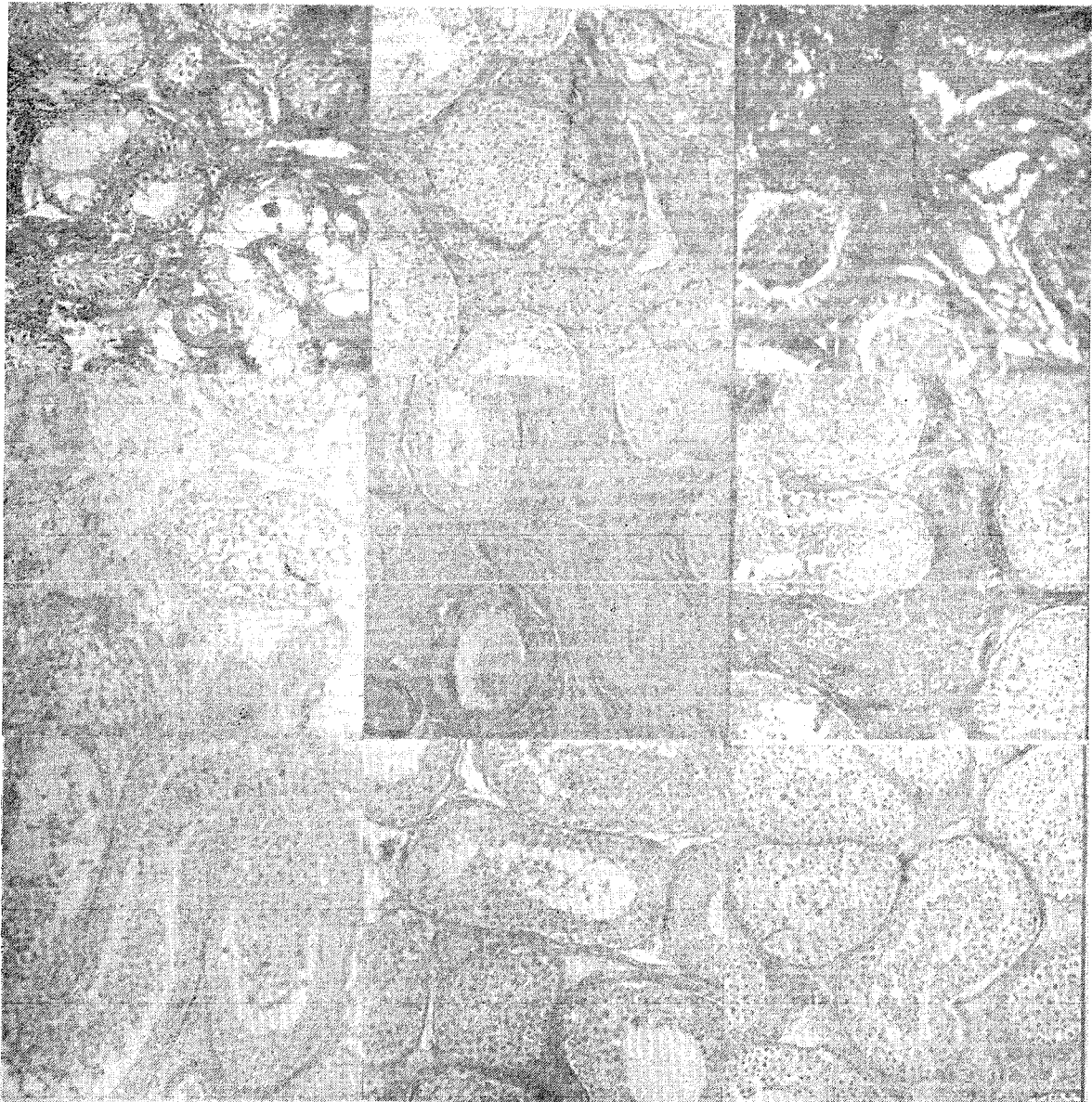


Fig. 1. Diagrammatic representation of the cellular composition in human seminiferous tubules SER-Sertoli cell, Ad-dark type A spermatogonia, Ap-pale type A spermatogonia, B-B type spermatogonia, PL-preleptotene primary spermatocytes, L-Leptotene primary spermatocytes, P-Pachytene primary spermatocytes, Sa and Sb-early spermatids, SC & Sd-Late spermatids, RB-Residual bodies.

2

3

4



5,6

7

8

9

10

Fig. 2. Testicular biopsy showing active evidence of spermatogenesis. (Haematoxylin and eosin  $\times 100$ ).

Fig. 3. Testicular biopsy showing sloughing and disorganisation (Haematoxylin and eosin  $\times 100$ ).

Fig. 4. Testicular biopsy showing hypospermatogenesis (Haematoxylin and eosin  $\times 100$ ).

Fig. 5. Testicular biopsy showing sheets of Leydig cells hyperplasia (Reticulin  $\times 100$ ).

Fig. 6. Testicular biopsy showing hyalinised tubules, tubules with moderate evidence of

spermatogenesis and sheets of Leydig cells (Van Gieson  $\times 100$ ).

Fig. 7. Testicular biopsy showing thickening of the tunica propria (Van Gieson  $\times 100$ ).

Fig. 8. Biopsy of epididymis showing extravasation of spermatozoa in the interstitium (Masson's trichrome  $\times 100$ ).

Fig. 9. Testicular biopsy showing extravasation of spermatozoa in the interstitial tissue (Van Gieson  $\times 100$ ).

Fig. 10. Testicular biopsy showing sertoli cell only pattern. (Masson's trichrome  $\times 100$ ).