

Palmar Split Skin Graft for Resurfacing Flexor Aspects of Fingers

Acharyya, S. K.*

THE flexor aspects of fingers require resurfacing when the skin is lost either from recent trauma or is replaced by a scar. The usual procedures for the resurfacing of the flexor aspects of fingers are :

- (a) Full thickness skin grafts
- (b) Thick split skin grafts
- (c) Local Flaps
- (d) Distal Flaps.

The basic principle in reconstruction of a body surface is replacement with new tissues having similar texture and surface quality. The skin of the palm is cosmetically and functionally an unique structure. Functionally the skin is superior to that of the other parts of the body as it consists of a thick epidermis which covers a high concentration of dermal papillae. Cosmetically the hand enjoys exposure only second to the face. So ideally the resurfacing of the flexor aspects of fingers should be done by the skin of the palm.

Full thickness skin grafts from the hairless parts of the body are extensively used for resurfacing the palm and volar aspects of fingers. Though these grafts are supple and their subsequent contracture is negligible, the order of sensation they regain

falls short to that of whole or split palmar skin graft. Moreover the cosmetic effects of such grafts are poor. It is well known that split thickness skin grafts are much inferior to whole thickness skin grafts both cosmetically and functionally.

Cross-finger flaps are hairy, the donor site is limited and very few cases are suitable for such flaps. Distal flaps from the abdomen or thigh can best be described as unsightly insensitive blotches. Direct palmar flap can only be used for reconstruction of the contour defects of the terminal pulp of fingers.

The skin of the sole has many features in common with the skin of the palm. Webster (1955) advocated full thickness graft from the medial aspect of the foot for resurfacing the flexor aspects of hand. The technique however, requires secondary split skin grafting of the foot defect. This limitation was lessened by Leeworthy (1963) and Erro (1972) who used split skin graft from the instep of the foot. These procedures gave superior results compared to split or full thickness skin grafts from other parts of the body but have the disadvantage of creating concurrent morbidity of both hand and foot.

*Classified Specialist (Reconstructive Surgery), Command Hospital, Central Command, Lucknow-2.
This Paper was presented at the XXXV Annual Conference of ASI.

Split thickness skin grafts from ulnar border of the hand has been used by Patton (1939). Its limitations are that very small area of skin is available as donor which has a hairlined border. Lie (1970) suggested free whole skin grafts from palm. The cosmetic as well as the functional results were excellent, but the disadvantage is that the donor area is very limited. Worthier (1973) has used palmar split skin graft for a long period with excellent functional and cosmetic results and without any complication of the donor area which has been the inspiration for undertaking the present study.

Material

The palmar split skin grafts have been used for resurfacing the flexor aspects of fingers in 18 cases. The indications were varied and is described in Table 1.

Table-1

Indication	No. of cases
Fresh wounds	2
Septic wounds	2
Post-burn Contractures	9
Dupuytren's contracture	1
Post-Tenosynovitis scars	2
Coverage of defect after Heuston's flap	2
Total	18

The total number of grafts needed in these cases were 24. All the grafts took well except one. The failure in one case was due to very poor vascularity of the recipient area, a post-tenosynovitis scar (Table 2).

Table-2

Indication	No. of cases	No. of grafts	Take of grafts
Fresh wounds	2	2	2
Septic wounds	2	2	2
Post Burn Contractures	9	14	14
Depuytren's Contracture	1	1	1
Post Tenosynovitis scars	2	2	1
Surgical defect created after Heuston's flap	2	3	3
Total	18	24	23

Technique

Both the hypothenar and thenar eminences have been used as donor sites. General anaesthesia is preferred. Its advantage over local analgesia is that an exsanguinating tourniquette can be used, which facilitates speedy and precise excision of the scar and keeps the donor site free of dressings which may hinder the operative procedure. A graft of intermediate thickness and appropriate site is removed free hand by Humby's knife. The graft is cut to the pattern of the defect and sutured into place in the standard fashion. It must be handled with care as it has little extensibility and its edges are fragile. Standard dressings for the graft and donor site are used. The first dressing may be carried out on the seventh day. The graft this time will look dark but this should not disappoint the surgeon as it is due

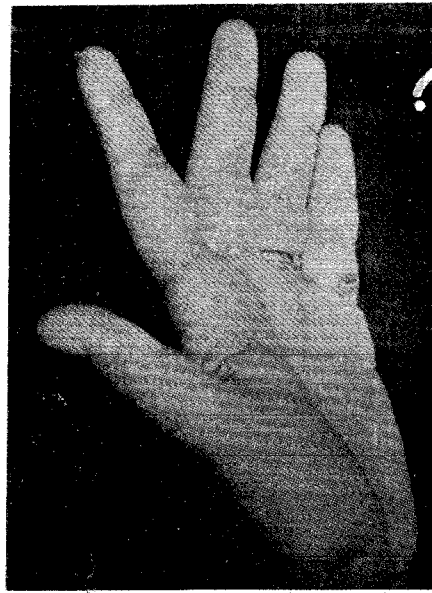
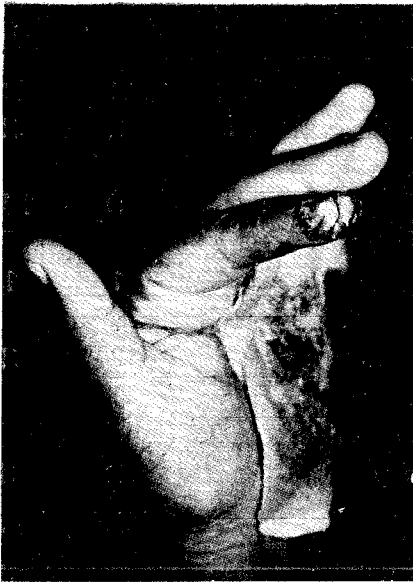

Fig. 1 (a) The post operative picture on 8th day and Fig. 1 (b)—shows the final result. The cosmetic effect is excellent.

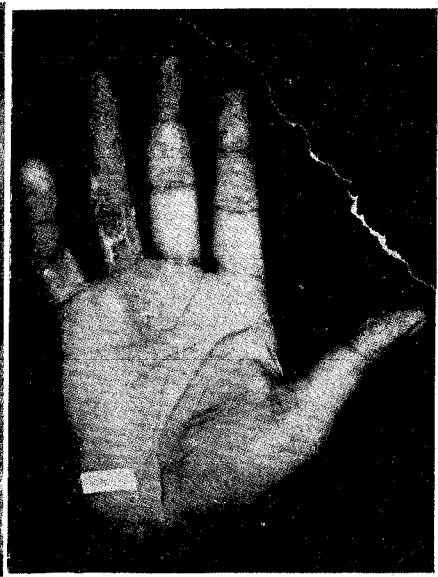
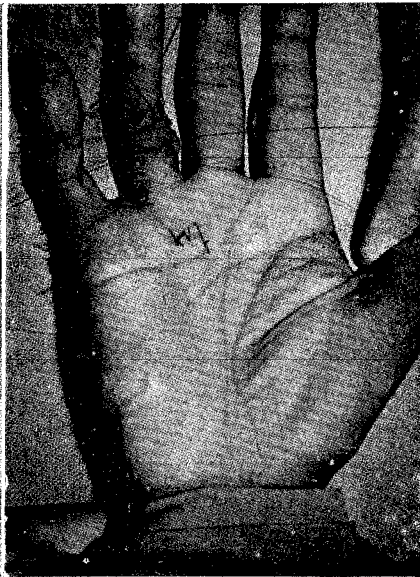
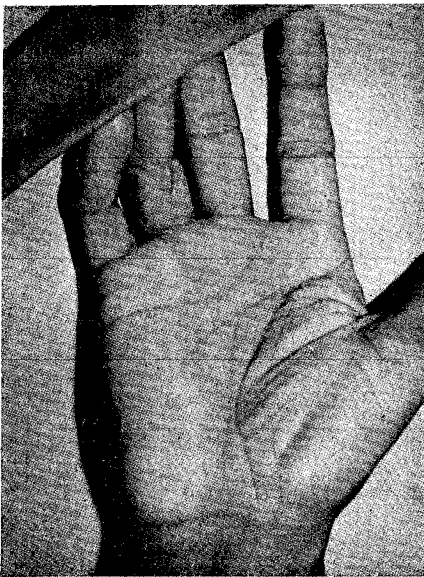


Fig. 2 (a)—Dupuytren's contracture affecting ring and little fingers.

Fig. 2 (b)—The contractures were excised and the defect of the ring finger was covered by split palmar skin graft from the hypothenar eminence.

Fig. 2 (c)—The final result.

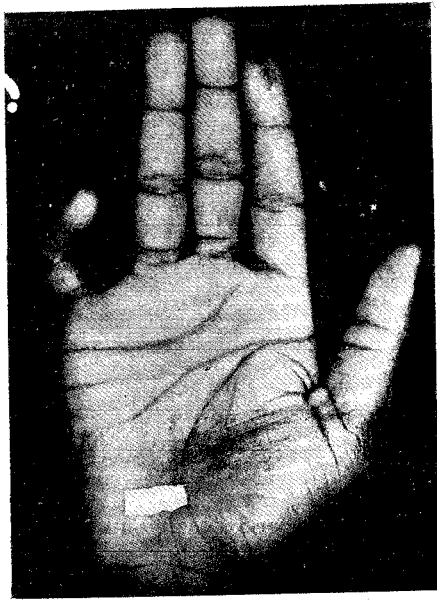


Fig. 3 (a)—Contracture of little finger following tenosynovitis.

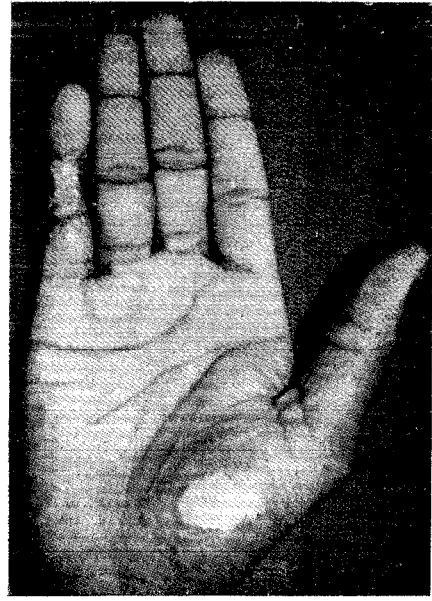


Fig. (b)—Shows the final result obtained after excision of scar and palmar split skin graft.

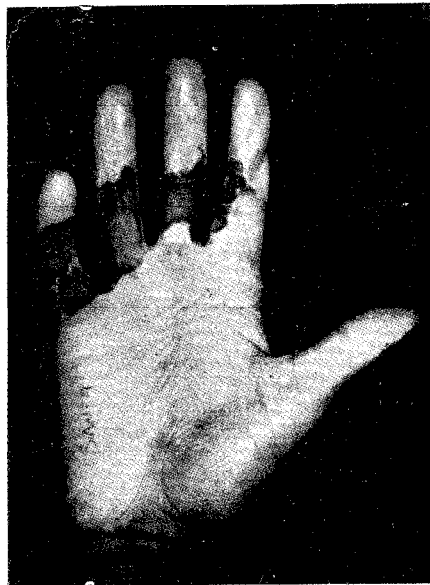


Fig. 4 (a)—Post-burn contractures of fingers, the coverage of defects was by split skin grafts.

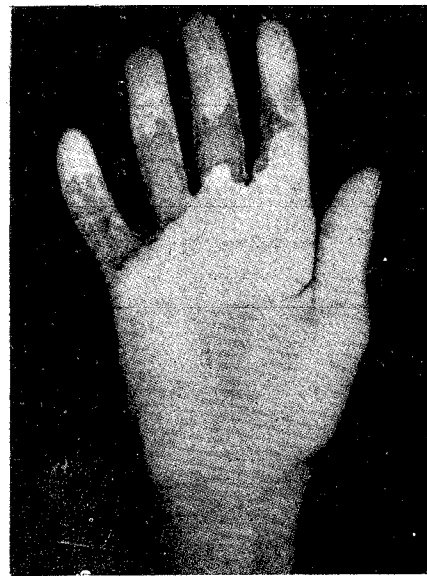


Fig. 4 (b)—Recurrence of contracture of the little finger was corrected by palmar split skin graft.

to the eschar consisting of stratum corneum mostly. In next few days the eschar separates out and the new dry pink surface with ridge formation appears. The donor site heals up by three weeks and the protective dressings both for the recipient and donor site may be discarded after this period. Some representative cases are illustrated (Fig. 1 to 9).

Results

Out of 24 grafts 23 took well. The only failure as described earlier was due to excessive scarred bed of the recipient site of a finger badly damaged by tenosynovitis. The return of sensation was speedy and almost complete in all cases.

Conclusion

The palmar split skin graft is ideal for resurfacing the defects of the volar aspects of the fingers. The return of sensation is speedier and it is certain that the dermal papillae of these grafts provide tactile sensory power superior to other grafts. The cosmetic results are excellent. There is no donor area complications.

Acknowledgement

The author expresses his deep gratefulness to the Director of Medical Services, Army, for his kind permission to publish this paper.

REFERENCES

1. Webster, J. P. : Skin grafts for hairless area of the hands and feet, *Plastic and Reconstructive Surgery*, 15 : 93, 1955.
2. Leeworthy, G. W. : Sole skin as donor site to replace palmar skin, *Plastic and Reconstructive Surgery*, 32 : 30, 1963.
3. Patton, H. S. : Split skin grafts from hypothenar area for fingertip anovulsions, *Plastic and Reconstructive Surgery*, 43 : 426, 1969.
4. Lie, K. E., Magargle, R. K. and Posch, J. L. ; Free full thickness skin graft from the palm to cover the defects in the fingers. *Journal of Bone and joint Surgery* 52—A : 559, 1970.
5. Erro, E. P. : Grafting of Palmar areas of hand with plantar skin of the feet, *Rev. Espan. Cir. Plast.*, 5 : 175, 1972.
6. Worther, E. F. : The palmar split skin graft, *British Journal of Plastic Surgery*, 26 : 408, 1973.