

Extension of Direct Pedicle Skin Flap—An Experimental and Clinical Study

Thind, R. S.* Singh, P. D.** Kaur, H.

THE direct pedicle skin flap is a very useful method of skin transfer. It is not only fast but also it is a clean and sound method in good hands.

Transferring a direct pedicle skin flap of L. B. ratio of 1:1 with proper base and easy position and fixation is a safe method. However, when L.B. ratio is 2:1 or even more or multisurface covering is required or when vascular compartments of thighs or leg are to be transgressed, a delay procedure is indicated, Primary delay may be useful in some cases but it is the experience of the authors that it does not work well in the above mentioned situations. With a purpose to study a good method of secondary delay or extension of the flap, this experimental and clinical study was done at the Department Of Plastic Surgery, Medical College, Patiala.

Experimental Study

Female Pigs of 19-20 kg. were used as experimental animals as these are most suitable for such a study (Patterson 1968). Premedication of Pathedine 100 mg and atropine 0.6 mg. was given. The pig was then given Nembutal 15 mg/kg intramuscularly and when the pig was asleep it was shaved and prepared and put on the table. The

anaesthesia was maintained by ether by open drop method keeping a good watch on respiration.

In first group of five pigs paramedian flaps going to flanks were raised 4 cm. away from the vessel line. A set of three flaps on each side were made and a flap was standardised which would survive (Fig. 1 and 4). These flap were 4 c.m.

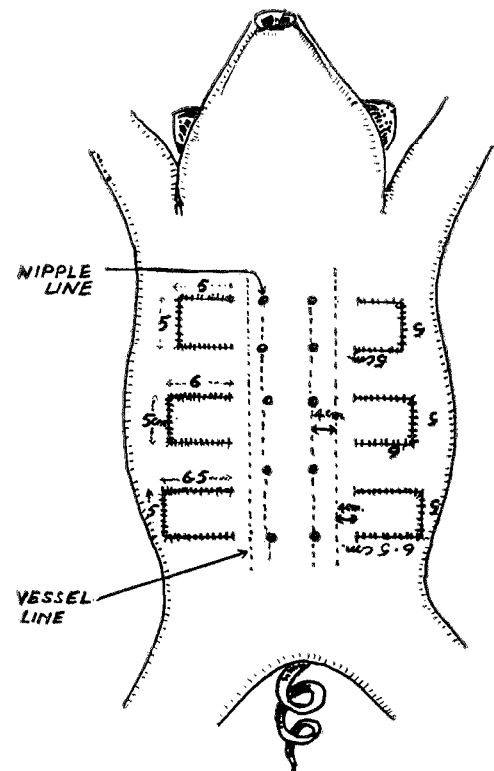


Fig. 1—Standard Flaps Raised and Stitched Back

*Professor & Head of Deptt. of Plastic & Maxillofacial Surgery, Govt. Medical College, Patiala.

**Professor of Anaesthesia, Govt. Medical College, Patiala.

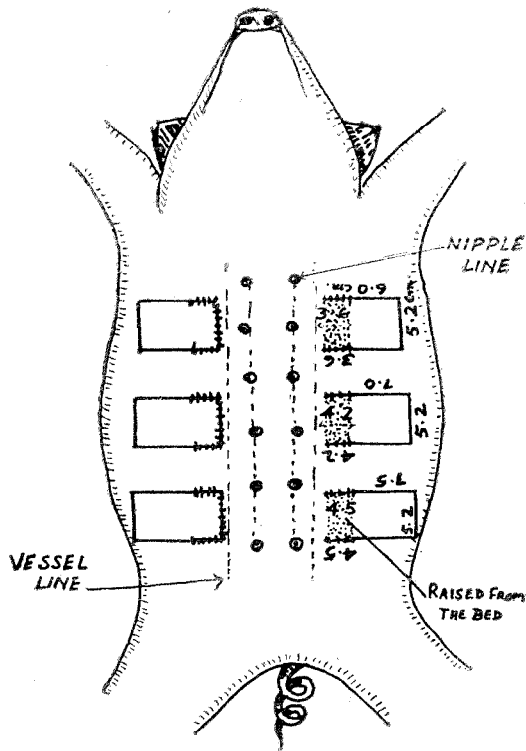


Fig. 2—Extension (Delay) of Flaps Three Weeks Later

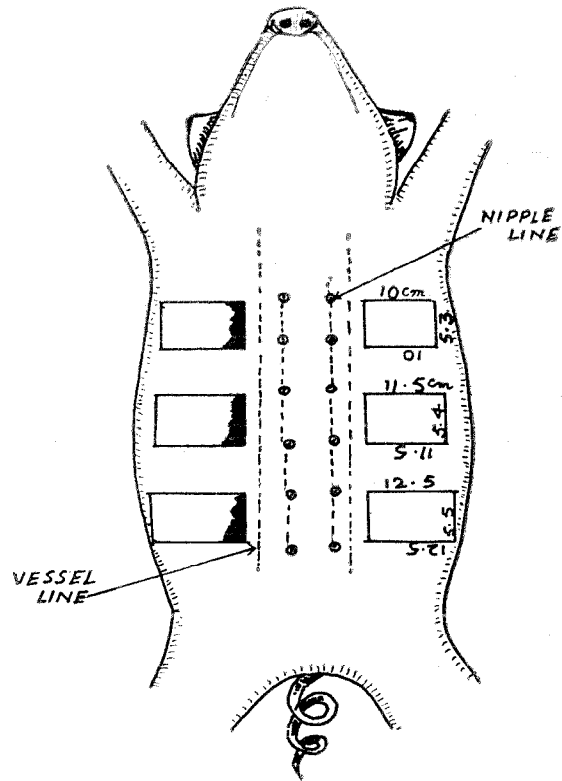


Fig. 3—Result. Two Weeks after Raising of Extended Flaps
Note Necrosis on one side.

from vessel line or 8 cm. from the nipple line and were 5cm. x 5 cm; 6cm. x 5cm. and 6.5 cm x 5 cm cephalic to caudal end respectively.

In the second group of pigs, after initial raising and stitching back of standard flap as detailed above, three weeks later, the flap was extended medially towards vessel line by two different methods on each side. On one side it was extended to the extent of the size of original flap by incising on three sides and suturing the wounds. On the other side the flap extension to the same extent was done by dividing on the two parallel sides and raising the extended portion from its bed. The parallel incisions were then stitched.




Fig. 4—Standard flaps on removal of stitches, flaps grow with the pig.

One week later the extended flap was

raised from all sides except its base which was the base of the primary flap and stitched back. It was noticed that after few days necrosis occurred on both sides in the extended flaps. It was more on the side where extension was done by first method. In subsequent pigs the length of extended flap was reduced gradually till no necrosis occurred on one side i.e. the side where extension was done by giving parallel incision and raising of flap from its bed but it occurred in the other side. The length of extension in such animals was 0.6 times of the original flap.

In third group of five animals the primary flaps were raised as described above and one type of extension was done on each side, extended flap was 0.6 time the original flap, and it always grew in the period which elapsed between first and second operations. It was observed uniformly that the extended flap always survived on the side where delay was done by parallel incisions and raising the flap from the bed, and it always necrosed to varying extent, on the side where extension was done by incising on three sides and not raising the flap at the delay operation (Fig. 2-3 and 5-8). In early stages necrosis was cheesy white (Fig. 6), then it became blue, subsequently brown (Fig. 7) and finally black (Fig. 8).

Thus it was convincingly proved that extension by parallel incision and raising the extended portion from its bed was the superior and safe method of extension of flap (Secondary delay).

Clinical Study

Based on the experimental study

described above the same method of extension was applied on the clinical cases. This extension method was used when :

- (i) L.B. ratio of the flap was well more than 1:1.
- (ii) Multisurface covering of limbs, where large transfer at the primary stage will jeopardise the flap survival because of antigravity drainage of the part of flap.
- (iii) Transgressing vascular compartments of leg or thigh.

Material and Method

This series include 74 cases of extension of flap (Table 1)

Table 1

Sr. No.	Type of flap	Donor site of extension	No. of cases
1.	Cross thigh flap	anterior and medial surface	30
2.	Cross thigh flap	Lateral surface	20
3.	Abdominal flap	Lower abdomen	16
4.	Cross leg flap	Postromedial surface	8
Total			74

In these cases planning was done so that the adequate site and size of flap was marked. The position to be kept after operation and after separation of flap, were studied. Gravity drainage of the flap was kept in mind at all stages of transfer. At the primary operation, the flap of adequate size was transferred. Proper fixation and position of the patient was

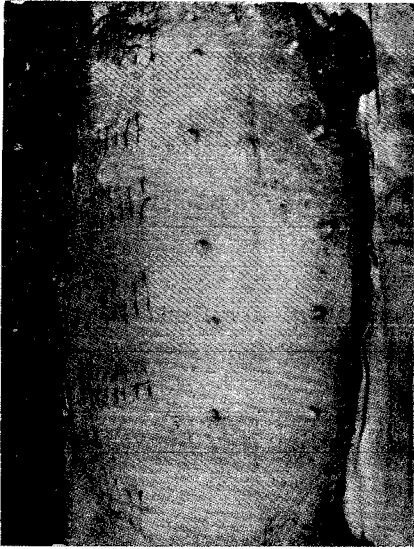

Fig. 5—Delay by parallel incisions, undermining of the extended flap and suturing.




Fig. 6—Cheesy white necrosis on side extended by division on three sides.

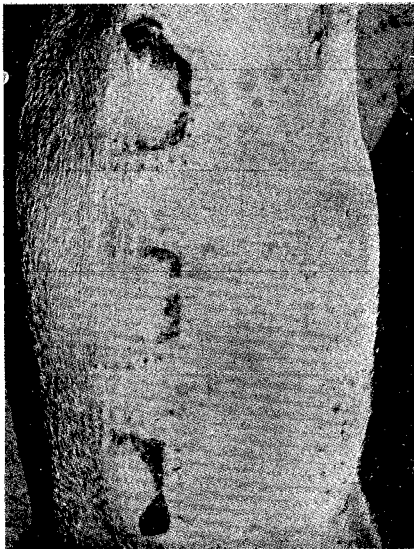

Fig. 7—Brownish black necrosis, Note no necrosis on the other side where extension was done by parallel incision and its raising from bed.

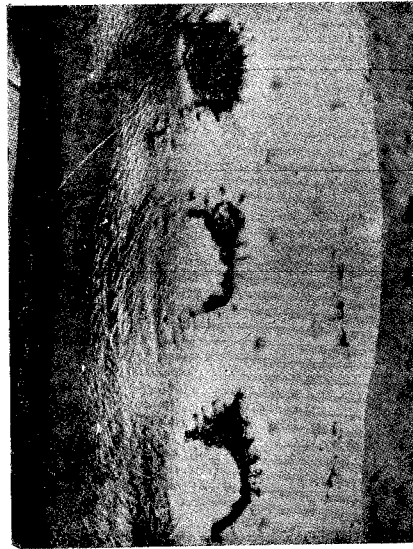

Fig. 8—Black necrosed flap (Partial). No necrosis on the other side.

kept to favour gravity venous drainage and also to avoid, tension and torsion of the base. Three weeks later the desired extension of the flap was done by incising on the two sides and raising it from its bed with the base of the extended skin at the primary flap. Raising from the bed should be thorough and then two side incisions are stitched. The bed of extended portion was packed with Eusol soaked gauze to avoid union of raw surfaces (Fig. 9, 10, 12). The pack was changed once or twice and culture and sensitivity of the swab from the raw area was done. One week after the extension, the distal end of the extended flap was divided, two parallel incisions already given were opened up so that the extended flap came onto recipient limb with its base at the primary attached portion. The extended flap was adjusted on the recipient area after excising the remaining scarred area. The donor site of the extended flap was split skin grafted.

Proper gravity venous drainage was kept by positioning the limb and the patient, so that the extended flap drained into primary flap.

In few cases, when extension desired was too big (Fig. 12) the colour of extended flap showed bluish tinge due to venous congestion when it was set into proper recipient area. This was because the gravity drainage of extended flap was impeded. In such a situation the flap was not set into the recipient area but kept in proper venous drainage position by a big bolus kept on the recipient site. This proper venous drainage was kept for one week and

then the flap was stitched to the recipient area, It then survived very well.

Discussion :

Transfer of large amount of full thickness skin is very often required in a Plastic Unit which cater to limb trauma-burns, accident or fracture with bad early care (Volkman's Ischaemic Contracture).

There are large number methods of skin transfer but direct pedicle skin transfer is a fast method. Tube pedicle, marsupial flap and jump flap are all multistaged procedure and take 4-5 months with fixation of the upper limb when it is used as intermediate carrier.

Direct pedicle skin flap needs gravity venous drainage with no tension and torsion of the base on the flap. Therefore it can cover one surface of the limb. For very big flaps where multisurface cover or even circumferential cover to the limb is required, single stage flap transfer will not be possible. Here a secondary delay or extension of the flap is required.

There are number of methods of delay or extension.

1. Division of three sides, except base, of extended flap.
2. Two side division without raising of extended flap from the bed.
3. Division of two parallel sides with raising of flap from the bed.

These methods have been studied experimentally and described before.

The last method, i.e. incising two

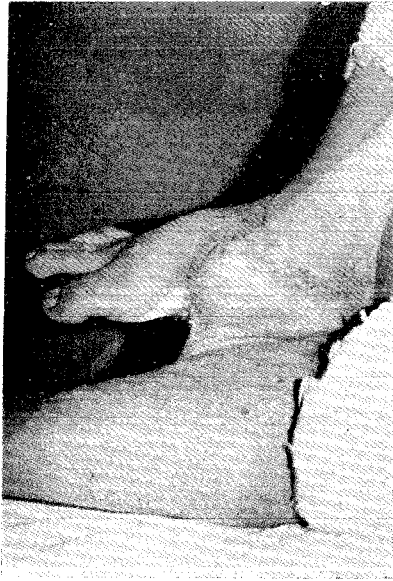

Fig. 9—Cross leg flap.

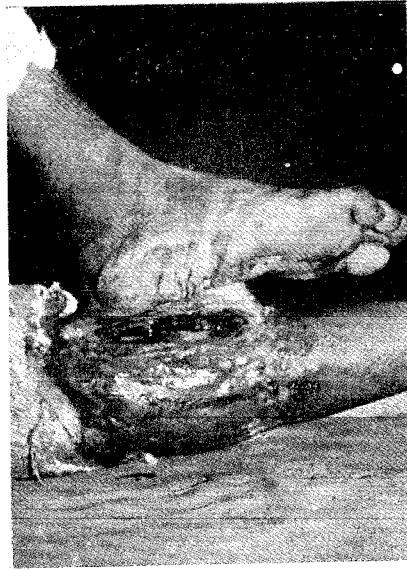

Fig. 10—Flap extended by undermining after parallel incision.

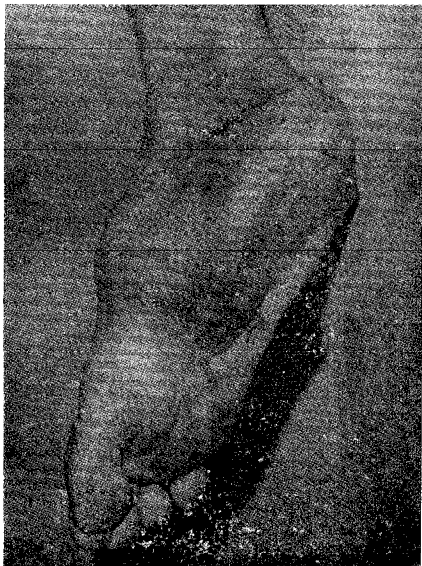

Fig. 11—Final result after transfer of extended flap.

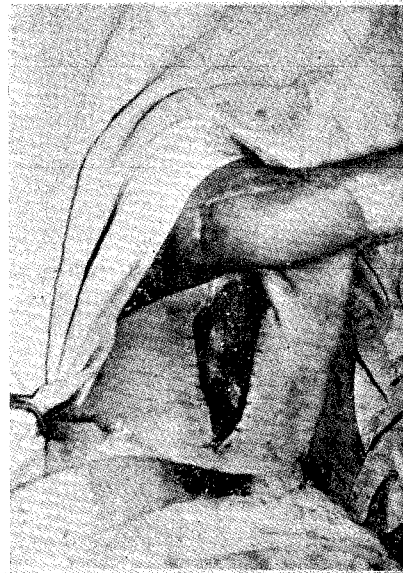


Fig. 12—Abdominal flap to the arm. Note the amount of extension. Raw bed is visible. L.B. ratio was 3:1.

parallel sides and raising the flap from its bed, so as to divide the perforators which are an important mode of blood supply of skin of limb and abdomen, is excellent. A week later the extended flap is separated from the donor site and set into the recipient area. This method has given excellent results in the hands of authors (Fig. 11) and a large or even circumferential flap cover has been provided to the limbs by using this technique.

This method has one defect, that it leaves a raw surface under the flap and on the donor site of extended flap at the time of extension. This disadvantage is not of great importance because with the Eusol pack this pocket can be kept infection free or at least infection is kept under control. Then it does not interfere with healing of flap after final transfer, and the take of the

graft at the donor site. Infection rate has been minimal with no losses of any consequence either due to infection or necrosis.

Summary

The paper describes an experimental method of extension (Secondary delay) of flap carried out in pigs. A method of extension where parallel incision and raising of extended flap has been done is found very suitable in large number of situations where large flap transfer is required.

This method has been extensively tried clinically (Seventy four cases) at various donor sites and in various required situations with excellent result. It has practically eliminated flap necrosis in authors hands.

REFERENCE

- Patterson, T.J.S. : The Survival of skin flaps in the Pigs, Brit. J. Plast. Surg., 21:113, 1968.