

## On Congenital Malformation of hands and feet

\*C.N. Malla, †Nancy Malla, ‡G.M. Mir, †B.M. Bhan,

### Introduction :

A study covering three families, presenting various congenital anomalies of hands and feet was made in SMHS Hospital, (Medical College, Srinagar).

### Case Report :

Farida 14 year girl was admitted in our surgical ward in July, 1973 with complaints of flexion contractures of the Right little finger and flexion contracture of toes since birth.

Examination revealed that the range of movement was about 5 degrees. She had also traumatic loss of terminal phalanx of right finger following operation elsewhere in childhood for syndactyly.

Family history revealed that the patients mother, elder sister's children and her own youngest brother were having congenital anomalies of hands and feet, Her grand parents (Paternal as well as maternal) were normal. There is no history of abortion, miscarriage or of stillbirths in the families studied. The mothers of the afflictions patients do not remember having taken any drugs during pregnancy. The names and afflictions of these patients is listed in the accompanying Table 1.

Farida on being operated achieved 90 degree extension of her little finger.

### Discussion :

According to Converse (1958) two sets of factors are commonly the cause of deformities.

1. Genetic or Hereditary.
2. Environmental.

In our series Noora (the mother) is affected as shown in Table 1, clinical photographs and accompanying X-ray pictures. Her first, third and fourth children are normal while 2nd and fifth child is affected revealing a greater incidence of congenital anomalies among subsequent children in the families studied, which coincides with the observation of Murphy, 1947 that if there is one defective child in the family the birth of the subsequent malformed children takes place with a frequency of about twenty five times greater than that of the general population.

Among the environmental factors believed to interfere in the development during first trimester of pregnancy none did seem to play any part in the causation of deformities observed in this series.

---

\* Lecture in Plastic surgery. † Assistant surgeon. ‡ Lecture Radiology.  
† Professor and head of deptt. of Surgery, Govt. Med. College, Srinagar, (Kashmir).



Fig. 1

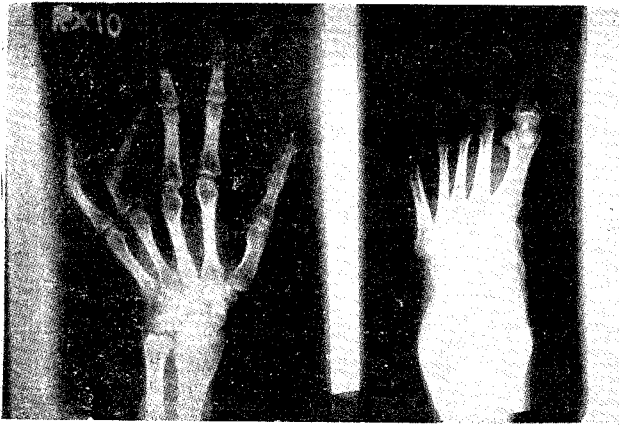


Fig. 2

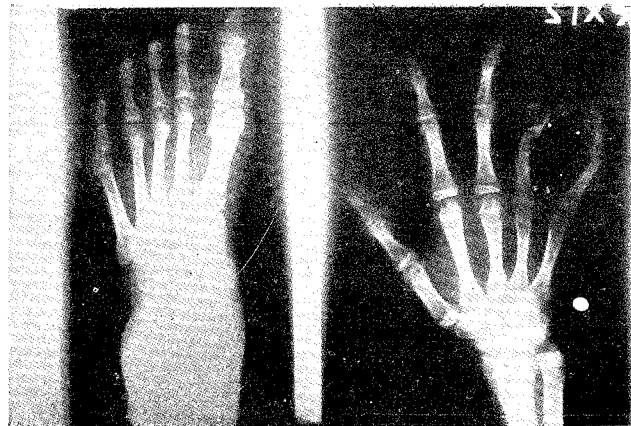


Fig. 3

Father Gulla  
Mother Fata

Noora (female)  
—Clinodactyly of rt. little finger (Fig. 1)  
—Arthrogryposis of toes (Fig. 2)

Mumtaz female normal  
—Ashraf (male) Clinodactyly rt. hand.  
—Iqbal (male) normal.

Female  
1st child Naseema—(Boba. normal)  
normal. (Rehana-Syndactyly rt hand.)  
2nd Farida :  
—Camptodactyly little finger (Fig. 1)  
—Syndactyly rt. hand  
—Arthrogryposis toes (Fig. 3)

Male-Nama  
3rd child normal.  
4th child Ashraf—normal  
5th Firdos-Syndactyly rt. hand.

#### REFERENCES

1. Converse, J.M : Congenital anomalies of hand : Reconstructive Plastic Surgery. p, 1676-4th Vol. W.B. Saunders Co., Lond. 1964.
2. Murphy : Quoted by Barsky, A.J.: Congenital anomalies of hands and feet Principles and Practice of Plastic Surgery. 2nd Ed. (1960). McGraw Hill Book Co., London.