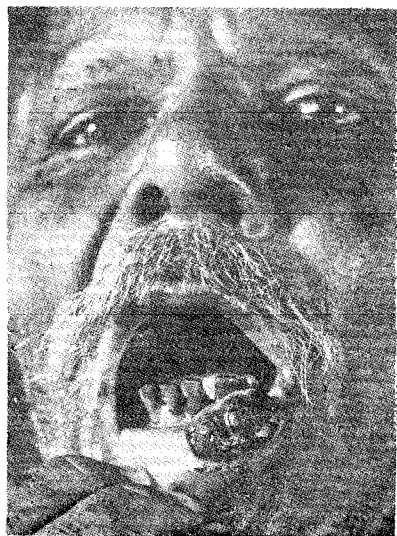


Cervical Tube Pedicle Graft in the Reconstruction of Full Thickness Defect of the Lower Lip

P. L. Bafna and Miss Kamla Sharma*

Cheiloplasty of the lower lip with two flaps from the unaffected upper lip was performed by Stein, as early as 1847, since then Sabattini (1857), Estlander (1872), Abbe (1898), devised their technique independently of each other, utilising the upper lip in the reconstruction of lower lip.

Von (1859), used bilateral full thickness naso-labial flaps for the reconstruction of lower lip. Gillies (1957), reconstructed lower lip by mobilisation and readjustment of the skin of the cheek. Olivary (1973) performed a one stage reconstruction of lower lip by subglandular flaps and provided the vermilion border



from the nasolabial mucosa. Harvey (1974) went a stage further in utilising the tongue

flap in the reconstruction of lower lip.

The use of a cervical skin tube for reconstruction of the lower lip is not preferable over the methods mentioned before, but was useful in our elderly patient whose lower lip was involved almost completely with malignant disease.

Case Report

A 75 year old man was admitted at M. C. Hospital, Jodhpur with a greyish white, raised, indurated, and ulcerated growth involving more than half of the lower lip on left side (Fig. 1). It had started near the left angle of the mouth close to the vermilion border six months previously. It had progressed gradually to involve almost 2/3 of the left side of the lower lip. The remaining third of the lower lip was covered by a leukoplakic patch, which extended down to the gingivo-labial fold. Biopsy revealed it to be a squamous cell carcinoma stage II.

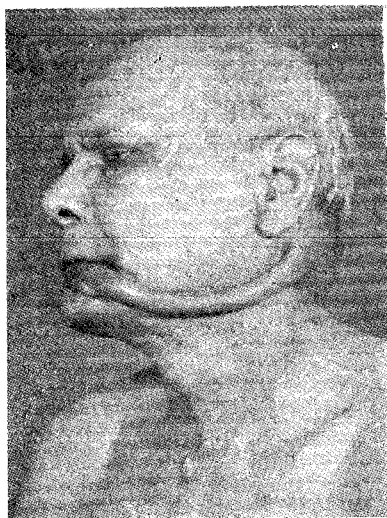
As the growth was involving almost the entire lower lip, a complete excision of the lower lip barring a small portion near the right angle was undertaken. The skin was stitched to mucosa.

Simultaneously a cervical tube was raised from the neck extending from mastoid region to the right side of suprasternal notch.

* Reader in Surgery, S.N. Medical College, Jodhpur.

** Lecturer in Surgery.

After 3 weeks the lip defect was reopened and the lower end of the tube which has had previously been separated from the cervical region, was refashioned and stitched into the defect (Fig. 2). After 3 weeks the redundant portion of the tube was excised and the reconstruction of the lip completed. (Fig. 3)



Commentary

In this elderly patient by reconstructing almost the whole of the lower lip with a cervical tube, instead of the other popular methods already mentioned, it was possible to reduce the extent of the operation considerably. There was no difficulty in providing him a good oral orifice which could accommodate his dentures and looked acceptable, apart from the slight colour difference in the transferred flap. The greater length of time required to complete this form of repair over direct local flaps is offset against the simplicity and safety of this technique.

REFERENCES

- Abbe, R. : A new plastic operation for the relief of deformity due to double hairlip. *M. Rec.*, 53 : 477, 1898. Quoted from *Reconstructive Plastic Surgery* by Converse, vol. II, 1964.
- Von, B.V. : *Handbuch der praktischer Chirurgie*. H. Laup. Tuebingen, 1859. Quoted from *Reconstructive Plastic Surgery* by Converse, vol. II, 1964.
- Estlander, J. A. : Methode d'autoplastie de la joue ou d'une levre par un lambeau emprunte a l'autre levre. *Rev. mens. med. et chir.* 1 : 344, 1877. Quoted from see Ref. 1 (Converse 1964).
- Gillies, H.D. and Millard, D. R. Jr. : *Principles and Art of Plastic Surgery*. Little, Brown & Co., Boston, 1957.
- Harvey, A. : *Plastic and Reconstructive Surgery*, 53 : 310-12, 1974.
- Olivary, N. : One stage treatment of the whole lowerlip. *Brit. J. Plast. Surg.*, 16 : 66-68, 1973.
- Sabattini, P. : Genno storico dell' origine e progressi della rinoplastica e cheiloplastica seguito della descrizione di queste operazioni sopra un solo individuo. Bologna, Bell' Arti, 1838. Quoted from see Ref. 1 (Converse 1964)
- Stein, S.A.W. : Laebedannelse (Cheiloplastik) udført paa en ny methode. *Hospitalsmeddele ; ser* (Copenhagen), 1 : 212, 1848. Quoted from, see (Converse 1964).