

## Management of Fibrous Dysplasia of the Mandible By Excision And Bone Grafting

I.N. Tiwari,\* D. Venkatratnam,\*\* K.S. Mehdiratta,\*\*\* K.K. Srivastava,\*\*\*\*

Reports of isolated involvement of mandible by fibrous dysplasia are not uncommon (Khosla, 1971; William, 1973; Dahlgren, 1969 and Kessel 1968). The present management consists of curettage (William 1973, Dahlgren 1969) and occasional excision of the involved bone (Khosla 1971). We wish to report a case where it was necessary to ablate the lesion and the resultant mandibular defect was made good with a rib graft. This was necessary to restore normal function and contour to the mandible for this benign condition.

### Case Report

A young boy of 13 years reported to the dental clinic of JIPMER Hospital on 4-5-73 with the complaint of swelling of right lower jaw of 6-8 weeks (Fig. 1) duration. Before the swelling developed the patient felt a toothache which was diagnosed as caries by a local doctor in the village who applied some local paint with which the pain subsided. About two weeks prior to this incident the patient hurt himself in this area while playing. The parents thought that the swelling was rapidly increasing in size.

The patient was an average built active boy. The deformity of the face was quite evident on the right side of the mandible. The size of the swelling was 6.5 cm. across.

It was not warm. The consistency was bony hard. The submandibular lymph nodes were not palpable. No evidence of any discharge or sinus was present. Skin looked to be normal in colour. The swelling involved almost the entire body of the mandible



Fig. 1—Photograph of the patient showing swelling over the Right side of the lower jaw (Case No. 2)

right up to the angle. The chin appeared to be free from the swelling.

An expanded buccal plate of the mandible was seen on X-rays. The lingual plate also appeared to be expanded and 76547 appeared to be loose. The mucosa in that area looked normal in colour and texture.

\* Jawahar Lal Institute of Post graduate medical Education and Research, Pondicherry.

Teeth were not displaced.

Roentgenograph showed multilocular cystic radiolucent lesion with ill defined margins. The lesion involved the body of the mandible from the canine region to the angle of the mandible (Fig. 2).

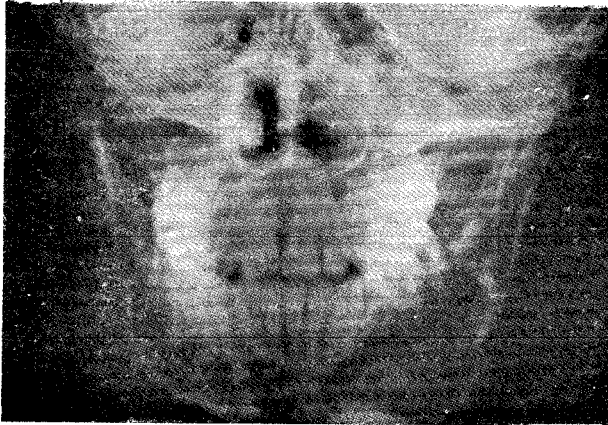


Fig. 2—Roentgenogram showing multilocular cystic areas over the right side of the Mandible (Case No. 2).

The patient was admitted on 5.5.73 for investigation and treatment. Physical examination was not contributory. All the routine investigations were within normal limits. A biopsy was done which indicated that the growth was a fibroma with myxomatous changes.

#### Treatment

Under endotracheal anaesthesia the tumour was excised extra-orally through a sub-mandibular incision. The tumour was dumbbell shaped, half lying in the lingual plate and the other half being lodged on the buccal side. It was well capsulated and was light yellowish in colour. The tumour was removed in two pieces (Fig. 3). Since there was hardly any bone support left, bone graft was felt essential. For a bone graft 6 cms. of rib was removed from the chest wall and fixed in to the defect by interosseous

wiring. The recovery of the patient was uneventful. The excised material was sent for histopathological examination. The final diagnosis was fibrous dysplasia after reviewing the previous slides.

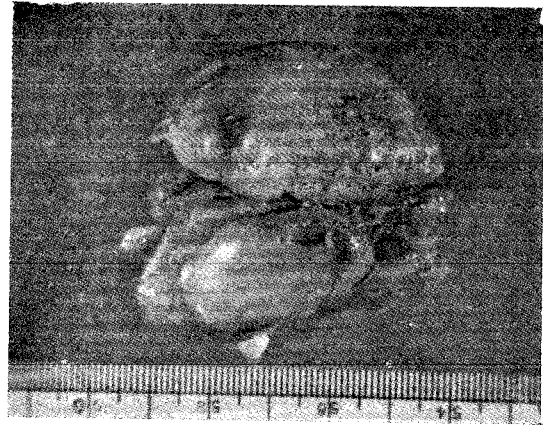


Fig. 3—Photograph showing gross specimen of the excised tumour mass.

#### Discussion

The lesions of fibrous dysplasia in the mandible, as elsewhere, are variable in size

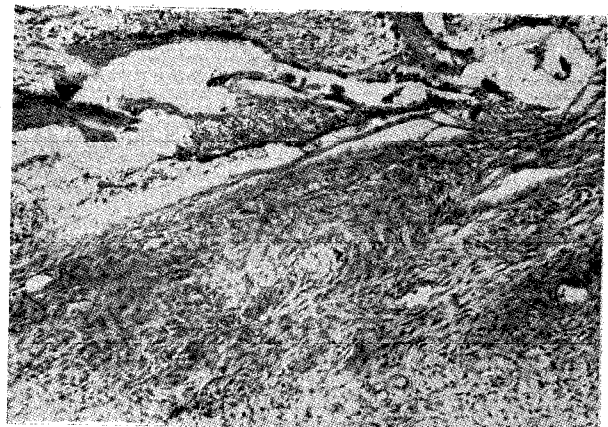

Fig. 4—Microphotograph of the cut specimen and present usually as fast growing swellings. Pain, though present, is seldom a major complaint. Deformity is always evident.

A complete excision of the lesion is not necessary because a shell of sufficient thick-

ness of bone is mostly available (William 1969-70 and William, J. 1973), which after curettage of the cavity, can be compressed in place and subsequent regeneration of

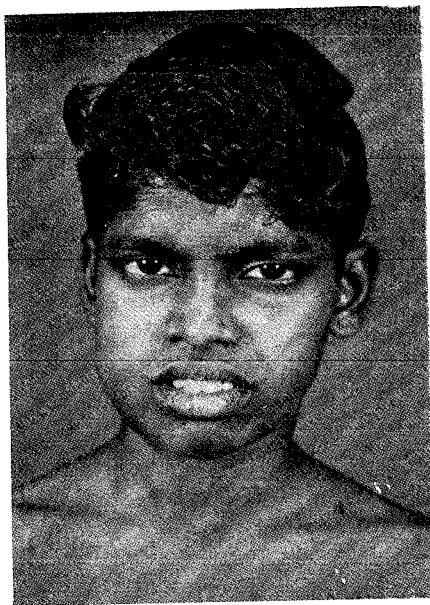


Fig. 5 - Photograph of the patient after surgery (Case No. 2)

bone gives adequate stability and strength to the jaw. The facial contour thus obtained is acceptable though the patient himself is always conscious of the irregular lump and thickness under the skin.

The reports of excision of this lesion are few (Khosla, 71) but none, where the gap has been bridged by a bone graft. Anterior 2/3 of the body of the mandible is virtually subcutaneous so that even small defects are likely to show to a perceptive eye. A sensitive patient is most unlikely to accept this aesthetic drawback. Our patient had involvement of this site.

#### Summary

The occurrence of fibrous dysplasia as a mono-ostotic lesion on the mandible is comparatively rare. Authors had occasion to treat a young patient by total excision of the growth and replacement of the defect of the mandible by a bone graft.

#### REFERENCES

1. Cangiano, R., & Stratigas, G.T., : Clinical and radiographic manifestations of fibro-osseous lesions of the jaws, *J. Oral. Surg.*, 873 : 29 Dec. 1971.
2. Dahlgren, S. E., Lind, P. O., Lindbom, A. & Martensson, G. : Fibrous dysplasia of jaw bones, *Acta. Oto-laryngoscope.* 68 : 257-270, 1969.
3. Khosla, V.M. and Korobkin, M. : Monostotic fibrous dysplasia of the jaw, *J. Oral. Surg.* 507 : 29 July 71.
4. Kessel, L.J. and William, M. : Fibro-osseous lesion of the mandible, *Brit. J. Oral. Surg.*, 84 : 6, 1968-69.
5. Browne, W.G. : Central Fibroma of the mandible, *Brit. J. Oral. Surg.*, 127 : 7 1969-1970.
6. Williams, J.L.I. and Faccini, J.M. : Fibrous dysplastic lesions of the jaws in Nigerians, *Brit. J. of Oral. Surg.*, 11 : 118-125, 1973.