

## Correction of Nasal Deformity in Leprosy with Nasolabial Flaps

*Dr N. H. Antia*

Hon. Plastic Surgeon

Tata Department of Plastic Surgery, J. J. Group of Hospitals, Bombay 8.

*Dr. V. I. Buch*

Asstt. Hon. Plastic Surgeon & Homi Bhabha Fellow,

Tata Department of Plastic Surgery, J. J. Group of Hospitals, Bombay 8.

The correction of the depressed nose in Leprosy by post nasal inlay procedure has been described by one of the Authors (Dr. N. H. Antia). This procedure still continues to be the method of choice in the majority of patients and can be relied to provide a

very satisfactory result. Unfortunately this entails prolonged wearing of a mould to prevent contracture of the skin graft and has to be followed by the wearing of an acrylic splint introduced through a permanent oro-nasal fistula or by the operation of a cantilever

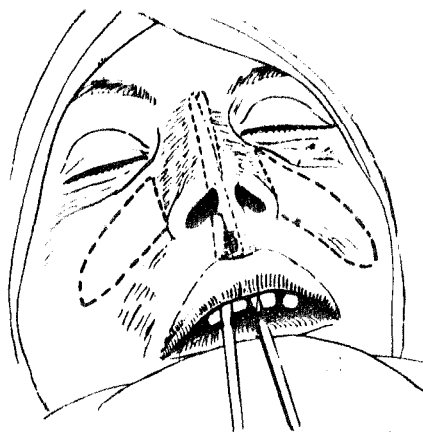


Fig. 1 A—Nose is freed from the bony margin.

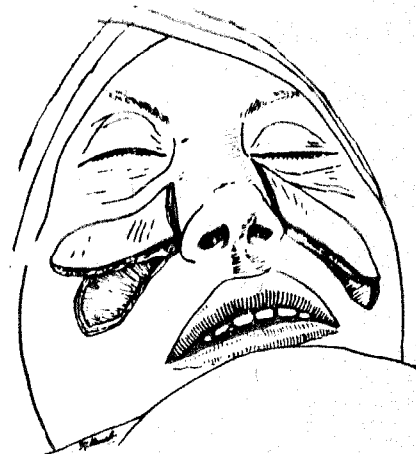

Fig. 1 B—Nasolabial flaps.

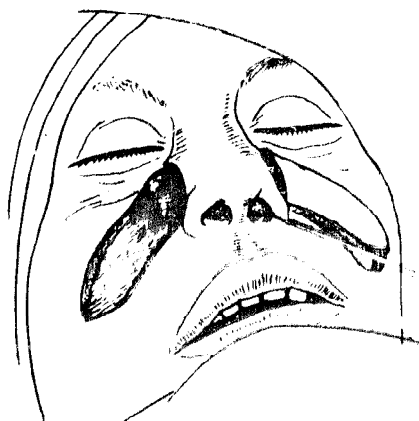

Fig. 1 C—Introduction of nasolabial flaps into the nasal cavity.

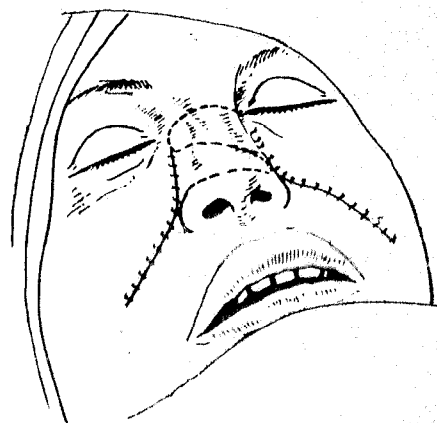


Fig. 1 D—Closure.

bone graft.

In order to overcome some of these problems, we have tried to use non contractile local flaps from the nasolabial folds. This report is based on such operations for the correction of the moderately depressed nose.

Farina, Wintsch and Morel Fatio (Personal Communication) have described the use of nasolabial flaps in correction of depressed nose. The operation as performed by us is the modification of the above methods and have provided satisfactory results.

### Operation

Under local infiltration anaesthesia the

tethered nose is released through an incision in the upper labial sulcus as described by us previously. The dissection is kept close to the bony margin of the pyriform aperture. Nasolabial flaps are raised on both sides as shown in the diagram based on a subcutaneous pedicle lateral to the pyriform bony margin (Fig. 1-B). Incisions are made on the sides of the nose through which the nasolabial flaps are summersaulted into the nasal cavity to provide the missing lining (Fig. 1-C). Excess of the flaps are excised to obtain accurate fit. The lateral incisions on the nose and the raw area in the nasolabial folds are closed by primary suture (Fig. 1-D). If necessary the lateral nasal

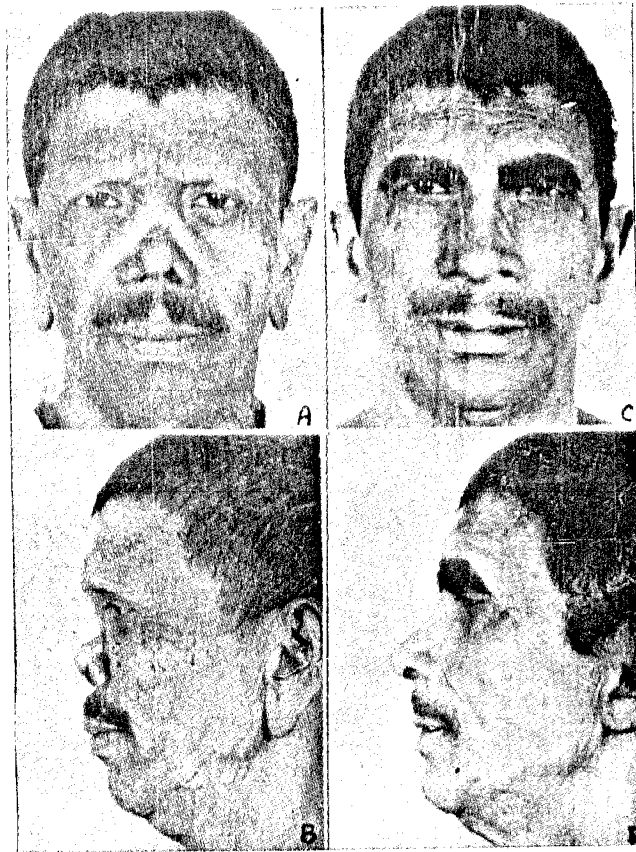


Fig. 2A & 2B—Pre-operative.

Fig. 2C & 2D—Post-operative.

incisions can be united by a  $\Omega$  shaped incision over the root of the nose thus giving better access to the nasal cavity. The transverse incision in the upper labial sulcus is sutured longitudinally in two layers to give the necessary additional length to the colu-

mella and correct the nasolabial angle.

Support may or may not be deemed necessary for the stiff nasolabial flaps help to raise dorsal line. L shaped silicone implant was inserted in two cases six months after the provision of lining.

#### REFERENCES

1. Antia, N. H. : Ann. Royal Coll. Surg. England, 32:71, 1963.
2. Converse, J. M. : Reconstructive Plastic Surgery, 2:790, 1964.
3. Farina, R. : Ann. Chir. Plast. (Paris), 9:119, 1964.
4. Farina, R. : Ann. Chir. Plast. (Paris), 5:279, 1960.
5. Kazanjian, V. H. : Transac. Amer. Academy Ophthal. Otolaryn., 43:1937.
6. Kubacek, V. : Act. Chir. Plastica, 2:108, 1960.
7. Wintsch, K. : Plast. Reconstr. Surg., 42:208, 1968.