

"Z" Plasty Repair for Torn Ear Lobule

S. C. Lodha, (Jodhpur)

Introduction

Indian ladies often come to the Surgeon for repair of their torn ear lobules. The common aetiological factor is that they put on heavy ear rings, the fine wire of the ring with the heavy decorated pendent cuts through the ear lobule which is devoid of a firm supporting structure. The procedure commonly undertaken has a great recurrence rate and multiple operations often reduce the size of the lobule. Application of "Z" Plasty for its repair solves all these problems.

Method

The operation is performed under local anaesthesia, an ellipse of the skin is made in partially torn lobule or edges are freshened in cases where the lobule is completely torn. "Z" is marked out along the defect with the skin dye, the flaps are raised and then transposed reversing the diagonals of the "Z", a moderate amount of pressure is applied to secured haemostasis. The notching specially in completely torn lobules is suitably corrected.

Observations

This operation has been performed on 75 cases, 55 were operated for the first time and remaining 20 had undergone more than one operations in the past. The recurrence in these 20 cases was within two years of the operation.

Table 1

Showing the Results of "Z" Plasty

Total No. of cases.	Operated for the first time by "Z" Plasty.	Had undergone multiple operations in the past, before "Z" Plasty
75	55	20

35 patients, who are under observation for the last 2½ years, when interviewed, were satisfied with the operation and they were putting the same earring after this operation. The size of the hole was upto 2mm. in 28 cases and upto 5mm in the rest. The weight of the ornament varied between 1.5 gms to 4.0 gms.

Table 2

Review of the Patients

Total No. of cases.	Size of hole up to 2 mm.	Size of hole between 2 to 5 mm.	Recurrence of torn.	Weight of Earring.
35	28	7	Nil	1.5 to 4 gms.

Discussion

The custom of putting on of heavy earrings by the Indian ladies, so much so that the ladies have to support them to the hair pins, is the cause of torn ear lobule. The recurrence rate is high in commonly performed operations as the repair done is in the weight bearing line. Thus the weaker scar gives way again to the ornament. (Fig. 1 & 2)

"Z" Plasty undertaken in this series on the other hand has two distinct advantages,

firstly it alters the direction of the scar line, interposes a good amount of healthy tissue and thereby prevents the recurrence. Secondly in cases where the lobule is shrunken because of previous operations, this procedure increases the size of the ear lobule thereby giving a symmetrical appearance (Fig. 3) and hence should be accepted for its repair.

Summary & Conclusion

Due to the heavy earrings, the ear lobule is often torn in Indian women. The recurrence rate is high in commonly performed operations. "Z" Plasty operation in its treatment is devoid of recurrence and adds length to the shrunken ear lobules. This is the only operation which solves all the problems faced by a Surgeon.

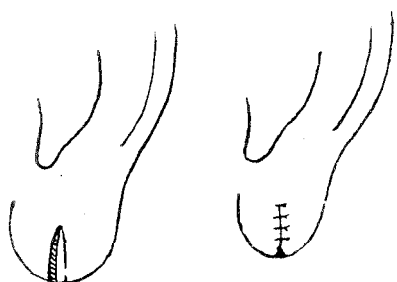


FIG. 1

Fig. 1 Simple freshening the edges and suturing—In completely torn cases the size of the lobule is reduced. Recurrence is high as the scar is in the weight bearing line.

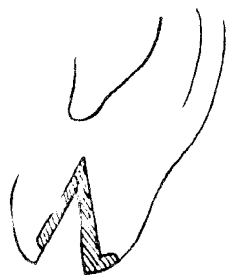


FIG 2

Fig. 2 Repair after Nelaton and Ombredanne prevents notching but takes away a good amount of tissue. The recurrence is again high.

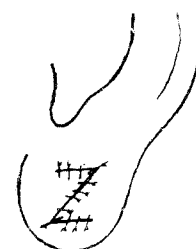



FIG 3

Fig. 3 'Z' Plasty alters the direction of the scar, restores the size of the lobule and interposes healthy tissue, and thereby prevents recurrence.