

Pharyngeal Flap Operation

P. B. Sulakhe

Honorary Plastic Surgeon Dept. of Plastic Surgery, Sassoon General Hospitals, Poona.

CLEFT palate patients are operated to get normal speech. If cleft palate is repaired before the child begins to speak, in the vast majority of children the speech will be normal. Wardill-Kilner operation, either with two flaps or four flaps has produced excellent results and is now accepted as standard method. In spite of good operation done at correct age i. e. between 1st and 2nd year, some will have nasal speech. This is due to imperfect velo-pharyngeal closure. To solve this problem pharyngeal flap operation is done.

Passavant in 1862 was the first to attribute nasality in speech of operated palate patients to velo-pharyngeal incompetence. Rutenberg (1876), later Wardill (1927) attempted to reduce the antero-posterior diameter of the pharynx by incising posterior pharyngeal wall horizontally and suturing it vertically. In 1872 Schoenborn and Trendelenburg raised a flap from posterior pharyngeal wall and sutured it to soft palate. The credit of this operation should go to them. In reality this operation is known as Rosenthal operation because he made this operation popular. In 1924 Rosenthal used inferiorly based flap. In 1934 Sanvenero-Roselli described superiorly based flap. In 1950 Hynes introduced muscle transposition of flaps on posterior pharyngeal wall which

produced a bulge and narrowed the size of the pharynx.

The nasality in speech after the palate repair may be due to—

- (a) Congenitally short palate or due to scarring following surgery
- (b) Weakness of musculature due to paralysis of levator palatini or tensor vela palatini
- (c) Due to pharyngomegaly
- (d) Due to faulty speech habits.

Quite often nasality may disappear but defective articulation persists. It is well demonstrated in some of my patients. If the patient is intelligent and keen, he shows remarkable improvement after surgical operations. Help of a speech therapist is a great asset to improve defective speech. Unfortunately many hospitals in our country lack this facility.

To achieve good velo-pharyngeal closure the following procedures are done :

- (a) Lengthening of palate—in this group we have V—Y retroposition operation, Wardill-Kilner operation, and Gillies-Fry operation.
- (b) Pharyngo plasty—Hynes muscle transposition flaps.
- (c) Pharyngeal flap operation of Rosenthal or Sanvenero-Roselli operation.

- (d) Retropharyngeal implants—various materials have been used like paraffin, fat fascia graft. Cartilage autogenous and homogenous and silicon compounds.

This paper deals with pharyngeal flap operation. I have not done Hynes pharyngoplasty or retropharyngeal implants on any patient. I have operated on 10 patients with flap procedure. Two patients had palatoplasty and pharyngeal flap procedure at the same time. Out of these two cases one was done by Dr. Richard Stark of New York who visited our hospital in 1965 and demonstrated his technique. He is a great advocate of primary flap operation. The main object is to fix soft palate to posterior pharyngeal wall. In the remaining 8 cases palatoplasty was first done by Wardill-Kilner method and later when it was discovered that the nasality had persisted, the patients were operated for pharyngeal flap operation. In India, we see unoperated cleft palates at all age groups. If the defect is wide it will be justifiable to combine palatoplasty and pharyngeal flap operation in one sitting particularly in adults.

After the repair of the palate the following methods are used to establish velo-pharyngeal incompetence.

(1) As a working rule, if on elevating the soft palate it comes within 0.5 cm of posterior pharyngeal wall-velopharyngeal closure will be good.

(2) Cold mirror test—with a cold mirror held in front of nose, patient is asked to say ee or oo if there is nasal escape

there will be clouding of the mirror.

(3) X-Ray examination in lateral position to study soft palate at rest and at elevated position with the help of barium.

(4) Tomographic studies.

(5) Spirometric studies of escape of air through nose. I have not used these methods in my cases. Nasality in speech was clear in all my cases.

Types of flaps :

There are four anatomical varieties-

- (a) Superiorly based—Senvenero—Rosselli
- (b) Inferiorly based—Rosenthal
- (c) One superiorly and one inferiorly (Double flap of Millard)
- (d) Superiorly based bilateral pharyngeal flaps from the lateral pharyngeal wall (Rethi-Moore).

Contra-indications for operations :

If adenoids are enlarged—it is better to do adenoidectomy first and three months later to do the flap operation. Middle ear infection should first be controlled.

Technique of Operation

Patient should be supine with hyper-extended neck. Under oral endotracheal gas, oxygen and ether anaesthesia operation is performed. Oxford right angled stiff tubes are best. The tube should lie in the centre, in the slot of the tongue blade of Davis Kiiner gag. Metal connection to the tube should rest on alveolar edge. Operative steps for superiorly based or inferiorly based are very much the same. Here superiorly based flap operation will be described. Distance between posterior pharyngeal wall

and free edge of soft palate should be measured carefully. After division flap shrinks in all directions, so sufficient margin should be kept for shrinkage and then flap should be marked, with Bonney's blue. Posterior pharyngeal wall should be infil-

Two holding sutures of linen, are passed at two corners of the flap and distal incision is taken either horizontally or with a V. and flap is lifted from its bed. Hemostasis is readily obtained by pack and pressure. An incision is taken over free edge of soft palate,

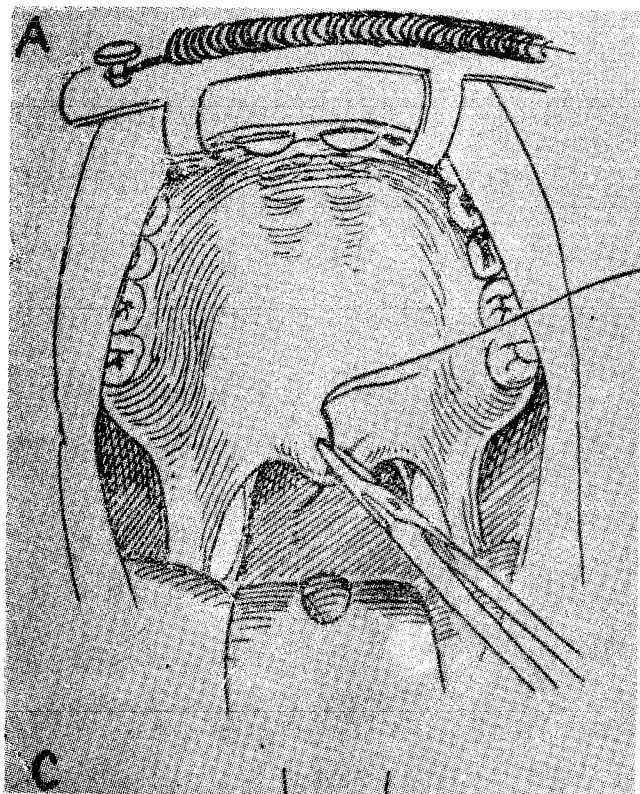


Fig. 1 Stitch being passed through soft palate for retraction.

trated with adrenaline saline (5 drops of adrenaline (1 in 1000) to 10 cc of normal saline). Longitudinal incisions are first taken on either side by retracting the soft palate (Figs. 1, 2). The incision in the flap should go down to the bone. With right angled scissors the flaps are undermined medially, laterally and inferiorly. (Fig. 3) The flap has mucous, submucous and muscle layer in it. It is a dynamic flap.

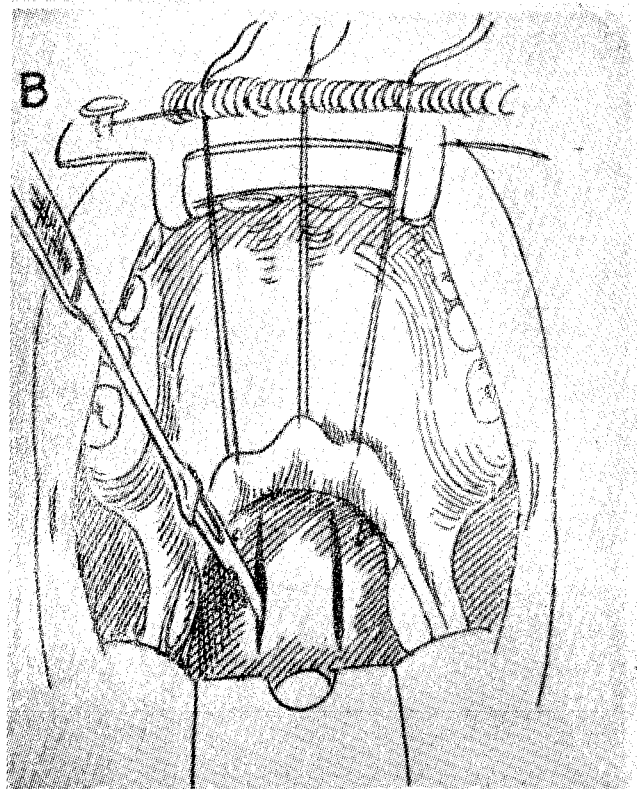


Fig. 2 Lateral incisions taken on posterior pharyngeal wall.

extending over posterior pillar of tonsil (Fig. 4) Uvula should be left attached to the oral layer of the flap. Some patients look into their throats and if uvula is not seen they keep on bothering. This procedure has one disadvantage—Anaesthesiologist may overlook this point and try to pass a nasal tube for anaesthesia. The free edge of the upturned flap is sutured with nasal layer of palatal flap with N₁ nylon end on mattress

sutures with knots on nasal side. I used 4/0 chromic catgut in some of my early cases and

found that because of premature absorption of catgut flap failed to unite. This being a

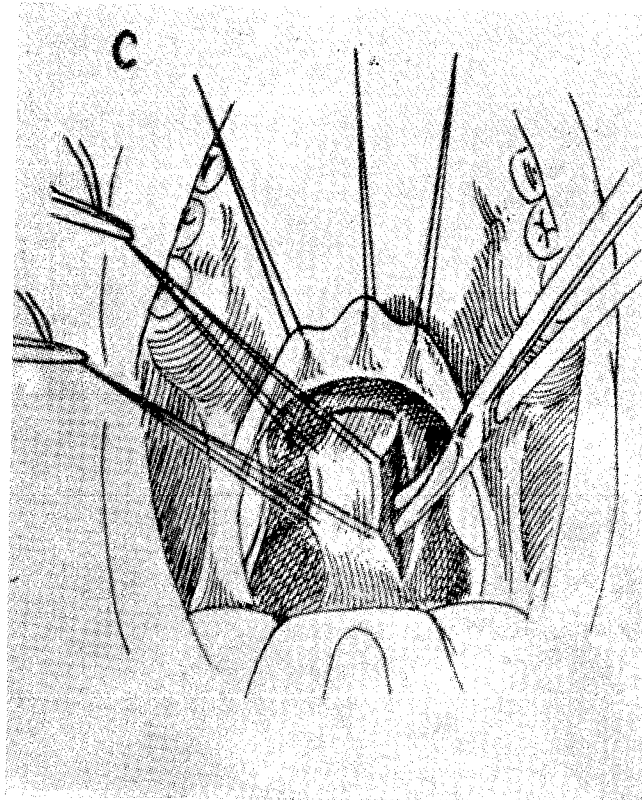


Fig 3 With right angled scissors flap is undermined medially, laterally and inferiorly.

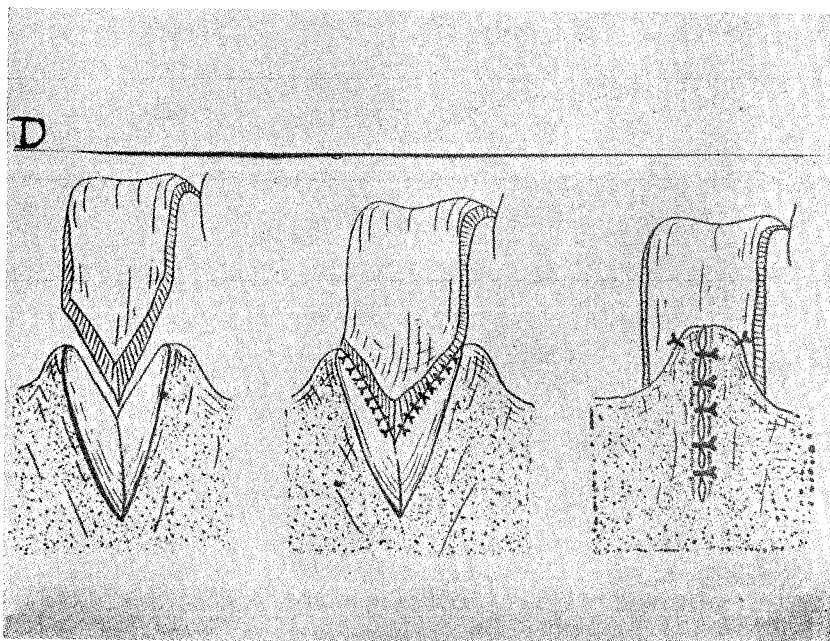


Fig. 4 Incision in the soft palate to receive free edge of the flap. Flap sutured to nasal layer. Uvula sutured in front of the flap

mobile part non-absorbable suture is best. About 5 sutures are sufficient for uniting free edge of flap to posterior layer of palatal flap. The oral layer of the palatal flap is pulled posteriorly and sutured to the raw surface of the flap. The raw area on the posterior pharyngeal wall is closed with chromic catgut with Reverdin needle (Fig. 5).

Post operative care—Endotracheal tube should be kept until patient is well out of anaesthesia. As patient is not able to breath through nose, air way should be kept over the tongue for breathing. While sucking great care should be taken not to traumatise

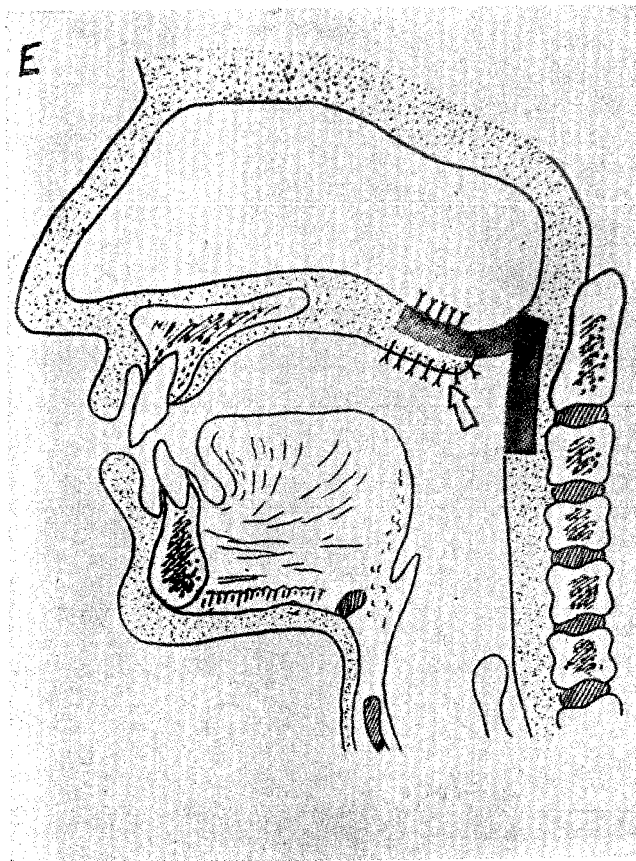


Fig. 5 Lateral view to show superiorly based flap in position.

the flap. Patient should have liquid diet for 10 days. Hard food should be avoided for two weeks.

Discussion

I started flap operation with inferiorly based flaps. I had some successes and some failures. Technically it is easier operation, but sometimes you cannot have sufficient length of the flap. It is also more liable to trauma. It has advantage as it will divert sound through oral cavity. Those cases where I failed I have done them again with superiorly based flap. Technically, though it is more difficult one could easily master it. One can get long enough flap to close the gap. It has an easy lie. It is easier to control hemorrhage. Palatal elevation during speech is not interfered with.

Results

My series is very small but some have shown excellent results. Some have such defective speech that you cannot understand them though their nasality has reduced or disappeared. In India there is great scope for this operation because we see so many badly operated palates or adults with wide defects in palates.

REFERENCES

- Iwao, N. The Journal of Osaka University Dental Society., 2:1-15, 1956.
- Peet, E. W. & Patterson T. J. S. Essentials of Plastic Surgery, 324-372, 1963.
- Rees Thomas D. : Plastic Reconst. Surgery. 1521-1531, 1964.
- Stark R. B. and DeHaan C. R. : Plastic and Reconstructive Surgery, 26:378, 1960.