

## Some Personal Observations in Cleft Palate Surgery

*R. J. Maneksha, F.R.C.S., Bombay.*

THERE are many unsolved problems in the reconstructive surgery of cleft palate and no two surgeons treat this defect in the same way. Any competent surgeon with sufficient training will produce over 80 per cent of closed palates still a closed palate is not the criteria of a successful palatal operation. A long term follow up should produce a normal maxillary arch development as well as a mobile and retroposed soft palate. Are we justified in closing the hard and soft palate at the early age of two years or is it enough to close the soft palate at this period? Results in West German University centres have shown me that there is a lot of sense in the closure of the posterior two-third of the hard palate around the age of 4 to 6 years instead of earlier surgery before two years when the soft palate is only repaired. Comparing the results of total closure of the hard and soft palate at the early age of 2 with those where the hard palate is closed at 4 or 5 years has shown that collapse of the maxillary arch could be prevented in the later cases. The speech is within normal limits even when the hard palate is unrepaired till 4 to 5 years of age.

At the time of the repair of the cleft lip attempt must be made to close the anterior third of the palate also—this is easily done using an inferiorly based mucosal flap from the nasal septum and

a superiorly based mucosal flap from the lateral wall of the nasal cavity which also includes the mucosa over the inferior turbinate—dissection of this flap requires delicacy and patience, and dissectors of various curvatures. Suturing of the flaps at different levels creates an airtight pocket wherein a bone graft is put in. Orthodontia at a later stage has succeeded in migrating a tooth into the bone grafted segment.

Mucosa from the septal cartilage has often been used by us to line the nasal layer of the region of the repaired soft palate (Figs. 1 to 3). In cases of post alveo-

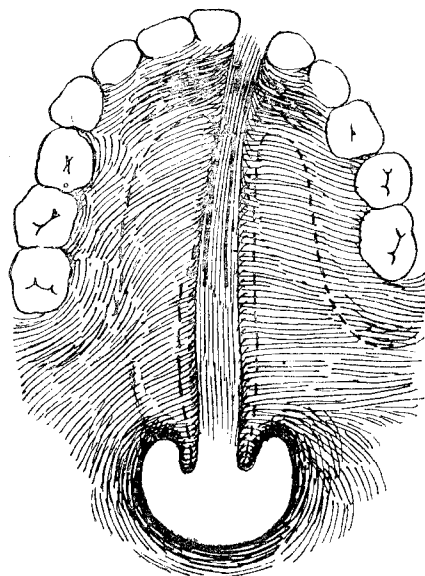


Fig. 1 Pre and post alveolar cleft. Septum attached to the non cleft side which supplies a hinged flap for the nasal layer of the soft palate. In alveolar cleft the septal mucosa is divided and

used for closure of the nasal layers as shown in Figs. 4 to 6.

The dissection of the nasal layer has to be very thorough especially at the posterior

margin of the hard palate. We have not done a Z plasty of the nasal layer so far. When the closure of the nasal layer is difficult we have used a superiorly based phary-

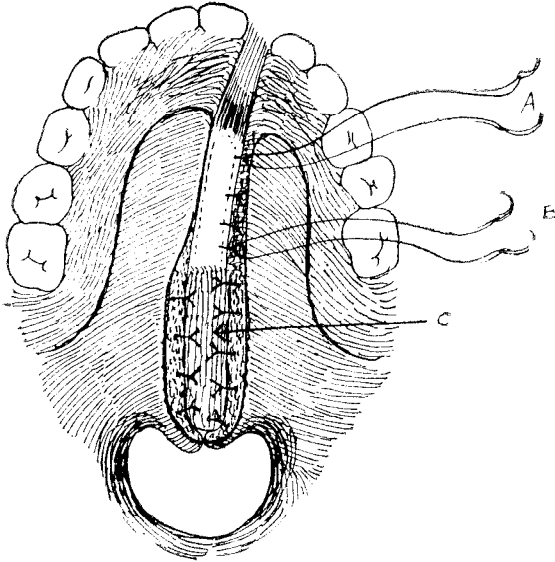


Fig. 2 The hinged flap C was turned backwards to form the nasal lining of the soft palate. Nasal layer in the region of hard palate closed and two cardinal stitches kept long to anchor to the oral flaps. This avoids any dead space.

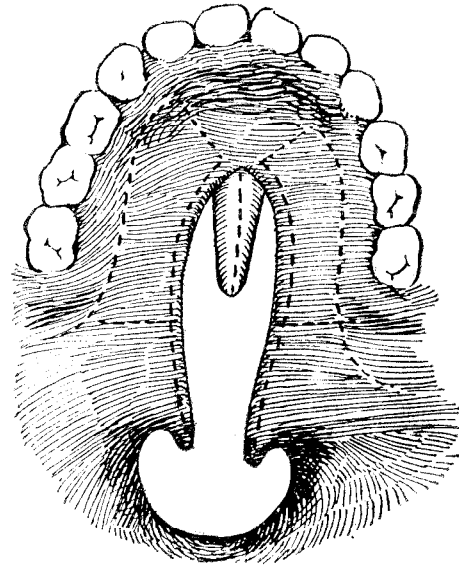


Fig. 4 Secondary or post alveolar cleft. There is agenesis of the septum in this case.

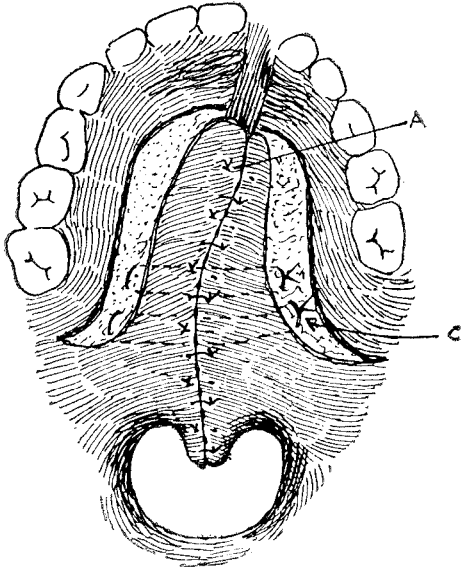


Fig. 3 Palate closed. Anterior cardinal suture at A and Veau muscle stitches at C. Palatal layer closed with vertical mattress sutures.

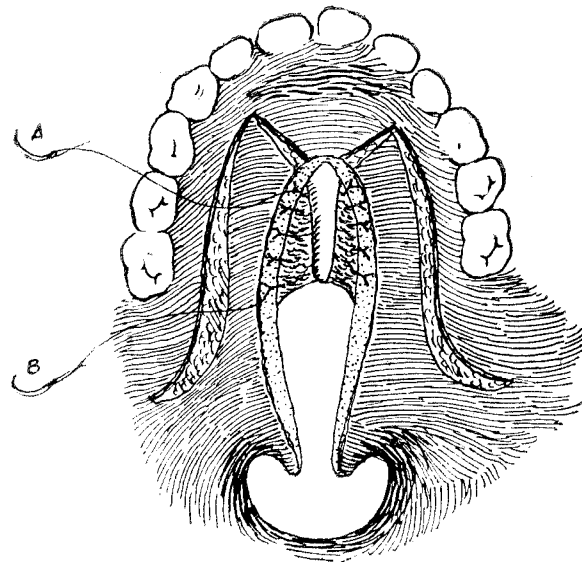


Fig. 5 Septal mucosa used for closing the nasal lining and two cardinal stitches kept long.

ngeal flap even in the primary repair. The post operative period is definitely more comfortable when there is an absence of tension on the suture line. Linen is used for closure in all the layers. We do not prefer catgut or nylon. The stitches are removed from the oral layer in 12-14 days—this is done without general anaesthesia.

The lateral incision on the hard palate (Fig. 1.) extends well beyond the last molar. Careful dissection of the flap avoids injury to the main posterior palatine vessel as it comes out from the palatine foramen. We have not tried to liberate this vessel by nibbling the bony canal. The hamulus is fractured as a routine although it is diffi-

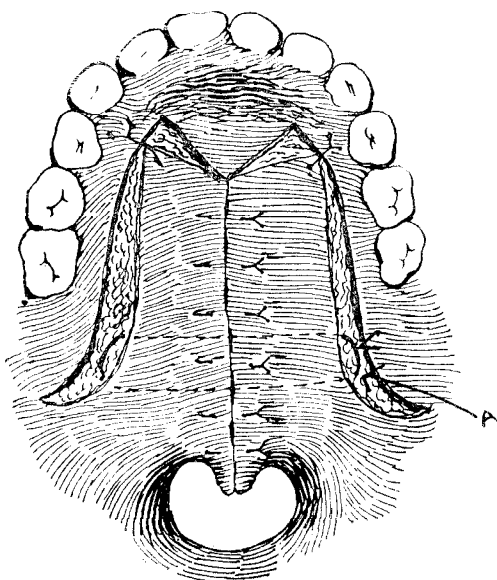


Fig. 6 Palate closed.

cult to say whether this is an advisable procedure as it changes the axis of action of the tensor palati muscle. The gap in the posterior part of this incision is closed by a rotation or transposition flap of cheek mucosa. This avoids any raw area as well as

scarring in a vital area of the palate.

“Island” flaps of Millard are useful in secondary clefts with a foreshortening of the soft palate. We have done only six of these but with satisfactory improvement in speech. The flaps are not tunnelled through the medial segment which is dissected off so as to lay the oral and nasal flaps (A and B in Fig. 8) one on top of the other (Fig. 10). The two flaps are also stitched to each other in the middle to avoid any dead space. Flap B has to be rotated 180 degrees on its long axis so that its mucosal surface faces the nasal side.

Sufficient time has passed to assess the value of either the superior or inferiorly bas-

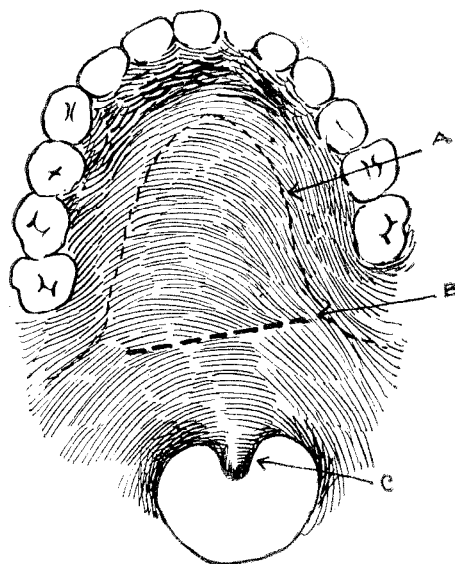


Fig. 7 The palate is already operated but is very short. There is nasal escape and speech is poor.

ed pharyngeal flap operations. Functionally not a very sound procedure as it tethered down the soft palate—although it reduced the nasal escape to a large extent. The flap often tends to contract into a fibrous band even in the best of hands. The Hynes ope-

ration is successful with a limited number of plastic surgeons as the majority feel that the cushioning effect is not marked. We have tried a V—Y type of operation on the pharyngeal wall to create a rolled cushion but it is too early to report on the results. A silastic implant in the midline would be useful if the material is not extruded.

The speech therapist and the orthodontist play an important part in the cleft palate team. The speech therapist is very often able to guide us when further surgery is necessary.

The orthodontist plays a parallel part with the cleft palate surgeon in the preoperative as well as the post operative period and very often assists during the operation if he is surgically minded.

Finally it is difficult to dogmatise on such a complicated subject as the repair of a cleft palate. Each surgeon may have his own method which in his hands may produce the best results. It is always better if the results are assessed by another surgeon with the help of a speech therapist and an orthodontist.

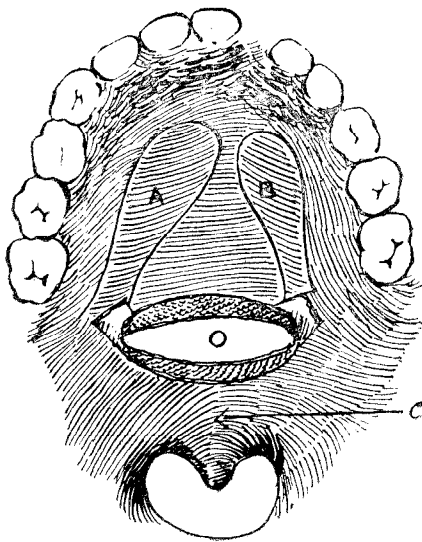


Fig. 8 The modified "island" flap operation. Gap O is created by detaching the soft from the hard palate. Sufficient push back is obtained. "Island" flaps A and B are dissected out and transposed to area O. They are not tunnelled through the intervening tissue which is excised instead.

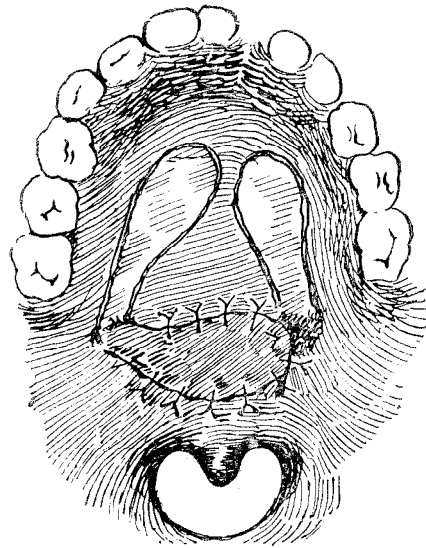


Fig. 9 "Island" flaps stitched to fill up the gap. Good push back.

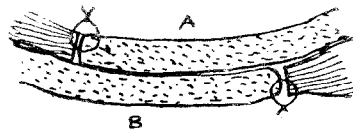


Fig. 10 Flaps in situ.