



It Is Necessary to Pay Attention to Where the Pcom Originate from the Aneurysm to Treat with FD

Takashi Fujii^{1,2} Kohsuke Teranishi³ Yumiko Mitome-Mishima^{2,3} Takayuki Kitamura³ Kojiro Wada²
Akihide Kondo³ Hidenori Oishi^{1,3}

¹Department of Neuroendovascular Therapy, Juntendo University, Graduate School of Medicine, Tokyo, Japan

²Department of Neurosurgery, National Defense Medical College, Saitama, Japan

³Department of Neurosurgery, Juntendo University, Graduate School of Medicine, Tokyo, Japan

Address for correspondence Takashi Fujii, MD, Department of Neuroendovascular Therapy, Juntendo University, Graduate School of Medicine, 2-1-1 Hongo, Bunkyo-ku, Tokyo 113-8421, Japan (e-mail: ta-fujii@juntendo.ac.jp).

Asian J Neurosurg 2024;19:168–173.

Abstract

Objective With the expansion of indications of flow diverter (FD) for cerebral aneurysms, FD placement for posterior communicating artery (Pcom) aneurysms has been approved. However, it is controversial whether Pcom aneurysms should be treated with FD or not. In this study, we report the outcome of FD treatment for Pcom aneurysms in Japan.

Materials and Methods We retrospectively analyzed 36 patients with 38 aneurysms treated with FD placement for Pcom aneurysms between 2015 and 2021 in our hospital. We divided our cases into complete occlusion (CO) and non-CO groups. And we extracted contributing factors to CO using multivariate analysis. We also compared the complications rate among the three types of FDs.

Results CO was obtained in 29 cases (79.3%), and complications were observed in 3 cases (7.9%). Multivariate analysis revealed that the type of Pcom branch from the aneurysmal dome was a significant factor contributing to CO (odds ratio: 0.0052, 95% confidence interval 0.000048–0.584, $p = 0.029$). In terms of complications, complication rate was significantly higher in the Flow-Redirection Endoluminal Device (FRED) group ($p = 0.0491$).

Conclusion The outcome for Pcom aneurysms treated by FD was acceptable. When treating, we must pay attention to where Pcom originates. Achieving CO with FD is difficult for aneurysms where the Pcom branches from the dome. Furthermore, when treating Pcom aneurysms with FRED, it is necessary to be careful about thromboembolic complications.

Keywords

- ▶ aneurysm
- ▶ flow diverter
- ▶ Pcom
- ▶ endovascular
- ▶ complete occlusion

Introduction

Ruptured cerebral aneurysm causes subarachnoid hemorrhage, and although the prognosis has improved with recent developments of treatments, the mortality rate is still high.¹

Large-scale studies have shown that the posterior communicating artery (Pcom) bifurcation is a common site of cerebral aneurysm and it has high rupture rate.^{2,3} Therefore, Pcom aneurysms should be treated even if they are found in

article published online
May 27, 2024

DOI <https://doi.org/10.1055/s-0043-1778085>.
ISSN 2248-9614.

© 2024. Asian Congress of Neurological Surgeons. All rights reserved.

This is an open access article published by Thieme under the terms of the Creative Commons Attribution-NonDerivative-NonCommercial-License, permitting copying and reproduction so long as the original work is given appropriate credit. Contents may not be used for commercial purposes, or adapted, remixed, transformed or built upon. (<https://creativecommons.org/licenses/by-nc-nd/4.0/>)

Thieme Medical and Scientific Publishers Pvt. Ltd., A-12, 2nd Floor, Sector 2, Noida-201301 UP, India

unruptured. In recent years, the flow diverter (FD) has been developed as a novel device for aneurysm, and its efficacy has been established.⁴⁻⁷ In the early days of FD treatment, its indication was the proximal vessel of the Pcom bifurcation in the internal carotid artery to avoid the risk of perforator occlusion. In recent years, it has been revealed that fewer ischemic complications in the perforating branch after FD placement^{8,9} and its indication have been expanded to distal vessels including Pcom. On the other hand, the orifice or size of Pcom is more important to treat Pcom aneurysm with FD than the size or shape of aneurysm itself. There are many reports that fetal Pcom aneurysm, which is defined thicker Pcom than P1,^{10,11} is difficult to achieve complete occlusion (CO) with FD.¹²⁻¹⁴ However, there are various outcome of reports for Pcom aneurysm with FD and there is no consensus whether to treat Pcom aneurysm with FD or not. In this study, we retrospectively summarized outcome of Pcom aneurysm treated with FD in single center. We focused on anatomical characteristics such as the shape or origin of the Pcom and extracted the factors that contribute to CO.

Materials and Methods

Patient Selection

A total of 38 aneurysms in 36 patients who underwent placement with three types of FDs, Pipeline (Covidien/Medtronic, Irvine, California, United States) Flex or Pipeline Shield, and Flow-Redirection Endoluminal Device (FRED; Microvention, Tustin, California, United States), and Surpass (Stryker Neurovascular, Fremont, California) for Pcom aneurysms at our hospital between 2015 and 2020 were included in this analysis. Age, sex, history, and presence or absence of complications were reviewed from the electronic medical records. Complication was defined as National Institutes of Health Stroke Scale score deterioration more than 3 points. This was a retrospective study conducted in a single center.

Antiplatelet Therapy

All patients were administered dual antiplatelet therapy with a daily dose of aspirin 100 mg and clopidogrel 50 to 75 mg, depending on body weight, at least 14 days before the day of surgery. Platelet aggregation was assessed within 1 day before the surgery. The platelet aggregation test was considered effective if there was a decrease in platelet aggregation compared with the control before antiplatelet medication. For patients whose platelet aggregation was judged to be ineffective, prasugrel 20 mg was loaded on the day of surgery. Subsequently, 3.75mg doses of prasugrel were administered as an alternative drug for clopidogrel. If the 1-year follow-up radiological examinations showed CO without significant in-stent stenosis, clopidogrel was discontinued, and aspirin was maintained for as long as 1.5 to 2 years. Patients with non-CO and/or significant in-stent stenosis should continue with aspirin until angiographic confirmation is made of CO and/or there is no further deterioration of in-stent stenosis.

Endovascular Procedure

All operations were performed under general anesthesia. General heparinization was performed to achieve that the activated clotting time was more than 300 seconds. Basically, pipeline was used most of the case because it had the most experience using it, but other FDs were also used in cases what it was judged to be relatively easy to deploy FD. One operator (HO) made the decision as to which of the three types of FDs to use. We also investigated whether there were differences in outcomes depending on the types of FDs. The method of FD deployment was performed in the same manner as in previous reports.⁶ And we performed adjunctive coiling for the cases that were likely to occur delayed aneurysmal rupture such as symptomatic case, and that with inertia-driven flow or high aspect ratio.¹⁵

Radiographical Assessment

Angiography was performed every 6 months to 1 year after the operation. Aneurysm morphologies including dome-size and neck-width were evaluated with the images made with a biplane angiographic system (Siemens Artis Q BA Twin System, Siemens, Munich, Germany) with three-dimensional rotational angiography. Embolic status was evaluated using O'Kelly-Marotta (OKM) scale. The assessment for embolic status was performed independently by two of the authors. Discrepancies were resolved by another neurosurgeon. The embolic status was classified as OKM scale D for CO and OKM scale A, B, and C for incomplete occlusion.

In addition to embolic status, Pcom was also evaluated and classified as fetal type or nonfetal type according to the Pcom diameter. Fetal-type Pcom was defined as Pcom larger than ipsilateral P1.^{10,11} Furthermore, the origin of Pcom was classified into three types, which are 1. No branch, 2. Neck branch, and 3. Dome branch groups. "No branch type" was defined as an aneurysm without Pcom, "Neck branch type" as an aneurysm with Pcom originating from the neck, and "Dome branch type" as an aneurysm with Pcom originating from dome, respectively. The presence and absence of P1 were also evaluated.

We divided patients into two groups: those who achieved CO after FD placement for Pcom aneurysms and those who did not. Then, factors contributing to CO were extracted using univariate and multivariate analysis. The period from the date of surgery until angiography was performed was defined as the follow-up period.

Statistical Analysis

Binary variables showed presented as number and percentage. Continuous variables showed presented as mean \pm standard deviation (SD). Differences between the two groups for the binary variables were performed using the Fisher's exact test. The Mann-Whitney U test was used for differences between the two groups for continuous variables. Multivariate logistics analysis was performed to identify contributing factor to CO, using all candidate variables in which *p*-values are less than 0.05 in univariate analyses. *p*-Values less than 0.05 were considered statistically significant. The data were obtained using statistical software, GraphPad Prism 9

(San Diego, California, United States) or EZR version 1.55 (Saitama Medical Center, Jichi Medical University, Omiya, Saitama, Japan).

Results

Patients Characteristics

The patient characteristics are shown in ►Table 1. The mean \pm SD age of the patients who underwent FD placement was 67.3 ± 10.3 years, and the male to female ratio was 6: 32. The mean aneurysmal dome size was 10.9 ± 5.6 mm and the mean neck size was 5.8 ± 2.1 mm. Fourteen patients (36.8%) had hypertension and eight patients (21.1%) had dyslipidemia. Platelet aggregation tests showed that collagen (COLL) and adenosine diphosphate (ADP) were 46.5 ± 14.0 and 46.3 ± 10.6 , respectively. Fetal-type Pcom was with 15 aneurysms (39.5%). Pcom branch type was 7 (18.4%) in no branch type, 24 (63.2%) in neck branch type, and 7 (18.4%) in dome branch type, respectively. Six aneurysms (15.8%) had no P1. Twelve cases (31.6%) had history of treatment. The mean (\pm SD) follow-up period was 24.7 ± 16.8 months.

Radiological and Clinical Outcomes

The radiological and clinical outcome results are shown in ►Table 2. CO was obtained in 29 cases (79.3%). There were 32 cases (84.2%) that required the use of adjunctive coiling. Regarding FD types, 22 cases (57.9%) were Pipeline Shield, 8 cases (21.1%) were Pipeline Flex, 6 cases (15.8%)

Table 1 Patient characteristics treated with FD placement for Pcom aneurysm between CO and non-CO groups

Parameters	Whole (n = 38)
Age (years, mean \pm SD)	67.3 \pm 10.3
Female (n, %)	32 (84.2)
Aneurysm dome size (mm, mean \pm SD)	10.9 \pm 5.6
Aneurysm neck size (mm, mean \pm SD)	5.8 \pm 2.1
History	
Hypertension (n, %)	14 (36.8)
Dyslipidemia (n, %)	8 (21.1)
Platelet aggregation test (mean \pm SD)	
COLL	46.5 \pm 14.0
ADP	46.3 \pm 10.6
Fetal-type Pcom (n, %)	15 (39.5)
Pcom branch	
Nonbranch (n, %)	7 (18.4)
Neck branch (n, %)	24 (63.2)
Dome branch (n, %)	7 (18.4)
P1 absence (n, %)	6 (15.8)
History of treatment (n, %)	12 (31.6)
Follow up duration (months)	9.4 \pm 5.4

Abbreviations: ARU, aspirin reactivity unit; CO, complete occlusion; FD, flow diverter; Pcom, posterior communicating artery; PRU, P2Y12 reactivity unit; SD, standard deviation.

Table 2 Patients outcomes treated with FD placement for Pcom aneurysm between CO and non-CO groups

Parameters	Whole (n = 38)
OKM scale (n, %)	
A	0 (0.0)
B	4 (10.5)
C	5 (13.2)
D	29 (76.3)
Adjunctive coiling	32 (84.2)
Flow diverter device type	
Pipeline Shield	22 (57.9)
Pipeline Flex	8 (21.1)
FRED	6 (15.8)
Surpass	2 (5.3)
Additional treatment (n, %)	1 (2.6)
Complication (n, %)	3 (7.9)

Abbreviations: CO, complete occlusion; FD, flow diverter; FRED, Flow-Redirection Endoluminal Device; Pcom, posterior communicating artery; OKM, O'Kelly-Marotta.

were FRED, and 2 cases (5.3%) were surpass. One case (2.6%) required additional treatment after FD treatment. Complications were observed in three cases (7.9%).

Univariate and Multivariate Analysis

►Table 3. showed the results of univariate and multivariate analysis based on the results in ►Tables 1 and 2. When comparing the two groups by dividing the results into CO and non-CO groups, univariate analysis revealed statistically significant differences in age ($p=0.021$) and aneurysmal dome size ($p=0.00281$) and neck size ($p=0.028$), and Pcom branch type ($p=0.000227$). Multivariate analysis using these factors revealed that the only type of Pcom branch from the aneurysmal dome was a statistically significant factor contributing to incomplete occlusion (odds ratio: 0.0052, 95% confidence interval 0.000048–0.584, $p=0.029$). Furthermore, when comparing the treatment results by FD type, no significant difference was found in the CO rate (►Supplementary Table S1, available in the online version). On the other hand, in terms of complications, complication rate was significantly higher in the FRED group ($p=0.0491$).

Discussion

In this study, the treatment results after FD treatment for Pcom bifurcation aneurysm were found to be acceptable, with CO in 76.3% and complication rate in 7.9%. In terms of complications, complications were significantly higher in cases using FRED. From the perspective of CO, it was suggested that the aneurysm in which the Pcom bifurcation branches from the dome is a factor that significantly lowers the occlusion rate, rather than whether the Pcom is fetal (►Table 3, Figure and ►Supplementary Table S2, available in the online version).

Table 3 Univariate and multivariate analysis of factors contributing to CO for Pcom aneurysm after flow diverter placement

Parameters	Univariate analysis			Multivariate analysis		
	CO (n = 29)	Non-CO (n = 9)	p-Value	OR	95% CI	p-Value
Age (years, mean ± SD)	65.1 ± 10.8	74.3 ± 2.9	0.021	0.838	0.693–1.01	0.0689
Female (n, %)	26 (89.7)	6 (66.7)	0.131			
Aneurysm dome size (mm, mean ± SD)	9.4 ± 4.7	15.8 ± 5.7	0.00281	0.758	0.537–1.07	0.114
Aneurysm neck size (mm, mean ± SD)	5.3 ± 1.8	7.4 ± 2.4	0.028	1.77	0.549–5.73	0.338
Past history						
Hypertension (n, %)	10 (34.5)	4 (44.4)	0.699			
Dyslipidemia (n, %)	5 (17.2)	3 (33.3)	0.363			
VerifyNow (mean ± SD)						
ARU	464.0 ± 82.4	442.3 ± 40.1	NA			
PRU	222.3 ± 34.3	211.3 ± 18.0	NA			
Platelet aggregation test (mean ± SD)						
COLL	45.4 ± 13.8	53.2 ± 15.1	0.33			
ADP	45.9 ± 10.7	48.6 ± 10.2	0.679			
Fetal-type Pcom (n, %)	9 (31.0)	6 (66.7)	0.0814			
Pcom branch			0.000227			
Nonbranch (n, %)	6 (20.7)	2 (22.2)	NA	control		
Neck branch (n, %)	22 (75.9)	1 (11.1)	NA	0.979	0.0188–51.0	0.991
Dome branch (n, %)	1 (3.4)	6 (66.7)	NA	0.0053	0.000048–0.584	0.029
P1 absence (n, %)	3 (10.3)	3 (33.3)	0.131			
History of treatment (n, %)	8 (27.6)	4 (44.4)	0.423			
Follow-up duration (months)	8.7 ± 4.4	11.8 ± 7.4	0.354			
Adjunctive coiling	23 (79.3)	9 (100.0)	0.303			
Flow diverter device type			0.8			
Pipeline Shield	17 (58.6)	5 (55.6)				
Pipeline Flex	5 (17.2)	3 (33.3)				
FRED	5 (17.2)	1 (11.1)				
Surpass	2 (6.9)	0 (0.0)				
Additional treatment (n, %)	0 (0.0)	1 (11.1)	0.237			
Complication (n, %)	2 (6.9)	1 (11.1)	1.00			

Abbreviations: ARU, Aspirin reactivity unit; CI, confidence interval; CO, complete occlusion; FRED, Flow Redirection Endoluminal Device; NA, not applicable; Pcom, posterior communicating artery; PRU, P2Y12 activity unit; SD, standard deviation.

Acceptable Outcome for Pcom Aneurysm with FD Treatment

The results of this FD treatment for Pcom were good compared with past reports.^{12–14} The high rate of adjunctive coiling (84.2%) may cause this good outcome. Looking at past reports of FD treatment for Pcom, there are few cases with adjunctive coiling. Furthermore, although it has been reported that it takes longer to achieve CO for fetal Pcom aneurysms,⁸ this may be a problem that can be overcome by using an adjunctive coiling.

Furthermore, when we looked at factors contributing to CO with multivariate analysis, we found that, unlike previous

reports,^{8,9,12} fetal Pcom was not a contributing factor to CO. On the other hand, from the perspective of the origin of Pcom, the origin of Pcom from aneurysmal dome was found to be the only contributing factor to non-CO in multivariate analysis. Looking at previous reports, fetal Pcom and P1 absence are factors that contribute to non-CO, so when we summarize CO from these points of view, we find that the non-CO rate is highest at the origin of dome Pcom branch (→ Fig. 1). Even if you think about it theoretically, in the case of a Pcom that originates from dome, blood flows out to the Pcom, so to achieve CO, a thrombosed or endothelialized corridor must be created within the aneurysm, or because

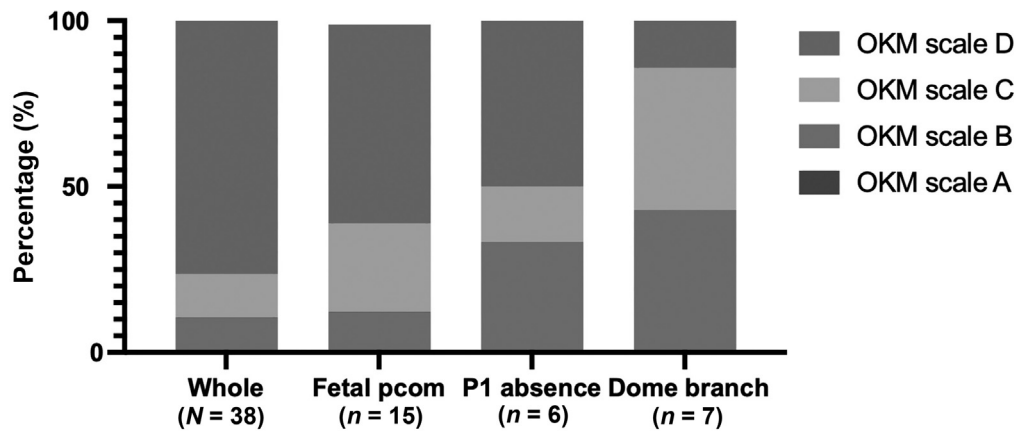


Fig. 1 The occlusion rate of posterior communicating artery (Pcom) aneurysms by branch vessel type. The occlusion rate for each fetal type, P1 absence, and dome type Pcom was evaluated using O'Kelly Marotta (OKM) scale.

the Pcom itself needs to be occluded, it is presumed that it is difficult to achieve CO without symptoms.

Complication of Pcom Aneurysm after FD Placement

This study found that complications were more common in cases using FRED. Regarding complications, all cases were thromboembolic complications that occurred early postoperatively. After FRED placement, the patient's abnormalities were quickly discovered during intensive care unit management, and fortunately there was almost no effect on modified Rankin scale, but the use of FRED for Pcom aneurysms was hesitant. We thought that this result may be due to the special structure of FRED's double layer. In cases involving areas with strong vascular tortuosity, such as Pcom, the possible mechanism is that a thrombus is formed in the gap between the double layers and flows distally. However, no such analysis results were obtained from this study. On the other hand, in our own institution's experience, no thrombotic complications have occurred in cases where FRED was placed in the posterior circulation, which is different from the anterior circulation, which has strong tortuosity. Further analysis of the mechanism of FRED's thrombotic tendency is awaited.

From the above, while the results of FD treatment for Pcom are not worse than what has been reported in the past, several tips must be considered when performing FD treatment. To obtain CO, it is necessary to pay particular attention to the type of Pcom, and when treating Pcom originating from the dome with FD, it is important to consider whether the Pcom can be sacrificed, the presence or absence of P1, and whether it is a fetal type Pcom. It will be necessary to evaluate the situation and switch to surgical treatment if necessary. However, there are only a few types of aneurysms with Pcom originate from the dome (18.4%), and we believe that most Pcom aneurysms can be treated using FD.

Limitations

There are limitations to our study. First, the number of cases is small. Only recently has FD been covered by insurance for Pcom in Japan. Partly due to this influence, our cases have a

relatively high number of recurrence cases (31.6%). We are looking forward to further case collection, including initial treatment cases. Second, it is the bias of FD type. As for FD, pipeline has been used for a long time, so from the point of view of the surgeon, pipeline is familiar and used at a high rate. Both FRED and surpass have less experience with use than pipeline due to the small number of cases. It is also possible that the lack of experience in using FRED is the reason for the high number of complications with FRED.

Conclusion

The outcome for Pcom aneurysms treated by FD was acceptable. When treating, we must pay attention to where Pcom originates. Achieving CO with FD is difficult for aneurysms where the Pcom branches from the dome. Furthermore, when treating Pcom aneurysms with FRED, it is necessary to be careful about thromboembolic complications.

Ethical Approval

The study was approved by the Institutional Review Board of Juntendo University, Graduate of School of Medicine (E22-0005-H01). All procedures performed in studies involving human participants were in accordance with the ethical standards of the institutional and/or the national research committee and with the 1964 Helsinki declaration and its later amendments or comparable ethical standers.

Patient Consent

For this type of study, patient consent is not required.

Authors' Contributions

T.F. was involved in conceptualization, methodology, formal analysis and investigation, and writing-original draft preparation. K.T., Y.M.M, and T.K. were involved in methodology. K.W., and A.K. supervised the study. H.O. was involved in review and editing, resources, and supervision.

Funding

None.

Conflict of Interest

H.O. receives donations in the form of research funds to him as an endowed chair of his department from Terumo Co., Ltd., Stryker CO., Ltd., Medtronic CO., Ltd., for consulting fees of over one million yen yearly from each of three companies.

Acknowledgments

We thank all the operation room staff for their technical assistance and the electronic medical records clerks, who helped to collect patient data.

References

- 1 Nieuwkamp DJ, Setz LE, Algra A, Linn FHH, de Rooij NK, Rinkel GJE. Changes in case fatality of aneurysmal subarachnoid haemorrhage over time, according to age, sex, and region: a meta-analysis. *Lancet Neurol* 2009;8(07):635–642
- 2 Morita A, Kirino T, Hashi K, et al; UCAS Japan Investigators. The natural course of unruptured cerebral aneurysms in a Japanese cohort. *N Engl J Med* 2012;366(26):2474–2482
- 3 Wiebers DO, Whisnant JP, Huston J III, et al; International Study of Unruptured Intracranial Aneurysms Investigators. Unruptured intracranial aneurysms: natural history, clinical outcome, and risks of surgical and endovascular treatment. *Lancet* 2003;362(9378):103–110
- 4 Nelson PK, Lylyk P, Szikora I, Wetzel SG, Wanke I, Fiorella D. The pipeline embolization device for the intracranial treatment of aneurysms trial. *AJNR Am J Neuroradiol* 2011;32(01):34–40
- 5 Becske T, Kallmes DF, Saatci I, et al. Pipeline for uncoilable or failed aneurysms: results from a multicenter clinical trial. *Radiology* 2013;267(03):858–868
- 6 Oishi H, Teranishi K, Yatomi K, Fujii T, Yamamoto M, Arai H. Flow diverter therapy using a pipeline embolization device for 100 unruptured large and giant internal carotid artery aneurysms in a single center in a Japanese population. *Neurol Med Chir (Tokyo)* 2018;58(11):461–467
- 7 Kallmes DF, Hanel R, Lopes D, et al. International retrospective study of the pipeline embolization device: a multicenter aneurysm treatment study. *AJNR Am J Neuroradiol* 2015;36(01):108–115
- 8 Rinaldo L, Brinjikji W, Cloft H, et al. Effect of fetal posterior circulation on efficacy of flow diversion for treatment of posterior communicating artery aneurysms: a multi-institutional study. *World Neurosurg* 2019;127:e1232–e1236
- 9 Kan P, Duckworth E, Puri A, Velat G, Wakhloo A. Treatment failure of fetal posterior communicating artery aneurysms with the pipeline embolization device. *J Neurointerv Surg* 2016;8(09):945–948
- 10 Brinjikji W, Kallmes DF, Cloft HJ, Lanzino G. Age-related outcomes following intracranial aneurysm treatment with the Pipeline Embolization Device: a subgroup analysis of the InTRePED registry. *J Neurosurg* 2016;124(06):1726–1730
- 11 Adeeb N, Moore JM, Wirtz M, et al. Predictors of incomplete occlusion following pipeline embolization of intracranial aneurysms: is it less effective in older patients? *AJNR Am J Neuroradiol* 2017;38(12):2295–2300
- 12 Roy AK, Howard BM, Haussen DC, et al. Reduced efficacy of the pipeline embolization device in the treatment of posterior communicating region aneurysms with fetal posterior cerebral artery configuration. *Neurosurgery* 2018;82(05):695–700
- 13 Saeki N, Rhoton AL Jr. SMicrosurgical anatomy of the upper basilar artery and the posterior circle of Willis. *J Neurosurg* 1977;46(05):563–578
- 14 Rhoton AL Jr. The supratentorial arteries. *Neurosurgery* 2002;51(4, suppl):S53–S120
- 15 Kulcsár Z, Houdart E, Bonafé A, et al. Intra-aneurysmal thrombosis as a possible cause of delayed aneurysm rupture after flow-diversion treatment. *AJNR Am J Neuroradiol* 2011;32(01):20–25