



Outcomes after Embolization in Pediatric Abdominal Solid Organ Injury: A Trauma Center Experience

Samarth Gowda¹ Tushar Ghosh¹ Rengarajan Rajagopal¹ Pawan Garg¹ Pushpinder Khara¹
Arvind Sinha² Taruna Yadav¹

¹Department of Diagnostic & Interventional Radiology, All India Institute of Medical Sciences, Jodhpur, Rajasthan, India

²Department of Pediatric Surgery, All India Institute of Medical Sciences, Jodhpur, Rajasthan, India

Address for correspondence Rengarajan Rajagopal, MD, DM, EBIR, Department of Diagnostic & Interventional Radiology, All India Institute of Medical Sciences, Basni Industrial Phase II, Jodhpur 342005, Rajasthan, India (e-mail: heraghava@gmail.com).

Indian J Radiol Imaging 2024;34:416–421.

Abstract

Background Trauma is a significant cause of morbidity and mortality worldwide among children. Nonoperative management is the standard of care in hemodynamically stable children with blunt abdominal solid organ injury. Embolization is a potential pathway, which has shown increasing evidence for benefit in adult trauma patients. However, the data in children is limited.

Materials and Methods A retrospective analysis of hospital data of all children (<18 years of age), presenting to a tertiary-care trauma center in India, with history of blunt trauma from January 2021 to June 2023, was performed. Preprocedural imaging, angiographic and embolization details, number of blood transfusions, and length of hospital stay were assessed.

Results Two hundred and sixteen children (average age: 11.65 years) presented with a history of abdominal trauma during the study period. Eighty four children were FAST positive, out of whom, 67 patients had abdominal solid organ injury on computed tomography. Liver was the most commonly injured solid organ ($n = 45$), followed by the spleen and kidney. Ten children had solid abdominal organ arterial injuries for which eight children underwent embolization. The average length of hospital stay in embolization group ($n = 8$) was 4 days, as compared to 11 days in children undergoing operative management ($n = 2$). At 6 months follow-up, all children were asymptomatic.

Conclusion Superselective embolization is a safe and feasible procedure in appropriately selected children with abdominal injury.

Keywords

- ▶ pediatric abdominal solid organ trauma
- ▶ angiography
- ▶ nonoperative management
- ▶ angioembolization

Introduction

Trauma is a significant cause of morbidity and mortality worldwide among children, with higher burden of injury in

lower middle-income countries, when compared to developed nations.¹ Abdomen is the third most common site of trauma in children, after head and extremities, with accidental blunt trauma being the cause in approximately 80% of

article published online
January 23, 2024

DOI <https://doi.org/10.1055/s-0043-1778057>.
ISSN 0971-3026.

© 2024. Indian Radiological Association. All rights reserved.
This is an open access article published by Thieme under the terms of the Creative Commons Attribution-NonDerivative-NonCommercial-License, permitting copying and reproduction so long as the original work is given appropriate credit. Contents may not be used for commercial purposes, or adapted, remixed, transformed or built upon. (<https://creativecommons.org/licenses/by-nc-nd/4.0/>)
Thieme Medical and Scientific Publishers Pvt. Ltd., A-12, 2nd Floor, Sector 2, Noida-201301 UP, India

these children. Spleen is the most commonly injured solid organ followed by the liver and kidney.² The most common mode of injury is by traffic accidents, followed by falling from height, bicycle accidents, and child abuse.^{2,3} With increasing population, rapid urbanization, and rising numbers of vehicles, the burden of disease is expected to rise in the subsequent decade. Nonoperative management (NOM) is often considered the standard of care in children with blunt solid organ injury who are hemodynamically stable, with clinical success rates more than 90%.⁴ Laparotomy can be challenging in children, and in some instances, can result in release of tamponade effect, which may lead to catastrophic bleeding. Embolization is a potential management pathway, which has shown increasing evidence for proven benefit in adult patients with blunt abdominal solid organ injuries. Compared to the large body of evidence in adults, the evidence in children is still limited. With the advent of newer endovascular technology and equipment (in small caliber that is required in children), superselective embolization is being used more frequently in children to control hemorrhage with a possibility of organ preservation.

Methodology

A retrospective analysis of hospital data of all children (<18 years of age), presenting to tertiary-care trauma center in India, with a history of blunt trauma to the abdomen from January 2021 to June 2023, was performed. Preprocedural imaging, angiographic and embolization details, number of blood transfusions, and length of hospital stay were retrieved from hospital records and analyzed. Contrast-enhanced computed tomography (CT) scans (arterial and venous phase acquisition of abdomen) using intravenous injection of 1 to 2 mL/kg body weight of iodinated contrast (Iohexol 300 mgI/mL, Omnipaque, GE Healthcare) were graded according to the American Association for the Surgery of Trauma (AAST) organ injury score. NOM was the initial approach for all children with solid organ injury on CT. Embolization was performed in children with ongoing hemorrhage defined by a hemoglobin reduction of more than 2 g/dL over 24 hours on serial laboratory measurement or persistent tachycardia despite fluid resuscitation and evidence of arterial injury on CT.

Embolization was directed based on positive findings on the preprocedure CT angiograms to reduce the use of radiation and iodinated contrast. Under adequate conscious sedation, these children underwent angiography using a 4Fr common femoral arterial access (5Fr in children with common femoral arterial access (CFA) diameter more than 2.5 mm). Superselective cannulation of the injured vessel was performed using a microcatheter (Progreat 2.4Fr, Terumo Interventional Systems, USA or Maestro 2.4Fr, Merit Medical, USA). Vascular injury seen on CT angiograms was confirmed by demonstration of pseudoaneurysm, active contrast extravasation, major vessel truncation, or arteriovenous fistula. Pushable fibered microcoils of appropriate sizes (Nester, Cook Medical, USA) were used for embolization in all patients. For liver injury, selective embolization was performed as distally as possible,

and for splenic injury selective embolization was performed to minimize the risk of splenic infarction and abscess formation. Outcome measures studied postembolization were technical success, intra- and postprocedural complications, time to discharge, and clinical outcome at 6 months postprocedure.

Results

Two hundred and sixteen children (average age: 11.65 years) presented to our trauma center emergency room during the study period with a history of abdominal trauma (►Table 1, ►Fig. 1). Road traffic accidents were the most common mode of injury followed by accidental fall from heights and stray animal-related injury. Eighty four children were FAST positive, out of which 67 patients had abdominal solid organ injury on CT angiograms. Twenty three children had more than one solid organ involvement. The liver was the most commonly injured solid organ ($n = 45$; ►Fig. 2), followed by the spleen ($n = 16$; ►Fig. 3), kidney ($n = 14$), adrenal gland ($n = 12$), and pancreas ($n = 7$). Total 18 patients had associated injuries to vascular structures (arterial and venous injuries), with a total of 13 patients showing evidence of arterial injury (demonstrated as contrast extravasation/pseudoaneurysm formation), out of which 10 patients had solid abdominal organ related arterial injuries. Two patients underwent laparotomy and operative management due to grade V splenic injury (shattered spleen with active arterial bleed into peritoneum) and grade V liver injury (parenchymal disruption with arterial injury and active bleed). Eight patients underwent embolization (liver = 7 and spleen = 1). The average length of hospital stay was 4 days in the embolization group ($n = 8$), as compared to 11 days in children undergoing operative management ($n = 2$). One child who underwent surgical management received multiple blood transfusions due to massive blood loss. One child who underwent embolization received a single unit of packed red blood cells. At 6 months follow-up, all children were asymptomatic.

Discussion

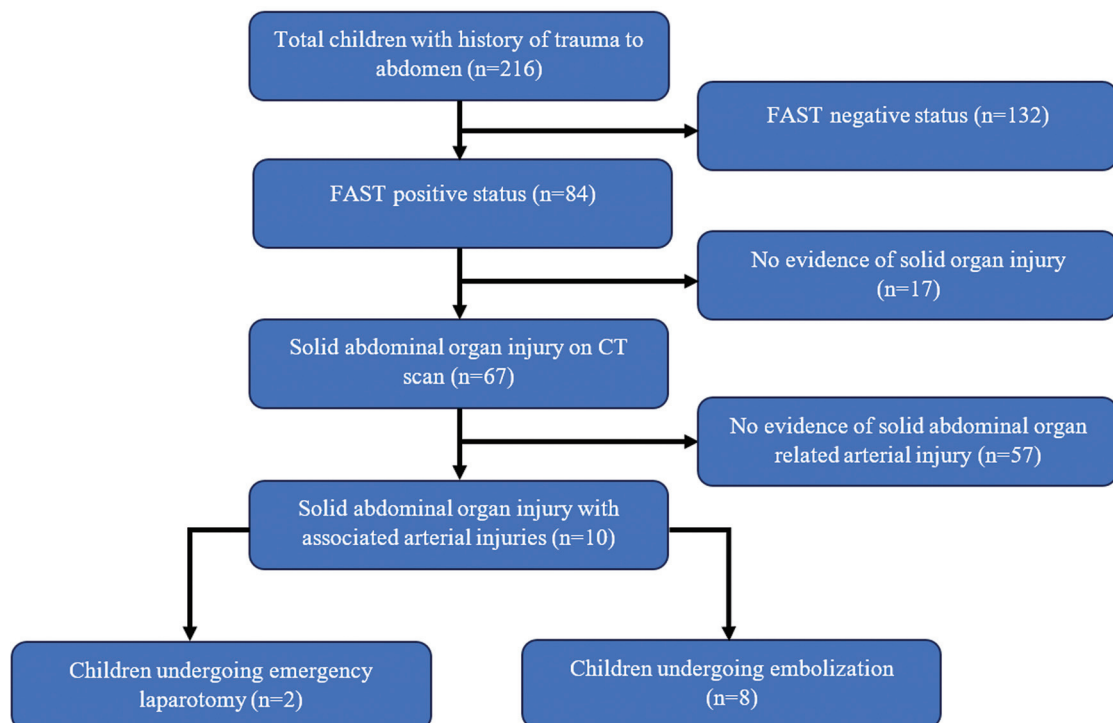
The management of children with trauma depends on the hemodynamic status at presentation.^{5,6} Though earlier guidelines were in favor of NOM for pediatric solid abdominal organ injury, failure of NOM with resultant conversion to laparotomy was estimated to be close to 3%,⁷ most common causes of which were hemorrhage and persistent hypovolemic shock. There is an increasing use of embolization in children with trauma, due to its lesser invasive nature as compared to surgery.

Children have higher success rates for NOM of solid abdominal organ injuries as compared to adults. Success rates of NOM of pediatric blunt spleen injuries are more than 90% and that for liver injuries are reported to be from 80 to 90%.¹ Isolated cases of spontaneous occlusion of pseudoaneurysm in a solid organ have been reported particularly in children.⁸ However, it has been observed that superselective embolization can be lifesaving in pediatric abdominal injuries with

Table 1 Details of children included in analysis

| Sl no. | Age | Organ involved | AAST grade | Clinical history | CT finding | Preembolization blood transfusions | Number of coils used | Average length of hospital stay in days |
|--------|------|----------------|------------|---|---|------------------------------------|----------------------|---|
| 1 | 11 y | Liver | IV | RTA | Pseudoaneurysm in right hepatic artery segmental branch | None | 2 | 6 |
| 2 | 13 y | Liver | IV | RTA | Pseudoaneurysm in left hepatic artery segmental branch | Yes | 1 | 4 |
| 3 | 10 y | Liver | III | Bull-related injury | Right hepatic artery-right portovenous fistula | None | 1 | 4 |
| 4 | 10 y | Liver | III | RTA; delayed presentation after 1 month with jaundice | Biloma with right hepatic artery segmental branch pseudoaneurysm | None | 1 | 5 |
| 5 | 7 y | Liver | III | Blunt trauma abdomen | Right hepatic artery segmental branch pseudoaneurysm | None | 1 | 3 |
| 6 | 10 y | Liver | III | Blunt trauma abdomen | Pseudoaneurysm arising from anterior segmental branch of the right hepatic artery | None | 2 | 2 |
| 7 | 17 y | Liver | III | RTA | Pseudoaneurysm arising from segmental branch of the left hepatic artery | None | 2 | 3 |
| 8 | 16 y | Spleen | V | RTA | Splenic artery pseudoaneurysm (intraparenchymal branch) | None | 3 | 5 |

Abbreviations: AAST, American Association for the Surgery of Trauma; CT, computed tomography; RTA, road traffic accident.

**Fig. 1** Details of the study. CT, computed tomography.

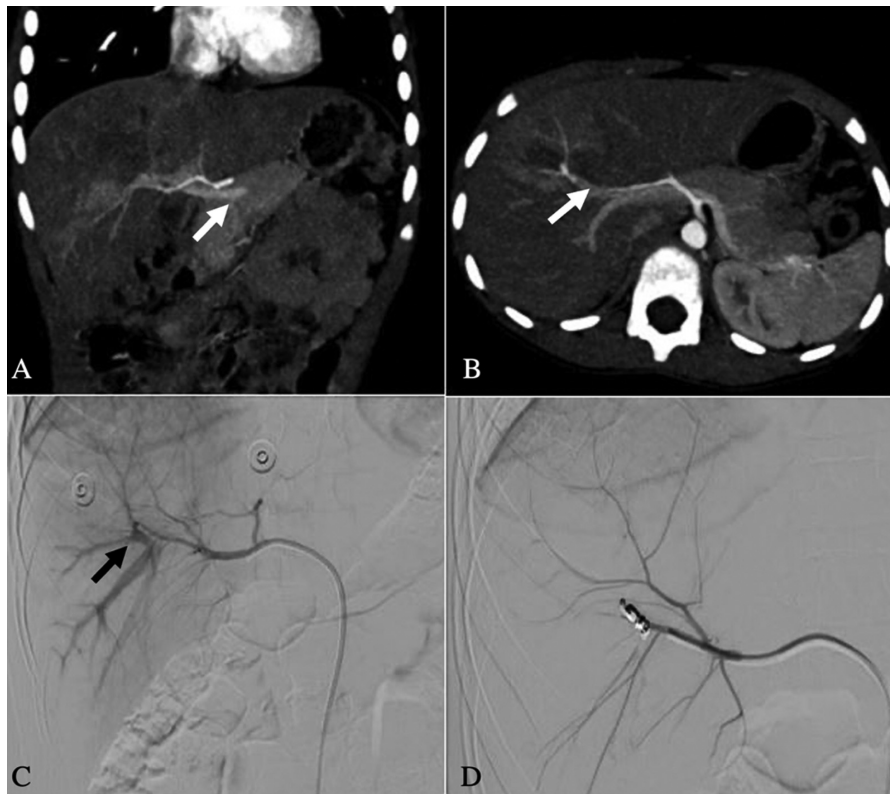


Fig. 2 Coronal and axial maximum intensity projection arterial phase images (A, B) of 10-year-old boy with bull-related injury showing early enhancement of the portal venous system in the arterial phase (white arrow), suggesting a possible hepatic arterioportal venous fistula. Selective right hepatic artery angiogram (C) depicting the early opacification of the portal vein in the arterial phase (black arrow). Post coil embolization (D) across the arterioportal fistula, there is no opacification of the portal vein.

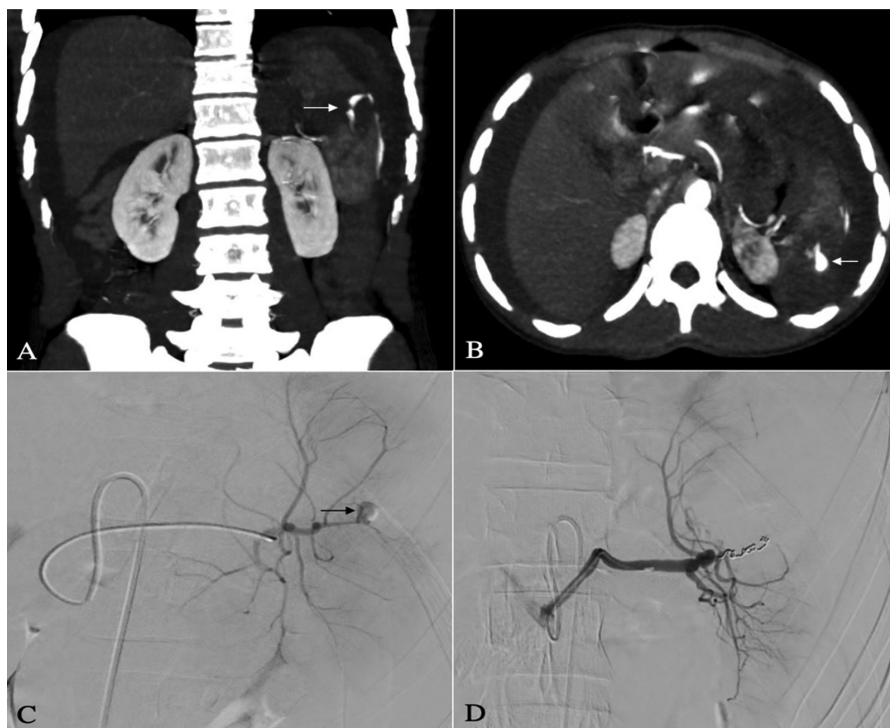


Fig. 3 Coronal and axial maximum intensity projection reformatted arterial phase images (A, B) of a 16-year-old boy with accidental road injury showing the splenic laceration with intraparenchymal pseudoaneurysm (white arrow in A) with contrast extravasation with adjacent perisplenic collection. Superselective splenic artery angiogram (C) showing the pseudoaneurysm (black arrow in C). Postembolization angiogram(D) showing exclusion of the pseudoaneurysm with normal filling of other branches.

Table 2 Prior literature

| Literature | Total overall Injuries | Average age in years | Angioembolization for solid organ injury performed | Indication | Blood transfusion before angioembolization | Major complication |
|---------------------------------|------------------------|----------------------|--|---|--|---|
| Sweed et al ⁹ | 4 | 3.75 | 4 | Active extravasation | None | None |
| Kiankhooy et al ¹⁰ | 149 | 12.3 | 7 | Ongoing hemorrhage; pseudoaneurysm | 3 | No |
| Gross et al ¹¹ | 259 | 13.5 | 21 | Contrast blush on CT; hemodynamic instability | 6 | None |
| Skattum et al ¹² | 72 | 32% < 14 youngest 6 | 22 | Bleeding; active extravasation; pseudoaneurysm | None | 1 slipped coil, 1 failure |
| Vo et al ¹³ | 97 | 16 | 21 | Active extravasation, pseudoaneurysm, AV fistula | – | hepatic abscess, bile leak, and urinary incontinence |
| Gürünlüoğlu et al ¹⁴ | 83 | 11.7 | 11 | Active extravasation | 11 | 1 (Converted to laparotomy due to ongoing hemorrhage) |
| Ben-Ishay et al ¹⁵ | 448 | 13.5 | 11 | Ongoing hemorrhage; pseudoaneurysm | 1 | Drained perisplenic abscess |
| Spijkerman et al ¹⁶ | 121 | 12 | 4 | Active extravasation | None | None |
| Ingram et al ⁸ | 318 | 10 | 1 | Contrast blush | 15 | None |
| Safavi et al ¹⁷ | 362 | 10.1 | 4 | Pseudoaneurysms with ongoing hemorrhage; 1 case was asymptomatic detected 7 days after injury | – | None |
| Linnaus et al ¹⁸ | 1008 | 10.3 | 19 | Contrast extravasation | – | None |
| Our study | 216 | 11.6 | 8 | Hemodynamic instability, CT signs –active contrast extravasation, pseudoaneurysm, hepatic arterio-portal fistula, elevated bilirubin (jaundice) | 1 | None |

Abbreviations: AV, arteriovenous; CT, computed tomography.

demonstrable vascular involvement. Embolization can offer many advantages compared to surgery, such as the intra-procedural precise localization of pseudoaneurysms, assessment of collateral flow and easier approach to the injury, particularly in case of deep-seated injuries where surgical approach may be difficult. These benefits help reduce complication rates and eventually improve clinical outcomes, morbidity, and mortality rates. However, in contrast to the established literature proving the utility of embolization in adult trauma, the evidence in pediatric population is limited and still growing (– **Table 2**). Liver injuries are well suited for embolization because of the dual blood supply from the hepatic artery and the portal vein, hence resulting in very rare chances of ischemia. Embolization is also a useful adjunct for splenic preservation, because the trabecular distribution of the intraparenchymal splenic vessels allows for targeted embolization while preserving the blood flow to noninjured areas of the organ, and also the splenic reticulo-endothelial function. This becomes vital in children as they have a high exposure to infections.

Early reports described the use of embolization, demonstrating its efficacy in small series of pediatric patients.⁹ Kiankhooy et al¹⁰ conducted a 5-year review of a total of

127 children who had hemorrhage from blunt abdominal solid organ injuries (72 spleen, 51 liver and 26 renal). The success rates of NOM in this cohort were high (>90%); however, in children with failed NOM, higher rates of splenectomy were seen.¹⁹ Other studies also reported high success rates of NOM between 80 and 90%.⁴ The addition of angioembolization could increase the already high success rates of NOM in these children. High splenic preservation rates have been demonstrated with superselective angioembolization.^{11,12}

The spectrum of angiographic findings in pediatric solid organ vascular injuries has been previously described, including active extravasation (usually most common), vessel truncation, petechial hemorrhage, vasospasm, pseudoaneurysm, dissection and arterio-venous fistula formation.¹³ Our current study had one child with hepatic arterioportal fistula, seven with pseudoaneurysms and one child with active contrast extravasation. The hemorrhage control in our child cohort was high (100%), which is similar to rates described in prior studies.

The incidence of complications caused by catheterization procedures in children ranges between 0.3 and 20%. The complications which may be seen after percutaneous

embolization include access site complications like hematoma, pseudoaneurysm formation in the femoral artery, femoral artery dissection, femoral artery thrombosis during hemostasis, and complications like visceral pseudoaneurysm rupture, coil migration, intra-abdominal organ infarction, and systemic symptoms such as fever.¹² Technical success rate in our cohort was 100% and no immediate- or short-term complications were seen. Children also reportedly have a significantly higher risk of subsequent radiation-induced malignancies as compared to adults.²⁰ However, these side effects can be reduced by thorough evaluation of preprocedural imaging, directed angiograms and by using optimal imaging technical parameters such as collimation, frame rate, and magnification.²¹ Systematic reviews have shown that splenic function was preserved after splenic artery embolization in long-term follow-up and none of the embolized patients developed opportunistic infection in postprocedure follow-up.^{12,22} Hence, routine prophylactic immunization is not performed in our center after splenic artery embolization, as splenic immune volume and function are preserved even after embolization.

Our study is limited by the small number in the embolization group. This is similar to other prior studies, where the number of injuries requiring intervention as compared to the total number of injuries was lesser in children.

Conclusion

Superselective embolization is a safe and feasible procedure in appropriately selected symptomatic children with solid abdominal organ vascular injury.

Conflict of Interest

None declared.

References

- Peden M, McGee K, Krug E. Injury: A Leading Cause of the Global Burden of Disease. Geneva: World Health Organization; 2000:1–54
- Gaines BA. Intra-abdominal solid organ injury in children: diagnosis and treatment. *J Trauma* 2009;67(2, Suppl):S135–S139
- Murray BL, Cordle RJ. Pediatric trauma. In: Marx JA, Hockberger RS, Walls RM, eds. *Rosen's Emergency Medicine: Concepts and Clinical Practice*. 8th ed. Philadelphia: Elsevier Saunders; 2014
- Vane D, Keller M, Sartorelli K, Miceli AP. Pediatric trauma: current concepts and treatment. *J Intensive Care Med* 2002;17:230–249
- Stylianou S. The APSA Trauma Committee. Evidence-based guidelines for resource utilization in children with isolated spleen or liver injury. *J Pediatr Surg* 2000;35(02):164–167, discussion 167–169
- Notrica DM, Eubanks JW III, Tuggle DW, et al. Nonoperative management of blunt liver and spleen injury in children: evaluation of the ATOMAC guideline using GRADE. *J Trauma Acute Care Surg* 2015;79(04):683–693
- Minaya-Bravo AM, Aguado-Lopez H. The challenge of blunt abdominal trauma in children: report of a case and review of Management. *J Med Cases* 2017;8(11):340–346
- Ingram MC, Siddharthan RV, Morris AD, et al. Hepatic and splenic blush on computed tomography in children following blunt abdominal trauma: Is intervention necessary? *J Trauma Acute Care Surg* 2016;81(02):266–270
- Sweed Y, Singer-Jordan J, Papura S, Loberant N, Yulevich A. Angiographic embolization in pediatric abdominal trauma. *Isr Med Assoc J* 2016;18(11):665–668
- Kiankhooy A, Sartorelli KH, Vane DW, Bhavne AD. Angiographic embolization is safe and effective therapy for blunt abdominal solid organ injury in children. *J Trauma* 2010;68(03):526–531
- Gross JL, Woll NL, Hanson CA, et al. Embolization for pediatric blunt splenic injury is an alternative to splenectomy when observation fails. *J Trauma Acute Care Surg* 2013;75(03):421–425
- Skattum J, Gaarder C, Naess PA. Splenic artery embolisation in children and adolescents—an 8 year experience. *Injury* 2014;45(01):160–163
- Vo N-J, Althoen M, Hippe DS, Prabhu SJ, Valji K, Padia SA. Pediatric abdominal and pelvic trauma: safety and efficacy of arterial embolization. *J Vasc Interv Radiol* 2014;25(02):215–220
- Gürnlüoğlu K, Ceran C, Yıldırım İO, et al. Use of angiographic embolization in trauma-induced pediatric abdominal solid organ injuries. *Ulus Travma Acil Cerrahi Derg* 2019;25(03):238–246
- Ben-Ishay O, Gutierrez IM, Pennington EC, Mooney DP. Trans-arterial embolization in children with blunt splenic injury results in postembolization syndrome: a matched case-control study. *J Trauma Acute Care Surg* 2012;73(06):1558–1563
- Spijkerman R, Bulthuis LCM, Hesselink L, Nijdam TMP, Leenen LPH, de Bruin IGJM. Management of pediatric blunt abdominal trauma in a Dutch level one trauma center. *Eur J Trauma Emerg Surg* 2021;47(05):1543–1551
- Safavi A, Beaudry P, Jamieson D, Murphy JJ. Traumatic pseudoaneurysms of the liver and spleen in children: is routine screening warranted? *J Pediatr Surg* 2011;46(05):938–941
- Linnaus ME, Langlais CS, Garcia NM, et al. Failure of nonoperative management of pediatric blunt liver and spleen injuries: a prospective Arizona-Texas-Oklahoma-Memphis-Arkansas Consortium study. *J Trauma Acute Care Surg* 2017;82(04):672–679
- Potoka DA, Schall LC, Ford HR. Risk factors for splenectomy in children with blunt splenic trauma. *J Pediatr Surg* 2002;37(03):294–299
- Brenner D, Elliston C, Hall E, Berdon W. Estimated risks of radiation-induced fatal cancer from pediatric CT. *Am J Roentgenol* 2001;176(02):289–296
- Sidhu MK, Goske MJ, Coley BJ, et al. Image gently, step lightly: increasing radiation dose awareness in pediatric interventions through an international social marketing campaign. *J Vasc Interv Radiol* 2009;20(09):1115–1119
- Schimmer JAG, van der Steeg AFW, Zuidema WP. Splenic function after angioembolization for splenic trauma in children and adults: a systematic review. *Injury* 2016;47(03):525–530