




Congenital Myopathy-1B due to RYR 1 Gene Mutation in Three Libyan Families

Samira Etarhuni¹ Majdi Kara²  Nadia Alghazir³

¹Department of Pediatric Neurology, Faculty of Medicine, University of Tripoli, Tripoli, Libya

²Department of Neuropediatric, Tripoli University, Tripoli Children Hospital, Tripoli, Libya

³Department of Pediatric Endocrine, Tripoli University, Tripoli University Hospital, Tripoli, Libya

Address for correspondence Samira Ali Etarhuni, Department of Pediatric Neurology, Faculty of Medicine, University of Tripoli, Tripoli, Libya (e-mail: samiraracd@yahoo.com).

Ibnosina J Med Biomed Sci 2024;16:77–84.

Abstract

Introduction We report a series of patients in three different Libyan families diagnosed with congenital myopathy to study the wide clinical variability between these families, and the genetic heterogeneity.

Description of Cases We describe six patients, one patient presented with severe neonatal-onset RYR1-associated myopathy while the other five patients came mainly due to delay in motor development; genetic testing confirmed the diagnosis of CMY-1B disease due to RYR1 mutation in all patients. Clinical features of congenital widely varied between the families ranging from profound hypotonia during the neonatal period in one family to a motor delay and abnormal gait during childhood in other two families. Whereas the clinical picture is quite similar in the patients of same family, the patient who presented with severe neonatal presentation of RYR1-associated myopathy also had gastrostomy feeding, respiratory involvement, clubfeet, cleft palate, and undescended testes. The five patients who presented due to delay in motor development all were ambulatory without the need of support, except the youngest one aged 4 years still walking with support. The genetic study in the form of whole-exon sequencing as well as next-generation sequencing showed homozygosity of a gene mutation in five patients and a compound heterozygosity in one patient which presented with neonatal severe hypotonia.

Conclusion CMY-1B disease is a rare autosomal dominant and recessive genetic disorder that has variable clinical presentations. The early diagnosis is very important for genetic counseling as well as avoiding malignant hyperthermia. We also report rare and unusual presentations that may further delay the diagnosis.

Keywords

- ▶ neuromuscular disorder
- ▶ central hypotonia
- ▶ genetic tests
- ▶ malignant hyperthermia
- ▶ scoliosis

DOI <https://doi.org/10.1055/s-0043-1778047>.
ISSN 1947-489X.

© 2024. The Libyan Biotechnology Research Center. All rights reserved.

This is an open access article published by Thieme under the terms of the Creative Commons Attribution-NonDerivative-NonCommercial-License, permitting copying and reproduction so long as the original work is given appropriate credit. Contents may not be used for commercial purposes, or adapted, remixed, transformed or built upon. (<https://creativecommons.org/licenses/by-nc-nd/4.0/>)

Thieme Medical and Scientific Publishers Pvt. Ltd., A-12, 2nd Floor, Sector 2, Noida-201301 UP, India

Introduction

Congenital myopathy-1B (CMY-1B) is an autosomal recessive inherited disease caused by homozygous or compound heterozygous mutation in the ryanodine receptor 1 (RYR1) gene (180901) on chromosome 19q13. A disorder of skeletal muscle characterized by severe hypotonia and generalized muscle weakness apparent soon after birth or in early childhood with delayed motor development, generalized muscle weakness and atrophy, and difficulty walking or running. Affected individuals show proximal muscle weakness with axial and shoulder girdle involvement, external ophthalmoplegia, and bulbar weakness, often resulting in feeding difficulties and respiratory insufficiency. Orthopaedic complications such as joint laxity, distal contractures, hip dislocation, cleft palate, and scoliosis are commonly observed. Serum creatinine kinase is normal.

CMY-1B is a genetic neuromuscular disorder characterized by central cores on muscle biopsy and clinical features of a CMY. Exact prevalence is not known, but the condition is most likely more common than other congenital myopathies.¹ The clinical features of CMY-1B are variable, but usually involve hypotonia at birth, mild delay in child development (highly variable between cases), weakness of the facial muscles, and skeletal malformations such as kyphoscoliosis and hip dislocation.² CMY-1B is likely to be diagnosed in infancy or childhood, but some patients remain asymptomatic until adulthood to middle age.³ While generally not progressive, there appears to be a growing number of patients who showed a slow clinical significant progression of symptoms. Autosomal dominant CMY-1A with susceptibility to malignant hyperthermia (MHS) is caused by heterozygous mutation in the RYR1 gene (a pharmacogenetic disorder of skeletal muscle characterized by an abnormal response to muscle relaxants such as succinylcholine and volatile anesthetics is a frequent complication).^{4,5} MHS is a severe and occasionally fatal reaction characterized by muscular rigidity, rhabdomyolysis, rapid increase in body temperature, and signs of generalized metabolic decompensation; survivors may suffer severe renal and neurologic damage. Many patients with cleidocranial dysplasia (CCD) test positive for the MHS trait on in vitro contracture test^{6,7} and should therefore be considered at risk for MHS during general anesthesia. Mutations in RYR1 (19q13.1), encoding a skeletal muscle calcium release channel (RYR), account for the majority of MHS and CCD cases.⁷ The onset of the CCD are widely varied, some patients of CCD can present in utero or at birth with severe CMY⁸ and some present in adulthood.⁹

Case Series

An informed consent for the publication of photos and results of investigations of our patients was signed by the families.

There were three families who attending our pediatric neurology department at the Tripoli University Hospital where the diagnosis of CMY-1B was confirmed by whole-

exon sequencing (WES) and next-generation sequencing (NGS).

Family A

Three children of first-degree consanguineous marriage to completely healthy parents.

Patient A1: A 9 years old male child presented at the age of 2 years due to delay of motor milestone, he started walking at the age of 3 but he has waddling gait and then developed severe progressive scoliosis, he has normal speech and hearing, and good school performance.

On examination: No dysmorphic features, normal higher mental functions, and average body built.

Neurological examination showed hypotonia and hyporeflexia more at lower limbs. The power in upper limbs was grade 4 and in lower limbs was grade 3 at the muscle around the hip joint, and 3 to 4 at distal muscle. He has positive Gower sign.

Examination of back showed sever scoliosis (►Fig. 1, patient A1).

Patient A2: A 6 years old female child presented at age 2 years also due to delay in motor development; currently she walks without support put with waddling gait, she also has scoliosis, she has normal speech and hearing, and good school performance.

On examination: No dysmorphic features, normal higher mental functions, and average body built.

Neurological examination showed hypotonia and hyporeflexia more at lower limbs. The power in upper limbs was grade 4 and in lower limbs was grade 3 at the muscle around the hip joint, and 3 to 4 at distal muscle. She has a positive Gower sign.

Examination of the back showed scoliosis (►Fig. 1, patient A2).

Patient A3: A 4 years old female child presented also due to delay in motor development; currently she walks with support with a waddling gait and has scoliosis. She has normal speech and hearing and good school performance.

On examination: No dysmorphic features, normal higher mental functions, and average body built.

Neurological examination showed hypotonia and hyporeflexia more at lower limbs. The power in upper limbs was grade 4 and in lower limbs grade was 3 at the muscle around the hip joint, and 3 to 4 at distal muscle. She has a positive Gower sign.

Examination of the back showed scoliosis (►Fig. 1, patient A3).

WES confirmed that patients A1, A2, and A3 of this family have CMY-1B disease due to mutation of RYR1 in homozygous state, both the mother and father carry the same gene mutation in heterozygous state (►Table 1).

Family B

Patient B1

One male child aged 3 years old, product of nonconsanguineous marriage of healthy parents, presented from neonatal period due to severe hypotonia; he is a product of full-term

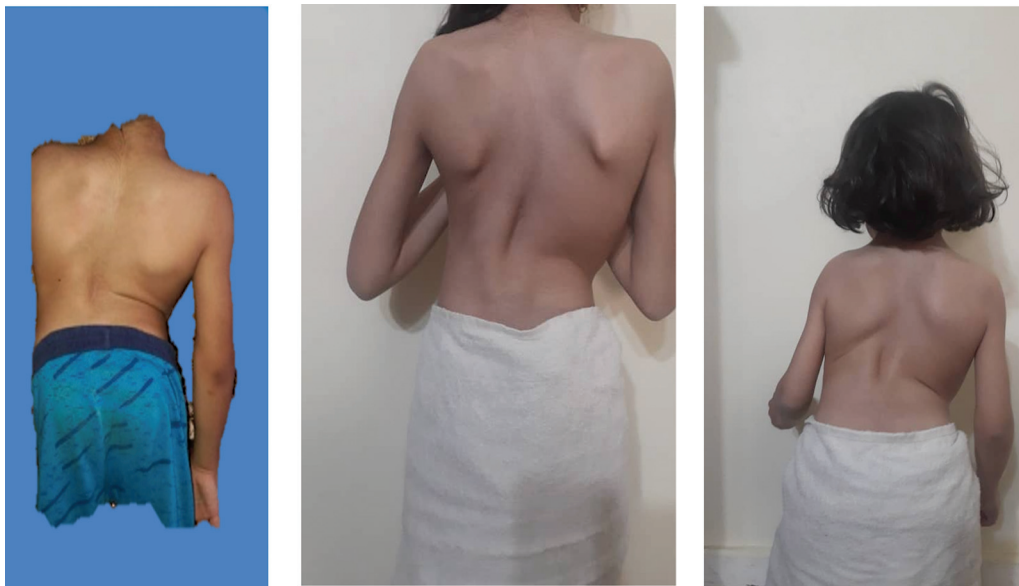

Fig. 1 Family A. Photos of family A (patients A1, A2, and A3) showed sever scoliosis.

normal vaginal delivery with no history of birth asphyxia. The patient was kept in nursery due to sever hypotonia, and also had a cleft palate, club feet, and bilateral undescended tests. Currently, the patient has a profound motor delay with head lag and unable to sit, his weight is 8,500g which is below the third centile on growth chart. The patient at 1.5 years started feeding by gastrostomy tube (► **Fig. 2**). He has recurrent hospital admissions due to recurrent chest infections.

On examination, he is alert, follows objects, and turns to sounds with complete head lag.

The upper and lower limbs showed sever hypotonia and hyporeflexia.

WES confirmed that the child has two gene mutations, it identified the heterozygous variant c.8692 + 3G> A in RYR1 (OMIM 255320) causing CMY-1B and also identified the heterozygous variant c.2787-11 C> T in RYR1 (OMIM 180901) causing CMY-1A (see ► **Table 2**).

Family C

Two children, one male and one female, product of healthy parents, first-degree consanguineous marriage.

Patient C1: A 7 years old male patient presented to our clinic at the age of 3 years because of abnormal walking. He is a product of full-term normal vaginal delivery, given

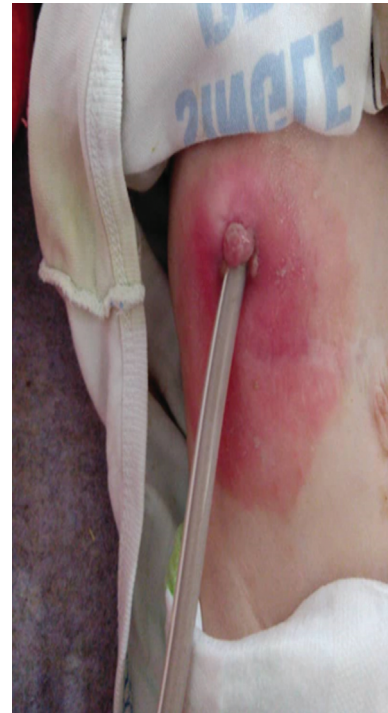

Fig. 2 Family B. Patient B showed gastrostomy tube inserted at age of one and half years.

Table 1 Interpretation: WES identified the homozygous variant c.11315 c.11315G> A P. (Arg3772Gln) in RYR1 (OMIM: 180901) which lead to an amino acid exchange

Gene (Isoform)	OMIM-P (mode of inheritance)	Variant	Zygoty	MAF gnomAD [%]	Classification
RYR1 (NM_000540.2)	117000(AR) 255320(AR)	c.11315G> A P.(Arg3772Gln) Chr19:39025415	homo -	0.0016	Pathogenic

Abbreviations: gnomAD, Genome Aggregation Database; MAF, minor allele frequency; WES, whole-exon sequencing.

Note: Eight out of 9 bioinformatic in silico programs predict a pathogenic effect for this variant. Parallel analysis of parental WES data revealed that both parents are heterozygous carriers of the detected variant in RYR1. This confirms homozygosity of detected variant in the index (Bioscientia, Ingelhiem, Germany).

Table 2 WES identified the heterozygous variant c.8692 + 3G> A in RYR1 (OMIM 18901)

Gene (isoform)	OMIM-P (mode of inheritance)	Variant	Zygoty	MAF gnomAD[%]	Classification
RYR1 (NM_000540.2)	255320(AR)	c.8692 + 3G> A P? Chr19:38997189	het.	0	Variant of uncertain significance

Abbreviations: gnomAD, Genome Aggregation Database; MAF, minor allele frequency; mRNA, messenger ribonucleic acid; WES, whole-exon sequencing.

Note: The identified variant could lead to significant alteration of the mRNA splicing due to an altered donor site.

To the best of our knowledge the variant has not been described in literature so far (HGMD2019.3). Allele frequency of this variant in the general population has not been documented and this is the first time we detected it in our internal database. Considering the available information the variant is classified as variant of uncertain significant. WES also identified the heterozygous variant c.2787-11 C> T in RYR1 (OMIM 180901). The identified variant could lead to significant alteration of the mRNA splicing due to an altered acceptor site (Bioscientia, Ingelhiem, Germany).

immediately to the mother, and he developed normally until he started walking where the parents noted that he has abnormal gait. His speech and hearing are normal with good school performance.

On examination:

No dysmorphic feature, average built, convergent sequent, and spastic gait.

The tone and reflexes are increased more in lower limbs along with positive clonus. The power in upper limbs was grade 4 to 5, and in lower limbs was grade 4 at the muscle around the hip joint, and grade 4 at distal muscle. He has positive Gower sign. Magnetic resonance imaging (MRI) brain was normal (►Fig. 3, patient C1).

Patient C2: A 5 years old female child presented to our clinic at the age of 3 because of abnormal walking. She is a product of full-term normal vaginal delivery, given immediately to the mother, and developed normally until she started walking where the parents noted abnormal gait. Her speech and hearing are normal with good school performance.

On examination:

No dysmorphic feature, average built, and abnormal gait.

The tone and reflexes are increased more in lower limbs along with positive clonus. The power in upper limbs was grade 4 to 5 and in lower limbs was grade 4 at the muscle around the hip joint, and grade 4 at distal muscle. She has positive Gower sign. MRI brain was normal (►Fig. 3, patient C2).

NGS confirmed that the patients of this family have CMY-1B due to mutation in the RYR1 gene, both the mother and father carry the same gene mutation in the heterozygous state.

The coding exons of the RYR1 gene (OMIM 180901; chromosome 19q13.2) were enriched using Roche\Nimble-Gen sequence capture technology and sequenced on an Illumine system (NGS), see ►Table 3.

Discussion

When analyzing the data of our three families (see ►Table 4) we have clearly noted that there are different clinical presentations, first the age of presentation, while the affected children of the first and third families presented around the

age of 3 years due to delay in motor development and abnormal gait, the child of the second family presented from the neonatal period due to severe hypotonia.

While the child of the second family had multiple congenital anomalies in the form of cleft palate, bilateral undescended tests, and club feet, the children of the other two families had no congenital anomaly.

While the feeding history the children of family one and three are normal, the child of the second family is fed by gastrostomy tube because of severe hypotonia along with the cleft palate.

The child of the second family had many hospital admissions due to recurrent chest infections, the other two families did not report any hospital admissions.

There are strong positive consanguinity in family A and C, while no consanguinity was observed in family B.

The examination of these children also revealed wide variations; hypotonia was very severe in the child of the second family, whereas it was mild in the children of first and second families. The reflexes were decreased in the children of family one, absent in the child of the second family, and were exaggerated in the children of the third family.

The presence of scoliosis was also different, it was severe and needed surgical interventions in family one (►Fig. 1), while it was not present in the child of the second and third families.

The eye examination revealed presence of sequent in one child of the third family only.

The body weight of the children of family one and three are average and going with their age, the child of the second family is blow third centile of the growth chart.

The diagnosis of CMY in all our children is confirmed by genetic studies in the form of WES and NGS which revealed the presence of a gene mutation on the RYR1 gene (AR) (see ►Table 5). Were the family A and C the state of gene are homozygous and classified as pathogenic put with the considering the supportive phenotype of the patient of second family (B1) and assuming compound heterozygosity of the two variants of uncertain significance (VUS) in RYR1, a genetic diagnosis of CMY-1B or CMY-1A are possible. And as both parents of this patient are asymptomatic the diagnosis of CMY-1B is more likely.

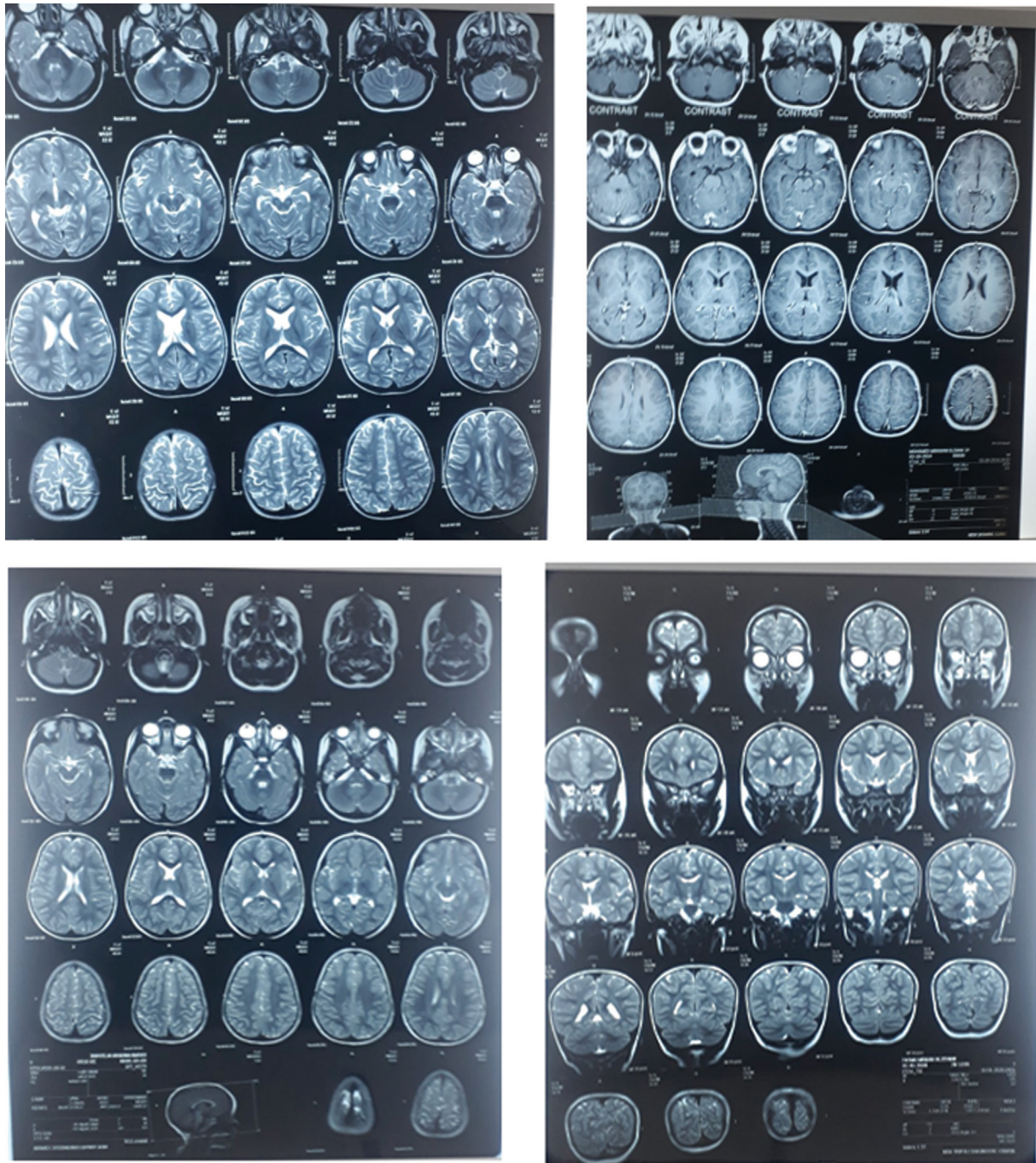


Fig. 3 Family C. Magnetic resonance imaging (MRI) brain of patient C1 showed normal study. MRI brain of patient C2 showed normal study also.

The investigations of our child revealed mild elevations of muscle enzyme (cpk) in all three families. Other routine investigations were all normal in all the patients.

MRI of the brain were also normal in all our children.

Comparing our study with the study done by Klein et al¹⁰ who reported 40 patients from 35 families with myopathy associated with a heterozygous RYR1 mutation, they concluded that the severity and age at onset were highly variable and these findings were also concluded in our study.

They also concluded that the onset ranged from reduced fetal movements and polyhydramnios prenatally to adult-onset muscle weakness. In our study, we also noticed differ-

ent age of onset ranging from neonatal period with severe hypotonia to the early childhood presenting with delay in motor development. They also noticed that most patients could walk, put only 14 could run,¹⁰ in our study five patients could walk, put could not run, one of them still walked with support, and one was completely bedridden.

Regarding family B, comparing our study with the study conducted by Bharucha-Goebel et al⁸ who also reported 11 patients, presented in neonatal onset RYR1-associated myopathy which are confirmed by genetic study, including two siblings, with severe congenital RYR1-associated myopathy, they concluded variable features present at birth including

Table 3 Interpretation: NGS analysis of the RYR gene revealed the homozygous variant c.2383C> T p. (P.(Arg795CYs) in exon20 of the RYR1 gene

Gene (isoform)	OMIM-P (mode of inheritance)	Variant	Zygoty	MAF gnomAD[%]	Classification
RYR1 (NM_000540.2)	117000(AR) 255320(AR)	c.2383C> T P.(Arg795CYs) Chr19:38951037	homo -	0.0016	Pathogenic

Abbreviations: gnomAD, Genome Aggregation Database; MAF, minor allele frequency; NGS, next-generation sequencing.

Note: To the best of our knowledge this variant has not been described in literature so far (HGMD) version2091.4. Its allele frequency in general population is 0.005% (gnomAD database), which would be compatible with a potential pathogenicity. A significant effect on protein function was predicted by 16 out of 20 bioinformatics analysis tools used. Considering the available information the variant can be classified as likely pathogenic (Bioscientia, Ingelhiem, Germany).

Table 4 Comparison study of our patients in the three families regarding their gender, age of onset, different clinical feature, and their inheritance

Patient	Current age	Gender	Onset	Consanguinity	Clinical examination	Congenital anomaly	Sequent	Scoliosis	Inheritance
Family A Patient A1 Patient A2 Patient A3	9 years 7 years 4 years	Male Female Female	2 years 2 years 2 years	First degree	Hypotonia, hyporeflexia Hypotonia, hyporeflexia Hypotonia, hyporeflexia	Absent Absent Absent	Absent Absent Absent	Present Present Present	Homozygous mutations in the RYR1 gene
Family B Patient B1	3 years	Male	Early neonatal period	First degree	Sever hypotonia, areflexia	Present	Absent	Absent	Heterozygous missense mutations in the RYR1 gene
Family C Patient C1 Patient C2	6 years 5 years	Male Female	2 years 2 years	First degree	Hypotonia, hyperreflexia Hypotonia, hyperreflexia	Absent Absent	Present Present	Present Present	Homozygous mutations in the RYR1 gene

Table 5 Results of genetic study performed in the three families

	Gene (isoform)	OMIM-P (mode of inheritance)	Variant	Zygoty	MAF gnomAD[%]	Classification
Family A	RYR1 (NM_000540.2)	117000(AR) 255320(AR)	c.11315G> A P.(Arg3772GLn) Chr19:39025415	homo -	0.0016	Pathogenic
Family B	RYR1 (NM_000540.2)	255320(AR)	c.8692 + 3G> A P.? Chr19:38997189	het.	0	Variant of uncertain significance
			c.2787-11C.T P.? Chr19:38955268	het.	0	Variant of uncertain significance
Family C	RYR1 (NM_000540.2)	117000(AR) 255320(AR)	c.2383C> T P.(Arg795CYs) Chr19:38951037	homo -	0.0016	Pathogenic

Abbreviations: gnomAD, Genome Aggregation Database; MAF, minor allele frequency.

hypotonia, feeding difficulties, arthrogryposis, hip dislocation, and respiratory insufficiency, our patient also had gastrostomy tube and recurrent respiratory infections. Other variable features included kyphoscoliosis, cleft palate (also present in our patient), rigid spine, and ophthalmoparesis. The genetic study carried in this study revealed four with dominant RYR1 mutation, and seven had recessive RYR1 mutation, six patients were compound heterozygosity for

RYR1 gene mutation, our patient also carried compound heterozygosity for RYR1 gene. And due to these typical phenotypes of our patient comparing them with this study as well as the presence of compound heterozygosity which is also reported in this study, we consider the gene mutation of our patient is pathogenic rather than of uncertain significant.

The presence of hyperreflexia and positive clonus in the two patients in the same family were not reported before and we did

not find the explanation for these findings. Matthews et al⁹ reported three patients with periodic paralysis who were found to have heterozygous or compound heterozygous mutations in the RYR1 gene. One patient had an early-onset proximal myopathy and developed ophthalmoplegia, but the others did not. Three of four had a positive McManis test and abnormal muscle biopsy with variation in fiber size and increased internal nuclei. The fourth case had only episodic limb weakness with myalgia and cramping from the age of 23 years.

Conclusion

CMY-1A and CMY-1B are very rare diseases caused by mutations in the RYR1 gene located on chromosome 19q13, some mutations of the gene are inherited as an autosomal dominant way causing CMY-1A, some are inherited as an autosomal recessive way causing CMY-1B, the autosomal dominant type carry the risk of MHS while the recessive type are not. CMY has variable clinical presentations, the early diagnosis of the disease is very important for genetic counseling as well as to avoid MHS which is a recognized complication in patients carrying dominant mutation which manifests when these patient are exposed to certain anesthetic drugs. Also, we report the unusual presentation of this disease in one family, which presented with upper motor neural sign in the form of hypertonia and hyperreflexia which was not reported before. On the other hand, we report one patient presented with neonatal onset of disease which is a very rare presentation, which carry compound heterozygous mutation of the RYR1 gene with typical phenotype as well as congenital anomaly such as cleft palate which is reported only in one patient before.

Compliance with Ethical Principles

Prior ethical approval is not required for single cases and small case series. All patients or guardians consented for participation provided identity is not revealed.

Funding

None.

Conflict of Interest

None declared.

Acknowledgment

The author would like to thank all families that participated in this study.

Reference

- 1 Jungbluth H. Central core disease. *Orphanet J Rare Dis* 2007;2:25
- 2 Quinlivan RM, Muller CR, Davis M, et al. Central core disease: clinical, pathological, and genetic features. *Arch Dis Child* 2003;88(12):1051–1055
- 3 Talwalkar SS, Parker JR, Heffner RR, et al. Adult central core disease. Clinical, histologic and genetic aspects: case report and review of the literature. *Clin Neuropathol* 2006;25(04):180–184
- 4 Denborough MA, Forster JF, Lovell RR, et al. Anaesthetic deaths in a family. *Br J Anaesth* 1962;34:395–396
- 5 Rueffert H, Olthoff D, Deutrich C, et al. A new mutation in the skeletal ryanodine receptor gene (RYR1) is potentially causative of malignant hyperthermia, central core disease, and severe skeletal malformation. *Am J Med Genet A* 2004;124A(03):248–254
- 6 Shuaib A, Paasuke RT, Brownell KW. Central core disease. Clinical features in 13 patients. *Medicine (Baltimore)* 1987;66(05):389–396
- 7 Robinson RL, Brooks C, Brown SL, et al. RYR1 mutations causing central core disease are associated with more severe malignant hyperthermia in vitro contracture test phenotypes. *Hum Mutat* 2002;20(02):88–97
- 8 Bharucha-Goebel DX, Santi M, Medne L, et al. Severe congenital RYR1-associated myopathy: the expanding clinicopathologic and genetic spectrum. *Neurology* 2013;80(17):1584–1589
- 9 Matthews E, Neuwirth C, Jaffer F, et al. Atypical periodic paralysis and myalgia: a novel RYR1 phenotype. *Neurology* 2018;90(05):e412–e418
- 10 Klein MJ, Kuemin C, Tamulevicius T, et al. Note: a microfluidic chip setup for capillarity-assisted particle assembly. *Erratum Rev Sci Instrum* 2012;83(08):086109