

Accidental Ingestion of Live Ants

Brij Sharma¹ Vishal Bodh¹ Rajesh Sharma¹ Ashish Chauhan¹ Mohit Tripathi¹ Anshul Bhateja¹ 

¹ Department of Gastroenterology, IGM, Shimla, Himachal Pradesh, India

Address for correspondence Anshul Bhateja, MD, Department of Gastroenterology, IGM, Shimla, Himachal Pradesh 171001, India (e-mail: dr.anshulabh@gmail.com).

J Digest Endosc 2023;14:249–250.

A 23-year-old male presented in emergency department with complaint of foreign body sensation in throat after accidental ingestion of live ants during suctioning of a hollow rubber garden watering pipe. Immediately after ingestion, he spit most of the ants and did warm water gargles. Despite all these measures, he continued to have foreign body sensation in throat, so direct laryngoscopy was performed and dead ants were seen adhering to epiglottis and pyriform fossa (► **Fig. 1**). His upper gastrointestinal endoscopy was done after couple of hours of presentation that revealed one live ant in stomach with adjacent small ulcer (► **Fig. 2**). The dead ants in epiglottis and pyriform fossa as well as one live ant in stomach were removed under endoscopic guidance using foreign body forceps following which patient had relief in his symptoms and patient was discharged in satisfactory condition. On follow-up after 1 month, patient was asymptomatic.

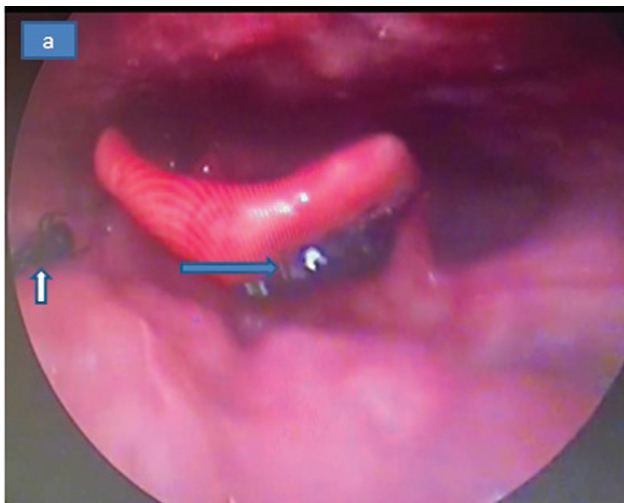


Fig. 1 Direct Laryngoscopic Image showing dead ants adherent to epiglottis and pyriform fossa.

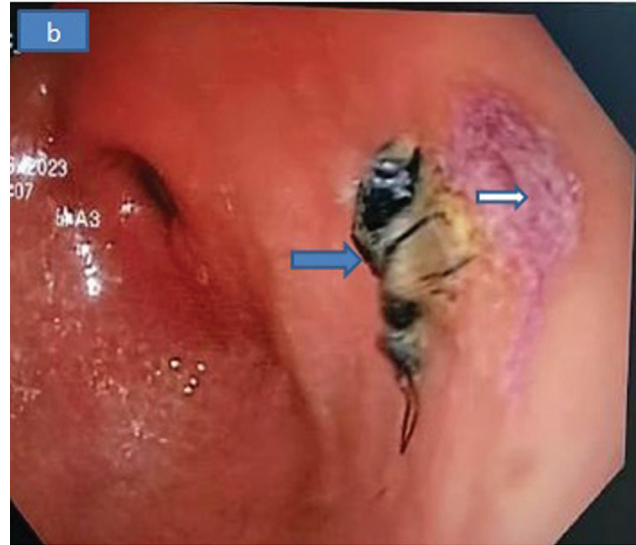


Fig. 2 Upper gastrointestinal endoscopy image showing one live ant in stomach with adjacent small ulcer.

article published online
December 12, 2023

DOI <https://doi.org/10.1055/s-0043-1777342>.
ISSN 0976-5042.

© 2023. The Author(s).

This is an open access article published by Thieme under the terms of the Creative Commons Attribution License, permitting unrestricted use, distribution, and reproduction so long as the original work is properly cited. (<https://creativecommons.org/licenses/by/4.0/>)

Thieme Medical and Scientific Publishers Pvt. Ltd., A-12, 2nd Floor, Sector 2, Noida-201301 UP, India

