Article published online: 2024-01-22

Original Article

Morphometry of Superior Sagittal Sinus and Its Clinical Significance

Grace Suganya[1] Ariharan Krishnaraj[2] Raveendranath Veeramani[3] Dinesh Kumar[3] Nagarajan Krishnan[2]

[1] Department of Anatomy, All India Institute of Medical Sciences (AIIMS) Kalyani, Nadia, West Bengal, India
[2] Department of Radiology, Jawaharlal Institute of Postgraduate Medical Education and Research (JIPMER), Puducherry, India
[3] Department of Anatomy, Jawaharlal Institute of Postgraduate Medical Education and Research (JIPMER)], Puducherry, India

Address for correspondence Raveendranath Veeramani, MD, Department of Anatomy, Jawaharlal Institute of Postgraduate Medical Education and Research (JIPMER), Dhanvantri Nagar, Puducherry-605006, India (e-mail: dr_raveendra@rediffmail.com).

Indian J Neurosurg

Abstract

The position of the superior sagittal sinus (SSS) in the midline along the sagittal suture is still a debate among neurosurgeons. The aim of the study is to evaluate the diameter and deviation of the SSS at various landmarks in the midline. We evaluated 100 computed tomography venography images. The mean diameter of SSS between nasion and bregma was 2.6 ± 0.7 mm and it was 3.7 ± 0.9 at bregma. Between bregma and lambda and at lambda, the mean diameters were 5.1 ± 1.2 and 5.7 ± 1.04, respectively. Deviation of SSS toward the right side was seen in approximately 77% of cases, while left deviation and no deviation were seen in 11 and 12%, respectively, between nasion and bregma. At bregma, 62, 10, and 28% deviation was seen toward the right side, left side, and in midline, respectively. In other three segments between bregma and lambda, at lambda and beyond lambda the right and left deviation of SSS were found in 68, 70, 71% and 11, 9, 11% respectively. While in these three segments there was no deviation in SSS in 21(between bregma and lambda), 21(at lambda) and 18% (beyond lambda). Further, we compared our data between genders and age groups. A statistically significant difference in diameter of SSS between genders was noted at the level of bregma and a significant difference in deviation of SSS between genders was noted in the segment between nasion and bregma. Thus, the findings of this study would serve as the crucial surgical data for the neurosurgeons in placing the burr holes in craniotomies and in the interhemispheric approach for midline tumors.

Keywords
- superior sagittal sinus
- sagittal suture
- bregma
- lambda
- burr holes

Introduction

Dural venous sinuses, situated between the endosteal and meningeal layers of dura mater, drain blood from the brain and cranial bones. They are lined by endothelium and have no valves. Their walls are thin and devoid of muscular tissue.[1] The superior sagittal sinus (SSS) is located in the falx cerebri in the midline, curving the inner surface of the frontal bone, in between the parietal and the occipital bone in its squamous part.[1]

To date, sagittal suture in the midline extending from nasion to inion was considered as the external landmark to locate the SSS by the neurosurgeons. But there are a lot of studies contesting this fact.[2] The deviation of the SSS from the

DOI https://doi.org/10.1055/s-0043-1777276.
ISSN 2277-954X.

© 2024. The Author(s).
This is an open access article published by Thieme under the terms of the Creative Commons Attribution License, permitting unrestricted use, distribution, and reproduction so long as the original work is properly cited. (https://creativecommons.org/licenses/by/4.0/)
Thieme Medical and Scientific Publishers Pvt. Ltd., A-12, 2nd Floor, Sector 2, Noida-201301 UP, India

midline was noticed in various studies. This may be of importance to the neurosurgeons in the placement of burr holes for craniotomies and in the interhemispheric approach to the midline tumors and the vascular lesions. Any fortuitous injury to the sinus during surgical approaches leads to uncontrolled bleeding leading to catastrophic results.[3]

The aim of this study is to evaluate the diameter of SSS and deviation of SSS from midline using computed tomographic venography (CTV) taking certain landmarks in the midline and dividing the SSS into segments based on the landmarks. Thus, the findings of this study might help in knowing the preoperative positioning and diameter of SSS at various landmarks in the midline and help in preventing the various potential intraoperative complications.

Materials and Methods

This study was a descriptive study with data collected retrospectively. The study was done in the Department of Radiology and the Department of Anatomy between 2020 and 2022. The normal CTV studies of the patients, evaluated for various neurological/ neurosurgical conditions, were taken up for this study. The consecutive 100 CTV studies were used up for analysis. The data were taken from the Picture Archiving and Communication System (PACS) of the Department of Radiology, from the year 2017-to 2020. Approval from both the Departmental Postgraduate Research Monitoring Committee and the Institute Human Ethics Committee was obtained. (JIP/IEC/2020/076). All cerebral CTV studies done during 2017 to 2020; patients between the age group of 18 to 60 years, who were reported as normal by a neuroradiologist, were included in the study. Patients with poor quality of CTV either due to motion artifacts or inadequate contrast opacification or pathologies affecting the normal venous anatomy like venous thrombosis and tumor invading dural venous sinuses were excluded from the study.

CTV records of patients satisfying inclusion criteria were used in the study. The CTV studies of the brain were retrieved from PACS, Department of Radiology.

The CTV datasets were loaded in SERVER WORKSTATION (Siemens Syngovia, Germany) and the venographic images obtained in the axial plane were reconstructed by multiplanar reformation and the diameter and deviation of SSS were noted in the appropriate plane. The landmarks used were nasion, bregma, and lambda. Based on these landmarks, the SSS was divided into five segments. The segments were between nasion and bregma, at bregma, between bregma and lambda, at lambda, and beyond the level of lambda The diameter and position of SSS were measured at these landmarks. All measurements were done by a single investigator thrice and its mean was taken as final. Twenty-five CTV images were measured independently by another observer and the interobserver variability was checked. Twenty-five CTV images evaluated by the principal investigator have repeated again after a month and the intraobserver variability was checked. The demographic data like age and sex were noted. The records were divided into five groups based on the ages less than or equal to 20, 21 to 30, 31 to 40, 41 to 50, 51 to 60, and the data were evaluated.

Independent Student's *t*-test was done to compare gender differences between the above-mentioned parameters. One-way analysis of variance was done to compare the variables between different age groups. A post-hoc Tukey test was done to compare each age group.

p-Value less than 0.05 was considered as significant. Chi-squared test was used to analyze the frequency of deviation of SSS at various landmarks. Statistical Package for Social Sciences (SPSS) software version 19.0 was used for all statistical analysis

CTV versus MRV or DSA

We used CTV as the intravenously injected contrast results in uniform opacification of the dural venous sinuses, unlike the magnetic resonance venography (MRV) where flow-related inherent artifacts may obscure detail or digital subtraction angiography (DSA) venous phase with nonopacified blood joining the contrast resulting in wrong estimation of sinus lumen or diameter.

Results

In this study, 100 CTV records were analyzed, out of which 37 records were of from male subjects and 63 from female subjects. In this study, along the sagittal suture, the sinus was divided into five segments based on the various bony landmarks in the midline. The landmarks used were nasion, bregma, and lambda. The segments were between nasion and bregma, at bregma, between bregma and lambda, at lambda, and beyond the level of lambda. The diameter and deviation of SSS were measured at these segments.

Diameter of SSS

The mean diameter between nasion and bregma was 2.6 ± 0.7 ranging from 4.3 to 1.2 mm. The mean diameter at bregma was 3.7 ± 0.9 ranging from 6.3 to 1.7 mm. The mean diameter in the other two landmarks between bregma and lambda and lambda were 5.1 ± 1.2 (8.2–2 0.2 mm) and 5.7 ± 1.04 (8–2 mm), respectively. The overall diameter and comparison of diameters of SSS at various landmarks between genders are given in ►**Table 1**. The comparison of diameters of SSS at various landmarks between different age groups are summarized in ►**Table 2**. At the level of bregma, there was a significant difference in the diameter of SSS between the genders ($p = 0.017$). However, there was no other significant difference in diameter of SSS between the genders or the age groups. The CTV images showing the measurement of the diameter of SSS between nasion and bregma, at bregma, between bregma and lambda, and at lambda are given in ►**Figs. 1**, **2**, **3**, and **4**, respectively.

Deviation of SSS

The deviation of the SSS from the midline, that is, from the sagittal suture was noted. The deviation was more towards right side when compared to that of left side. At the level between nasion and bregma, the right and left deviation

 © 2024. The Author(s).

Table 1 Overall and comparison of diameter of SSS between gender

Landmarks	Mean ± SD	Maximum–Minimum (mm)	Mean ± SD		Maximum–Minimum (mm)		*p*-Value
			Male ($n = 37$)	Male ($n = 37$)	Male ($n = 37$)	Female ($n = 63$)	
SSS—between nasion and bregma (mm)	2.6 ± 0.7	4.3–1.2	2.7 ± 0.8	4.3–1.2	3.9–1.3	0.32	0.32
SSS—bregma (mm)	3.7 ± 0.9	6.3–1.7	4 ± 1.02	6.3–1.8	5.3–1.7	0.38	0.38
SSS—between bregma and lambda (mm)	5.1 ± 1.2	8.2–2 0.2	5.3 ± 1.3	8–2.8	8.2–2.2	0.017[a]	0.017[a]
SSS—lambda (mm)	5.7 ± 1.04	8–2	5.9 ± 1.08	5.5 ± 1.005	7.6–6.3	8–5.3	0.115

Abbreviations: SD, standard deviation; SSS, superior sagittal sinus.
Independent *t*-test was done to compare the difference between the gender.
[a]$p < 0.05$ was considered as statistically significant.

were 77 and 11%, respectively, and there was no deviation in around 12%. Whereas at the level of bregma deviation was 62 and 10% toward right and left side, respectively, no deviation was seen in 28%. Between bregma and lambda, no deviation was seen in 21%, while the right deviation was 68% and the left deviation was 11%. In other two landmarks at lambda and beyond lambda, the right deviation was 70 and 9%, respectively. However, the left deviation was 9% at lambda and 11% beyond the level of lambda. Around 21% had no deviation at the level of lambda and 18% had no deviation beyond the level of lambda. The overall deviation of SSS at various landmarks is given in ►**Table 3**.

The deviation of SSS was measured from midline; the mean deviation to the right between nasion and bregma was 3 mm, whereas on the left side it was 1.5 mm, at bregma the right deviation was 4 mm, and at left it was 1.8 mm. While the mean deviation on right side between bregma and lambda was 3.5 mm, to the left it was 2 mm and at lambda the mean right deviation was 5 mm and at the left side it was 3 mm. Beyond the level of lambda, the mean deviation was 5.8 mm toward right and toward left it was 3.2 mm.

The frequency of deviation of SSS from the sagittal suture was compared between genders. There was a significant difference noticed in the deviation of SSS between nasion and bregma between genders. The results are summarized in ►**Table 4**. The CTV image showing the deviation of SSS is given in ►**Fig. 5**. Three-dimensional image showing the deviation of SSS from sagittal suture at the site between bregma and lambda is given in ►**Fig. 6**.

Dominancy of Transverse Sinus

The dominancy of the transverse sinus (TS) was decided by the flow pattern of SSS into TS. According to the flow pattern based on the continuation of SSS at the level of lambda, the dominancy was decided. If the SSS continue as the right TS, it is right dominance, or if SSS continue as left TS, it is left dominance. On the other hand if SSS splits into right and left TS at the level of lambda then it is considered as equal dominance. Around 52% of the cases had a right dominance, 23% had left dominance, and 41% had equal dominance.

Discussion

The SSS is located in the falx cerebri in the midline extending from the crista galli to the level of the internal occipital protuberance. The sinus is said to be coursing in the midline along the sagittal suture. As per literature, there were many cadaveric and radiological studies done to estimate the width and the position of the SSS using various landmarks in the midline.

Diameter of SSS

The width or diameter of the SSS was found to be increasing as it courses posteriorly. The diameter was 2.6 ± 0.7 between nasion and bregma, whereas the diameter was 5.7 ± 1.0 at lambda in this study. This confirms the findings of the various previous both cadaveric and radiological studies. The findings of the cadaveric studies by Reis et al,[3] Samadian et al[4] and Sayhan et al[5] were similar to this study in which the maximum diameter of the SSS was found to be at lambda and was approximately 7.9, 9.4, and 13.1 mm, respectively.[3–5] Similarly in a radiological study using magnetic resonance imaging (MRI) by Oberman et al, the maximum diameter was at the lambda that was approximately 8.5 mm.[2] However, another radiological study using MRI by Reis et al contrasted the findings of this study. In this study, the maximum diameter of the SSS was found to be between the bregma and lambda that was 12.4 mm.[3] In the same way, in contrast to this study there were two cadaveric studies. In the study by Tubbs et al, the maximum diameter of SSS was at the midpoint of the sagittal suture (9.4mm).[6] The second cadaveric study was by Thamke et al in which the maximum diameter of SSS was at the midpoint of SSS (1.3 mm).[7]

Deviation of SSS

The position of the SSS was assessed by taking the midline structure sagittal suture as the reference point. In this study, it was found that there was a deviation in the direction of the SSS from the midline. In all the taken five landmarks, it was found that the deviation of SSS was more toward the right

 © 2024. The Author(s).

side. It was around 77, 62, 68, 70, and 71% at nasion and bregma, at bregma, between bregma and lambda, at lambda, and beyond the level of lambda, respectively.

There were few radiological and cadaveric studies in the literature that confirms the findings of this study. In the cadaveric study by Reis et al, the deviation was almost equal on the right and the left side between nasion and bregma that was 12.5%. Further, at this point, there was no deviation in SSS for approximately 12.5%. The SSS was not found to be in the midline in all other landmarks.[3] But in our study the SSS was found to be in midline (no deviation) in all the five observed landmarks. Around 12% between bregma and lambda, 28% at bregma, 21% between bregma and lambda, 21% at lambda and 18% beyond lambda was found in midline without any deviation. This is confirmed by various other cadaveric studies by Samadian et al, Tubbs et al, where there was no deviation of SSS from the midline. In all these taken cadaveric studies, the deviation was more toward the right side like our study.[4,6]

In the radiological study by Reis et al using MRI, the deviation was more toward the right side in all the landmarks confirming the findings of this study. But there was one exception in this study wherein the segment between nasion and bregma the deviation of SSS was found to be more toward the left side (47.6%) than the right side (42.8%) that was found to be in contrast to the findings of this study.[3] In another radiological study by Oberman et al using MRI, the author has measured the distance of deviation of SSS from the midline. These distances from the midline were found to be increased toward the right side when compared with the left. In this study again the author has reported that none of the SSS was found in the midline; almost all had deviations that were again in contrast to the findings of this study.[2]

In a study by Reis et al using MRI, the mean deviation between nasion and bregma was 2.4 mm and at nasion it was 4.5 mm. Between bregma and lambda, it was 5.9 mm and at lambda it was 6 mm.[3] The deviation was found to be increasing as the SSS was coursing posteriorly toward the lambda. In the similar way in a radiological study using MRI by Oberman et al, the mean deviation was found to be increasing from nasion to lambda. The mean deviation between nasion and bregma was 5.62 mm, at bregma it was 6.5 mm, between bregma and lambda it was 7.4 mm, and 8.5 mm at lambda.[2] These findings were consistent with this study where the deviation toward right between nasion and bregma was 3 mm at nasion it was 4 mm. Between bregma and lambda, it was 3.5 mm and at lambda it was 5mm and beyond lambda it was 5.8 mm. The mean deviation to the left side were 1.5 mm between nasion and bregma, 1.8 mm at bregma, 2 mm between bregma and lambda, 3 mm at lambda, and 3.2 mm beyond lambda.

Another study by Samadian et al also confirmed the findings of this study where the mean deviation toward right at bregma was 3.5 mm, at midpoint of sagittal suture it was 4.5 mm, and at lambda it was 5.7 mm. The mean left deviations were 2.5 mm at bregma, 2 mm at midpoint of sagittal suture, and 2.5 mm at lambda.[4]

Table 2 Variations in diameters of SSS between age groups

Diameter	SSS—between nasion and bregma					SSS—bregma					SSS—between bregma and lambda					SSS—lambda				
	Age ≤ 20	Age 21–30	Age 31–40	Age 41–50	Age 51–60	Age ≤ 20	Age 21–30	Age 31–40	Age 41–50	Age 51–60	Age ≤ 20	Age 21–30	Age 31–40	Age 41–50	Age 51–60	Age ≤ 20	Age 21–30	Age 31–40	Age 41–50	Age 51–60
Mean (mm)	2.84	2.5	2.6	2.6	2.4	4.05	3.5	4	3.7	3.1	5.6	5.2	5.04	4.7	4.7	5.9	5.6	5.7	5.7	5.7
SD	0.9	0.7	0.7	0.6	0.6	1.2	0.8	0.9	0.9	0.2	1.6	1.1	1.3	1.1	1.3	1.01	1.1	0.9	1.1	0.2
Maximum (mm)	3.8	4.3	4.3	3.9	3.2	6.3	5.2	6.1	5.3	3.4	8	8	8.2	6.3	6.2	7	7.6	7.4	8	5.9
Minimum (mm)	1.2	1.2	1.3	1.5	1.9	2.7	1.8	2.5	1.7	3	3.5	2.2	2.8	3.2	3.8	4.5	2	3.7	1.7	5.5
p-Value	0.927					0.105					0.481					0.953				

Abbreviations: ANOVA, analysis of variance; SD, standard deviation; SSS, superior sagittal sinus.
One way ANOVA was done to determine the difference between the age groups. Post-hoc Tukey test was done to compare between each age groups. $p < 0.05$ was considered statistically significant.

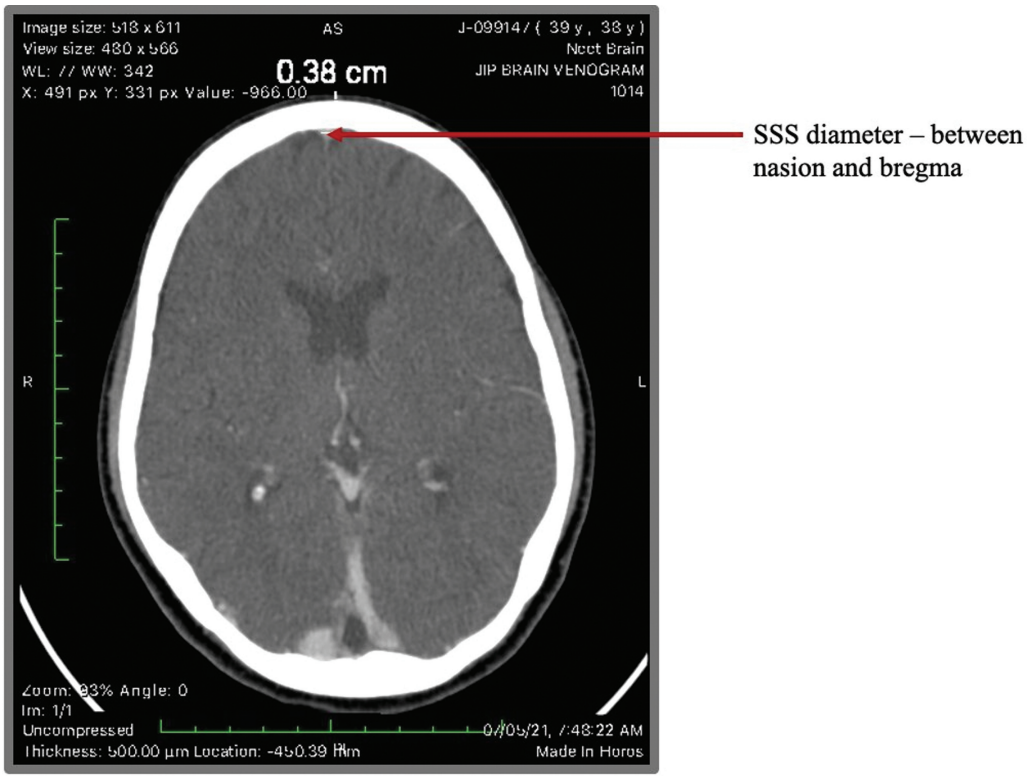

Fig. 1 Diameter of superior sagittal sinus (SSS) between nasion and bregma. Red line—Diameter of SSS between nasion and bregma.

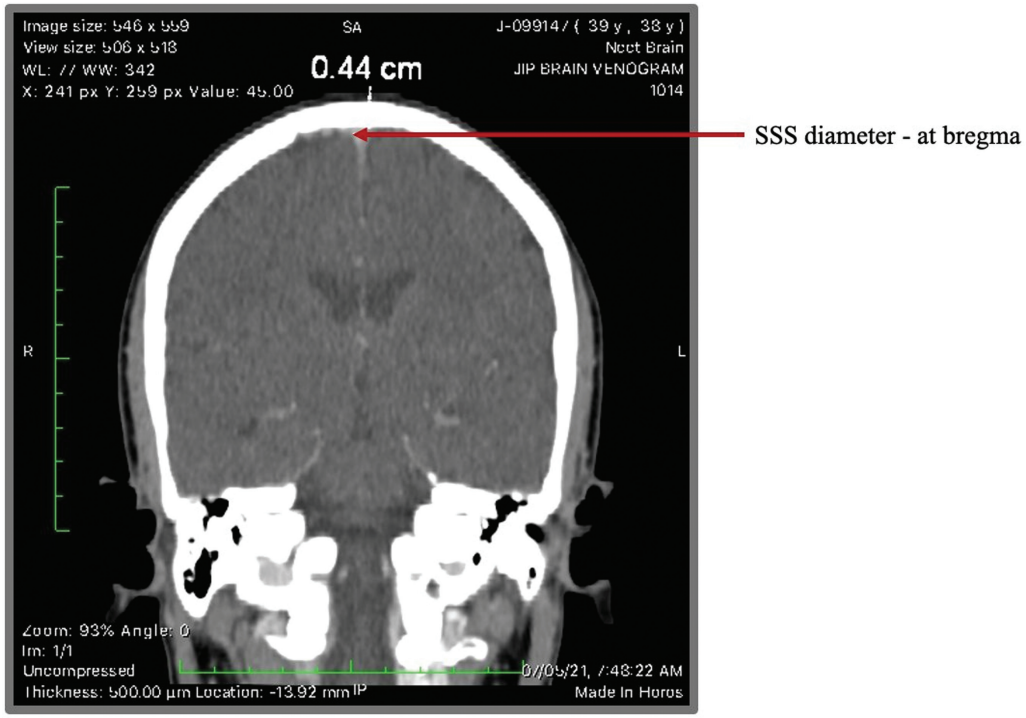

Fig. 2 Diameter of superior sagittal sinus (SSS) at nasion. Red line—Diameter of SSS at nasion.

Thus, these findings prove that the SSS does not lie exactly in the midline. The developmental basis for the displacement of SSS is that initially the sinus develops as sagittal plexus; along with these plexuses there appears lot of intercommunicating channels. These intercommunicating channels, enlarges, or diminishes in size that lead to asymmetry in developing SSS. This asymmetry of the sinus leads to the drainage of the sinus toward one side, mostly to the right side, thus, leading to the displacement of the SSS most commonly toward the right side.[4,6]

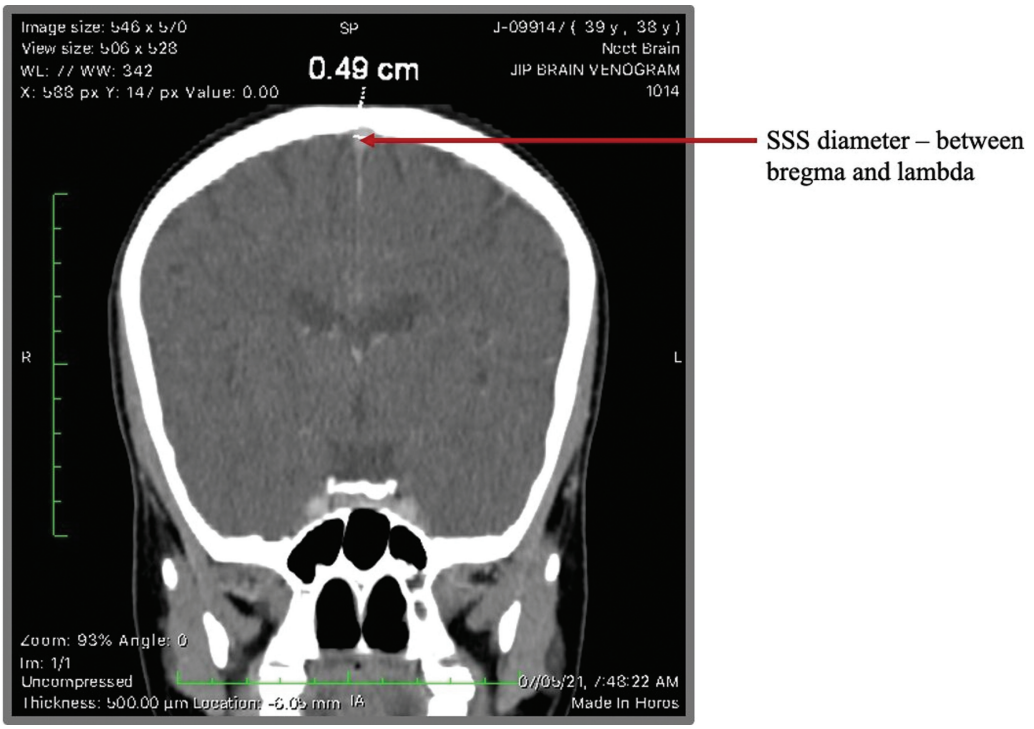

Fig. 3 Diameter of superior sagittal sinus (SSS) between bregma and lambda. Red line—Diameter of SSS between bregma and lambda.

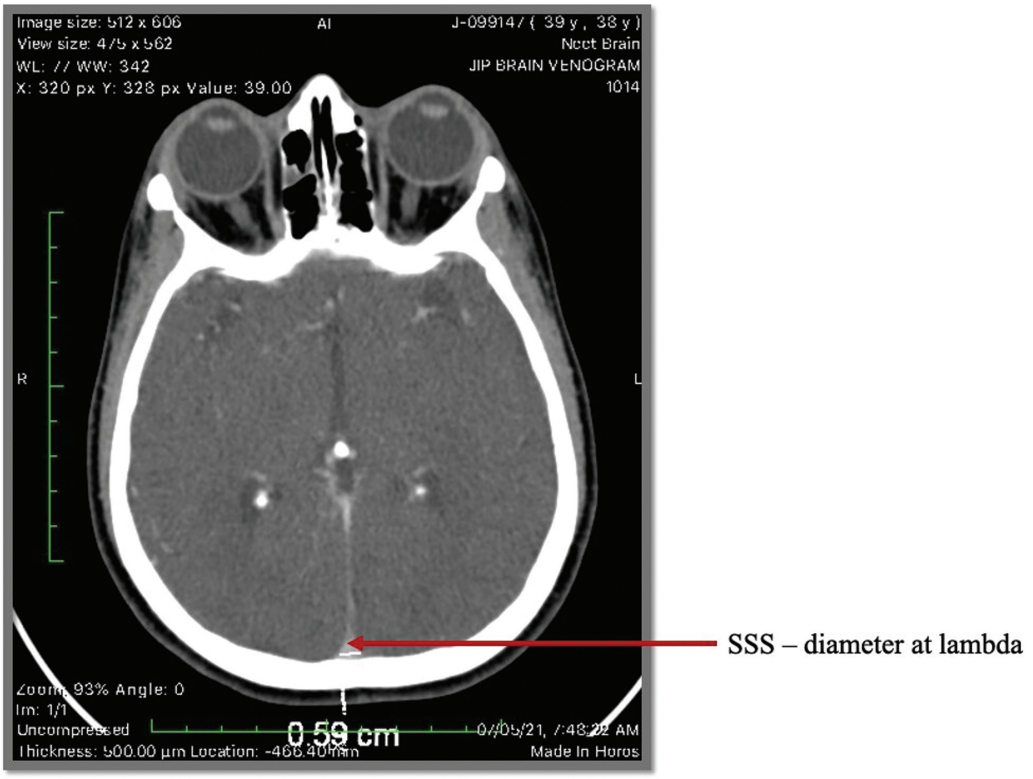

Fig. 4 Diameter of superior sagittal sinus (SSS) between at lambda. Red line—Diameter of SSS at lambda.

Surgical Recommendations Based on This Study

➢ Craniotomies should be approached carefully in relation to SSS. Usually, sagittal suture is taken as the landmark for SSS. But our study proves that the SSS does not lie exactly in the midline in relation to sagittal suture but deviation is there, usually toward right side. Further in our study, we did not observe any changes in deviation with respect to age groups. Irrespective of age the SSS was

Table 3 Overall frequency of deviation of SSS

Landmarks	Deviation		
	Right	Left	No
SSS—between nasion and bregma (%)	77	11	12
SSS—bregma (%)	62	10	28
SSS—between bregma and lambda (%)	68	11	21
SSS—Lambda (%)	70	9	21
SSS—beyond lambda (%)	71	11	18

Abbreviation: SSS, superior sagittal sinus.

Table 4 Comparison of frequency of deviation of SSS between gender

Landmarks	Deviation						*p*-Value
	Male ($n = 37$)			Female ($n = 63$)			
	Right	Left	No	Right	Left	No	
SSS—between nasion and bregma (%)	27	2	8	50	9	4	0.04[a]
SSS—bregma (%)	2	22	13	40	8	15	0.3
SSS—between bregma and lambda (%)	24	3	10	44	8	11	0.4
SSS—lambda (%)	30	1	6	40	8	15	0.119
SSS—beyond lambda (%)	26	5	6	45	6	12	0.8

Abbreviation: SSS, superior sagittal sinus.
[a]*p*-Value—significant.
Chi square test was used to compare the frequency of deviation of SSS between gender.

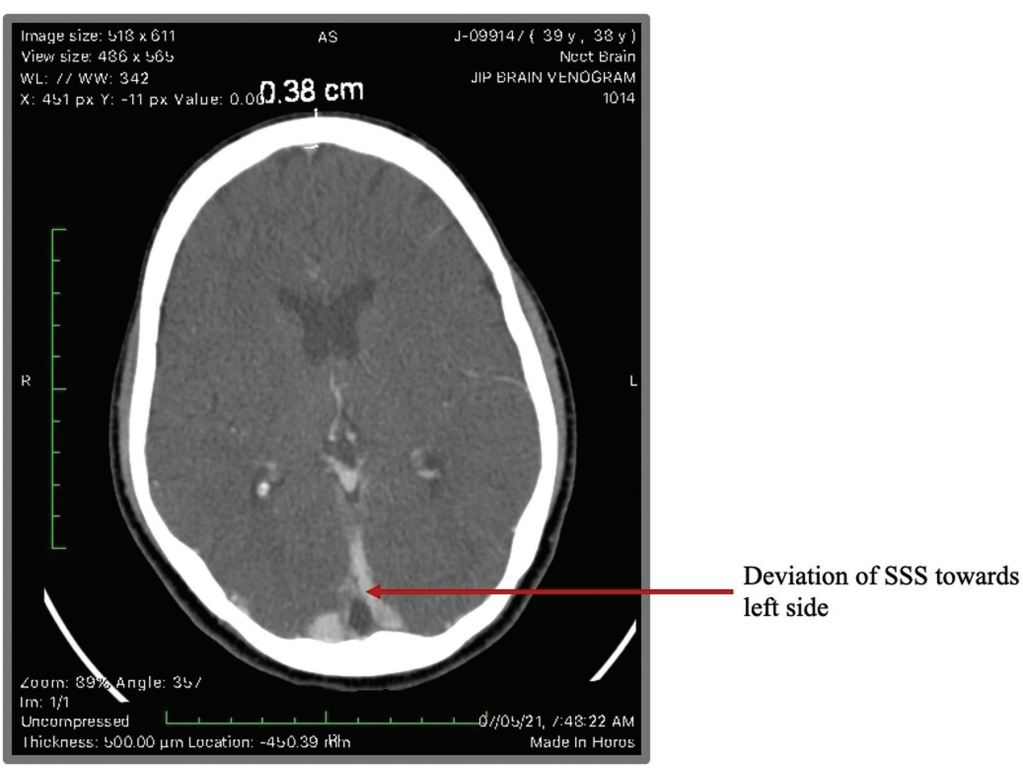

Fig. 5 Deviation of superior sagittal sinus (SSS). Red line—Deviation of SSS toward left.

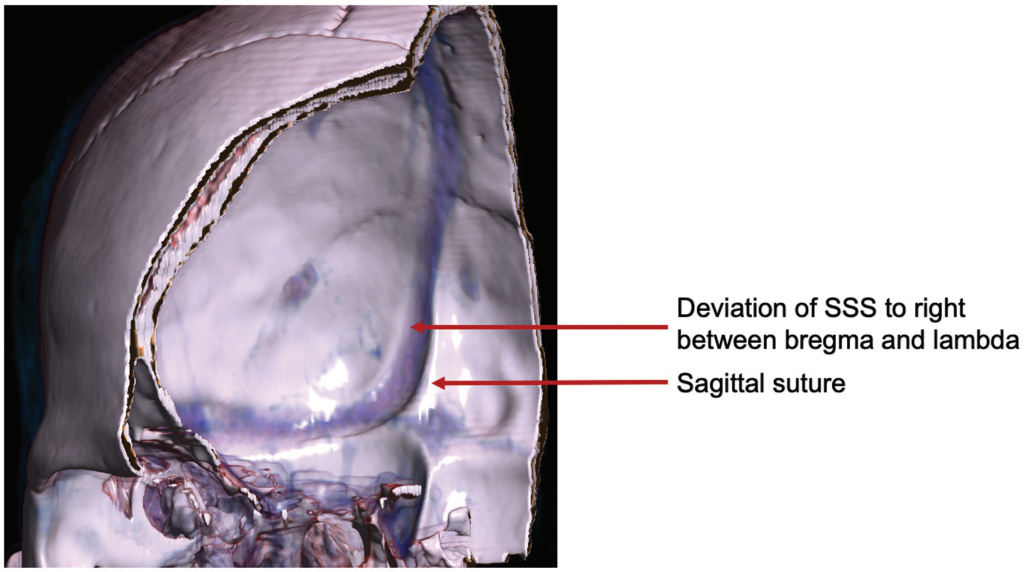

Fig. 6 Three-dimensional image showing the deviation of superior sagittal sinus (SSS) from sagittal suture at the site between bregma and lambda. Red line—Deviation of SSS toward right between bregma and lambda.

deviated more toward the right side at lambda. The Gigli saw or high-speed drill may lacerate the wall of the sinus if the drill is placed within 1cm of sagittal suture. For example, in the case of unilateral frontal craniotomy, the medial margin of craniotomy lies close to the midline. In this craniotomy, anterior one-third of the SSS is exposed between the nasion and bregma. If there is any injury to SSS, it can be ligated if it is near nasion while ligation is not recommended beyond bregma as it may lead to infarction.[3] The middle one-third of the SSS is exposed in case of anterior transcallosal approach, which lies between nasion and bregma and at bregma. Even in this point the SSS does not lie exactly on the midline. Ascertaining the position of sinus through MRI before neurosurgical interventions are recommended. In a safer side, it is suggested to place the burr holes few millimeters away from the midline either on the same or the opposite side of the craniotomy based on the surgeons perspective.[3] In the similar way, when the posterior one-third of the SSS is exposed between bregma and lambda, and at lambda point for procedures like posterior transcallosal approaches, it is safer to place the burr holes few millimeters away from the midline.[3] Oberman et al after measuring the deviation distance of SSS from midline recommended to place the drill or burr holes at a distance of at least 1.7 cm from the midline.[2]

➢ In case of midline tumors and vascular lesions around third ventricle interhemispheric approach is used.[2] Parafalcine and parasagittal meningiomas are the second most common intracranial meningiomas.[8] Since these tumors are in an intimate relationship with major sinuses and draining veins, their resection requires careful preservation of cortical veins that surround the tumor. The parasagittal meningiomas involving the posterior two-thirds of the SSS pose a major challenge to the neurosurgeon to remove the tumor completely without significant morbidity. However, gross total resection of the tumor is preferred, provided the cortical veins responsible for the collateral drainage are preserved.[7–10]

Conclusion

Thus, the findings of this study prove that the SSS does not lie in the midline along the sagittal suture. So, the sagittal suture cannot be taken as a reliable landmark to locate the SSS. The sinus deviates more toward the right side. Further, the diameter of the SSS was also estimated. With the advancement in radiological techniques, the diameter and displacement of the SSS can be easily observed with the help of CTV. These findings would help the neurosurgeons in various neurosurgical procedures in the midline along the sagittal suture.

Limitations

We did not compare the parameters in the cadavers due to the feasibility and complexity in the procedure which involves injection of dyes and evaluating the venous sinuses. The postmortem clots in the cadavers would hinder the passage of dye posing difficulty in evaluation.

Authors' Contribution

R.V. and D.K.V. conceptualized the study. G.S.S., A.K., and N.K. helped in data acquisition. G.S.S. was involved in data analysis and interpretation. G.S.S., R.V., and D.K.V. drafted the manuscript. G.S.S., R.V., D.K.V., and N.K. critically revised the manuscript. All authors provided approval for this study.

Conflict of Interest

None declared.

Acknowledgment

The authors would like to acknowledge the technicians of PACS from department of radiology, JIPMER

References

1 Gleeson M. Head and neck. In: Gray's Anatomy - The Anatomic Basis of Clinical Practice, Standring S, ed. 41st ed. New York: Elsevier Limited; 2016:434–435

2 Oberman DZ, Rabelo NN, Correa JLA, Ajler P. Relationship of superior sagittal sinus with sagittal midline: a surgical application. Surg Neurol Int 2020;11:309

3 Reis CV, Gusmao SN, Elhadi AM, et al. Midline as a landmark for the position of the superior sagittal sinus on the cranial vault: an anatomical and imaging study. Surg Neurol Int 2015;•••:6

4 Samadian M, Nazparvar B, Haddadian K, Rezaei O, Khormaee F. The anatomical relation between the superior sagittal sinus and the sagittal suture with surgical considerations. Clin Neurol Neurosurg 2011;113(02):89–91

5 Sayhan S, Guvencer M, Ozer E, Arda MN. Morphometric evaluation of parasagittal venous anatomy for intracranial approaches: a cadaveric study. Turk Neurosurg 2012;22(05):540–546

6 Tubbs RS, Salter G, Elton S, Grabb PA, Oakes WJ. Sagittal suture as an external landmark for the superior sagittal sinus. J Neurosurg 2001;94(06):985–987

7 Thamke S, Kalra S, Khandelwal A. Morphometric evaluation of dural venous sinuses: anatomical study with its implications in surgical interventions. J Morphol Sci 2016;33(02):83–89

8 Eichberg DG, Casabella AM, Menaker SA, Shah AH, Komotar RJ. Parasagittal and parafalcine meningiomas: integral strategy for optimizing safety and retrospective review of a single surgeon series. Br J Neurosurg 2020;34(05):559–564

9 DiMeco F, Li KW, Casali C, et al. Meningiomas invading the superior sagittal sinus: surgical experience in 108 cases. Neurosurgery 2004;55(06):1263–1272, discussion 1272–1274

10 Ricci A, Di Vitantonio H, De Paulis D, et al. Parasagittal meningiomas: our surgical experience and the reconstruction technique of the superior sagittal sinus. Surg Neurol Int 2017;8:1

 © 2024. The Author(s).