

# DACA Aneurysm Presenting as Ischemic Stroke

Shah Pratik<sup>1</sup> Gordhan Sangani<sup>1</sup> Manish Shrivastava<sup>1</sup> Tushar Raut<sup>2</sup> Krishna Mundada<sup>3</sup> 

<sup>1</sup>Department of Interventional Radiology, Kokilaben Dhirubhai Ambani Hospital and Medical Research Institute, Mumbai, Maharashtra, India

<sup>2</sup>Department of Neurology Kokilaben Dhirubhai Ambani Hospital and Medical Research Institute, Mumbai, Maharashtra, India

<sup>3</sup>Department of Radiology Kokilaben Dhirubhai Ambani Hospital and Medical Research Institute, Mumbai, Maharashtra, India

Address for correspondence Shah Pratik, DNB Radiology, FNVIR, Department of Interventional Radiology, Kokilaben Dhirubhai Ambani Hospital and Research Institute, Mumbai 400058, Maharashtra, India (e-mail: shahpratik74@gmail.com).

J Clin Interv Radiol ISVIR 2024;8:60–64.

## Abstract

### Keywords

- ▶ DACA
- ▶ aneurysm
- ▶ stroke
- ▶ thrombectomy

Aneurysms rarely present with features of ischemic stroke. The data on treatment of such strokes is limited. We present a case of multiple aneurysms and an ischemic stroke caused by distal anterior cerebral artery (DACA) aneurysm treated with flow diverter placement, the first case of endovascular treatment of DACA aneurysmal ischemic stroke reported to our knowledge.

## Introduction

An 80-year-old female, with chronic hypertension, compliant to medications, came with left hemiparesis in the hospital casualty. Her vitals were found to be within the normal range. After thorough examination of the patient, National Institute of Health Stroke Scale (NIHSS) score was found to be 9 and an emergency magnetic resonance imaging (MRI) was performed that revealed hyper acute subcortical infarct at right parasagittal high frontal region of anterior cerebral artery (ACA) territory (▶**Fig. 1A**). The patient was out of window for thrombolysis, and clinical–diffusion mismatch and diffusion–perfusion mismatch were seen. Digital subtraction angiography/cerebral angiogram was performed that showed distal ACA (DACA) thrombosis (▶**Fig. 1B**). Mechanical thrombectomy was performed with Trevo 4 × 30 mm for DACA thrombosis. However, a small DACA aneurysm (1.7 × 2 mm) was noted at the site of thrombosis post-thrombectomy (▶**Fig. 2**). On exploration, another small aneurysm at proximal pericallosal ACA segment and a left posterior inferior cerebellar artery (PICA) aneurysm were noted (▶**Fig. 3**). Twenty-four hours follow-up MRI with

perfusion imaging showed reversal of hypoperfusion in the right parasagittal high frontal cortex (▶**Fig. 4**). We decided to treat the patient with placement of flow diverter stents in ACA and WEB in the aneurysm sac at left PICA (▶**Fig. 5A and B**).

A neuron max was placed into the right internal carotid artery (ICA) through which a 6F neuron guiding catheter was introduced in the distal cervical ICA. A headway 21 microcatheter navigated over hybrid microwire into right A3 segment across distal pericallosal aneurysm. This was followed by deployment of Flow Redirectional Endoluminal Device (FRED) JR 2.5 × 13 × 8 mm across the neck of aneurysm and another FRED JR 3 × 13 × 9 mm across proximal pericallosal artery aneurysm.

The final ICA angiogram post-procedure showed good blood flow across the diverter stents and stasis in both aneurysms.

At the same setting, a neuron max was placed into the left subclavian artery, and a 6F neuron guiding was navigated into distal V2 segment of left vertebral artery. VIA 17 microcatheter was navigated over hybrid microwire into

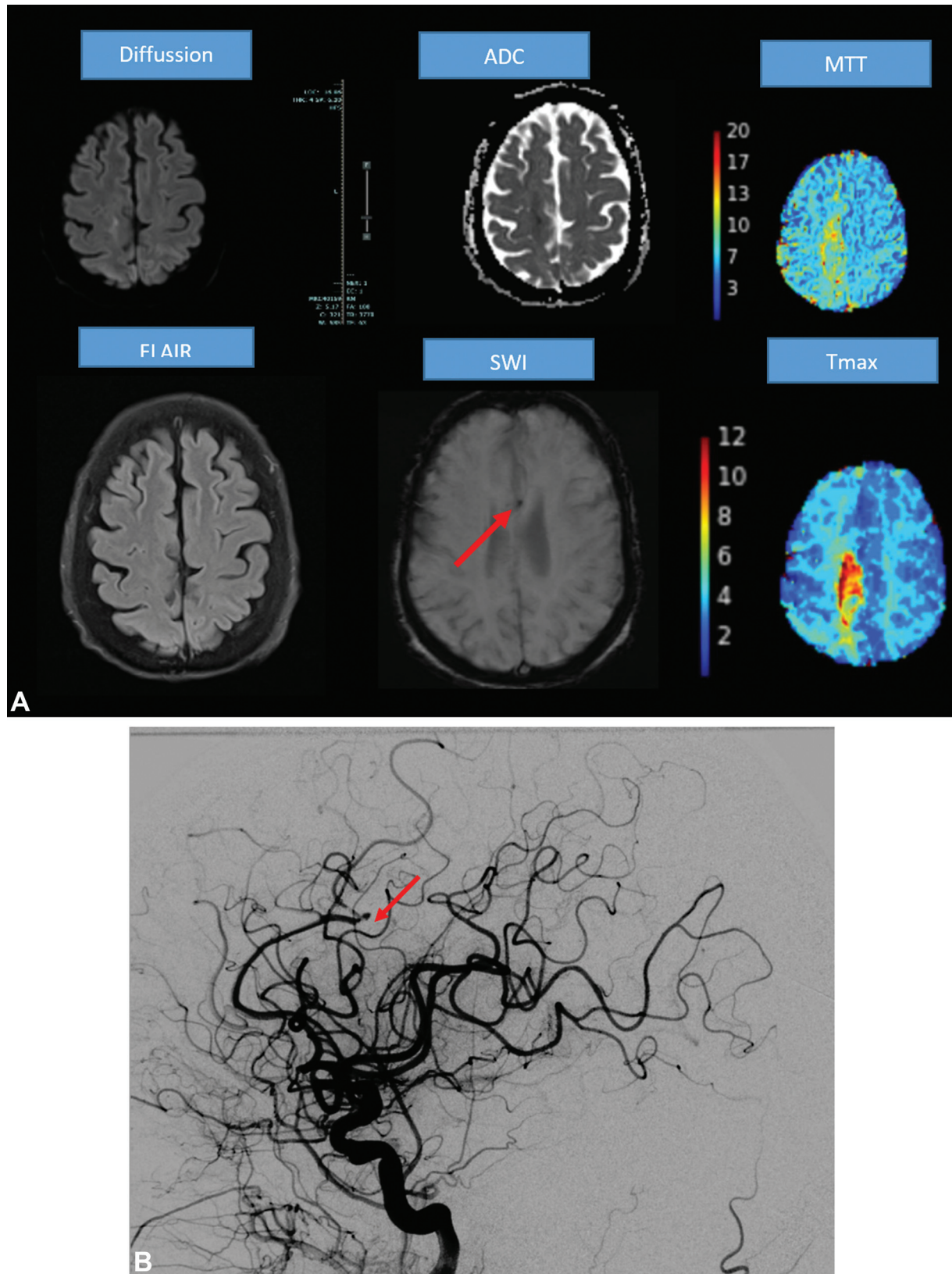
article published online  
January 5, 2024

DOI <https://doi.org/10.1055/s-0043-1777122>.  
ISSN 2457-0214.

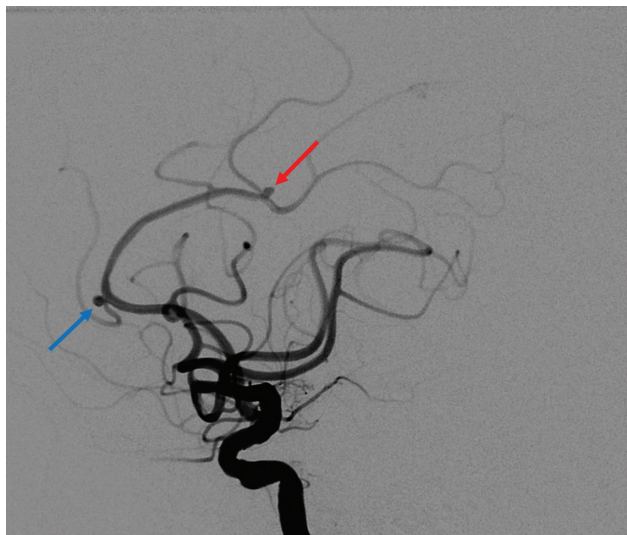
© 2024. Indian Society of Vascular and Interventional Radiology. All rights reserved.

This is an open access article published by Thieme under the terms of the Creative Commons Attribution-NonDerivative-NonCommercial-License, permitting copying and reproduction so long as the original work is given appropriate credit. Contents may not be used for commercial purposes, or adapted, remixed, transformed or built upon. (<https://creativecommons.org/licenses/by-nc-nd/4.0/>)

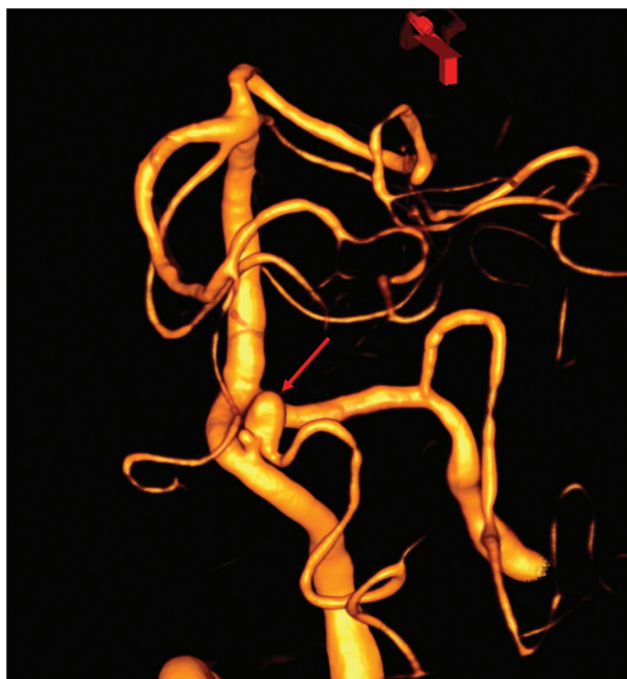Thieme Medical and Scientific Publishers Pvt. Ltd., A-12, 2nd Floor, Sector 2, Noida-201301 UP, India



**Fig. 1** Anterior cerebral artery (ACA) aneurysm thrombotic stroke. (A) Magnetic resonance imaging of brain showing hyperacute subcortical infarct at right parasagittal high frontal region of ACA territory with hypoperfused area on perfusion images adjacent to it. On susceptibility-weighted imaging (SWI), arrow points toward distal ACA thrombus. (B) Lateral right internal carotid artery angiogram showing thrombotic occlusion of right distal ACA (A3 segment)/pericallosal artery (red arrow). ADC, apparent diffusion coefficient; FLAIR, fluid-attenuated inversion recovery; MTT, mean transit time.

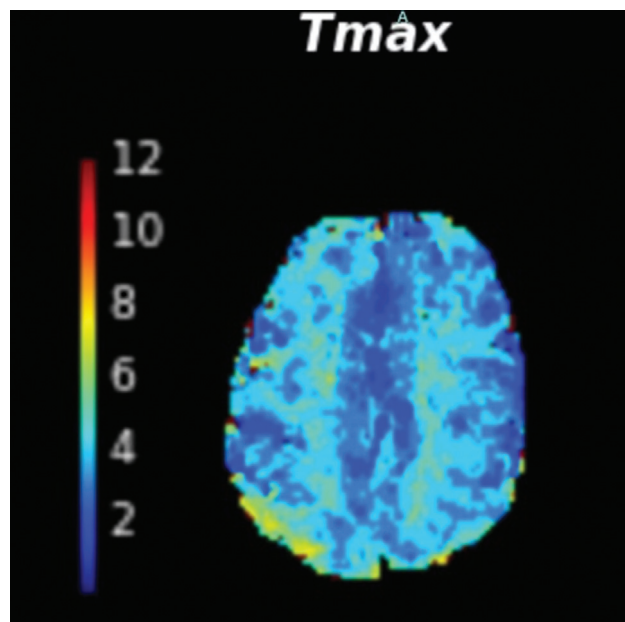


**Fig. 2** Post-mechanical thrombectomy, saccular wide neck aneurysm is seen at the bifurcation exactly at the location of thrombotic occlusion of distal A3/pericallosal artery (red arrow) with mTICI III recanalization and another small saccular aneurysm is also seen at the bifurcation at proximal pericallosal artery (blue arrow).



**Fig. 3** Three-dimensional rotational angiogram showing left posterior inferior cerebellar artery aneurysm with small daughter sac adjacent to it.

the left PICA aneurysm that was followed by deployment of WEB SL 5 × 3 mm into aneurysm sac and a post-procedural angiogram showed a well-positioned web with significant intra-aneurysmal stasis and good flow into distal PICA. The position was confirmed and no bleeding was noted in Dyna computed tomography performed post-procedure. The patient was discharged with no post-procedure complications.



**Fig. 4** Magnetic resonance imaging perfusion done after 24 hours showed reversal of hypoperfusion in the right parasagittal high frontal cortex.

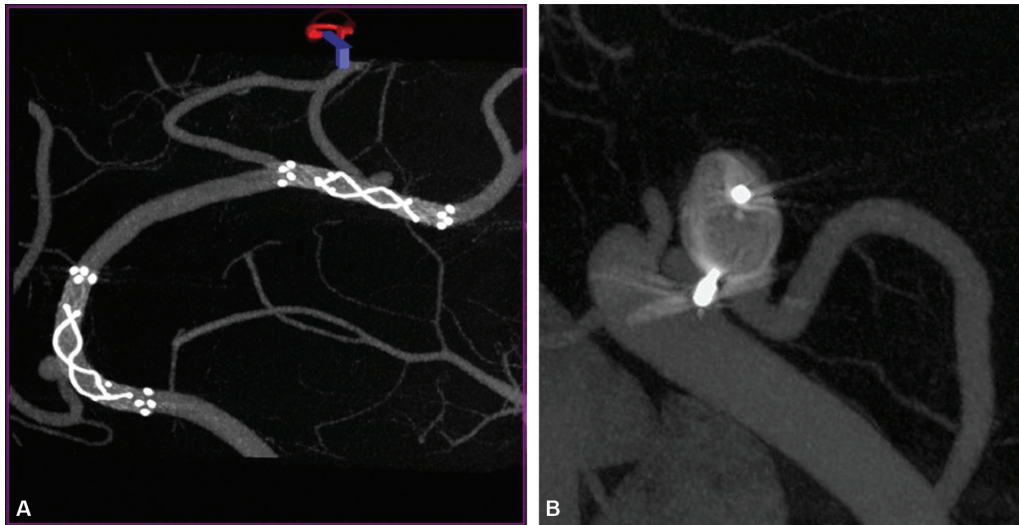
#### Follow-Up

On one year follow up patient had complete recovery and exclusion of all three aneurysms with no residual paresis. (→ Fig. 6A and B).

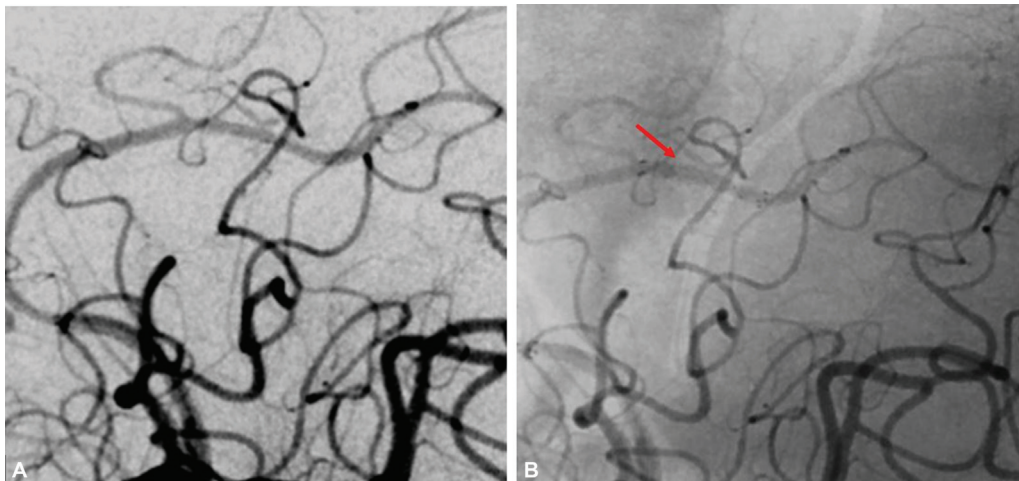
#### Discussion

An aneurysm is a ballooning arising from a weakened blood vessel wall. Saccular or berry aneurysms represent 90% of all the cerebral aneurysms, while there are various genetic factors such as connective tissue disorders, polycystic kidney disease, and arteriovenous malformations that can cause such aneurysms; however, arterial aneurysms in cerebral circulation are common in patients with chronic hypertension.<sup>1,2</sup> While cerebral aneurysms are likely to be seen in ACA/ACoA complex, supraclinoid ICA and ICA PcomA junction at the level of M1 and M2 bifurcation of middle cerebral artery in anterior circulation and basilar tip, superior cerebellar artery, or PICA of posterior circulation, aneurysms in DACA are uncommon and represent only 6% of intracerebral aneurysm.<sup>3</sup> Most of these patients remain asymptomatic, while those who remain symptomatic usually come with intracranial subarachnoid hemorrhage; thrombosis is usually seen in cases of larger aneurysms or in small arteries in the pediatric population.<sup>4</sup> However, our case presented with a thrombus lodging within a DACA aneurysm causing hemiparesis.

A study by de Sousa et al states that DACA aneurysms are associated with aneurysms in other locations, which were also seen in the patient, as another proximal aneurysm in ACA and one of relatively larger size in PICA were noted in our case.<sup>5</sup> Prompt treatment of aneurysm is necessary as rupture may lead to life-threatening intracranial bleeding and increased risk of morbidities.<sup>6,7</sup> Depending on the size of aneurysms, they are treated with either surgical measures that involve



**Fig. 5** (A) Dyna computed tomographic images showing flow diverter placement across both the distal anterior cerebral artery aneurysms. (B) WEB device within left posterior inferior cerebellar artery aneurysm.



**Fig. 6** (A) 1.5-year follow-up digital subtraction angiography image showing complete exclusion of distal anterior cerebral artery aneurysm. (B) Unsubtracted image showing corresponding location of previously placed flow diverter (red arrow).

clipping or endovascular procedures involving placement of coils, flow diverters, and WEB placement.<sup>8</sup> Symptomatic aneurysms, whether thrombotic or hemorrhagic, should be treated with surgical or endovascular approach irrespective of their size; in our case since the cause of stroke was the aneurysm, we decided to treat the aneurysm directly.<sup>9</sup> With advent of highly effective medical devices such as flow diverters and given an ideally skilled hands treating the patient, we advise active intervention in such cases. Endovascular approach to treatment of aneurysms has shown better prognosis in patients. Data portrays the use of flow diverters and WEBs as effective and safer treatment for small and wide neck aneurysms, respectively,<sup>10,11</sup> hence these two devices were used for the treatment of the patient. Similarly, in all cases of thrombotic occlusion at our institution, a blunt ended Jtip/loop of the wire is used to cross the occluded segment to prevent perforation of the vessel wall.

On literature search, very limited data are available on treatment of thrombotic DACA aneurysms. This is the first case we have discovered where one of the DACA aneurysms camouflaged as a thrombotic stroke that was treated with endovascular approach. It is thus important to also consider DACA aneurysmal thrombosis as a differential while assessing any patient with chronic hypertension and other comorbidities presenting with ACA stroke.

**Conflict of Interest**  
None declared.

#### References

- 1 Taylor CL, Yuan Z, Selman WR, Ratcheson RA, Rimm AA. Cerebral arterial aneurysm formation and rupture in 20,767 elderly patients: hypertension and other risk factors. *J Neurosurg* 1995; 83(05):812-819

- 2 Koutsathanasis GA, Sampath R. Berry Aneurysm. [Updated 2020 Oct 2]. In: StatPearls [Internet]. Treasure Island (FL): StatPearls Publishing; 2021 Jan-. Accessed October 31, 2023 at: <https://www.ncbi.nlm.nih.gov/books/NBK557480/>
- 3 Lehecka M, Dashti R, Lehto H, Kivisaari R, Niemelä M, Hernesniemi J. Distal anterior cerebral artery aneurysms. *Acta Neurochir Suppl (Wien)* 2010;107:15–26
- 4 Whittle IR, Dorsch NW, Besser M. Spontaneous thrombosis in giant intracranial aneurysms. *J Neurol Neurosurg Psychiatry* 1982;45(11):1040–1047
- 5 Ropper AH, Zervas NT. Outcome 1 year after SAH from cerebral aneurysm. Management morbidity, mortality, and functional status in 112 consecutive good-risk patients. *J Neurosurg* 1984;60(05):909–915 <https://thejns.org/view/journals/j-neurosurg/60/5/article-p909.xml>
- 6 de Sousa AA, Dantas FL, de Cardoso GT, Costa BS. Distal anterior cerebral artery aneurysms. *Surg Neurol* 1999;52(02):128–135, discussion 135–136
- 7 Hijdra A, Braakman R, van Gijn J, Vermeulen M, van Crevel H. Aneurysmal subarachnoid hemorrhage. Complications and outcome in a hospital population. *Stroke* 1987;18(06):1061–1067
- 8 Zhao J, Lin H, Summers R, Yang M, Cousins BG, Tsui J. Current treatment strategies for intracranial aneurysms: an overview. *Angiology* 2018;69(01):17–30
- 9 Lantigua H, Ortega-Gutierrez S, Schmidt JM, et al. Subarachnoid hemorrhage: who dies, and why? *Crit Care* 2015;19(01):309. Doi: 10.1186/s13054-015-1036-0
- 10 Fiorella D, Gache L, Frame D, Arthur AS. How safe and effective are flow diverters for the treatment of unruptured small/medium intracranial aneurysms of the internal carotid artery? Meta-analysis for evidence-based performance goals. *J Neurointerv Surg* 2020;12(09):869–873
- 11 Arthur AS, Molyneux A, Coon AL, et al; WEB-IT Study investigators. The safety and effectiveness of the Woven EndoBridge (WEB) system for the treatment of wide-necked bifurcation aneurysms: final 12-month results of the pivotal WEB Intrasaccular Therapy (WEB-IT) Study. *J Neurointerv Surg* 2019;11(09):924–930