

# Common Pediatric Hand Anomalies

Jacob H. McCarter, BA<sup>1,2</sup> Ricardo A. Zeledon, BS<sup>1,2</sup> Samuel H. Cole, MD<sup>1,2</sup> Sarah A. Layon, BS<sup>1,2</sup>  
Jenny Lee Nguyen, MD<sup>1,2</sup>

<sup>1</sup>Division of Plastic Surgery, Michael E. DeBakey Department of Surgery, Baylor College of Medicine, Houston, Texas

<sup>2</sup>Division of Plastic Surgery, Texas Children's Hospital, Houston, Texas

Address for correspondence Jenny Lee Nguyen, MD, Division of Plastic and Reconstructive Surgery, Baylor College of Medicine, 1 Baylor Plaza, Houston, TX 77030 (e-mail: JennyLee.Nguyen@bcm.edu).

Semin Plast Surg 2023;37:275–286.

## Abstract

### Keywords

- ▶ upper extremity
- ▶ congenital hand
- ▶ thumb hypoplasia
- ▶ syndactyly
- ▶ trigger thumb
- ▶ amniotic band syndrome
- ▶ polydactyly

Upper extremity congenital anomalies in the newborn are second only to congenital heart anomalies. Some of the more commonly encountered upper extremity anomalies are trigger thumb, thumb hypoplasia, polydactyly, syndactyly, and amniotic band syndrome. While some conditions occur in isolation, others are known to commonly occur in association with syndromes. Familiarity with these conditions is important not only to provide adequate evaluation and workup of these patients but also to deliver appropriate surgical intervention and prepare parents with appropriate expectations. In this article, we outline the etiology, classification, surgical management, and outcomes of these five commonly encountered upper extremity congenital anomalies.

One to three percent of newborns are born with congenital anomalies, approximately 10% of these anomalies affect the upper extremity.<sup>1,2</sup> Upper extremity congenital anomalies occur in 27 per 10,000 live births<sup>3</sup> and are second in incidence only to those of congenital heart disease.<sup>4</sup> Most defects are either inherited or occur spontaneously.<sup>5</sup> The plastic surgeon may either be the first to notice more subtle anomalies or be referred to for definitive treatment. It is important to be aware of the spectrum of presentation, associated medical comorbidities, and potential complications to effectively treat the patient and educate parents. We will review the more common congenital hand anomalies seen, including trigger thumb, hypoplastic thumb, polydactyly (pre- and post-), syndactyly, and amniotic band syndrome.

## Pediatric Trigger Thumb

Often called congenital trigger thumb, no study of newborn infants has identified this condition at birth.<sup>6–8</sup> It is an acquired flexion deformity of the thumb interphalangeal (IP) joint with a palpable thickening of the flexor pollicis

longus (FPL) tendon noted at the base of the thumb. Rarely, the IP joint can get caught in extension.<sup>9</sup> It is reported to occur in 1 in 2,000 office visits or 3.3 cases per 1,000 live births by 1 year of age.<sup>7,10</sup>

The cause of pediatric trigger thumb is unknown, although theories vary from posttraumatic changes from repeated injury to the flexor tendon to a congenital predisposition of narrowing of the pulley.<sup>11,12</sup> Traditionally, trigger thumb is attributed to an incongruence in size between the FPL tendon and the A1 pulley, but when reviewing 28 patients, Kuo and Rayan noted a majority of patients had stenosis of the oblique pulley in association with an attenuated A1 pulley.<sup>13</sup> While ultrasound has identified a larger-than-normal size of FPL compared with the contralateral uninvolved FPL tendon, both ultrasound and electron microscopy of the flexor tendon have not demonstrated inflammatory or degenerative changes of the tendon.<sup>14–16</sup>

The most common classification system used is that of Sugimoto, in which stages range from a palpable Notta's nodule without triggering of the thumb to a locked IP joint without active or passive extension (▶ **Table 1**).<sup>17</sup>

**Table 1** Sugimoto classification for pediatric trigger thumb

Stage I	No passive or active triggering of thumb IP joint; palpable Notta's nodule
Stage II	Triggering with active extension of thumb IP joint
Stage III	No active extension of thumb IP joint but is passively extendable with triggering
Stage IV	No active or passive extension of thumb IP joint

Abbreviation: IP, interphalangeal.  
Source: Nguyen and Ho.<sup>26</sup>

Pediatric trigger thumb is diagnosed based on physical exam with no need for imaging. The volar base of the thumb should be palpated for fullness of the flexor tendon, termed Notta's nodule, which can be tender or nontender (►Fig. 1). Both passive and active range of motion of the thumb IP joint should be documented. The metacarpophalangeal (MCP) joint should be evaluated for hyperextension as this can be a consequence of long-standing trigger thumb and may need to be surgically addressed at the time of trigger release.<sup>13</sup> The contralateral, uninvolved thumb should be examined as up to 25 to 34% of patients will develop bilateral trigger thumb.<sup>18,19</sup> The thumb deformity should be differentiated from the slightly similar but different presentation of congenital clasped thumb.

Treatment of pediatric trigger thumb is controversial, ranging from observation, splinting and stretching, to surgical release of the A1 pulley. An observational study from Baek and Lee showed that 75.9% of thumbs spontaneously resolved at a median duration of 49 months of follow-up, with only duration of follow-up significantly different between patients with and without spontaneous resolution.<sup>20</sup> In contrast, a review of the natural history of pediatric trigger thumb in the United States showed that within 5 years of initial visit, 32% of thumbs spontaneously resolved, 25% did not resolve, and 43% of parents opted for surgery.<sup>21</sup> They found 30 degrees or less of IP joint flexion to be associated with spontaneous resolution at 3-year follow-up. It has been suggested that Sugimoto stage I-III thumbs be initially

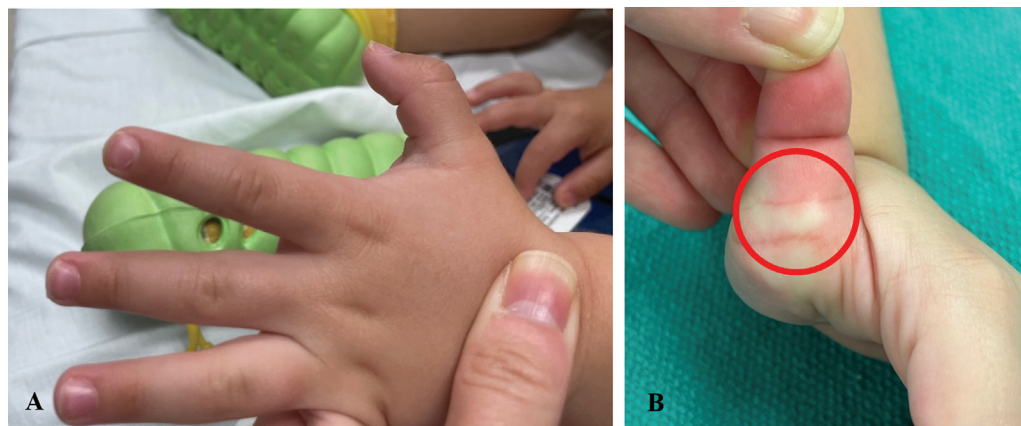
treated nonoperatively.<sup>22</sup> When polled, 52% of North American pediatric hand surgeons stated that they would operate on a 2-year-old patient presenting with a nonpainful intermittent locking trigger thumb.<sup>23</sup> Decision to operate should take into account the patient's age for anesthetic safety, the length of deformity, associated pain or effect on hand function, potential for bilateral thumb involvement, and parents' preferences.

Surgery for pediatric trigger thumb consists of an incision over the volar base of the thumb. The A1 pulley is opened longitudinally to allow unimpeded gliding of the FPL tendon throughout the entire range of motion of the thumb IP joint. The radial digital nerve to the thumb crosses the surgical field just proximal to the A1 pulley and must be protected to avoid inadvertent transection.

Surgical release of the pediatric trigger thumb is safe and effective. A literature review of surgery for pediatric trigger thumb found a 1% complication rate consisting of wound infections, either deep or minor.<sup>23</sup> A 20-year review of a single institution's surgeries identified a 1.9% rate of wound complications, either infection or dehiscence. They did note a 4.9% rate of residual stiffness or IP joint flexion contracture.<sup>24</sup>

## Hypoplastic Thumb

Thumb hypoplasia is part of radial longitudinal deficiency (RLD), in which the radial aspect of the upper extremity is malformed. One-third of patients with RLD will have a named syndrome, as it is commonly associated with other medical comorbidities.<sup>25</sup> It is important to screen these patients for associated syndromes, the most common being Fanconi anemia, thrombocytopenia absent radius syndrome, Holt-Oram syndrome, and vertebral anomalies, anal atresia, cardiac anomalies, tracheoesophageal fistula, renal defects, and limb anomalies association (►Table 2).<sup>26</sup> Initial workup should include spinal radiographs, echocardiogram, complete blood-cell count, abdominal ultrasound, and possibly chromosomal breakage test (i.e., diepoxybutane testing) to rule out Fanconi anemia.<sup>25,27</sup> Surgical reconstruction of the hypoplastic thumb should only be performed after obtaining appropriate medical clearance.



**Fig. 1** (A) Thumb IP joint cannot be actively extended past 40 degrees of flexion. (B) Prominence (encircled in red) at the base of the volar thumb consistent with Notta's nodule.

**Table 2** Syndromes and associations with radial longitudinal deficiency

Syndrome or Association	Characteristics		Inheritance
Holt-Oram	Congenital structural and/or electrical cardiac defects		Autosomal dominant
Fanconi anemia	Early onset aplastic anemia		Autosomal recessive
Thrombocytopenia absent radius	Thrombocytopenia that improves within first few years of life		Multifactorial inheritance including a 1q21.1 microdeletion
VACTERL	V A C TE R L	Vertebral anomalies Anal atresia Cardiac abnormalities Tracheoesophageal fistula Renal agenesis Limb defect	Sporadic

Source: Nguyen and Ho.<sup>26</sup>**Table 3** Modified Blauth classification of thumb hypoplasia

Type I	Smaller thumb with intrinsic and extrinsic musculature present
Type II	Narrowed first web space Absence of intrinsic thumb musculature UCL insufficiency
Type III	Type II with abnormal extrinsic musculature
Type IV	Floating thumb (pouce flottant)
Type V	Absent thumb

Source: Nguyen and Ho.<sup>26</sup>

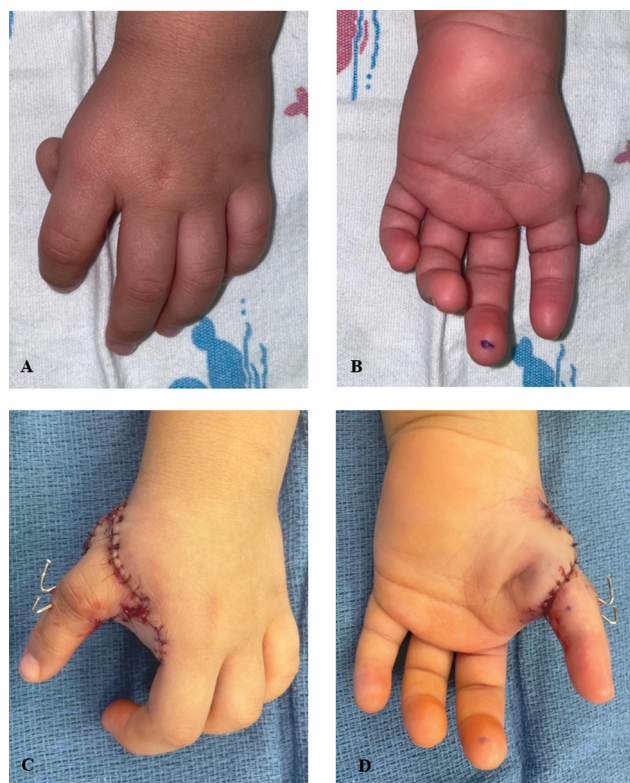
Twenty to sixty percent of patients have bilateral thumb hypoplasia.<sup>28</sup> It has been noted that the severity of hypoplasia is proportional to the severity of RLD.<sup>29</sup> The modified Blauth classification categorizes thumbs from a slightly smaller than normal thumb (type I) to the complete absence of a thumb (type V; ▶Table 3).<sup>30</sup> Key characteristics of the hypoplastic thumb are a smaller sized thumb in both length and girth. The first web space is deficient. The thumb MCP joint may be unstable from incompetence of the ulnar collateral ligament (UCL) and possibly also the radial collateral ligament (RCL). Extrinsic and intrinsic thumb musculature is hypoplastic or missing. The carpometacarpal (CMC) joint may be hypoplastic and unstable, which can be tested on physical exam. Radiographs are unreliable in assessing this joint until approximately 6 years of age when the trapezium and base of the first metacarpal ossify. Ultrasound is an option for early imaging assessment.<sup>28</sup>

Surgical treatment is dictated by the modified Blauth classification system. Type I thumbs do not require surgical treatment as they are fully functional. Type II and IIIa thumbs require reconstruction of the thumb addressing the three main problems: the first web space, lack of thumb opposition, and MCP joint instability. The narrowed first web space is deepened with adjacent tissue transfers, usually a 4-flap Z-plasty, and release of the first dorsal interosseous and adductor pollicis muscle fascia. Opposition is restored by performing a tendon transfer, most commonly the abductor digiti minimi (ADM) or flexor digitorum superficialis (FDS) to the middle or ring finger. Proponents of the ADM transfer cite

its restoration of natural contour to the thenar eminence.<sup>31</sup> Others prefer the FDS tendon transfer as its tendon can be simultaneously used to reconstruct the MCP joint collateral ligament(s).<sup>32</sup> Alternatively, a palmaris longus (PL) tendon graft can be used to reconstruct the MCP joint collateral ligaments. With global CMC joint instability, some prefer performing an MCP joint chondrodesis.<sup>17</sup>

Type IIIB and IV thumbs are most commonly treated with index pollicization after removal of the hypoplastic thumb. Removal of the thumb is advocated because of CMC joint instability, which cannot provide a stable foundation for thumb reconstruction. Of note, there are reports of stable, functional reconstructed type IIIB and IV thumbs in Asian cultures in which the presence of five digits is culturally important.<sup>33,34</sup> Type V thumbs are treated with index pollicization. Index pollicization is a complex procedure in which the index finger is transposed into a thumb position with its tendons and neurovascular supply intact. It is typically fixed into a position of 35 degrees palmar abduction, 20 degrees radial abduction, and 90 to 100 degrees pronation (▶Fig. 2).<sup>35,36</sup> ▶Table 4 details the structural and functional changes that occur during pollicization.<sup>26</sup>

Overall, both thumb hypoplasia reconstruction and index pollicization do well. One review of ADM opponensplasty showed mean postoperative key pinch strength of 40% when compared with normal age-matched controls.<sup>37</sup> Studies assessing FDS opponensplasty for type II and IIIa thumbs have also shown positive functional outcomes. Vuillermin et al reported mean strengths of 46% for grip, 49% for lateral pinch, and 48% for tripod pinch relative to age and sex-matched controls.<sup>38</sup> de Kraker et al found grip strength, pinch strength, tripod strength, and key pinch strength to be 50% in type II thumbs and 35% in type IIIa thumbs. MCP joint stability was attained in all type II thumbs and 40% of type IIIa thumbs.<sup>39</sup> A total of four patients required MCP joint revision for continued instability.<sup>38,39</sup> Goldfarb et al evaluated postop complications after index pollicization and found a 10.9% perioperative complication rate consisting of venous congestion, marginal necrosis, and infection. Thirty-six percent of patients required additional procedures for either poor opposition or limited extension.<sup>40</sup> Other known



**Fig. 2** (A, B) A Blauth type IV hypoplastic thumb, also known as a “pouce flottant.” (C, D) Immediate postoperative results after index pollicization.

**Table 4** New roles of joints, bones, and muscles of the index finger after thumb pollicization

Joints and Bones		Muscles	
Index finger	New thumb	Index finger	New thumb
DIP joint	IP joint	First volar interosseous	AdP
PIP joint	MCP joint	First dorsal interosseous	APB
MCP joint	CMC joint	EIP	EPL
Metacarpal	Trapezium	EDC to index	APL

Abbreviations: AdP, adductor pollicis; APB, abductor pollicis brevis; APL, abductor pollicis longus; CMC, carpometacarpal; DIP, distal interphalangeal; EDC, extensor digitorum communis; EIP, extensor indicis proprius; EPL, extensor pollicis longus; IP, interphalangeal; MCP, metacarpophalangeal; MCP, metacarpophalangeal; PIP, proximal interphalangeal.

Source: Nguyen and Ho.<sup>26</sup>

long-term complications after pollicization include malrotation, failure to grow, excessive length, and stiffness.<sup>17,41</sup>

## Polydactyly

### Preaxial Polydactyly

Preaxial polydactyly, also known as duplicated thumb or split thumb, occurs in 0.8 to 1.4 of 1,000 live births.<sup>42</sup> While usually sporadic and unilateral, a duplicated thumb with a triphalangeal component is autosomal dominant.<sup>43</sup> The



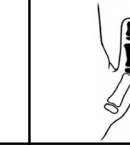
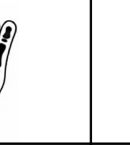



Wassel–Flatt classification system is most commonly used, which identifies the most proximal level of duplication within the thumb, starting distally and progressing proximally. A type VII thumb contains a triphalangeal component (►Table 5).<sup>44</sup> More complex preaxial polydactylies that involve triplications and triphalangism do not easily fit into the Wassel–Flatt classification system, and other classification systems have been developed to account for these more complex variations.<sup>45–47</sup>

Thumbs vary widely in appearance from slightly widened, completely duplicated, or partially syndactylized thumbs that can be triplicated and include triphalangism (►Fig. 3). Preaxial polydactyly can occur with ipsilateral hypoplastic thumb.<sup>48</sup> Thumbs may be angulated, displaying a characteristic divergent-convergent deformity, which is difficult to correct surgically. The thumb should be evaluated for pollex abductus, an anomalous connection between the FPL and extensor pollicis longus (EPL) tendons, which causes IP joint apex ulnar angulation with attempted IP joint flexion. Preoperative active motion of joints should be documented, as a poorly moving thumb before surgery will not improve after surgery. Radiographs are always obtained to help in classification and surgical planning.

Surgical reconstruction is delayed until 1 year of age to decrease risks of anesthesia, but still allow reconstruction before the development of tip-to-tip pinch. Thumb reconstruction can be divided into four general types. Simple excision of the extra digit can be performed in rudimentary thumbs attached by a skin bridge. More well-formed duplications are not appropriate for this procedure. Most duplicated thumbs are reconstructed by excising the more diminutive thumb, usually the radial thumb to preserve the UCL, which is important for pinch. Flexor and extensor tendons to the retained thumb are preserved and centralized if needed. The tendon to the excised thumb can be preserved and inserted into the retained thumb for augmentation. Depending on the level of duplication, the collateral ligament to the IP, MCP, or CMC thumb joint is preserved by dissecting it proximally with a strip of periosteum to allow for reinsertion on the retained thumb.<sup>49</sup> More proximal duplications also require reinsertion of the thenar musculature. Angulation of the retained thumb may require closing wedge osteotomy of the bone to straighten the thumb. The head of the bone proximal to thumb duplication may have a widened articular surface which requires excision of the facet to the removed thumb to prevent future growth in that direction and an unsightly prominence. K-wires are typically kept for 4 weeks to maintain linear alignment of joints and bones as soft tissues and osteotomies heal.

The Bilhaut–Cloquet procedure is a surgical option for type I and II thumbs in which neither thumb is dominant.<sup>50</sup> The central portion of the duplicated bone and soft tissue is excised with the lateral aspects of each thumb reapproximated in the midline. It is criticized for causing nail deformity, growth plate arrest, and joint stiffness.<sup>51</sup> Finally, an on-top plasty is rarely indicated for thumb reconstruction when one thumb has a better proximal portion and the other has a better distal portion. The better distal portion is transposed

**Table 5** Wassel–Flatt classification for thumb duplication

						
Type I	Type II	Type III	Type IV	Type V	Type VI	Type VII
Split distal phalanx	Duplicated distal phalanx	Split proximal phalanx and duplicated distal phalanx	Duplicated proximal and distal phalanx	Split metacarpal with duplicated proximal and distal phalanges	Completely duplicated thumb	Duplicated thumb with triphalangism

Source: Nguyen and Ho.<sup>26</sup>

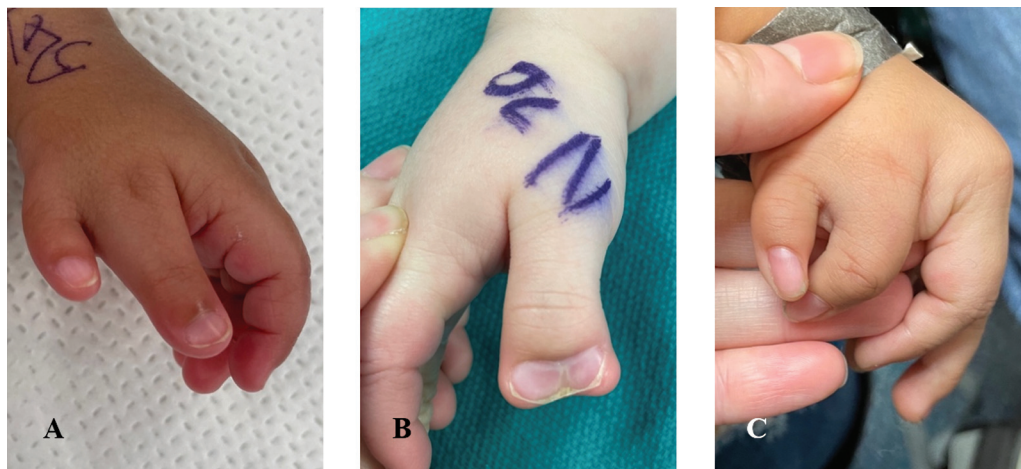onto the better proximal portion with its tendons and neurovascular pedicle intact.<sup>52</sup>

Reported functional outcomes after duplicated thumb reconstruction are encouraging. Gholson et al reported similar disabilities of arm, shoulder, and hand scores of preaxial polydactyly reconstructions when compared with the general population. They also found similar pinch strength, side pinch strength, and grip strength when compared with the contralateral uninvolved hand.<sup>53</sup> Dijkman et al found that type II and IV preaxial polydactyly reconstructions demonstrated competence with all manual tasks.<sup>54</sup> However, some patients do report ongoing psychosocial issues related to the aesthetics of the reconstructed thumb, with satisfaction rates ranging from 58 to 88%.<sup>55</sup> Goldfarb et al found that lower visual analog scale scores were associated with increased IP joint angulation and Wassel–Flatt type VI and VII thumbs.<sup>56</sup> Some studies have tried to establish initial thumb joint angulation parameters to determine if osteotomy at the time of surgery is needed for long-term correction of angulation deformity. Hong et al recommended performing corrective osteotomy if metacarpal deviation angle is greater than 10.8 degrees, while others have found soft-tissue correction alone sufficient for metacarpal deviation angles less than 30 degrees.<sup>57,58</sup>

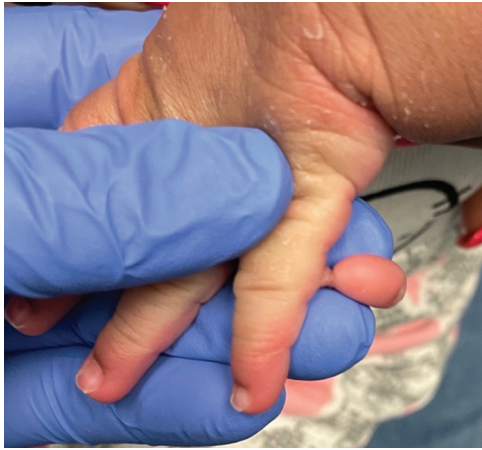### Postaxial Polydactyly

Postaxial polydactyly is an extra digit on the ulnar aspect of the hand. It is very common, occurring in almost 4 out of every 10,000 live births per year.<sup>59</sup> The most common classification system used divides fingers into type A, well-formed extra digit with articulation at the fifth or sixth metacarpal, and type B, underdeveloped, rudimentary digit attached to the ulnar aspect of the hand by a skin bridge (►Fig. 4).<sup>5</sup> Postaxial polydactyly is much more common in African-Americans, estimated to occur in 1 in 143 live births, occurs in isolation, and is usually inherited in autosomal dominant fashion with variable penetrance.<sup>17</sup> In Caucasians, postaxial polydactyly can be associated with systemic anomalies such as chondroectodermal dysplasia or Ellis-van Creveld syndrome.<sup>17</sup>

Traditionally, type B postaxial polydactyly has been treated by suture ligation in the nursery. However, long-term studies have found unsatisfactory cosmetic outcomes with residual bumps as well as painful neuromas. Watson and Hennrikus reported residual bumps in 43% of patients.<sup>60</sup> Rayan and Frey found a 16.1% rate of “tender or unacceptable remnant” after suture ligation.<sup>61</sup> Goebel et al found that 10 of 24 patients who underwent suture ligation required revision surgery for either symptomatic neuroma or persistent polydactyly.<sup>62</sup> Texas Scottish Rite reported its use of surgical clips



**Fig. 3** Various examples of preaxial polydactyly, from (A) a clearly diminutive radial thumb to (B) thumbs of equal size with synonychia to (C) divergent-convergent thumbs whose angulation will be difficult to correct.



**Fig. 4** Example of postaxial polydactyly type B in a newborn.

to perform in-office ligation of type B postaxial polydactyly, the thought being the wider area of ligation decreases the risk of nubbin formation. Seven percent of extremities required surgical revision for painful, residual nubbins. Surgical excision either in the office or in the operating room is another treatment option. Multiple studies have shown minimal postoperative complications after surgical excision, consisting of either surgical site infection, residual nubbin, or symptomatic neuroma.<sup>61,63</sup>

Type A postaxial polydactyly is much less common than type B. An excision and reconstruction approach similar to that for preaxial polydactyly should be used. Typically, the ulnar digit is excised. If the duplication occurs at the MCP joint, the UCL must be preserved as a ligamentoperiosteous flap as well as the ADM insertion for reinsertion onto the retained finger. Realignment of tendons is rarely needed. If the metacarpal head is bifacet, widened for articulation of the duplicated distal bones, the ulnar facet must be contoured to eliminate future ulnar growth and formation of a bump.

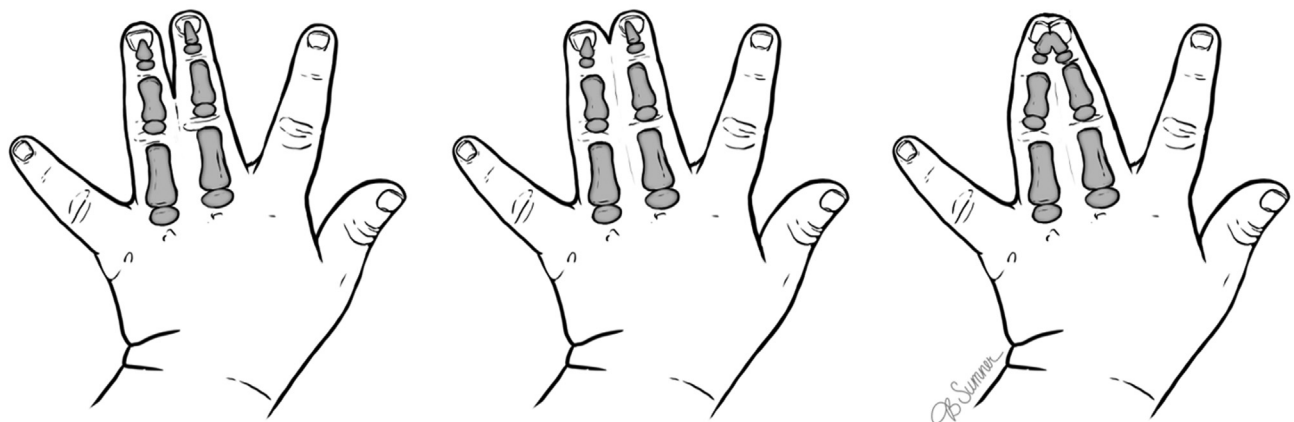
## Syndactyly

Syndactyly, or webbed digits, occurs in 2 to 2,000 live births, affects males twice as often as females, and occurs bilaterally in

50% of patients.<sup>64</sup> While usually sporadic, 10 to 40% of patients will demonstrate a family history, indicating autosomal dominance with variable penetrance and expressivity.<sup>64</sup> Syndactyly usually occurs in isolation but can be associated with other conditions or syndromes such as Poland syndrome (symbra-chydactyly), Apert's and other acrocephalosyndactyly syndromes (complex syndactyly), and amniotic band syndrome (ABS) (acrosyndactyly).<sup>64,65</sup>

Syndactyly is a failure of apoptosis between the digits to create web spaces. The third webspace is most commonly affected followed by the fourth, second, and first. Radiographs are mandatory to assess involvement of underlying bony structures, such as bony fusions, accessory bones, extra digits (synpolydactyly), or other joint anomalies. Traditionally, syndactyly is classified based on extent of distal fusion between the digits and the involved fused structures. It is labeled complete or incomplete, based on whether it extends to the fingertip, and simple or complex, based on whether it involves only skin and subcutaneous tissue or includes fusion of underlying bones (► **Fig. 5**). Kozin modified this classification to assist with optimal surgical timing and technique by dividing the simple and complex categories further into standard (s), complicated (c), and urgent (u).<sup>66</sup> Complete syndactyly may involve synonychia, conjoined nails.<sup>66</sup>

Timing of syndactyly reconstruction varies between surgeons, but most advocate surgery before 2 years of age. Children develop hand function patterns between 6 to 24 months.<sup>67</sup> Surgery before school age may prevent ridicule and stigma from peers.<sup>68</sup> Border digit syndactyly must usually be addressed before 12 months of age due to length discrepancy between the digits which becomes more accentuated with growth (the hand doubles in size during the first year of life). Tethering of the longer digit, left unaddressed, can lead to long-term angular and/or rotational deformities. Syndactyly of adjacent web spaces will require staged reconstruction so as not to jeopardize vascularity to the digits. In syndactyly involving all four web spaces, typically the first and third web spaces are initially addressed and 3–6 months later, the second and fourth web spaces are treated. In complex syndactylies, for example Apert's, a careful examination of the hand is required as sometimes anatomy will not support five



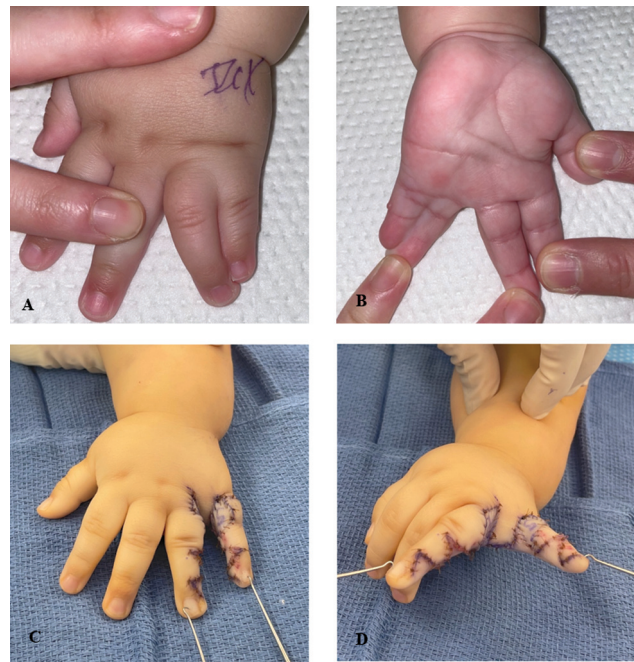**Fig. 5** Types of syndactylies: simple, incomplete (left); simple, complete (middle); complex (right).

functioning separated digits and consideration should be given to maintaining some of the syndactylies in exchange for stable digital constructs.

Many articles have been published on the technical aspects of syndactyly reconstruction, but they all share the same basic tenants. Most surgeons will agree the key to syndactyly reconstruction is recreation of the web space commissure. The normal commissure extends distally to half the length of the proximal phalanx and slopes 45 to 50 degrees from dorsal to palmar.<sup>66</sup> In general, the web space is recreated with adjacent skin flaps, either dorsal flaps, volar flaps, or interdigitating V-flaps, although many favor some version of the dorsal flap. Various other flaps, such as the local advancement flap with triangle-shaped wings or the dorsal metacarpal island flap have been described in an attempt to prevent the need for skin grafts proximally, adjacent to the commissure.<sup>69,70</sup> The commissural flap must be inset without tension to prevent future web creep. It has also been suggested that any breakup in the direction of scarring within the web space will help decrease tension.<sup>71</sup> The digits are then separated distally, usually by zig-zag incisions to create alternating flaps for coverage of the digits from both volar and dorsal aspects. Distally, when synonychia is present, Buck-Gramcko flaps can be designed for recreation of the involved paronychia folds. Care must be taken to preserve the neurovascular bundles to each finger. A distal bifurcation of the common digital nerve may need to be neurolyzed proximally. A distal bifurcation of the common digital artery may require ligation of the digital artery to one of the fingers, provided there is sufficient flow from the digit's other digital artery. Skin flaps are inset after defatting to help increase coverage, and the finger is assessed for the need of skin grafts (→ Fig. 6).

Skin grafting is essential to syndactyly reconstruction as it has been shown that the circumference of separated digits is 22% greater than the circumference of syndactylized digits.<sup>1</sup> Full-thickness skin grafts are most often taken from the groin or volar wrist. Proponents of the groin donor site cite a scar at the wrist can be seen as a suicide attempt. Advocates of the volar wrist cite the lack of hair growth in this area, even in the most hirsute individuals, and excellent color match. More recently, synthetic dermal substitutes have been used instead of full-thickness skin grafts with encouraging results. Wall et al reported only 5 of 21 web spaces required revision surgery for web creep.<sup>72</sup> Of note, this was only at 1-year follow-up, so long-term outcomes are still awaited. Patients are typically casted for 3 to 4 weeks postoperatively, while incisions and skin grafts heal.

Both short and long-term studies of simple syndactyly reconstruction are favorable. Edwards et al reported on 2-year postoperative results after simple syndactyly reconstruction and found that in 143 web space reconstructions, there were six infections, one pyogenic granuloma, one donor site dehiscence, and four revisions for webspace creep or scar contracture.<sup>73</sup> Long-term outcomes for simple syndactyly remain encouraging, with one study reporting an 8% incidence of web creep which did not interfere with hand function.<sup>74</sup> Only 2 of 19 patients reported functional issues (crocheting and



**Fig. 6** (A, B) Dorsal and volar aspects of a fourth web space simple complete syndactyly without synonychia. Ulnar angulation of the ring finger is noted due to tethering effect from the small finger. (C, D) Immediate postoperative results after syndactyly release using zigzag dorsal and volar incisions and a dorsally based pentagonal shaped flap for web space reconstruction.

catching a ball), but one patient had concomitant oligodactyly and the other had symbrachydactyly. Skin grafts were obtained from the groin, and 70% of patients showed hair growth within their skin graft sites.<sup>74</sup> Complex syndactylies are typically noted to have worse outcomes than simple syndactyly. Goldfarb et al assessed their long-term results after reconstruction of complete, complex syndactyly in 25 web spaces.<sup>75</sup> Twenty-four percent of web spaces required revision, either for scar contracture release, PIP joint contracture release, web space deepening, or bony work. Notable web creep was identified in 48% of web spaces, while angulation and rotation of digits and nail deformity were commonly noted.<sup>75</sup>

### Amniotic Band Syndrome

Amniotic band syndrome (ABS), or constriction band syndrome, is a congenital disorder with circumferential bands around affected limbs which cause a constrictive hour-glass appearance, malformation, and even amputation depending on severity. ABS occurs in 1 in 1,200 to 15,000 live births.<sup>76,77</sup> Females are affected more often than males (1.44 to 0.91), and African-Americans are affected 1.76 times more frequently than Caucasians.<sup>76</sup> No distinct risk factor has been identified, but an abnormal pregnancy event is documented in up to 60% of patients.<sup>78,79</sup> Craniofacial abnormalities, body-wall defects, talipes equinovarus, and internal organ abnormalities have all been associated with ABS.

The cause of ABS is not fully understood, with multiple theories regarding the cause. First described by Streeter in 1930, the intrinsic theory states that an abnormality within the germline development causes the amniotic band.<sup>80</sup> This

**Table 6** Patterson classification for amniotic constriction bands

Stage I	Simple constriction ring	
Stage II	Constriction ring with the deformity of distal part lymphedema may be present	
Stage III	Distal fusion (acrosyndactyly)	
	Type I	Normal web space with distal fingertip fusion
	Type II	Incomplete web space formation with distal fingertip fusion
	Type III	Sinus tracts between digits with distal fingertip fusion
Stage IV	Intrauterine amputation	

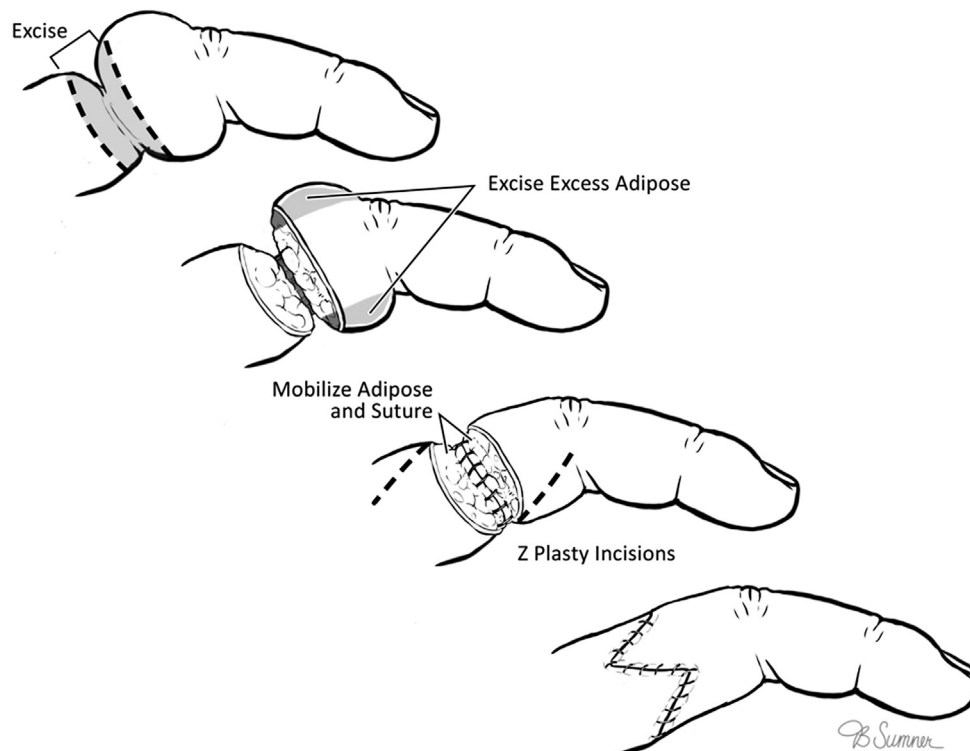
Source: Gogola.<sup>87</sup>

theory helps support the association with body-wall defects and internal organ and craniofacial abnormalities and has been supported by several studies.<sup>81</sup> Extrinsic theory, probably the most widely accepted theory currently, argues that rupture of the amniotic sac from the failure of fusion of the amniotic and chorionic sacs leads to the development of amniotic bands which encircle and constrict body parts.<sup>82</sup> Finally, some point to vascular disruption which then causes systemic alteration of embryonic blood supply.<sup>83</sup>

Presentation of ABS is highly variable and can involve all four extremities. The distal aspect of limbs is more commonly affected, with fingers and hands involved up to 80% of the time.<sup>79</sup> The thumb is rarely affected, while the middle fingers are most commonly involved.<sup>79</sup> Constriction bands can be mildly indented to severely constricting with distal edema and

even vascular compromise and nerve compression. Digits can display acrosyndactyly in which the distal aspects are fused, but proximally they are separate. Historically, anatomy proximal to the amniotic band has been described as normal. However, recent studies have noted metacarpal hypoplasia and proximal vascular abnormalities that are proximal to bands.<sup>84</sup> The most widely used classification system is that of Patterson, which classifies patients based on deformity distal to the constriction band (→ **Table 6**).<sup>85</sup>

Surgical timing to correct amniotic bands varies on presentation. In the setting of acute limb ischemia or severe distal edema, amniotic band release is done urgently with nerve and soft tissue reconstruction done at a second stage. This is rare and most amniotic bands can be treated in a delayed manner, timing determined by amniotic band depth and resulting distal

**Fig. 7** Amniotic band correction as described by Upton and Tan.



edema. The more severe the distal edema, the sooner surgery should be done to prevent secondary fibrosis. Acrosyndactyly should be corrected before the age of 1 year to prevent longitudinal bone growth restriction.<sup>86,87</sup> In the setting of amputation, various options consist of no surgical intervention, digital lengthening, bone grafting, and finger and toe transfers.<sup>86</sup> Preoperative radiography assists in surgical planning.

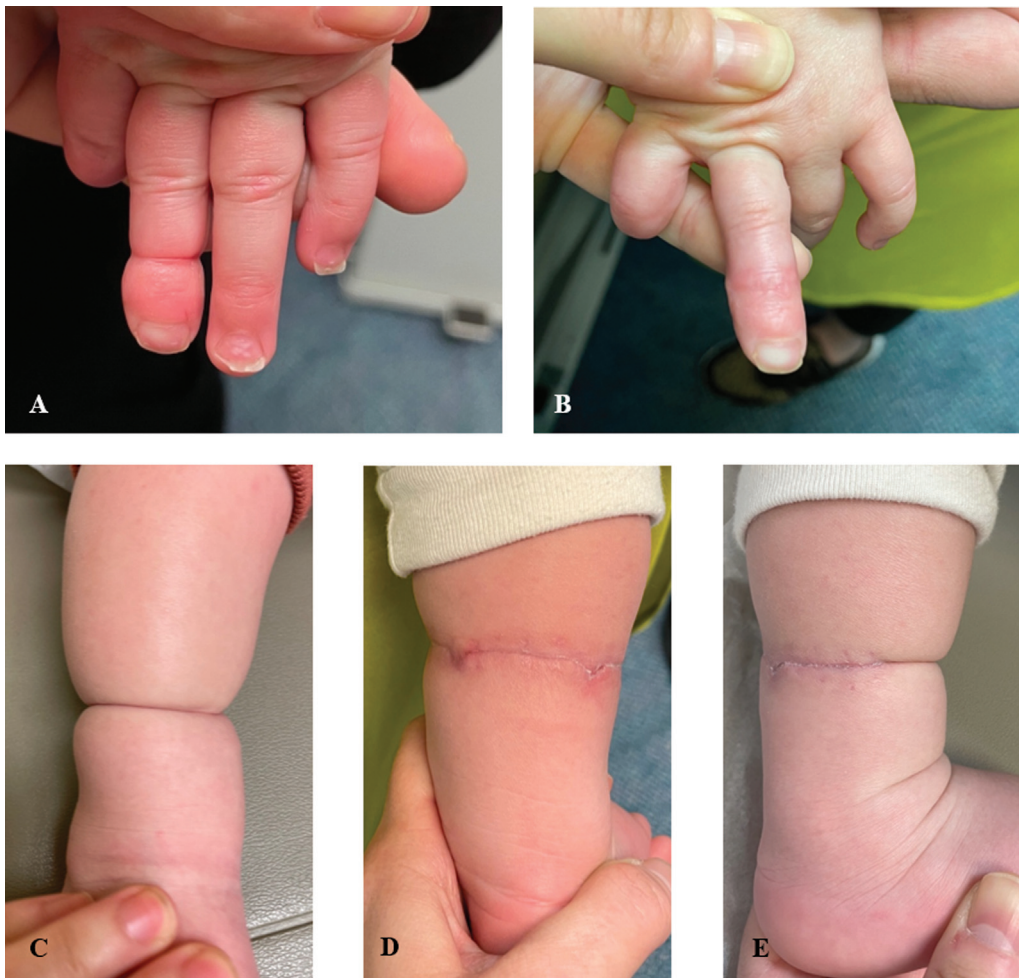While superficial bands can be released in 1 stage, many surgeons still advocate a two-stage reconstruction for deep amniotic bands to prevent vascular compromise to the distal extremity. Six to twelve weeks is recommended between surgeries.<sup>87</sup> The most commonly used technique for amniotic band excision is that described by Upton and Tan (→Figs. 7 and 8).<sup>88</sup> The band is excised, and skin flaps are elevated proximally and distally. Separate subcutaneous fat flaps are dissected out and debulked as needed. Care is taken to preserve veins. Subcutaneous fat flaps and skin flaps are advanced separately for skin closure and to correct the indentation deformity. Often, z-plasties are needed on the lateral aspects of the finger or arm.

Historically, amniotic bands of the forearm and arm have been reconstructed with either z- or w-plasties to prevent band recurrence. Some surgeons now advocate for straight-

line closure as in general scars should be aligned within relaxed skin tension lines (RSTLs) and limb RSTLs lie in an almost circular pattern. Multiple studies have reported good outcomes with linear closure.<sup>89,90</sup> Habenicht et al reported their 10-year experience with linear closure of amniotic bands and found excellent cosmetic results with no recurrence of banding in 43 surgical corrections.<sup>90</sup>

There are limited studies on outcomes after surgical reconstruction of amniotic bands, primarily consisting of case series. Almost all report satisfactory aesthetic outcomes with minimal recurrence of bands. Mutaf and Sunay reconstructed 12 severe amniotic bands with dermofat flaps and found aesthetically acceptable results at mean follow-up of 3 years.<sup>91</sup> Jiang et al performed single-stage resection of amniotic bands with fascial flap and triangular flap-plasty in 21 patients and found no band recurrence in any patients at 26-month follow-up.<sup>92</sup> Inglesby's review of ABS cites a 0 to 33% recurrence rate of amniotic bands with recurrence attributed to incomplete resection of the band at the time of reconstruction.<sup>93</sup>

Preoperative nerve dysfunction secondary to amniotic banding is associated with poor prognosis.<sup>94</sup> Jones et al performed early release of amniotic bands causing ulnar nerve



**Fig. 8** Amniotic band syndrome. (A, B) Preoperative and postoperative pictures, respectively, of an amniotic band to the left middle finger. Correction was done using the Tan and Upton method. (C–E) Preoperative and postoperative pictures of an amniotic band to the right lower extremity. Excision was performed in staged fashion, and patient is awaiting excision of remaining half of amniotic band.

palsy and found no nerve recovery at 7 years postop. In light of these findings, he advocated the urgent release of amniotic bands with excision of the compressed segment with either primary repair or nerve grafting.<sup>94</sup> Other case reports support poor nerve outcomes in nerve palsies associated with amniotic bands, with only two of nine patients' nerves improving after amniotic band excision and neurolysis.<sup>95–99</sup> Several patients went on to require nerve grafting or tendon transfers.

## Conclusion

There are a wide number of congenital upper extremity anomalies. Due to their prevalence, plastic surgeons should be familiar with the various presentations and cognizant of which anomalies require further workup due to association with systemic conditions. Particularly, thumb hypoplasia may be associated with underlying syndromes or associations, while ABS usually presents with multiple extremities and body parts affected. Accurate classification of hand anomalies assists in determining both reconstructive technique and surgical timing. Surgical timing should minimize the risks of anesthesia to the developing brain while maximizing hand function and aesthetics.

## References

- 1 Flatt A. *The Care of Congenital Hand Anomalies*. 2nd ed. St. Louis, MO: Quality Medical Pub., Inc.; 1994
- 2 Parker SE, Mai CT, Canfield MA, et al; National Birth Defects Prevention Network. Updated National Birth Prevalence estimates for selected birth defects in the United States, 2004–2006. *Birth Defects Res A Clin Mol Teratol* 2010;88(12):1008–1016
- 3 Goldfarb CA, Shaw N, Steffen JA, Wall LB. The prevalence of congenital hand and upper extremity anomalies based upon the New York Congenital Malformations Registry. *J Pediatr Orthop* 2017;37(02):144–148
- 4 Bamshad M, Watkins WS, Dixon ME, et al. Reconstructing the history of human limb development: lessons from birth defects. *Pediatr Res* 1999;45(03):291–299
- 5 Temtamy SA, McKusick VA. The genetics of hand malformations. *Birth Defects Orig Artic Ser* 1978;14(03):i–xviii, 1–619
- 6 Rodgers WB, Waters PM. Incidence of trigger digits in newborns. *J Hand Surg Am* 1994;19(03):364–368
- 7 Kikuchi N, Ogino T. Incidence and development of trigger thumb in children. *J Hand Surg Am* 2006;31(04):541–543
- 8 Slakey JB, Hennrikus WL. Acquired thumb flexion contracture in children: congenital trigger thumb. *J Bone Joint Surg Br* 1996;78(03):481–483
- 9 Shen K, Han B, Xu Y. Characterization of pediatric extension trigger thumb: an insight into a rare manifestation from a single-center retrospective cohort analysis. *J Hand Surg Am* 2021;46(10):926.e1–926.e8
- 10 Ger E, Kupcha P, Ger D. The management of trigger thumb in children. *J Hand Surg Am* 1991;16(05):944–947
- 11 Hueston JT, Wilson WF. The aetiology of trigger finger explained on the basis of intratendinous architecture. *Hand* 1972;4(03):257–260
- 12 Fahey JJ, Bollinger JA. Trigger-finger in adults and children. *J Bone Joint Surg Am* 1954;36-A(06):1200–1218
- 13 Kuo M, Rayan GM. Complete annular and partial oblique pulley release for pediatric locked trigger thumb. *Hand (N Y)* 2010;5(04):408–414
- 14 Verma M, Craig CL, DiPietro MA, et al. Serial ultrasound evaluation of pediatric trigger thumb. *J Pediatr Orthop* 2013;33(03):309–313
- 15 Kim J, Gong HS, Seok HS, Choi YH, Oh S, Baek GH. Quantitative measurements of the cross-sectional configuration of the flexor pollicis longus tendon using ultrasonography in patients with pediatric trigger thumb. *J Hand Surg Am* 2018;43(03):284.e1–284.e7
- 16 Khoshhal KI, Jarvis JG, Uthoff HK. Congenital trigger thumb in children: electron microscopy and immunohistochemical analysis of the first annular pulley. *J Pediatr Orthop B* 2012;21(04):295–299
- 17 Kozin S, Pederson W, Wolfe S, Cohen M, Hotchkiss R. *Green's Operative Hand Surgery*. Seventh Edition. Philadelphia, PA: Elsevier; 2017
- 18 Dinham JM, Meggitt BF. Trigger thumbs in children. A review of the natural history and indications for treatment in 105 patients. *J Bone Joint Surg Br* 1974;56(01):153–155
- 19 Baek GH, Kim JH, Chung MS, Kang SB, Lee YH, Gong HS. The natural history of pediatric trigger thumb. *J Bone Joint Surg Am* 2008;90(05):980–985
- 20 Baek GH, Lee HJ. The natural history of pediatric trigger thumb: a study with a minimum of five years follow-up. *Clin Orthop Surg* 2011;3(02):157–159
- 21 Hutchinson DT, Rane AA, Montanez A. The natural history of pediatric trigger thumb in the United States. *J Hand Surg Am* 2021;46(05):424.e1–424.e7
- 22 Dittmer AJ, Grothaus O, Muchow R, Riley S. Pulling the trigger: Recommendations for surgical care of the pediatric trigger thumb. *J Pediatr Orthop* 2020;40(06):300–303
- 23 Marek DJ, Fitoussi F, Bohn DC, Van Heest AE. Surgical release of the pediatric trigger thumb. *J Hand Surg Am* 2011;36(04):647–652.e2
- 24 Ray SB, Gibbs CM, Fowler JR. Trigger thumb in pediatric patients: a 20-year update. *Hand (N Y)* 2022 (e-pub ahead of print). Doi: 10.1177/15589447221130088
- 25 Colen DL, Lin IC, Levin LS, Chang B. Radial longitudinal deficiency: recent developments, controversies, and an evidence-based guide to treatment. *J Hand Surg Am* 2017;42(07):546–563
- 26 Nguyen JL, Ho CA. Congenital disorders of the pediatric thumb. *JBJS Rev* 2022;10(03):21–147
- 27 Webb ML, Rosen H, Taghnia A, et al. Incidence of Fanconi anemia in children with congenital thumb anomalies referred for diepoxbutane testing. *J Hand Surg Am* 2011;36(06):1052–1057
- 28 Soldado F, Zlotolow DA, Kozin SH. Thumb hypoplasia. *J Hand Surg Am* 2013;38(07):1435–1444
- 29 Forman M, Canizares MF, Bohn D, et al; CoULD Study Group. Association of radial longitudinal deficiency and thumb hypoplasia: an update using the CoULD Registry. *J Bone Joint Surg Am* 2020;102(20):1815–1822
- 30 Manske PR, McCarroll HR Jr. Reconstruction of the congenitally deficient thumb. *Hand Clin* 1992;8(01):177–196
- 31 Ishida O, Ikuta Y, Sunagawa T, Ochi M. Abductor digiti minimi musculocutaneous island flap as an opposition transfer: a case report. *J Hand Surg Am* 2003;28(01):130–132
- 32 Kozin SH, Ezaki M. Flexor digitorum superficialis opponensplasty with ulnar collateral ligament reconstruction for thumb deficiency. *Tech Hand Up Extrem Surg* 2010;14(01):46–50
- 33 Kawabata H, Tamura D, Goldfarb CA. Treatment of blauth type IIIB thumb hypoplasia using a nonvascularized toe phalanx. *J Hand Surg Am* 2021;46(01):68.e1–68.e7
- 34 Liu B, Chen S, Chow ECS, Li P, Liu K, Yang C. Type IIIB and IV hypoplastic thumb reconstruction with non-vascularized fourth metatarsal. *J Hand Surg Eur Vol* 2020;45(07):722–728
- 35 Manske PR. Index pollicization for thumb deficiency. *Tech Hand Up Extrem Surg* 2010;14(01):22–32
- 36 Carter P, Ezaki M. Pollicization: making a thumb—for the surgeon. *Texas Scottish Rite Hospital for Children* 2006 Accessed August 5, 2023. <https://vimeo.com/tsrh/pollicization-surgeon>

- 37 Upton J, Taghnia AH. Abductor digiti minimi myocutaneous flap for opponensplasty in congenital hypoplastic thumbs. *Plast Reconstr Surg* 2008;122(06):1807–1811
- 38 Vuillermin C, Butler L, Lake A, Ezaki M, Oishi S. Flexor digitorum superficialis opposition transfer for augmenting function in types II and IIIA thumb hypoplasia. *J Hand Surg Am* 2016;41(02):244–249, quiz 250
- 39 de Kraker M, Selles RW, Zuidam JM, Molenaar HM, Stam HJ, Hovius SE. Outcome of flexor digitorum superficialis opponensplasty for Type II and IIIA thumb hypoplasia. *J Hand Surg Eur Vol* 2016;41(03):258–264
- 40 Goldfarb CA, Monroe E, Steffen J, Manske PR. Incidence and treatment of complications, suboptimal outcomes, and functional deficiencies after pollicization. *J Hand Surg Am* 2009;34(07):1291–1297
- 41 Clark DI, Chell J, Davis TRC. Pollicisation of the index finger. A 27-year follow-up study. *J Bone Joint Surg Br* 1998;80(04):631–635
- 42 Baek G. *The Pediatric Upper Extremity*. 1st edition (Abzug J, Kozin S, Zlotolow D, eds.). New York, NY: Springer; 2015
- 43 Watt AJ, Chung KC. Duplication. *Hand Clin* 2009;25(02):215–227
- 44 Wassel HD. The results of surgery for polydactyly of the thumb. A review. *Clin Orthop Relat Res* 1969;64(64):175–193
- 45 Zuidam JM, Selles RW, Ananta M, Runia J, Hovius SER. A classification system of radial polydactyly: inclusion of triphalangeal thumb and triplication. *J Hand Surg Am* 2008;33(03):373–377
- 46 Miura T. Triphalangeal thumb. *Plast Reconstr Surg* 1976;58(05):587–594
- 47 Wood VE. Polydactyly and the triphalangeal thumb. *J Hand Surg Am* 1978;3(05):436–444
- 48 Bauer AS, Netto AP, James MA. Thumb hypoplasia occurring in patients with preaxial polydactyly. *J Hand Surg Am* 2020;45(03):182–188
- 49 Manske PR. Treatment of duplicated thumb using a ligamentous/periosteal flap. *J Hand Surg Am* 1989;14(04):728–733
- 50 Tonkin MA, Bulstrode NW. The Bilhaut-Cloquet procedure for Wassel types III, IV and VII thumb duplication. *J Hand Surg Eur Vol* 2007;32(06):684–693
- 51 Baek GH, Gong HS, Chung MS, Oh JH, Lee YH, Lee SK. Modified Bilhaut-Cloquet procedure for Wassel type-II and III polydactyly of the thumb. *J Bone Joint Surg Am* 2007;89(03):534–541
- 52 Bell B, Butler L, Mills J, Stutz C, Ezaki M, Oishi S. “On-top plasty” for radial polydactyly reconstruction. *J Hand Surg Am* 2017;42(09):753.e1–753.e6
- 53 Gholson JJ, Shah AS, Buckwalter JA IV, Buckwalter JA V. Long-term clinical and radiographic follow-up of preaxial polydactyly reconstruction. *J Hand Surg Am* 2019;44(03):244.e1–244.e6
- 54 Dijkman RR, van Nieuwenhoven CA, Selles RW, Hovius SE. Comparison of functional outcome scores in radial polydactyly. *J Bone Joint Surg Am* 2014;96(06):463–470
- 55 Bickham RS, Waljee JF, Chung KC, Adkinson JM. Postoperative patient- and parent-reported outcomes for children with congenital hand differences: a systematic review. *Plast Reconstr Surg* 2017;139(06):1422–1429
- 56 Goldfarb CA, Patterson JM, Maender A, Manske PR. Thumb size and appearance following reconstruction of radial polydactyly. *J Hand Surg Am* 2008;33(08):1348–1353
- 57 Hong SW, Kim J, Oh S, Lee MH, Baek GH. When is primary metacarpal corrective osteotomy recommended in patients with Flatt type IV radial polydactyly? *Plast Reconstr Surg* 2021;147(02):399–408
- 58 Luangjarmekorn P, Virojanawat N, Pongpacharaamphon P, Kitudumrongsook P. Preoperative angulation as a predictor for operations of Wassel type IV polydactyly. *J Pediatr Orthop B* 2021;30(06):605–610
- 59 Ekblom AG, Laurell T, Arner M. Epidemiology of congenital upper limb anomalies in 562 children born in 1997 to 2007: a total population study from Stockholm, Sweden. *J Hand Surg Am* 2010;35(11):1742–1754
- 60 Watson BT, Hennrikus WL. Postaxial type-B polydactyly. Prevalence and treatment. *J Bone Joint Surg Am* 1997;79(01):65–68
- 61 Ryan GM, Frey B. Ulnar polydactyly. *Plast Reconstr Surg* 2001;107(06):1449–1454, discussion 1455–1457
- 62 Goebel GJ, Dawson S, Loewenstein SN, Adkinson JM. Long-term outcomes after treatment for type B ulnar polydactyly. *J Pediatr Orthop* 2022;42(05):e466–e469
- 63 Singer G, Thein S, Kraus T, Petnehazy T, Eberl R, Schmidt B. Ulnar polydactyly - an analysis of appearance and postoperative outcome. *J Pediatr Surg* 2014;49(03):474–476
- 64 Manske M, Goldfarb C. *The Pediatric Upper Extremity*. 1st edition (Abzug J, Kozin S, Zlotolow D, eds.). New York, NY: Springer; 2015
- 65 Dao KD, Shin AY, Billings A, Oberg KC, Wood VE. Surgical treatment of congenital syndactyly of the hand. *J Am Acad Orthop Surg* 2004;12(01):39–48
- 66 Syndactyly KS. *J Am Soc Surg Hand* 2001;1(01):1–13
- 67 Hutchinson DT, Frenzen SW. Digital syndactyly release. *Tech Hand Up Extrem Surg* 2010;14(01):33–37
- 68 Vekris MD, Lykissas MG, Soucacos PN, Korompilias AV, Beris AE. Congenital syndactyly: outcome of surgical treatment in 131 webs. *Tech Hand Up Extrem Surg* 2010;14(01):2–7
- 69 Hsu VM, Smartt JM Jr, Chang B. The modified V-Y dorsal metacarpal flap for repair of syndactyly without skin graft. *Plast Reconstr Surg* 2010;125(01):225–232
- 70 Sherif MM. V-Y dorsal metacarpal flap: a new technique for the correction of syndactyly without skin graft. *Plast Reconstr Surg* 1998;101(07):1861–1866
- 71 Miyamoto J, Nagasao T, Miyamoto S. Biomechanical analysis of surgical correction of syndactyly. *Plast Reconstr Surg* 2010;125(03):963–968
- 72 Wall LB, Velicki K, Roberts S, Goldfarb CA. Outcomes of pediatric syndactyly repair using synthetic dermal substitute. *J Hand Surg Am* 2020;45(08):773.e1–773.e6
- 73 Edwards KE, Gannon NP, Novotny SA, Van Heest AE, Bohn DC. Complications in the 2-year postoperative period following pediatric syndactyly release [published online ahead of print. *J Hand Surg Am* 2022;2022(02):
- 74 Lumenta DB, Kitzinger HB, Beck H, Frey M. Long-term outcomes of web creep, scar quality, and function after simple syndactyly surgical treatment. *J Hand Surg Am* 2010;35(08):1323–1329
- 75 Goldfarb CA, Steffen JA, Stutz CM. Complex syndactyly: aesthetic and objective outcomes. *J Hand Surg Am* 2012;37(10):2068–2073
- 76 Garza A, Cordero JF, Mulinare J, Garza A. Epidemiology of the early amnion rupture spectrum of defects. *Am J Dis Child* 1988;142(05):541–544
- 77 Lindenau KF, Evers G. [An unusual case of bilateral and symmetric amniogenic indentations]. *Pediatr Grenzgeb* 1974;13(01):61–65
- 78 Goldfarb CA, Sathienkijkanchai A, Robin NH. Amniotic constriction band: a multidisciplinary assessment of etiology and clinical presentation. *J Bone Joint Surg Am* 2009;91(Suppl 4):68–75
- 79 Foulkes GD, Reinker K. Congenital constriction band syndrome: a seventy-year experience. *J Pediatr Orthop* 1994;14(02):242–248
- 80 Streeter GL. Focal deficiencies in fetal tissues and their relation to intrauterine amputation. *Contrib Embryol* 1930;22(126):
- 81 Bamforth JS. Amniotic band sequence: Streeter’s hypothesis reexamined. *Am J Med Genet* 1992;44(03):280–287
- 82 Torpin R. Amniochorionic mesoblastic fibrous strings and amniotic bands. Associated constricting fetal malformations or fetal death. *Am J Obstet Gynecol* 1965;91(01):65–75
- 83 Van Allen MI. Fetal vascular disruptions: mechanisms and some resulting birth defects. *Pediatr Ann* 1981;10(06):219–233
- 84 Satake H, Ogino T, Iba K, Watanabe T, Eto J. Metacarpal hypoplasia associated with congenital constriction band syndrome. *J Hand Surg Am* 2012;37(04):760–763
- 85 Patterson TJS. Congenital ring-constrictions. *Br J Plast Surg* 1961;14(C):1–31

- 86 Moran SL, Jensen M, Bravo C. Amniotic band syndrome of the upper extremity: diagnosis and management. *J Am Acad Orthop Surg* 2007;15(07):397–407
- 87 Gogola G. *The Pediatric Upper Extremity*. 1st edition (Abzug J, Kozin S, Zlotolow D, eds.). New York, NY: Springer; 2015
- 88 Upton J, Tan C. Correction of constriction rings. *J Hand Surg Am* 1991;16(05):947–953
- 89 Choulakian MY, Bruce Williams H. Surgical correction of band syndrome in Z-plasty with congenital constriction children: replacing direct closure. *Can J Plast Surg* 2008;16(04):221–223
- 90 Habenicht R, Hülsemann W, Lohmeyer JA, Mann M. Ten-year experience with one-step correction of constriction rings by complete circular resection and linear circumferential skin closure. *J Plast Reconstr Aesthet Surg* 2013;66(08):1117–1122
- 91 Mutaf M, Sunay M. A new technique for correction of congenital constriction rings. *Ann Plast Surg* 2006;57(06):646–652
- 92 Jiang Y, Mao H, Yang X, et al. Single-stage resection of Type II constriction rings in limbs on the basis of histologic and magnetic resonance imaging observations: A retrospective study of 21 consecutive patients. *Plast Reconstr Surg* 2016;138(01):164–173
- 93 Inglesby DC, Janssen PL, Graziano FD, Gopman JM, Rutland JW, Taub PJ. Amniotic band syndrome: Head-to-toe manifestations and clinical management guidelines. *Plast Reconstr Surg* 2023;152(02):338e–346e
- 94 Jones NF, Smith AD, Hedrick MH. Congenital constriction band syndrome causing ulnar nerve palsy: early diagnosis and surgical release with long-term follow-up. *J Hand Surg Am* 2001;26(03):467–473
- 95 Meyer H, Cummins H. Severe maternal trauma in early pregnancy: congenital amputations in the infant at term. *Am J Obstet Gynecol* 1941;42(01):150–153
- 96 Weeks PM. Radial, median, and ulnar nerve dysfunction associated with a congenital constricting band of the arm. *Plast Reconstr Surg* 1982;69(02):333–336
- 97 Tada K, Yonenobu K, Swanson AB. Congenital constriction band syndrome. *J Pediatr Orthop* 1984;4(06):726–730
- 98 Richardson GA, Humphrey MS. Congenital compression of the radial nerve. *J Hand Surg Am* 1989;14(05):901–903
- 99 Uchida Y, Sugioka Y. Peripheral nerve palsy associated with congenital constriction band syndrome. *J Hand Surg [Br]* 1991;16(01):109–112